THE QUARTERLY JOURNAL OF MEDICINE

EDITED BY

W. RUSSELL BRAIN
CRIGHTON BRAMWELL
W. D. W. BROOKS
D. M. DUNLOP
H. L. MARRIOTT
ROBERT PLATT

NEW SERIES, VOLUME XVIII
(VOLUME XLII OF THE CONTINUOUS SERIES)
1949

OXFORD
AT THE CLARENDON PRESS

Oxford University Press, Amen House, London E C 4
GLASGOW NEW YORK TORONTO MELBOURNE WELLINGTON
BOMBAY CALCUTTA MADRAS CAPE TOWN
Geoffrey Cumberlege, Publisher to the University

PRINTED IN GREAT BRITAIN
AT THE UNIVERSITY PRESS, OXFORD
BY CHARLES BATEY, PRINTER TO THE UNIVERSITY

CONTENTS

NEW SERIES, VOLUME XVIII, NUMBER 69, JANUARY 1949

Honeycomb Lungs By Neville Oswald and Thomas Parkinson. With Plates 1 to 4 1

Bronchoscopic Studies in Primary Tuberculosis in Childhood By James H Hutchison. With Plates 5 and 6 21

The Effect of Smoking on Water Diuresis in Man By J M Walker . 51

On the Nature and Significance of Stippling in Lead Poisoning, with Reference to the Effect of Splenectomy By A J S McFadzean and L J Davis With Plates 7 and 8 . 57

Reduction in Coronary Flow by Pituitary (Posterior Lobe) Extract in Relation to the Action of Nicotine and to Smoking By Edith Bülbring, J H Burn, and J M Walker 73

NUMBER 70, APRIL 1949

Massive Dilatation of the Left Auricle By Raymond Daley and Raymond Franks With Plates 9 to 14 . . 81

Primary Optic Atropy in von Recklinghausen's Disease (Multiple Neurofibromatosis) By E Dresner and D A D Montgomery With Plates 15 and 16 93

The Marchiafava Micheli Syndrome By John Marks . . 105

The Ocular Manifestations of Polyarteritis Nodosa By R N Herson and R Sampson With Plate 17 123

Cushing's Syndrome and Thymic Carcinoma By Douglas Hubble With Plates 18 to 20 . 133

A Clinical and Pathological Study of Renal Disease Part I Nephritis By J Davson and Robert Platt With Plates 21 and 22 . 149

NUMBER 71, JULY 1949

Chronic Agranulocytosis By E B Adams and L J Witts 173

Ankylosing Spondylitis By Robert Mowbray, Albert L Latner, and J Howard Middlemiss With Plates 23 to 26 . 187

The Retinal Vessels in Hypertension By Aubrey Leatham With Plates 27 and 28 203

Ankylosing Spondylitis By F Dudley Hart, K C Robinson, F M Allchin, and N F Maclagan With Plates 29 to 32 217

Carbohydrate Metabolism and Gastric Secretory Activity By Andrew Muir 235

Circulatory Dynamics in Emphysema By A D Gillanders 263

NUMBER 72, OCTOBER 1949

William Osler By Robert Hutchison 275

Idiopathic Thrombocytopenic Purpura By H N Robson 279

Three Cases of Thrombocytopenic Purpura occurring after Rubella, with a Review of Purpura associated with Infections By J F Ackroyd With Plate 33 299

The Syndrome of Hypopituitarism By H L Sheehan and V K Summers With Plates 34 to 37 319

Genetic and Environmental Factors in Congenital Heart Disease By Maurice Campbell 379

Proceedings of the Association of Physicians of Great Britain and Ireland, 1949 Forty-third Annual General Meeting 393

Sir William Osler By W W D Thomson 403

616 24-006.371.9

HONEYCOMB LUNGS[1]

By NEVILLE OSWALD and THOMAS PARKINSON

(From St Bartholomew's Hospital and Brompton Hospital, London)

With Plates 1 to 4

The confusion of terms in medical literature concerning cystic conditions of the lungs is well known Following the example of Koontz (1925) there has been a tendency to group together all such disorders, whether they be localized or generalized in distribution, or whether they derive from bronchial or alveolar tissue It is becoming increasingly evident that some cysts are secondary to bronchial obstruction, whilst others are closely related to bronchiectasis, there is also a smaller group in which the causative factor is not clear and for which the easy and often unjustified assumption that they are congenital is made

In the present paper it is proposed to describe a single variety of cystic disease in which there are thin-walled cysts distributed uniformly throughout the substance of both lungs, varying in size up to a maximum of 1 cm in diameter Sixteen such cases, including one previously reported by Fletcher (1901), have been collected In six the disease formed part of a general medical disorder and in 10 there was no evidence, or insufficient evidence, of disease outside the lungs The clinical features of the group are distinctive, namely, spontaneous pneumothorax which is frequently bilateral, and progressive right heart failure which is almost invariably the cause of death Similar cases have been described as 'congenital cystic disease' (Koontz, 1925), 'alveolar cystic disease', and 'cystic emphysema' (Willis and Almeyda, 1943; Pahard, Plauchu, Galy, and Papillon, 1946), but none of these terms appears justifiable in the present state of our knowledge In the absence of a satisfactory name incorporating an anatomical and aetiological description, the group is given the simple name of 'honeycomb lungs', being descriptive of the appearance of the cut surface of the lungs (Plate 3, Fig 9)

Honeycomb Lungs Associated with Other Disorders

Although individual cases have been reported in which honeycomb lungs have occurred in conjunction with other diseases such as xanthomatosis, tuberous sclerosis and allied disorders, biliary cirrhosis, and pituitary disorders, no attempt has been made to collect and correlate them The six cases reported here are grouped together with similar ones from the literature with a view to establishing their entity

Xanthomatosis Case 1, a female child aged nine months For four months prior to admission to hospital there had been swelling of the lymphnodes in the

[1] Received July 15, 1948

TABLE I

Honeycomb Lungs in Xanthomatosis

Author	Sex	Age at onset (years)	Duration (onset to death) (years)	Pulmonary symptoms: Spontaneous pneumothorax	Pulmonary symptoms: Right heart failure	Other symptoms: Bony lesions	Other symptoms: Exophthalmos	Other symptoms: Polyuria	Other symptoms: Jaundice	Other symptoms: Lymphadenopathy	Blood cholesterol (mg per 100 c.c.)	Radiological findings: Pulmonary reticulation	Radiological findings: Cranial defects	Radiological findings: Other bony defects	Pathological data: Lungs: Interstitial fibrosis	Pathological data: Lungs: Interstitial lipoid cells	Pathological data: Other organs affected
Rowland (1928)	M	5	<1	−	+	+	+	−	−	−	0	+	+	0	+	+	Bone, liver
Farber, Hampton, and Mueller (1942)	F	1½	<1	−	−	−	−	−	+	+	268	+	−	−	+	+	Liver, lymphnodes, kidney, uterus, tongue
Currens and Popp (1943)	F	29	A	−	−	+	−	−	−	−	177	+	+	+			Bone (biopsy)
Case 1 of present paper	F	5/12	4/12	−	+	+	−	−	−	+	0	+	+	+	+	+	Lymphnodes, thymus, bone

+ = Present − = Absent 0 = Not recorded A = Alive at time of report

neck, and occasional vomiting Three weeks before admission she was found to be anaemic On examination she was a very ill, blue infant There was no jaundice Large firm smooth cervical lymphnodes were present, and adherent to the deep structures There was dyspnoea, and bronchial breath sounds and coarse râles were heard over the lungs The liver and spleen were enlarged Death took place nine days after admission

Before death, a blood count showed haemoglobin 53 per cent, red cells 2,880,000 per c mm, and white cells 16,000 per c mm The Wassermann reaction was negative Radiological examination of the chest showed scattered opacities through both lung fields giving rise to a trabeculated appearance In the skull there were focal areas of rarefaction There was rarefaction and collapse in the dorsal spine

On post-mortem examination, the lungs showed a diffuse honeycomb appearance, the size of the cysts being up to 0 9 cm in diameter (Plate 3, Fig 11) Between the cysts there were confluent areas of organizing bronchopneumonia There were xanthomatous foci in the vault of the skull, basisphenoid, pituitary fossa, the body of the ninth thoracic vertebra, and the ninth left rib There were scattered xanthomatous nodules throughout the liver The spleen was enlarged but otherwise normal The cervical, coeliac, and lumbar lymphnodes were enlarged and infiltrated with xanthomatous material Microscopy showed granulomatous infiltration of the lungs and other affected organs with conspicuous multinucleate giant cells of the Touton type, some of which contained lipoid Lipoid was scanty in the lymphnodes There was no demonstrable infiltration of the spleen The thymus showed marked xanthomatous infiltration.

The occurrence of cystic changes in the lungs in xanthomatosis was first described by Rowland (1928), and a subsequent case (Farber, Hampton, and Mueller, 1942) was reported with similar changes Currens and Popp (1943) reported a case of Hand–Schuller–Christian disease with radiological changes suggestive of honeycomb lungs The main features of these three cases, together with our Case 1, are summarized in Table I Histologically the lungs showed fibrosis and lipoid-cell proliferation in the interstitial tissue in the three cases which came to autopsy, and in one (Rowland, 1928, 1929) there were papillary outgrowths into the lumina of the bronchioles, suggesting that partial bronchiolar obstruction might be a factor in the production of the air spaces The case of Currens and Popp (1943) showed the pulmonary changes at an older age than the fatal cases, these changes presumably represent a healing and fibrotic phase of the disease In addition to those cases in which cyst formation occurs, there are others which show pulmonary infiltration with interstitial lipoid histiocytosis and pulmonary fibrosis (Griffith, 1922, Thompson, Keegan, and Dunn, 1925, Turner, Davidson, and White, 1925, Kyrklund, 1926) Thannhauser (1940), in describing the normocholesterolaemic type of essential xanthomatosis, stated that a type occurs in which pulmonary changes may predominate He wrote that there was 'small, patchy, bronchial, pneumonic infiltration of the lung with xanthomatous granuloma tissue resulting in fibrosis of the lung' He emphasized that pulmonary lipoidosis never occurs alone, being always associated with infiltration of bones, lymphnodes, or dura Pulmonary infiltration without the honeycomb appearance has also been reported in Gaucher's disease

TABLE I

Honeycomb Lungs in Xanthomatosis

				Pulmonary symptoms		Other symptoms						Radiological findings			Pathological data		
															Lungs		
Author	*Sex*	*Age at onset (years)*	*Duration (onset to death) (years)*	*Spontaneous pneumothorax*	*Right heart failure*	*Bony lesions*	*Exophthalmos*	*Polyuria*	*Jaundice*	*Lymphadenopathy*	*Blood-cholesterol (mg per 100 c.c)*	*Pulmonary reticulation*	*Cranial defects*	*Other bony defects*	*Interstitial fibrosis*	*Interstitial lipoid cells*	*Other organs affected*
Rowland (1928)	M	5	<1	—	+	+	+	—	—	—	0	+	+	0	+	+	Bone, liver
Farber, Hampton, and Mueller (1942)	F	1½	<1	—	—	—	—	—	+	+	268	+	—	—	+	+	Liver, lymphnodes, kidney, uterus, tongue
Currens and Popp (1943)	F	29	A	—	—	+	—	—	—	—	177	+	+	+			Bone (biopsy)
Case 1 of present paper	F	5/12	4/12	—	+	+	—	—	—	+	0	+	+	+	+	+	Lymphnodes, thymus, bone

+ = Present — = Absent 0 = Not recorded A = Alive at time of report

cyst-like spaces surrounded by thick white walls representing cystic dilatations of the bile ducts The other organs were normal Microscopy of the lungs showed acute bronchitis The cystic spaces were lined with flat epithelium and the walls showed leucocytic infiltration There was vascular engorgement of the interstitial tissue and inflammatory cells were present in large numbers In the liver there was severe and widespread inflammation of the mucosa of the large bile ducts, the walls of which were considerably disorganized There was retention of bile in the lobular biliary vessels

Case 3, a male child aged two years and nine months, was admitted in September 1930 There was an indefinite history of loss of weight, cough, and shortness of breath On admission there were signs of bilateral bronchopneumonia and he also had faucial diphtheria He was transferred to a fever hospital, but re-admitted a month later with severe dyspnoea and cyanosis He was afebrile On examination his fingers were clubbed The percussion note over the chest was hyperresonant Rhonchi were present throughout the lungs During the next two weeks his condition deteriorated and he died from progressive heart failure On post-mortem examination, diffuse cystic changes were found throughout both lungs The liver was studded with pale nodules On microscopy, the lungs were inflamed, and there was a polymorphonuclear infiltration in the interstitial tissue The cyst spaces were irregular in size and contained varying degrees of epithelial lining In many places there were enlarged alveoli which appeared to coalesce in the formation of single large cysts The liver showed widespread subacute and chronic inflammation of the mucosa of the large bile ducts with concentric fibrosis The inflammatory cells were mostly mononuclear, plasma cells predominating

These two cases are separated from the others by the occurrence of inflammation of the bile ducts giving rise to hepatic biliary cirrhosis In neither case was there evidence of reticulum-cell proliferation of the type seen in the xanthomatoses or in the Letterer–Siwe disease, nor was the infecting organism identified It is difficult, however, to dissociate them completely from the reticuloses already discussed There is a remarkable similarity in their ages at death and in their pathological changes The case of Farber, Hampton, and Mueller (1942), which was described as an instance of the Letterer–Siwe disease, showed essentially a granuloma affecting the lungs, lymphnodes, bone-marrow, and liver, with biliary cirrhosis due partly to obstruction of the common duct by enlarged lymphnodes and granulation tissue, and partly to granulomatous invasion of the liver parenchyma Wallgren (1940) described a case of the Letterer–Siwe disease, without pulmonary manifestations, in which there was jaundice and hepatic fibrosis, produced by a granuloma-like proliferation of the cells of the reticulo-endothelial system In view of the rarity of honeycomb lungs in association with general medical disorders it is possible that these two cases represent an acute variety of reticulosis, alternatively their similarities may be regarded as a coincidence

Tuberous sclerosis and allied disorders Attention was first drawn to the occurrence of honeycomb lungs in tuberous sclerosis by Berg and Vejlens (1939) and the radiological and pathological details of their case were more fully described by Berg and Zachrisson (1941) and Vejlens (1941) Three other cases have since been reported (Samuelsen, 1942, Pallard, Plauchu, Galy,

(Merklen, Waitz, and Warter, 1933, Myers, 1937). It appears that pulmonary xanthomatosis is not very rare and that in the early stages there is a proliferation of reticulo-endothelial cells containing lipoid If healing takes place, the lipoid cells are replaced by diffuse interstitial fibrosis In a limited number of

TABLE II

Honeycomb Lungs Associated with Biliary Cirrhosis

			Respiratory symptoms		*Other symptoms*	
Author	*Sex*	*Age (years)*	*Right heart failure*	*Spontaneous pneumothorax*	*Hepatomegaly*	*Jaundice*
Case 2 of present paper (Fletcher, 1901)	M	$3\frac{1}{2}$	+	—	+	—
Case 3 of present paper	M	$2\frac{9}{12}$	+D	—	—	—

+ = Present — = Absent D = Cause of death

such cases cyst formation and a generalized honeycomb appearance of the lungs occurs

A few years ago a rapidly fatal aleukaemic reticulosis of infants was described by Letterer (1924) and Siwe (1933), which was later termed the Letterer–Siwe disease (Abt and Denenholz, 1936) The characteristic cell was a non-lipoid-containing large mononuclear, being found mainly in the liver, spleen, and lymphnodes, but occasionally invading the alveoli, alveolar walls, and pulmonary capillaries in large numbers More recently, views have been expressed that the Letterer–Siwe disease is not a specific form of reticulosis (Letterer, 1938, Farber, 1941, Jaffe and Lichtenstein, 1944) It is likely that Hand–Schuller–Christian disease, Letterer–Siwe disease, and the eosinophilic granuloma of bone of Otani and Ehrlich (1940) are all manifestations of the same disease, which may occasionally give rise to infiltration or even a honeycomb appearance of the lungs (Mallory, 1942)

Hepatic disorders in infancy The following two cases are reported as examples of honeycomb lungs occurring in infants in whom there was also evidence of biliary cirrhosis (Table II) The first of these cases (Case 2) was previously reported by Fletcher (1901)

Case 2, a male child aged $3\frac{1}{2}$ years, was admitted in April 1900 He had suffered from bronchitis when four months old Two weeks before admission he had had abdominal pain, which was followed by breathlessness and cough On examination he was a fat child The respiratory rate was 80 to 90 per minute Râles and rhonchi were heard over both lungs The liver was enlarged, but not the spleen There was no jaundice The urine contained no abnormal constituents He died with extreme dyspnoea five days after admission

On post-mortem examination, the lungs were voluminous, and the pleural surfaces studded with bullae The cut surface was reddish-grey and was riddled with spherical spaces, giving a honeycomb appearance There was no evidence of tuberculosis The liver weighed 600 gm and contained a large number of

and pathological data of these cases are summarized in Table III. It is noteworthy that all patients except one were female None of the cases of tuberous sclerosis showed any evidence of fits or imbecility, but all except one had adenoma sebaceum and subungual fibromata The case of Samuelsen (1942) is of particular interest as there were none of the usual manifestations of tuberous sclerosis during life, the diagnosis resting on typical histological changes in the lungs, brain, and kidneys at autopsy, emphasizing that the pulmonary lesions may be the sole clinical manifestation. The case of Pallard, Plauchu, Galy, and Papillon (1946) differs from all the other recorded cases in that the cystic changes were larger and not distributed so uniformly throughout the lungs The cases of Lutembacher (1918), Santos and Wohlwill (1942), and Burrell and Ross (1937) are examples of mesodermal embryonic neoplasms in which the lungs were diffusely infiltrated with leiomyomatous tissue (Plate 4, Fig 12) with the secondary production of cysts and in which there was a similar neoplasia in other organs In the cases described by de Fine Licht (1942), Rosendal (1942), and von Stössel (1937) there was simple but gross hyperplasia of smooth muscle in the lungs without involvement of other organs

The justification for considering these cases together lies in their pathological similarity, with pulmonary changes as a common factor The pathogenesis of tuberous sclerosis is imperfectly understood, but it is probably a developmental anomaly, either neoplastic or teratoplastic, to which the term 'neodysplasia' has been given (Wilson, 1940) The sites commonly affected are the brain, skin, kidneys, heart, and retina The visceral changes have been described as predominantly myomatous, angiomatous, fibrous, or lipomatous, or as any combination of these The origin of the muscle-tissue in the various tumours is uncertain, but it may derive from the blood-vessels, and be allied to the angiomatoses of the Hippel–Lindau and the Sturge–Weber syndromes (Hall, 1946) Incomplete forms of the disease occur and diffuse pulmonary myomatosis might well be the only manifestation in some cases

Pituitary disorders A few cases of honeycomb lungs have been reported in conjunction with diabetes insipidus, but in none has there been post-mortem proof of the aetiology of the pulmonary or pituitary disease In two patients in the present series there was evidence of pituitary abnormality.

Case 5, a boy aged 15 years, was admitted in January 1948 He was the eldest of seven children, his parents and the other children being healthy He had had an attack of mumps at the age of three years, but no other childhood ailments, and his early development had been normal At the age of seven years he had had an attack of whooping-cough, after which he had suffered from a persistent irritating cough, and it was noticed that he ceased to grow. During the three years before admission he had had frequent attacks of dyspnoea, and bouts of coughing lasting for several weeks, during which he produced purulent sputum Four months before admission he had been in another hospital with a right-sided spontaneous pneumothorax The lung had re-expanded after rest There was no history of polyuria or polydypsia On admission he was an unduly small but normally proportioned child His weight was 24 kilos and his height 129 cm His intelligence quotient was 75 per cent, his mentality corresponding

and Papillon, 1946, Berg and Nordenskjöld, 1946), and Loewenstein and Steel (1941) reported a case of tuberous sclerosis with retinal tumours in which there was 'infiltration of both lungs' in serial radiographs The following case is an example of tuberous sclerosis in which the radiological pulmonary changes were characteristic of honeycomb lung

Case 4, a woman aged 31 years Her only complaint was that she had suffered from dyspnoea on exertion for five years, which was insufficient to prevent her leading a normal life She had never suffered from fits and there were no mental changes She had had adenoma sebaceum of the face since the age of three years and this had been confirmed by biopsy Nothing was known of her family history except that one sister was said to suffer from asthma There was no history of rheumatic fever or other illness On examination she was a well-developed woman with a normal mentality There was adenoma sebaceum of the cheeks and subungual fibromata of the toes Retinoscopy was normal The heart was normal in size and there was a systolic and diastolic murmur at the apex There were no abnormal signs in the lungs Both kidneys were palpable and the spleen could just be felt on full inspiration There was no clubbing of the fingers

The white cells were 8,600 per c mm , and differential count, neutrophils 81 per cent , lymphocytes 14 per cent , monocytes 4 per cent , and eosinophils 1 per cent The erythrocyte sedimentation rate was 10 mm in one hour (Wintrobe) The Mantoux reaction was positive to a 1/10,000 dilution The plasma-proteins were total 6 3 gm per 100 c c , albumin 3 6 gm , globulin 2 4 gm , and fibrinogen 0 3 gm per 100 c c Radiological examination showed a diffuse reticulation throughout both lungs (Plate 1, Fig 1). Excretion pyelography showed enlargement of the left kidney, the calyces and pelvis of which were displaced downwards, suggesting a cyst or tumour in the upper pole The skull was normal The long bones showed no abnormality apart from a slight periosteal reaction in the middle thirds of the tibiae and a small cortical erosion on the proximal phalanx of the left second finger The urine contained no albumin or abnormal deposits

The combination of adenoma sebaceum, subungual fibromata, and characteristic pulmonary changes is sufficient for a diagnosis of tuberous sclerosis, so that the tumour in the left kidney is almost certainly a myoma The mitral diastolic murmur might possibly be due to myomatous infiltration of the heart, in view of the complete absence of evidence of a rheumatic origin In addition to these cases of unequivocal tuberous sclerosis a number of similar but obscure cases has been reported in which there were honeycomb lungs associated with multifocal mesodermal dysplasia of a kind resembling that found in tuberous sclerosis, but the characteristic clinical signs of this disease were absent and histological examination of the brain was not recorded (Lutembacher, 1918, Santos and Wohlwill, 1942, Burrell and Ross, 1937) A third group of cases has also been described which, from the nature of the histological changes, seems to be allied to tuberous sclerosis This group is characterized by honeycomb lungs showing histologically a vast increase in muscular tissue Von Stössel (1937) described two such cases under the title of 'muscular cirrhosis of the lung' De Fine Licht (1942) and Rosendal (1942) described similar cases and postulated that they were *formes frustes* of tuberous sclerosis The main clinical

to that of a child of 10 years There was gross clubbing of the fingers and toes There was no growth of pubic hair, the testicles were undescended, and the voice unbroken No abnormality was found in the central nervous system The pulmonary second heart sound was accentuated The blood-pressure was 110/70 The chest was thin, the lower part of the sternum prominent, and there was a Harrison's sulcus Râles and rhonchi were heard over both lungs The liver and spleen were not enlarged

The average daily urinary output was 750 c c , and there was no abnormal urinary deposit The daily amount of sputum was 30 c c , and examination for tubercle bacilli negative The predominant organisms on culture were *Streptococcus viridans* and *Neisseria catarrhalis* The Wassermann reaction was negative A blood count showed haemoglobin 100 per cent , red cells 5,400,000 per c mm , and white cells 10,000 per c mm , the differential count being within normal limits A glucose tolerance curve was normal The basal metabolic rate was —37 per cent The vital capacity was 500 c c The blood-urea was 20 mg per 100 c c and the plasma-cholesterol 230 mg per 100 c c The plasma-proteins were 8 5 gm per 100 c c The Mantoux reaction was positive to 1/1,000 dilution An electrocardiogram showed right axis deviation with peaking of the P wave in Lead II A liver biopsy showed normal liver structure Liver function tests revealed no abnormality Radiological examination of the chest showed a fine reticulation through both lung fields with numerous ring shadows from 3 to 5 mm in diameter Tomography confirmed the presence of the ring shadows A bronchogram on the left side was normal, none of the cyst spaces filling with oil (Plate 2, Fig 8) X-rays of the skeleton showed that all bones were small, corresponding in size with those of a child of seven years The epiphyses were normal and corresponded in age to about 13 years The calcium content of the bones was normal The skull was small but otherwise normal The dwarfism was considered to be of pituitary origin

Case 6, a man aged 36 years, was admitted in May 1936 with breathlessness, cough, and a trace of sputum The family history was not significant For nine years he had suffered from diabetes insipidus and was in the habit of drinking about 24 pints of fluid daily In 1930 he had had a right spontaneous pneumothorax On examination he was emaciated and had a dry atrophic skin There was excessive pigmentation of the abdomen and natal cleft Clubbing of the fingers was present There were moist sounds over both lungs No other abnormal signs were present In August 1936 he was readmitted with a sore throat and enlarged cervical lymphnodes He was blue and dyspnoeic There was no radiological evidence of pneumothorax He was re-admitted in November 1936 with dyspnoea Examination showed that the liver and spleen were palpable, and there was a soft mass behind the left sternomastoid The patient discharged himself from hospital after three weeks No other information is available, except that he died in 1937

On each admission radiographs of the lung fields showed a coarse reticulation and mottling throughout (Plate 1, Fig 2) No spontaneous pneumothorax was seen The skull was normal A blood count showed red cells 8,200,000, and white cells 11,800 per c mm The sputum amounted to 30–120 c c daily, and examinations were negative for tubercle bacilli

The details of these cases are summarized in Table IV, and compared with others from the literature The only case which came to autopsy was that of Occlsli and Miles (1934) and here the lungs showed a diffuse honeycomb structure, and the interstitial tissue consisted mainly of connective tissue and

TABLE III

Honeycomb Lungs in Tuberous Sclerosis and Allied Disorders

Classification of case	Authors	Sex	Age at onset (years)	Duration (onset to death) (years)	Family history of tuberous sclerosis	Respiratory symptoms: Spontaneous pneumothorax	Respiratory symptoms: Right heart failure	Symptoms of tuberous sclerosis: Adenoma sebaceum	Symptoms of tuberous sclerosis: Fits	Symptoms of tuberous sclerosis: Imbecility	Symptoms of tuberous sclerosis: Subungual fibromata	Radiological reticulation of lungs	Other organs affected	Author's opinion
Tuberous sclerosis	Berg and Vejlens (1939)	F	30	2	+	++	+D	+	—	—	+	+	Brain, kidneys, spleen	Tuberous sclerosis
	Berg and Nordenskjöld (1946)	F	29	3	+	+	+D	+	—	—	+	+	Pelvic angiomyomata	Tuberous sclerosis
	Samuelsen (1942)	F	40	0	—	—	+D	—	—	—	—	+	Brain, kidneys, bone	Tuberous sclerosis
	Pallard, Plauchu, Galy, and Papillon (1946)	F	39	A	0	—	—	+	—	—	+	0		Tuberous sclerosis
	Case 4 of present paper	F	27	A	—	—	+	+	—	—	+	+	Kidneys, spleen	Tuberous sclerosis
Multifocal mesodermal dysplasia	Lutembacher (1918)	F	36	0	0	++D	+	0	0	0	0	0	Kidneys	Dysembryoma
	Santos and Wohlwill (1942)	F	31	9	0	?	?	0	0	0	0	+	Uterus, lymphnodes	Lipo myoangioma
	Burrell and Ross (1937)	F	34	2	0	—	+D	0	0	0	0	0	Abdominal lymphnodes	Leiomyosarcoma
'Myomatosis of lungs'	de Fine Licht (1942)	F	63	4	+	—	+D	0	0	0	0	+	Hilar lymphnodes	Tuberous sclerosis
	Rosendal (1942)	F	44	7	0	—	+D	0	0	0	0	+	None	Tuberous sclerosis
	von Stössel (1937)	M	44	7	0	+	+D	0	0	0	0	+	None	Muscular cirrhosis
	von Stössel (1937)	F	42	1	0	+	+D	0	0	0	0	+	None	Muscular cirrhosis

+ = Present — = Absent ++ = Bilateral D = Cause of death A = Alive at time of report 0 = Not recorded

improvement On March 8, 1945, she suddenly developed a tension pneumothorax on the left, which was relieved by aspiration Her progress was satisfactory until March 22, 1945, when she suddenly collapsed, became blue, and died Permission for a post-mortem examination was not obtained Before death, X-rays showed a thin-walled honeycomb appearance throughout both lungs The cardiac outline suggested cor pulmonale

Case 8, a boy aged 12 years, was admitted in May 1941 He had had a cough during the first few weeks of life which had been regarded as whooping-cough, and had had bronchopneumonia at the age of 15 months In 1940 he had had an attack of dyspnoea lasting two weeks In April 1941 he had had a febrile illness with a dry cough from which he recovered, and this was followed by progressive dyspnoea for which he was admitted At this time there was no cough. He stated that he had been passing excessive amounts of urine during the three months prior to admission On examination he was found to have a spontaneous pneumothorax on the right side The pleural pressures were −4, +14 cm of water Continuous suction was applied to the right pleural space On the following day he developed a spontaneous pneumothorax on the left side (pressures −9, +4 cm of water) and this was also treated by continuous suction During the next two months he had repeated attacks of spontaneous pneumothorax affecting both lungs, which necessitated almost continuous intrapleural suction On July 19, 1941, two minims of 10 per cent silver nitrate solution were introduced into the left pleural space whilst suction was maintained on the right, and on July 31, 1941, three minims of 10 per cent silver nitrate solution were injected into the right pleural space As expansion was incomplete a further two minims of silver nitrate solution were introduced into the left pleural space on August 24, 1941 In September 1941 a left-sided empyema was treated by intercostal drainage After a prolonged illness both lungs eventually re-expanded and he was discharged from hospital in April 1942 A radiograph at that time showed no appreciable abnormality in the lungs The sputum was negative for tubercle bacilli A Mantoux reaction was not done During the first two weeks of his stay in hospital the urinary output varied from four to six litres daily with an average of 4 9 litres The urine had a specific gravity of 1 001 and contained no abnormal constituents Treatment with pituitrin improved the polyuria (full details not available) After discharge he remained well for about a year, but was re-admitted in April 1943 with an acute febrile illness He was found to have tuberculous pneumonia of the right lung, from which he died in May 1943

Post-mortem examination showed diffuse cystic changes throughout both lungs, the cysts being separated by fibrous strands containing blood-vessels In addition there was caseous tuberculosis of the right lower lobe The abdominal organs were normal The brain was not examined Microscopy showed that the cysts were lined by flattened epithelium, the septa were infiltrated with round cells

Case 9, a male medical student aged 26 years, was admitted and died on March 21, 1944 He had had three attacks of spontaneous pneumothorax in 1934, and since that time had had recurrences at yearly intervals On the day of admission to hospital he suddenly developed severe pain in the right side of the mouth which spread downwards to the sternum, becoming progressively more severe On examination he was profoundly shocked, sweating, and restless The left pulse was stronger than the right, and a to-and-fro murmur was heard over the precordium He died seven hours after admission

Post mortem, there was a dissecting aneurysm of the aorta originating from

muscle fibres Histologically the pituitary was said to 'resemble parathyroid tissue', but no details are given All but one of the cases had diabetes insipidus and that of Oechsli and Miles (1934) had Fröhlich's syndrome in addition The radiological changes were identical in each case and all suffered from spontaneous pneumothorax The nature of the pathological changes responsible for

TABLE IV

Honeycomb Lungs Associated with Pituitary Disorders

				Respiratory symptoms			*Radiological changes*	
Authors	*Sex*	*Age at onset (years)*	*Duration (onset to death) (years)*	*Spontaneous pneumothorax*	*Right heart failure*	*Pituitary symptoms*	*Reticulation in lungs*	*Bony erosions*
Oechsli and Miles (1934)	M	17	5	++	+D	Diabetes insipidus, Fröhlich's syndrome	+	0
Berg and Zachrisson (1941)	M	30	A	++	—	Diabetes insipidus	+	0
Ackermann (1944)	F	25	A	+	—	Diabetes insipidus	+	+
Case 5 of present paper	M	15	A	+	+	Pituitary dwarf	+	—
Case 6 of present paper	M	38	7	+	+	Diabetes insipidus	+	0

— = Absent + = Present ++ = Bilateral 0 = Not recorded
A = Alive at time of report D = Cause of death

this combination is not established Berg and Zachrisson (1941) and Ackermann (1944) suggested that such cases may well be examples of tuberous sclerosis in which the changes are confined to the lungs and the pituitary gland, in support of this contention, Ackermann (1944) stated that his case showed bony erosions of the spine, pelvis, and femur consistent with such a diagnosis In the absence of further proof it must be assumed that the lungs and pituitary gland are sometimes affected by a similar process, and the possibility of tuberous sclerosis and of xanthomatosis should be borne in mind

Honeycomb Lungs of Uncertain Aetiology

The following cases, arranged according to the age of onset of symptoms, showed little or no evidence of disease outside the lungs and the patients suffered either from spontaneous pneumothorax or right heart failure at the time of diagnosis

Case 7, a girl aged seven years, was admitted to hospital in February 1945 There was no past history of chest disease and the family history was negative For 10 days before admission she had suffered from increasing dyspnoea and cyanosis On admission she was deep blue and had a respiration rate of 84 per minute There were signs of a right spontaneous pneumothorax with gross mediastinal displacement A radiograph of the chest showed the right lung to be about 60 per cent collapsed and there was a shallow apical pneumothorax on the left The right pneumothorax was treated by under-water drainage, with

were present Sputum examination was negative for tubercle bacilli Radiographs of the chest confirmed the right-sided pneumothorax and showed diffuse coarse reticulation throughout both lungs Three days after admission he developed a left spontaneous pneumothorax Intrapleural pressures were right 0, +6, and left −10, +4 cm of water The right side was treated with continuous suction for a week, at the end of which time 1 c c of gomenol in olive oil was introduced An effusion and obliterative pleurisy developed Two weeks later a left valvular pneumothorax developed and this was also treated with continuous suction followed by gomenol in olive oil The pleural reaction was not satisfactory and the left-sided pneumothorax persisted A tomogram (Plate 2, Fig 5) showed the cysts on the left side The patient discharged himself from hospital in July 1940 and returned to India He has not been traced since

Case 12, a male compositor aged 24 years, was admitted in July 1947 He had been perfectly well until seven months before admission, since when he had suffered from increasing breathlessness and tightness in the chest On examination he had a left-sided pneumothorax A week later he suddenly developed cyanosis and intense dyspnoea He had signs of bilateral pneumothorax for which 1,400 c c of air were removed from each pleural space, with relief On the following day he became more dyspnoeic due to further collapse of the right lung, and was treated with continuous oxygen During the following 10 weeks he had recurrent attacks of spontaneous pneumothorax on both sides He was treated with continuous intrapleural suction, and both lungs eventually remained expanded He was discharged in November 1947 with a small residual apical pneumothorax on the left There has been no further pneumothorax since discharge, but he now has some dyspnoea on exertion which was not present before his illness

Radiographs showed a reticular pattern throughout both lungs, appearing to surround air-spaces of 1 to 2 cm in diameter (Plate 2, Fig 6), and being much more obvious when the lungs were collapsed than when they were expanded Bronchography showed a normal bronchial tree, and there was no filling of the cyst spaces Sputum examination was negative for tubercle bacilli A blood count showed haemoglobin 126 per cent , red cells 6,400,000 per c mm , and white cells 7,200 per c mm An electrocardiogram was normal A sister of this patient was subsequently admitted to hospital with a spontaneous pneumothorax, no radiological evidence of honeycomb lungs was found

Case 13, a housewife aged 26 years, was admitted in May and December 1947 During childhood she had suffered from whooping-cough and cervical adenitis, and in 1941 had had meningitis which was treated with sulphonamides In June 1946 she began to suffer from increasing dyspnoea on effort, and in May 1947, towards the end of her second pregnancy, was admitted to hospital with urgent dyspnoea and oedema of the legs On examination she was orthopnoeic and blue There was venous engorgement in the neck and oedema of the legs The fingers were long and thin There was no clubbing The lungs were hyperresonant to percussion and air entry was everywhere diminished The pulse rate was 130 and a diastolic triple rhythm was heard She was delivered of a normal child, after which there was steady improvement and she discharged herself from hospital in June 1947, at which time she still had moderate dyspnoea on exertion She remained fairly well, but had a haemoptysis of several ounces in October 1947 In December 1947 she was re-admitted with severe dyspnoea and mental confusion Jugular venous pressure was raised and there was oedema

a transverse tear one inch above the aortic ring The aorta showed mediconecrosis idiopathica cystica The dissecting aneurysm had ruptured into the pericardium Both lungs showed diffuse cystic changes, which were regarded as being congenital in origin There were scars on the visceral pleura No histological data are available

Case 10, a male clerk, was first seen in November 1945 at the age of 18 years, with dyspnoea and pain in the chest, of sudden onset He gave no history of chest disease and had played football until the onset of his symptoms His family history was irrelevant On examination he was found to have a pneumothorax on the left side, radiographs showing a honeycomb appearance throughout both lungs, much more obvious on the side of the pneumothorax He rested at home and the lung re-expanded in a month In January 1946 he was admitted to hospital with a recurrence of pain and dyspnoea, radiographs showing a left-sided pneumothorax The left lung expanded apart from a shallow apical pneumothorax, and he was discharged from hospital in February 1946 He was re-admitted three weeks later with a recurrence of symptoms Radiographs showed an 80 per cent pneumothorax on the right side and a shallow pneumothorax on the left The right lung in its collapsed state showed a honeycomb structure similar to that previously seen on the left side on the first film (Plate 1, Figs 3 and 4) Air was removed from the right pleural space on several occasions, but the lung remained collapsed In March 1946 0 5 c c of 10 per cent silver nitrate solution was introduced into the right pleural space and air withdrawn A satisfactory pleural reaction developed and the right lung remained expanded He was discharged in April 1946 He remained in good health until August 1946 when he developed extreme dyspnoea and was re-admitted, with a respiration rate of 48 per minute Radiographs showed a partial pneumothorax on the left side and a small pneumothorax at the right base He was treated with oxygen and the dyspnoea improved Further films, however, showed little change in either side during the next month Left-sided pleurodesis was performed in October 1946 and right-sided pleurodesis in November 1946, with 0 5 c c of 10 per cent silver nitrate solution on each occasion Both lungs remained expanded, and he was discharged from hospital in December 1946 He has been observed as an out-patient since that time and has remained in good health There has been no further spontaneous pneumothorax, but since December 1947 he has noticed slight dyspnoea on exertion

The Wassermann reaction was negative The blood-cholesterol was 230 mg per 100 c c , and blood-urea 23 mg per 100 c c Liver biopsy showed normal liver histology The skull and long bones were radiologically normal Bronchograms showed a normal bronchial tree, the oil did not enter any of the cysts Tomograms showed a fine reticular pattern throughout both lung fields with a honeycomb appearance most easily seen in the periphery An electrocardiogram in March 1948 showed right axis deviation, but was otherwise normal

Case 11, a male Indian medical practitioner aged 24 years, was admitted in April 1940 There was no family history of chest disease The patient had suffered from malaria, and had had attacks of asthma during the two years before admission In August 1939, after lifting a heavy weight, he had had an attack of pain in the right side of the chest which lasted a few days During the next six months there had been five similar attacks, usually after exertion Four days before admission he had had a similar but more severe attack accompanied by dyspnoea On examination there were signs of a pneumothorax on the right side, and a moderate number of râles, mainly on the left There was clubbing of the fingers The spleen was palpable No other abnormal signs

was enlarged and there was oedema of the legs He died within a few hours of admission.

On post-mortem examination, the lungs filled the thoracic cavity and did not collapse Both lungs showed a typical honeycomb appearance (Plate 3, Fig 9), the cysts being separated by collapsed pulmonary tissue in which there was apparently no fibrosis The bronchi were normal The pulmonary arterial branches were prominent and atheromatous There was hypertrophy of the right ventricle The liver was enlarged and showed chronic venous congestion All the other organs were normal

Case 16, a male labourer aged 57 years, was admitted to hospital in November 1947 There was no past history or family history of chest disease He complained of shortness of breath which had been increasing over the previous two years He had a morning cough and produced a little frothy clear sputum. On examination there was clubbing of the fingers He was blue and dyspnoeic There were coarse râles over the chest, but no other abnormal signs

A blood count showed haemoglobin 90 per cent and white cells 9,400 per c mm. The Wassermann reaction was negative The erythrocyte sedimentation rate was 4 mm in one hour (Westergren) Radiographs of the chest showed coarse reticulation throughout both lungs Sputum examination was negative for tubercle bacilli

He was discharged in December 1947 A few days later he died suddenly in the street Post-mortem examination showed gross pulmonary fibrosis with diffuse cystic disease The cystic air spaces were rather larger in the peripheral portions of the lungs The whole lung was firm and rubbery Microscopy showed that some air spaces had a thin epithelial lining which was columnar or flat, and others had none There was an increase in fibrous tissue throughout and the interstitial tissue was intensely vascular and contained inflammatory cells

The significant details of these cases are summarized in Table V Eight cases occurred in male and two in female subjects Spontaneous pneumothorax was seen predominantly in the younger age-group (range seven to 24 years, average 16·6 years) and right heart failure in the older patients (range 25 to 55 years, average 39 8 years) None of the patients dying from right heart failure gave a previous history of spontaneous pneumothorax This observation, which contrasts with the frequent concurrence of these two symptoms in the patients with honeycomb lungs associated with other diseases, suggests a difference in the nature of the cystic disease in the two age-groups

The pathological changes in the three cases which came to autopsy showed a striking similarity The normal lung structure was largely replaced by air-containing cystic spaces varying in size from those just visible to the naked eye to others about 1 cm in diameter The cyst walls contained no cartilage, the cysts being separated by thick fibrous septa amongst which were irregular areas of relatively normal aerated lung The thick septa consisted of dense collagen and contained blood-vessels There was a variable amount of polymorphonuclear infiltration throughout the interstitial tissue Some of the cyst spaces were lined with flat epithelium, and others had no epithelial lining In the sections so far examined, convincing evidence of bronchiolar obstruction has not been found Further histological studies are in progress It seems evident from the nature of the cyst walls that haemo-respiratory exchange in the cysts is minimal

of the dependent parts She was nursed in an oxygen tent and treated with penicillin Her condition deteriorated and she died 10 days later

Radiographs of the chest showed enlargement of the pulmonary conus, a honeycomb appearance was present in the right middle and lower zones A blood count showed haemoglobin 78 per cent and red cells 4,000,000 per c mm An electrocardiogram showed right axis deviation, and the P wave in Lead II was high and spiked The vital capacity in May 1947 was 2 litres The arterial oxygen saturation, whilst the patient was in an oxygen tent, was 72 per cent

Post-mortem examination showed diffuse cystic changes throughout both lungs In the heart there was a widely patent foramen ovale, and the right ventricle was hypertrophied There was embolic occlusion of the left posterior cerebral artery All organs showed venous congestion The body was long, the arms and legs thin, and the fingers and the toes were long, thin, and tapering Microscopy showed that some of the cysts were lined with a flattened epithelium and that others had no epithelium There was an increase in fibrous connective tissue and interstitial inflammation Inflammatory changes were present in the bronchi and alveoli

Case 14, a male instrument-maker aged 27 years, was admitted in November 1944 One sister had died from pulmonary tuberculosis He had been subject to bronchitis in the winter until the age of 10 years In January 1943 he had begun to suffer from breathlessness and cough His breathlessness had been progressive until admission He produced less than an ounce of sputum daily On examination he was dyspnoeic and blue There was no clubbing of the fingers The heart and blood-pressure were normal Many râles and rhonchi were present over the lungs The liver was not palpable and there was no oedema of the limbs A month later he suddenly became bluer, coughed up a little blood-stained frothy sputum, and died from acute right-sided heart failure within an hour

Before death, on radiography, the heart showed a large pulmonary conus, and the lungs a diffuse honeycomb structure throughout The Mantoux reaction was positive to 1/10,000 dilution Sputum examination was negative for tubercle bacilli

On post-mortem examination, the lungs were firm and elastic, having a rubbery consistency in the lower lobes On the upper lobes there were numerous surface bullae Section of the lungs showed air-containing cyst spaces throughout their substance (Plate 3, Fig 10) The hilar lymphnodes were enlarged The heart showed considerable dilatation of the right side The abdominal organs showed chronic venous congestion, but no other abnormality The brain was not examined On microscopy, the cyst spaces were mostly devoid of epithelial lining, but occasional areas of flat epithelium remained The septa varied in thickness and there was an increase in fibrous tissue The stroma was intensely vascular, there was moderate infiltration with inflammatory cells, and some anthracotic pigment was present The few remaining alveoli contained a serous or inflammatory exudate

Case 15, a male salesman aged 54 years, was admitted and died on November 14, 1944 The family history was negative There had been no pulmonary symptoms until 18 months before death, when he began to suffer from breathlessness and cough which became progressively worse A radiograph taken at the end of 1943 showed honeycomb lungs (Plate 2, Fig 7) Two days before admission he became extremely dyspnoeic and exhausted On examination he was blue and had laboured breathing There was no clubbing of the fingers There were moist sounds over both lungs The pulse-rate was 140 The liver

varying from fine (Plate 1, Fig 1) to coarse (Plate 1, Fig 2) The cyst spaces are consistently much more obvious in a lung partially collapsed by spontaneous pneumothorax than in the same lung completely re-expanded (Plate 1, Figs 3 and 4) Tomograms were done in only four cases and clearly demonstrated the honeycomb appearance in each Bronchograms, also performed in four cases, showed no bronchial abnormality, in no case did the cyst spaces fill with opaque oil, even after coughing Occasionally the opaque oil appeared to outline the walls of the cysts, as a result of distortion of the smaller bronchi around the cysts Interpretation of these findings may be far from easy, as many diseases give rise to reticulation in the lungs Similar, but not identical, appearances may be caused by pneumoconiosis, sarcoidosis, lymphangitis, carcinomatosis, chronic miliary tuberculosis, and other conditions producing scattered pulmonary disease (Berg and Zachrisson, 1941, Fletcher, 1948) Radiological diagnosis depends on the identification of the cysts throughout both lungs, reticulation, and a normal bronchial tree The cysts are often best demonstrable behind the sternum in a lateral film, or in a tomogram

Pathogenesis The causation of these widespread alveolar cysts is unknown In general, it may be assumed either that they arise as a developmental abnormality or that they are secondary to mechanical factors resulting from acquired disease When the nature of the underlying pulmonary disorder is known, the cysts may be produced by impeded expiration due to bronchial obstruction (Laënnec, 1819, Koontz, 1925) or by stress in the more normal parts of the lungs after widespread alveolar destruction elsewhere These mechanisms probably apply to the honeycomb structure of the lungs in the cases of xanthomatosis and tuberous sclerosis and allied disorders, and resemble those responsible for the focal emphysema of pneumoconiosis (Williams, 1944, Heppleston, 1947)

The cause of the honeycomb lungs in the patients in whom the nature of the pulmonary disease is unknown is less easy to determine No case in the present series showed convincing evidence of developmental defects outside the lungs, such as were seen in a case reported by Rubin (1947) He found, at autopsy on a girl of 12 years, multiple simple cysts throughout both lungs associated with patent ductus arteriosus, congenital aneurysms of the pulmonary arteries, and anomalous coronary arteries To conclude that such pulmonary cysts were developmental seems inescapable Our Case 7 had no history of pulmonary disease until a few weeks before her death at the age of seven years, from bilateral spontaneous pneumothorax, by which time she had well-marked honeycomb lungs In the absence of post-mortem material it is impossible to exclude a developmental cause In Case 12 the cysts appear radiologically to be rather larger than usual and to have particularly thin walls, features which were also seen in Rubin's case and suggest a developmental origin However, it seems probable that, in the majority of these cases, the mechanism of cyst formation is similar to that already discussed in the group of cases in which the nature of the underlying disease is known, that is, a mechanical factor operating on a diseased lung All the lungs examined histologically have shown extensive

or absent, and that life is maintained by virtue of the remaining normal alveoli Similar changes have been described by Kerley, Shore, and Young (1927), Weiss (1936), Nolte (1937), Cole and Nalls (1938), Bruce (1939), and Calma (1941) Histological data are not available in any of the cases in the younger age-group

TABLE V

Honeycomb Lungs of Uncertain Aetiology

Cases (all from present paper)	*Sex*	*Age at onset (years)*	*Duration (onset to death) (years)*	*Respiratory symptoms*		*Radiological reticulation of lungs*	*Other findings*
				Spontaneous pneumothorax	*Right heart failure*		
Case 7	F	7	0	++D	–	+	
Case 8	M	12	2	++	–	+	Transient polyuria
Case 9	M	16	10	++	–	0	Dissecting aneurysm (D), medionecrosis idiopathica cystica of aorta
Case 10	M	18	A	++	–	+	
Case 11	M	23	A	++	–	+	
Case 12	M	24	A	++	–	+	Sister had spontaneous pneumothorax
Case 13	F	25	1	–	+D	+	Patent foramen ovale, arachnodactyly
Case 14	M	26	1	–	+D	+	
Case 15	M	53	1	–	+D	+	
Case 16	M	55	2	–	+D	+	

+ = Present – = Absent D = Cause of death 0 = Not recorded
++ = Bilateral A = Alive at time of report

In two cases there was a co-existing developmental abnormality, in another the sister of the patient had had a spontaneous pneumothorax without other radiological evidence of pulmonary abnormality One patient had transient polyuria which suggests that there had been a hypothalamic or pituitary disturbance in addition

Discussion

Clinical features Irrespective of the aetiology of honeycomb lungs, the respiratory symptoms are the same Tables I to V show that eight patients in the present series suffered from spontaneous pneumothorax and that in five it was bilateral The remaining eight had dyspnoea which, in those cases followed for long enough periods, was progressive, in four death took place from progressive cor pulmonale within two years of the onset of respiratory symptoms Similarly, in the case histories extracted from other papers, spontaneous pneumothorax and progressive dyspnoea have predominated, and have frequently occurred together in the same patient

Radiological appearances In spite of the diverse conditions responsible for honeycomb lungs in the present series of cases, the radiological appearances are remarkably constant Throughout both lung fields a reticular pattern is seen,

E F Scowen, C J Fuller, Arthur Willcox, Russell Fraser, J M. Ross, Bertram Jones, G A Emmerson, and F Ray Bettley, and Mr Ivor Lewis for permission to publish their cases

REFERENCES

Abt, A F, and Denenholz, E J (1936) *Amer J, Dis Child* **51**, 499
Ackermann, A. J (1944) *Amer J Roentgenol* **51**, 315
Berg, G, and Nordenskjöld, A (1946) *Acta med scand* **125**, 428
—— and Vejlens, G (1939) *Acta paediat* **26**, 16
—— and Zachrisson, C G (1941) *Acta radiol* **22**, 425
Blumgart, H L, and MacMahon, H E (1929) *Med Clin N Amer* **13**, 197.
Bruce, T (1939) *Acta med, scand* **102**, 295
Burrell, L S T, and Ross, J M (1937) *Brit J Tuberc* **31**, 38
Calma, I (1941) *Ibid* **35**, 40
Cole, D B, and Nalls, W L (1938) *J Lab clin Med* **24**, 147
Currens, J H, and Popp, W C (1943) *Amer J med Sci* **205**, 780.
de Fine Licht, E (1942) *Acta radiol* **23**, 151
Farber, S (1941) *Amer J Path* **17**, 625
—— Hampton, A O, and Mueller, H L (Cabot Case 28101) (1942) *New Engl J. Med.* **226**, 392
Fletcher, C M (1948) *Brit med J* **1**, 1015
Fletcher, H M (1901) *Trans path Soc Lond* **52**, 193
Fraenkel, A (1902) *Dtsch Arch klin Med* **73**, 484
Griffith, J P C (1922) *Arch Paediat* **39**, 297
Hall, G S (1946) *Quart J Med*, N S **15**, 209
Heppleston, A G (1947) *J Path Bact* **59**, 453
Jaffe, H L, and Lichtenstein, L (1944) *Arch Path* **37**, 99
Kerley, P J, Shore, L R, and Young, W A (1927) *Lancet*, **2**, 699
Koontz, A R (1925) *Bull Johns Hopk Hosp* **37**, 340
Kyrklund, R (1926) *Z Kinderheilk* **46**, 56
Laënnec, R T H (1819) *Traité de l'auscultation médiate*, Paris.
Lange, W (1901) *Dtsch Arch klin Med* **70**, 342
Letterer, E (1924) *Frankfurt Z Path* **30**, 377
—— (1938) *Verh Ges Verdaukr* **14**, 12
Loewenstein, A, and Steel, J (1941) *Amer J Ophth* **24**, 731.
Lutembacher, R (1918) *Ann Med* **5**, 435
Mallory, T B (1942) *New Engl J Med* **227**, 955.
Merklen, P, Waitz, R, and Warter, J (1933) *Ann Med* **33**, 97.
Myers, B (1937) *Brit med J* **2**, 8
Nolte, A F (1937) *Fortschr Röntgenstr* **55**, 273
Oechsli, W R, and Miles, S H (1934) *Amer Rev Tuberc* **30**, 239.
Otani, S, and Ehrlich, J C (1940) *Amer J Path* **16**, 479
Pahard, Plauchu, Galy, P, and Papillon (1946) *Poumon*, **2**, 205
Rosendal, T (1942) *Acta radiol* **23**, 138
Rowland, R S (1928) *Arch int Med* **42**, 611
—— (1929) *Ann int Med* **2**, 1277
Rubin, E (1947) *Diseases of the Chest*, Phila
Samuelsen, E (1942) *Acta radiol* **23**, 373
Santos, R dos, and Wohlwill, F (1942) quoted by Berg, G, and Nordenskjöld, A. (1946).
Siwe, S A (1933) *Frankfurt Z Path* **55**, 212
Thannhauser, S J (1940) *Lipidoses*, New York
Thompson, C Q, Keegan, J J, and Dunn, A. D (1925) *Arch int Med* **36**, 650
Tooth, H H (1897) *Trans path Soc Lond* **48**, 30
Turner, A L, Davidson, J, and White, A C (1925) *Edinb med J* **32**, 153

pulmonary interstitial fibrosis, but there is no evidence as to the cause of these changes In no case was there a history of exposure to chemical poisons, silica particles, or other noxious irritants, nor was there any reason to suspect neoplastic infiltration of the lung It is possible that some cases were examples of a healed general disorder such as is described in the first part of the present paper, the history of polyuria in one patient suggesting that he might have suffered from xanthomatosis

An inflammatory origin remains to be considered There seems little doubt that acute infections, either after influenza, measles, or whooping-cough, or even in the absence of an obvious precursor, may effect predominantly the smaller radicles of the bronchial tree (Lange, 1901, Fraenkel, 1902, Blumgart and MacMahon, 1929), the so-called bronchiolitis fibrosa obliterans, which may occur at any age Also, gross acute emphysema may develop rapidly as a result of infection, at least in infancy (Tooth, 1897) Detailed pathological studies on the present material have not yet been made, but will appear in a later paper It is evident, however, that varying degrees of inflammation are the main feature, strongly suggesting an inflammatory origin in the majority Should such infection lead to obstruction or distortion of the smaller bronchi or bronchioles, the cysts may result from impeded expiration

Conclusions

The object in presenting these cases is to emphasize that honeycomb lungs occur in a variety of diseases in which there is diffuse interstitial pulmonary infiltration This infiltration may be produced by proliferation of smooth muscle in the patients with tuberous sclerosis and allied disorders, by lipoid cell granulomata in the xanthomatoses, and by inflammatory cells, as in the two cases associated with biliary cirrhosis There are other cases in which the nature of the underlying pulmonary lesion is less evident Occasionally a developmental cause seems most likely, but more often interstitial inflammation appears to be the predominant factor.

Summary

1. Sixteen cases of honeycomb lungs are described. In six the lesions were associated with a general medical disorder, namely, xanthomatosis, biliary cirrhosis, tuberous sclerosis, or pituitary disease, these are compared with similar cases from the literature In the remaining 10 cases the honeycomb structure occurred as an isolated manifestation of uncertain aetiology, an inflammatory cause being the most likely in the majority

2 The frequent occurrence of spontaneous pneumothorax and right heart failure is emphasized

Our thanks are due particularly to Professor Geoffrey Hadfield for his assistance and criticism and also to Professors R V Christie and Dorothy Russell, Drs Morley Fletcher, Geoffrey Marshall, A L Punch, J L Livingstone,

Fig 1 Case 4 Fine reticulation in tuberous sclerosis

Fig 2 Case 6 Coarse reticulatio
diabetes insipidu

Fig 3 Case 10 The appearance during spontaneous pneumothorax

Fig 4 Case 10 The honeycomb
obvious after re-exp

Vejlens, G (1941) *Acta path et microbiol scand* 18, 317
von Stössel, E (1937) *Beitr Klin Tuberk* 90, 432
Wallgren, A (1940) *Amer J Dis Child* 60, 471
Weiss, F H (1936) *Fortschr Röntgenstr* 54, 230
Williams, E (1944) Ministry of Fuel and Power (1944) *Report of Advisory Committee on Pneumoconiosis*, p 18
Willis, F E S , and Almeyda, J (1943) *Tubercle*, 24, 27
Wilson, S A K. (1940) *Neurology*, Lond

Case 15 Section of whole lung showing uniform tion of cysts and sub pleural bullae (See Fig 7)

FIG 10 Case 14 Section of lung (×1 5), showing multiple thin walled cysts

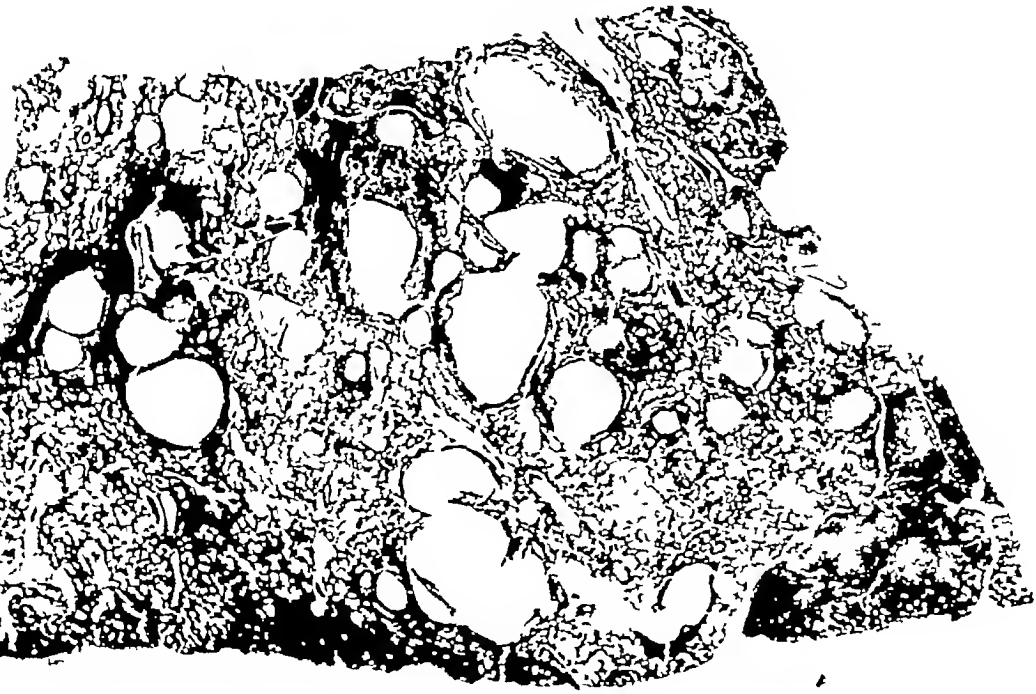

FIG 11 Case 1 Section of lung (×5), showing honeycomb appearance in xanthomatosis

Case 11 Tomogram during spontaneous pneumothorax

Fig 6 Case 12 Honeycomb appearance during spontaneous pneumothorax

Case 15 Honeycomb lungs with right heart The film was taken a year before death (see Fig 9)

Fig 8 Case 5 No evidence of bronchial dilatation There is a suggestion that some of the smaller bronchi are displaced by the cysts peripherally

616.24–002 5–072 1

BRONCHOSCOPIC STUDIES IN PRIMARY TUBERCULOSIS IN CHILDHOOD[1]

By JAMES H HUTCHISON

(From the Department of Child Health, University of Glasgow, and the Royal Hospital for Sick Children, Glasgow)

With Plates 5 and 6

In 1920 Ehasberg and Neuland described extensive radiographic shadows in the lungs of children passing through the primary tuberculous infection, without the grave symptoms usually associated with tuberculous pneumonia As the children recovered the shadows disappeared without leaving evidence of permanent lung disease To this condition they gave the name epituberculosis (Ehasberg and Neuland, 1920, 1921) There has been widespread disagreement as to its pathogenesis As complete disappearance of the lesion is one of the cardinal features of epituberculosis, material is not often available for pathological study, and in fact the view might be held that many of those cases in which histological examination has been reported were not undoubted cases of epituberculosis, because at the patient's death the lung lesion was still present

The literature suggests that epituberculosis may be due to three possible causes—a non-tuberculous pneumonia, a true tuberculous process, or absorption collapse produced by bronchial obstruction due to enlarged tuberculous hilar lymphnodes

Non-tuberculous pneumonia This was the view advanced by Ehasberg and Neuland in their original description of epituberculous infiltrations It has been suggested that interference with lymph flow due to tuberculosis in the regional lymphnodes may favour delay in resolution of a simple non-specific pneumonia occurring in a tuberculous subject This view is not now regarded as tenable There is little histological evidence in its favour (Rich, 1944)

A true tuberculous process The view that epituberculosis may be a true tuberculous process affecting the lung parenchyma is plausible and on the face of it would seem likely to be correct In fact, several different types of tuberculous tissue reaction have been described Pagel in Kayne, Pagel, and O'Shaughnessy (1939) stated that it may take the form of 'a "perifocal" infiltration, when a small bacillary focus is surrounded by a large area of toxic oedema or gelatinous infiltration, attributable to a hypersensitive response of the tissue towards soluble toxins or a few living or dead bacilli diffusing from the focal centre into the peripheral lung tissue This is often the anatomical basis of a large shadow of infiltration in a skiagram, but it cannot be determined how

[1] Received August 21, 1948



FIG 12 Leiomyomatous infiltration of the lung (×60) showing invasion of alveolar walls (photomicrograph by permission of Dr J M Ross)

in the words of Macgregor and Alexander (1937), who in their extensive experience had encountered occasional cases of 'undoubted tuberculosis in which there was extensive consolidation in one or both lungs without caseation, cavitation, or fibrosis, but in which the microscopic characters of the affected parts differed from those described as characteristic of "gelatinous infiltration"' 'Microscopic examination showed alveoli completely filled with large mononuclear cells, without fibrin formation or any appreciable amount of serous fluid The cells were either desquamated alveolar epithelium, or more probably histiocytes or both It was sometimes impossible to demonstrate either tubercle bacilli or other organisms in sections prepared from lungs affected in this way, if present, tubercle bacilli were never numerous The process is possibly the result of a "tuberculo-toxic" or allergic reaction There is nothing in its histological character to render resolution impossible or even improbable It does not seem to possess the tendency to rapid caseation manifested by sero-fibrinous exudates of the more usual forms of pneumonic tuberculosis That it may have some tendency to organization is indicated by the occasional finding of intra-alveolar tubercles, sometimes with giant cells, which may have progressed to the stage of fibroblastic proliferation' These workers concluded that 'it seems possible, therefore, that at least in some cases this peculiar type of non-caseating and non-fibrosing tuberculous reaction may be the histological basis of "epituberculous infiltrations"' The histological appearances from the patient described by Cameron and De Navasquez (1936) were identical with those described above, and the writers suggested that the enlarged caseous tracheobronchial lymphnode which had ulcerated into the stem bronchus of the left upper lobe had discharged into its lumen tubercle bacilli of varying virulence and vitality which produced a peculiar pneumonia with a predominantly endothelioid reaction Lesions which are histologically similar to those described above and are capable of complete resolution have been produced in sensitized rabbits by the intratracheal injection of dead, avirulent, or even small doses of virulent tubercle bacilli (Philibert and Cordey, 1925, Willis, 1934, Burke, 1935, Oppenheimer, 1935) By the use of a strain of tubercle bacillus of low pathogenicity to the guinea-pig, Baldwin and Gardner (1921) were able to produce allergic lesions in the guinea-pig's lung manifested by a localized inflammation accompanied by atypical and abortive tubercle formation It is clear from these animal experiments that a non-caseating tuberculous pneumonia can produce transient radiographic shadows in animals' lungs and that this tuberculous pneumonia is capable of complete resolution Whether a similar histological appearance and course is likely to be of common occurrence in naturally occurring human tuberculosis is uncertain

A third type of tuberculous tissue reaction without caseation has been described by Pagel (Kayne, Pagel, and O'Shaughnessy, 1939) in which the typical feature is the presence of innumerable tuberculoid granulomata with Langhan's giant cells but without tubercle bacilli and caseation Pagel (1932) described these appearances in a boy aged one and a half years with epituberculous infiltration in the left upper lobe who had died from causes other than

often the bacillary centre heals and how often the infiltration area becomes involved in the progressive central focus' This concept is supported by cases such as that reported by Langer (1922) in which, after the administration of 0 1 mg of tuberculin, an 'infiltration' demonstrable by radiography as a dense shadow appeared over a whole lobe, accompanied by a systemic reaction, the shadow disappeared after 14 days Gerstenberger and Burhans (1927) described the condition as a 'massive allergic exudate', and suggested that these exudates are part of a 'general immunologic attack of the body against the tubercle bacillus rather than the result of local irritation of the tissue by the tubercle bacillus' Stoloff (1928), describing a child with atelectasis of the whole left lung due to bronchial compression by enlarged tuberculous lymphnodes, none the less regarded less extensive lung parenchyma shadows as indicative of 'perifocal inflammation' due to 'serous lymphocytic exudation' The same view has been expressed by Friedenberg (1926) A similar pathogenesis of epituberculosis has recently been postulated by Dufourt and Mounier-Kuhn (1946 *a*, *b*) based on bronchoscopic examinations They suggested the following sequence of events after primary infection Firstly, there develops an 'epithelial pneumonia' in the lobe containing the primary focus At the same time, the bronchial wall develops intense oedema affecting the mucosa and submucosa and accompanied by diapedesis of macrophages into the sub-epithelial layer The result is incomplete bronchial obstruction combined with the outpouring of fluid into the lung parenchyma This oedema is interpreted as a manifestation of local hypersensitivity provoked by tuberculin secreted by the primary focus Dufourt and Mounier-Kuhn (1946 *a*, *b*) admit that trachee-bronchial lymph-node enlargement capable of compressing the bronchi does occur in primary tuberculosis, but they appear to regard this as of little or no importance in most cases of epituberculosis, and, in fact, they stress that the finding of bronchial stenosis in epituberculosis does not justify the assumption of cause and effect Rich (1944) comments as follows on the suggestion that epituberculosis is a perifocal pneumonia 'This view has no basis in observation to recommend it, and all available information speaks against it' He musters some convincing evidence against it

A second view is that all cases are not purely allergic or 'tuberculo-toxic', as is suggested by cases such as those reported by Spence (1932) and Parsons (1934) in which tubercle bacilli were found in material obtained by lung puncture Either these workers accidentally needled the primary lung focus itself on more than one occasion, or their patients were suffering from a true tuberculous infiltration of lung parenchyma which ultimately resolved completely A somewhat similar case was described by Görter and Lignac (1931) in which partial resolution took place before the child died of tuberculous meningitis Histological evidence that the radiographic appearances of human epituberculosis may on occasion be caused by parenchymatous tuberculosis unassociated with caseation has been put forward by several workers (Rubinstein, 1928, Reichle, 1933, Cameron and De Navasquez, 1936, Macgregor and Alexander, 1937) The histological picture described by these workers can be portrayed

was plugging of a bronchial tube with caseous debris from the before-mentioned tubercular abscess' Peterson (1885) described a similar case in a girl aged six years who recovered with endotracheal intubation and suction Scobie (1934) in a review of the literature reported a total of 94 cases of acute asphyxia with 20 recoveries, and added one of his own, which was apparently the first case of this type to be reported in American literature

The view that the radiographic shadow in epituberculosis may be due to pulmonary collapse consequent upon bronchial occlusion due to the compressive effects of enlarged tuberculous hilar lymphnodes was put forward by Wallgren (1926) and de Bruin (1936) Prosoroff (1929) noted a striking resemblance between the shadows in epituberculosis and those due to atelectasis in adults suffering from intrathoracic tumours In 1933 Morlock and Pinchin, in a case which had been regarded as epituberculosis, described bronchial occlusion which had been directly observed bronchoscopically In their case, one of left upper lobe collapse, tuberculous granulation tissue covered with intact mucous membrane was found bulging into the bronchial lumen After removal of this granulation tissue the radiographic shadow disappeared completely but temporarily Brock, Cann, and Dickinson (1937) described an infant with complete left lung collapse in whom it was shown at autopsy that an inferior tracheobronchial lymphnode had ulcerated into and completely obstructed the left main bronchus, and also a six-year-old child with collapse of the right lower lobe in whom bronchoscopy revealed granulation tissue within the lumen of the right main bronchus, from which tubercle bacilli were isolated Macpherson (1939) accepted the view that the radiographic appearances of epituberculosis were really indicative of absorption collapse, suggesting that bronchial occlusion results from one or more of three possible effects of tuberculous hilar lymphnodes—they may reduce the bronchial lumen by traction which alters the angle of the carina, they may exert direct pressure on the bronchial wall, or they may erode through the bronchial wall to fill the lumen with granulation tissue In 1942 two American papers provided strong evidence in support of this interpretation Kent (1942) described 10 cases, in seven of which bronchiectasis developed consequent upon atelectasis, in two cases bronchoscopy revealed that bronchial obstruction was due to the extrinsic pressure of enlarged lymphnodes, and in one, tubercle bacilli were isolated from the bronchus distal to the site of obstruction Jones, Rafferty, and Willis (1942) bronchoscoped 42 patients suffering from epituberculosis, and in 31 bronchial occlusion was clearly seen This was due to one or more of the following causes—bronchial narrowing from extrinsic pressure, mucosal oedema, erosion of a lymphnode through the bronchial wall with a resultant 'tuberculoma' within the lumen, and tuberculous ulceration of the bronchial mucosa, the base of the ulcer being an eroding tuberculous lymphnode In 1946 Jones, Peck, and Willis examined 34 of these 42 cases by lipiodol bronchography and demonstrated the existence of undoubted bronchiectasis in 24 (70 per cent) The most frequent bronchopulmonary segments to show bronchiectasis were the antero-lateral (pectoral-axillary) in the upper lobes and the dorsal (apical) in the lower lobes In

tuberculosis Part of the left upper lobe was atelectatic, and in this area were many little granulomata lying inside thickened alveolar septa These appeared to arise from epithelioid cells with better staining nuclei than is usual in tuberculosis, and they also contained many typical Langhan's giant-cells These tuberculoid granulomata were confined to the collapsed area, and Pagel regarded them as a specific constituent of the lesion and not as ordinary miliary tubercles In Kayne, Pagel, and O'Shaughnessy's book he stated 'They should be attributed to an allergic reaction of the tissue surrounding the primary focus to aspirated dead bacilli or perhaps diffusing focal toxins which easily enter the tissue after eruption or extension of the focus into a bronchus The granulomata thus appear as the sign of a successful fixation or destruction of the antigen and are comparable with those developing at the site of a positive intradermal tuberculin reaction' While he admitted that atelectasis due to tuberculous hilar glandular enlargement does occur, Pagel did not agree with those who regard transient radiographic shadows in primary tuberculosis as mostly or always due to atelectasis, and in fact he maintained that both atelectasis and an allergic tuberculous tissue reaction may be present in the same patient

Absorption collapse In the medical literature of the nineteenth century it was already recognized that tuberculous hilar lymphnodes could produce pulmonary collapse and rupture of the bronchial wall. The ulceration of tuberculous lymphnodes into the bronchial tree was mentioned by Laënnec (1821) In 1850 Gairdner described an autopsy in a case of tuberculous meningitis in which part of the left lower lobe was collapsed because 'enlarged glands at the root of the left lung pressed upon some bronchi going to the left lower lobe' He also quotes Carswell who 'figured the case of a monkey in which the left bronchus was much compressed or rather obliterated by a mass of enlarged tuberculous glands', the corresponding lung having diminished to less than a third of its normal bulk Gee (1877) in an article entitled 'The Chronic Pneumonia which attends Disease of the Tracheal and Bronchial Glands' described four cases, in three of which a tuberculous lymphnode had perforated an adjoining bronchus (and also the oesophagus in one of the cases), and in the fourth case the trachea and right bronchus were compressed In two cases the lung distal to the bronchial perforation showed tuberculous pneumonia, in the third case the affected lung was airless and the seat of a non-tuberculous pneumonia, the lung in the fourth case was collapsed and in a state of 'iron-grey induration' with 'much dilated' bronchi in the lower lobe The literature of the last century contains frequent reports of cases in which the sudden rupture of a tuberculous lymphnode into the trachea or a large bronchus had produced a fatal asphyxia (Fuller, 1861, Westcott, 1881, Widerhofer and Frühwald, 1885, Loeb, 1886, who quoted Weil (1874) as having found 50 such cases in the literature, Parker, 1890) An annotation in the *Lancet (1885)* described a coroner's inquest on the death from asphyxia of a girl aged 12 years Autopsy revealed that a caseous mediastinal lymphnode had emptied its fluid contents into the trachea A further observation was 'a wedge-shaped patch of consolidation' at the base of one lung in connexion with which 'it was discovered that the initial lesion

children attending a large asthma clinic Spivek (1936) described four typical cases Three were examined by bronchoscopy and the bronchial narrowing shown in two to be caused by extrinsic lymphnode pressure on the bronchial wall, and in one by granulation tissue within the lumen One patient had a sudden dyspnoeic attack presumed to be due to rupture of caseous material into a major bronchus Faust (1936) followed to recovery a case of obstructive emphysema affecting the whole left lung Bronchoscopy showed marked kinking of the left main bronchus by a greatly widened carina major and on the floor of the right main bronchus was found granulation tissue from which tubercle bacilli were isolated Barsby (1941) described three cases in which bronchoscopy was performed In two, narrowing of the bronchial lumen was effected by extrinsic pressure, and in the third by a mass of granulation tissue proved by biopsy to be tuberculous She pointed out the important fact that the earliest stage of obstructive emphysema will be missed unless the radiograph is taken in full expiration or the patient is screened Meneghello and Smith (1943), in a series of 15 patients with bronchial narrowing due to tuberculosis, described obstructive emphysema in seven Pray (1944) described a case of obstructive emphysema in a four-months-old infant, proved at autopsy to be caused by tuberculosis of the hilar lymphnodes

In August 1947 Görgényi-Göttche and Kassay published the results of their investigations into cases of 'epituberculous infiltration' in Budapest between 1940 and 1944 They decided that it was impossible from clinical and radiographic investigations alone to differentiate between 'infiltration' and atelectasis, and made use of the tomograph and bronchoscope for this purpose In 22 of 29 cases they were able 'exactly to prove the narrowing or obstruction of the bronchi' by tomography Furthermore, they noted that 'in cases of atelectasis the tomograms did not show narrowing of the bronchi so much as obstruction of them' To determine the cause of the obstruction they submitted 28 of their patients to bronchoscopy, with positive findings in 21 Of these 21 cases, atelectasis was shown on the radiographs in 12, obstructive emphysema in four, and in the remaining five bronchial stenosis was correctly deduced to be present from the sole finding on screening of a positive Holzknecht-Jakobson phenomenon (that is, during deep inspiration the heart and other mediastinal organs move toward the affected side) In 18 cases bronchoscopy revealed rupture of a lymphnode into a main bronchus, and in three a bronchus was narrowed by an encroaching lymphnode which had not yet penetrated the wall In 14 cases granulation tissue or necrotic caseous material was removed through the bronchoscope The authors produced photographs of amazingly large caseous masses removed from four of their patients, masses of such size as to suggest that these Budapest children reacted to a primary infection with much greater intensity than is usual in this country The ultimate fate of the children is not stated Of 12 described in detail, two died, but a somewhat optimistic outlook is indicated in some of the cases Thus, of one patient from whose left bronchus large caseous masses were removed it is said that he 'left the hospital in perfect health after a two week stay'

contrast to the classical infected bronchiectasis, the lingula was rarely involved None of these observers mentioned bronchial stenosis as a sequel to bronchial involvement in hilar tuberculosis, but that this can occur was shown by a case described by Lightwood and Wilson (1936) In their patient, a boy who three years previously had been diagnosed as suffering from pneumonia and in whom the tuberculin skin tests were positive, bronchial stenosis was demonstrated both by lipiodol bronchography and bronchoscopy The lung was removed and found to be shrunken and fibrous (absorption collapse) and to contain numerous areas of calcification

In 1936 Rössle added pathological evidence in support of the contention that epituberculosis is the consequence of bronchial occlusion He divided epituberculosis into two forms according to the mechanism which had occasioned bronchial occlusion—the 'pure' form where there is compression of a bronchus by the enlarged hilar lymphnodes of the primary tuberculous complex, and the 'obscure' form in which atelectasis is caused by obstruction of a bronchus by caseating lymphnodes which have produced a breach or rupture in the bronchial wall with the entry of cheesy material into the lumen To the 'pure' form he gave a good prognosis, but in the 'obscure' form he stressed the danger of subsequent 'confluent caseous pneumonia' Guillermo and Alberto (1945) published the autopsy findings in 17 patients who had exhibited the characteristic clinical and radiological features of epituberculosis. In half of the cases mucous plugs were found within the bronchial lumen, in one case occlusion was due to rupture of a caseous lymphnode into the lumen, and in every case there were adhesions between caseous lymphnodes and adjacent bronchi in the zone of atelectasis

If epituberculosis is in fact absorption collapse due to complete bronchial occlusion, then obstructive emphysema due to incomplete bronchial occlusion might also be expected to occur not infrequently The lung behind the stenosis is ballooned, the intercostal spaces are widened, the diaphragm is pushed downwards, and the mediastinum may be displaced to the sound side, especially during expiration Such a state of affairs in association with tuberculous hilar adenitis does in fact occur, and it was first described in this condition by Bird in 1842 He described the case of a girl aged 16 years in whom he diagnosed emphysema affecting the left lung, which was confirmed by autopsy The left bronchus was compressed between two tuberculous lymphnodes and he noted that 'the closure of the tube was not so complete as to prevent all air entering, for after death a chinklike opening existed' Bird's view as to the pathogenesis of the emphysema was wrong, but a correspondent (A G R) to the *Lancet*, commenting on Bird's case, suggested a mechanism so similar to that described by Jackson (1930) 88 years later that it is quoted here 'Two cells, the one communicating with a healthy, the other with a contracted or otherwise impeded bronchus, becoming distended by a forcible inspiration, the next expiratory effort expels the air from the former, while it compresses the air in the latter, over-distending and rupturing its parietes' Peshkin and Fineman (1926) discovered two cases of tuberculous obstructive emphysema among

gényi-Göttche and Kassay, 1947) and indeed in the absence of any form of anaesthesia, but in the writer's opinion this constitutes an unnecessary psychological if not physical assault upon the child Chloroform, although ideal from the point of view of the bronchoscopist, was considered to be too dangerous for use in a routine diagnostic procedure Ether carries a slight risk of explosion and is irritating to the eyes The author's present anaesthetic routine for

TABLE I

Type	*I*	*II*		*III*	
		a	*b*	*a*	*b*
Number of cases . .	9	3	2	7	5

TABLE II

Incidence of Lobes affected in the Author's 30 Cases

Right upper lobe, 5 cases
Right middle lobe, 5 cases
Right lower lobe, 4 cases
Right upper and right middle lobes, 1 case
Right middle and right lower lobes, 2 cases
Whole right lung, 2 cases
Left upper lobe, 6 cases
Left lower lobe, 2 cases
Left upper and left lower lobes, 2 cases
Whole left lung, 1 case

bronchoscopy in all types of case is light anaesthesia with a nitrous oxide–trilene mixture, relaxation being obtained with intravenous *d*-tubocurarine hydrochloride The dose of the latter required has been found to be approximately 2 5 to 3 0 mg per stone of body-weight This combination appears to be perfectly safe in the hands of an experienced anaesthetist, and is ideal for the bronchoscopist The danger of post-operative sub-glottic oedema is minimal when the larynx is completely relaxed before the bronchoscope is passed Premedication consists of omnopon and atropine given half an hour before bronchoscopy

Bronchoscopic findings The bronchoscopic findings in 26 of the 28 patients with active primary tuberculosis have been subdivided into several types (Table I), in two patients (Cases 24 and 25) no bronchoscopic abnormality was found The two cases of healed primary tuberculosis will be described separately

Type I (9 cases) The bronchial lumen is narrowed, frequently into a mere slit, by a local bulging of part of the wall The mucous membrane overlying the bulge is hyperaemic and swollen, and when the bronchoscope is first introduced it is often obscured by thick muco-pus which must be removed by suction On occasions the bulge into the main bronchus so involves a carina minor of the upper or middle-lobe bronchus that the entrance to one or other of these bronchi is completely occluded or so narrowed that the final obstruction is produced by thick muco-pus (Plate 5, Fig 1) This appearance is due to extrinsic

In September 1947 the author, in conjunction with Graham (Graham and Hutchison, 1947), published evidence from an analysis of 45 cases in favour of the view that epitubercolosis is in fact absorption collapse The clinical and radiological features were discussed The value in diagnosis of the 'asthmatoid wheeze' (Jackson, 1918) or of a history of pertussis-like cough was stressed, as was the paucity of other physical signs in many patients The frequent absence of some of the classical clinical and radiographic signs of pulmonary collapse—crowding of the ribs, elevation of the diaphragm, mediastinal or tracheal shift—was noted, but it was pointed out that with a knowledge of the anatomy of the bronchial tree (Foster-Carter and Hoyle, 1945, Brock, 1946) interpretation was not usually difficult with the help of antero-posterior, lateral, and oblique views (Erwin, 1939) Obstructive emphysema was seen in two patients Bronchiectasis was demonstrated in four patients, being in every case outstandingly free from secondary infection, in one of these cases bronchial stenosis was also present In another five cases lipiodol bronchography revealed complete bronchial obstruction, in one of which there was also stenosis of a main bronchus In four cases bronchial occlusion was demonstrated by bronchoscopy It appeared from this analysis that although in primary tuberculous infection the occurrence of bronchial obstruction does not seem materially to worsen the early prognosis as regards life, it can, none the less, leave permanent sequelae of some severity, such as bronchial stenosis and bronchiectasis, a fact not always appreciated when these cases were regarded as 'epitubercolous infiltrations' It was decided, therefore, to study the actual changes in the bronchial tree in further cases by bronchoscopy

The Present Investigation

Thirty children were examined on one or more occasions by bronchoscopy Of these 30 patients, 18 gave evidence of active primary tuberculosis associated with sharply outlined radiographic shadows in the lung fields, lobar or segmental in extent, but without mediastinal or tracheal displacement The clinical and radiological findings were such as to justify a diagnosis of 'epitubercolosis', although lipiodol bronchography in four patients showed bronchial obstruction In another 10 patients with active primary tuberculosis the clinical and radiological findings were similar to those already mentioned and in addition there was present mediastinal or tracheal shift, obstructive emphysema was also seen in two of this group The remaining two patients were suffering from uninfected bronchiectasis which had complicated a healed primary tuberculous infection The 30 cases are summarized individually in the Appendix, and the incidence of lobes affected is shown in Table II

Technique of bronchoscopy Negus-type bronchoscopes of various sizes were used Specimens from the bronchial tree were obtained by means of a sucker or alligator forceps Anaesthesia was the only problem requiring special consideration Pentothal and curare were tried, but young children tolerate the former badly Bronchoscopy is practicable with large doses of chloral hydrate (Gör-

seven and a half years, the radiograph showed a calcified primary complex in the right lung, and the bronchi in the right middle lobe were seen to be markedly dilated on the film Clinically the girl was in fair health, but an 'asthmatoid' wheeze was audible at the open mouth and she was subject to frequent attacks of 'bronchitis' Bronchoscopy revealed much sticky mucus in the right main bronchus This was aspirated with difficulty, when the entrance to the right middle-lobe bronchus was seen to be greatly narrowed and puckered A lipiodol bronchogram showed complete occlusion of the middle-lobe stem bronchus 1 cm from its origin

The second patient (Case 30), a girl aged nearly 10 years, was first seen at the age of nine months when a diagnosis of epituberculosis affecting the right lower lobe was made Caseous material containing tubercle bacilli was aspirated from the right lung on two occasions Serial radiographs in the intervening years showed this tuberculous lesion to heal with the development of calcification within the affected lobe and in the sentinel tracheo-bronchial lymphnodes Finally, at the age of nearly 10 years all traces of calcification (which had been extensive) had disappeared, but right lower-lobe collapse with marked shrinkage persisted At this time she had an infrequent loose cough with very little sputum, and experienced undue breathlessness on exertion The fingers showed slight clubbing The Mantoux test was positive She was 85 per cent of the expected weight for her age Abnormal physical signs present were diminished movement of the right lower chest and slightly impaired percussion note at the right base, where the breath-sounds were bronchial in type A lipiodol bronchogram showed cylindrical bronchiectasis in the right lower lobe Bronchoscopy showed patent bronchi on the right side, but the normal anatomical arrangements of the right bronchial tree were distorted, there being irregularity and distortion of the carinae, and the anterior, axillary, and posterior basal bronchi came off at unnatural relationships to each other The right lower lobe was successfully removed Histologically the bronchial walls and mucous membrane were intact, but almost all alveoli had disappeared and were replaced by fibrous tissue There was no sign of tuberculosis Furthermore, it was noted at operation that the right tracheo-bronchial lymphnodes had virtually disappeared These findings are of interest in that they afford proof that intrathoracic caseation may occur, probably extensively, and undergo complete resorption in the human subject Proof that this may occur in animals has been provided by Willis (1934), Oppenheimer (1935), and others The complete disappearance of calcification from a tuberculous lesion has already been described by Brailey (1937)

These two healed cases have been described to indicate that 'epituberculosis' may, on occasion, leave permanent damage of some severity, although it is not known how frequently.

Illustrative Cases

Case 1 (Type I), a girl aged three years and two months, had been a full-time healthy baby, bottle-fed, and apart from a febrile illness with a convulsion at the age of two years had thrived well History of contact with tuberculous

pressure on the bronchial wall by tuberculous broncho-pulmonary lymphnodes and closely resembles the appearances found in carcinoma of the lung with hilar gland involvement

Type II (a) (3 cases) Under the mucous membrane covering such a bulge as already described are found glistening, yellow, slightly raised areas which indicate that a caseous lymphnode is on the verge of 'pointing' into the bronchial lumen On one occasion such a 'papule' was accidentally ruptured, when semi-fluid caseous material rich in tubercle bacilli flooded into the bronchial lumen, this occurrence did not seem to upset the child in any way (Case 2) Presumably such an event must happen not infrequently in natural circumstances, though if sufficient of the caseous material ruptures into or reaches the trachea rapid death from asphyxia may ensue

Type II (b) (2 cases) The bulge described in Type I becomes more circumscribed and pinkish-yellow in colour, forming a 'tuberculoma', which projects abruptly into the bronchial lumen, the covering mucous membrane being intact (Plate 5, Figs 2 and 3) Such a tuberculoma has been removed with forceps (Case 3) and found histologically to consist of tuberculous tissue (Plate 6, Fig 6)

Type III (a) (7 cases) In this type there is found an area of ulceration of the bronchial mucous membrane covered by a thin layer of granulation tissue, sometimes dirty yellow in colour, sometimes raspberry-red and bleeding readily (Plate 5, Fig 4) It is not possible from the appearances to determine whether this is the sequel to rupture of the caseous lymphnode which has emptied its contents into the bronchial lumen or whether it is caused by a lymphnode slowly eroding its way through the bronchial wall Considerable difficulty is experienced in obtaining a satisfactory piece of this thin layer of granulation tissue for biopsy, and care must be taken not to punch through the bronchial wall

Type III (b) (5 cases) A main bronchus or a primary division to a lobe is filled with pinkish or greyish-yellow friable granulation tissue, which can often be dislodged readily with the sucker without much bleeding Such granulation tissue has been examined histologically on two occasions (Cases 5 and 26) and found to be typical tuberculous tissue with follicles, giant-cells, &c This state of affairs is presumably only a more advanced stage of Type II (b) when the mucous membrane has broken down, and in fact the change from Type II (b) to Type III (b) was observed in one of the cases of obstructive emphysema when absorption collapse supervened (Case 28) In another case (Case 6) repeated bronchoscopies showed the appearances change from Type I to both Types II (b) and III (b), and on the final bronchoscopic examination actual calcification was demonstrated histologically in the caseous material removed The carina major was appreciably widened in 15 of the 26 cases described above, indicating involvement of the inferior tracheo-bronchial lymphnodes in the tuberculous process In another of these cases (Case 3, Plate 5, Fig 2) the carina was distorted, the lower end being pulled to the right

Appearances in healed cases In the first case (Case 29), that of a girl aged

making a good recovery His mother suffered from tuberculosis of a knee-joint He was admitted to hospital on December 6, 1947, with a six months' history of loss of weight, listlessness, and persistent unproductive cough For six weeks prior to admission he had been noticed to wheeze audibly He was 89 per cent of the expected weight for his age, and looked well The right side of the chest was bulging and moved poorly, and had a hyper-resonant percussion note Breath-sounds and vocal resonance were markedly defective on this side The apex-beat was in the left nipple-line A radiograph on December 8 showed segmental collapse in the right lower lobe, and emphysema of the remainder of the lung, together with mediastinal shift to the left (Plate 6, Fig 5) Bronchoscopy on December 22 showed that the carina major was distorted and displaced to the right On the medial wall of the right main bronchus were two large, yellowish, submucosal 'tuberculomata' During inspiration air passed through a small slit between the tuberculomata and the lateral wall of the bronchus, but during expiration even this narrow channel disappeared as the bronchial wall closed Thus the 'check-valve' mechanism described by Jackson (1930) was clearly seen in action (Plate 5, Fig 2) The tuberculomata were removed with alligator forceps without much bleeding The pathologist's report on the tissue was 'The material consists entirely of tubercle follicles, some with giant-cells, and some caseous material' (Plate 6, Fig 6) Scanty tubercle bacilli were found in smears from this tissue After bronchoscopy the radiographs showed almost complete return of the appearances to normal, apart from persistent segmental collapse in the right lower lobe Two months after bronchoscopy the child was gaining weight and looked very well

Case 4 (*Type IIIa*), a boy aged eight years, had been a full-time healthy baby, breast-fed for nine months His recovery from measles and chickenpox had been uneventful History of contact with tuberculous patients was not obtained On December 27, 1946, he became febrile, dyspnoeic, and ill The fever decreased slowly while the patient was having penicillin and sulphonamide, and he seemed well apart from a cough In February he was noted to have evening pyrexia although he seemed otherwise well A radiograph showed collapse of the right middle lobe He was admitted to the Royal Hospital for Sick Children on April 27, 1947 The Mantoux reaction was positive and the erythrocyte sedimentation rate 28 mm in one hour (Westergren) Bronchoscopy on May 1, 1947, showed that the carina major was widened and the mucous membrane of the right bronchus appeared sodden On the anterior wall of the main bronchus below the origin of the middle-lobe bronchus the mucous membrane was replaced by a layer of red, unhealthy-looking granulations which had the appearances of clusters of tissue growing through the bronchial wall This tissue extended forwards into the right middle-lobe bronchus, which was completely occluded (Plate 5, Fig 4) A specimen of this tissue was submitted to the pathologist and showed 'respiratory epithelium, connective tissue, polymorph and mononuclear cells', tubercle follicles were not seen A lipiodol bronchogram on May 8, 1947, showed that all the bronchi of the right lung were well filled, save those of the right middle lobe into which lipiodol failed to run He was discharged to his home in the country under the supervision of Dr Anderson of the Glenlomond Sanatorium, Kinross, who reported on November 8, 1947, that he was doing well The evening pyrexia had ceased and the sedimentation rate approached normal values Radiographic appearances, however, remained unchanged Permission for further bronchoscopic investigation was refused

patients was not obtained She was admitted to hospital on October 21, 1946, with erythema nodosum, having had fever and a convulsion 10 days previously The Mantoux test was positive and the erythrocyte sedimentation rate (Westergren) 87 mm in one hour A radiograph taken on October 22 showed enlarged left hilar lymphnodes, but on November 1 the film showed partial collapse of the left upper lobe Bronchoscopy on November 25 showed that the carina major was normal Marked narrowing of the left main bronchus produced by a large lateral bulge, together with rotation of the bronchus in a clockwise direction, was seen so that the left upper-lobe bronchus arose anteriorly The origin of the left upper-lobe bronchus was much narrowed by swollen hyperaemic mucous membrane and was initially occluded by thick mucus which was removed by suction (Plate 5, Fig 1) The radiographic appearances after bronchoscopy remained unaltered On December 4 the child was transferred to a convalescent home in the country. On January 15, 1947, she was re-admitted having developed tuberculous meningitis A radiograph on January 16 showed re-expansion of the left upper lobe The primary focus was not clearly seen In spite of treatment with streptomycin the child died on February 8 At autopsy a large caseous lymphnode was found greatly narrowing the main bronchus, which was, in fact, rotated On the carina between the left upper lobe bronchus and the main bronchus was a small perforation through which could be expressed caseous material from the enlarged left tracheo-bronchial lymphnode The primary focus was in the left upper lobe and measured 4×3×2 cm

Case 2 (*Type IIa*), a girl aged two and a half years, had been a full-time healthy baby, bottle-fed, and had thrived well apart from chickenpox and whooping-cough A history of contact with tuberculous patients was not obtained She was admitted to hospital on August 7, 1947, with a 10-day history of fever, drowsiness, and irritability The Mantoux reaction was positive and the cerebrospinal fluid normal A radiograph showed enlarged hilar shadows She was discharged home to the care of her family doctor on August 13 She was re-admitted on October 2, 1947, because of loss of weight and a spasmodic cough On this occasion radiographs showed collapse of the right middle lobe and anterior basal segment of the lower lobe The erythrocyte sedimentation rate was 63 mm in one hour (Westergren) Bronchoscopy on October 9 showed that the carina major was widened The right bronchus was filled with mucus, which was aspirated The lumen was then seen to be narrowed by a large postero-medial bulge situated just below the upper lobe bronchus On the surface of the bulge were several glistening yellow submucosal 'papules', one of which was accidentally ruptured Thick caseous material exuded in large quantity into the bronchial lumen, and was removed with forceps and by suction The middle-lobe bronchus was then seen as a closed slit surrounded by swollen congested mucous membrane The bronchi of the lower lobe could not be seen, as the bronchoscope could not be pushed past the bulge The pathologist's report on the caseous material was 'Lymph gland with coagulative necrosis and caseation A few lymphocytes remain Acid-fast bacilli present in smears and section ' The child was sent to the country branch of the hospital and in four months gained over 2 5 kg in weight The radiographic appearances did not change immediately after bronchoscopy, but four months later showed collapse of the medial segment of the middle lobe only

Case 3 (*Type IIb*), a boy aged seven years and ten months, had been a full-time healthy baby, breast-fed for three months He had had pneumonia when aged one year, and bronchitis at two, three, and six years, on each occasion

before bronchial rupture had had time to take place Secondly, it is certain that bronchial rupture will be found more frequently if a special search for it is made Between 1932 and 1942 at the White Cross Hospital of Budapest, for example, routine autopsy technique revealed bronchial rupture in nine cases (11 3 per cent) among 79 children who died of tuberculosis (Görgényi-Göttche and Kassay, 1947) Since these workers became particularly interested in this subject, however, they reported the finding of bronchial rupture at autopsy in eight (47 1 per cent) of 17 cases of tuberculosis at the St James Hospital of Budapest, where the technique was designed to reveal bronchial rupture as far peripherally as a tertiary bronchus

Furthermore, clinicians are familiar with a type of progressive and fatal tuberculosis in children which produces large, sharply outlined, wedge-shaped radiographic shadows precisely like those of epituberculosis Their very shape indicates that they represent the involvement of a lobe or broncho-pulmonary segment Rich (1944) points out that when such cases come to autopsy 'there is found, practically invariably, an erosion of a large bronchus by an adjacent caseous lesion' He adds, 'since the appearance of the X-ray shadow of epituberculosis is identical with that of progressive pulmonary tuberculosis resulting from the discharge of a caseous lymph node into a large bronchus (from the roentgenogram alone no one could say whether the shadow represents progressive tuberculosis from bronchial aspiration, or whether it will resolve), there is good reason, on this basis alone, to suspect that the consolidation of epituberculosis results from the aspiration of material from a caseous lymph node that has discharged into a large bronchus ' In support of this concept he describes cases in which he encountered evidence of healed bronchial perforations in subjects who had died from diseases other than tuberculosis in later life In addition to this type of epituberculosis in which he postulates the presence of extensive pulmonary lesions produced by the aspiration of tuberculous material, Rich (1944) gave as his opinion that identical large wedge-shaped radiographic shadows can be caused by atelectasis resulting from the compression of a bronchus by an adjacent tuberculous lymphnode, or from the plugging of a bronchus by caseous material arising from a lymphnode that has eroded the bronchus In both these types of epituberculosis described by Rich (1944) an essential factor is the involvement of a bronchus with an adjacent tuberculous lymphnode

In the cases described in the present paper the radiographic appearances were identical with those discussed by Rich (1944) There were no clinical differences of diagnostic import between cases in which bronchoscopy revealed only extrinsic lymphnode pressure on the bronchial wall, and cases in which the bronchial wall had been perforated by a caseous lymphnode The bronchoscopic findings in those patients in whom the radiographs showed lung parenchyma shadows without mediastinal displacement did not differ materially from the findings in patients whose radiographs showed the classical appearances of absorption collapse Further, in four of the 18 patients without mediastinal displacement, lipiodol bronchograms revealed bronchial obstruction (Cases 4, 18, 19, and 20)

Case 5 (*Type IIIb*), a girl aged two years and nine months, had been a full-time healthy baby, bottled-fed History of contact with tuberculous patients was not obtained In September 1947 she developed cough, anorexia, and listlessness, and began to lose weight She was admitted to hospital on November 3 and appeared to be in good general health, and was the expected weight for her age Diminished movement of the right side of the chest, impaired percussion note at the right base, and diminished air-entry were noticed A radiograph showed the typical 'jib-sail' shadow of right lower- and middle lobe collapse, with shift of the trachea and heart to the affected side The Mantoux reaction was positive and the sedimentation rate 20 mm in one hour (Westergren) Bronchoscopy on November 17 showed that the carina major was normal The right bronchus was completely obstructed at the level of the middle-lobe orifice by friable granulation tissue which bled freely when touched An attempt was made to remove the obstruction by suction and with alligator forceps, but the lower part of the main bronchus could not be cleared The pathologist's report was. 'Tuberculous granulation tissue with tubercle follicles in the submucosa' Many tubercle bacilli were found in smears and section A radiograph after bronchoscopy showed partial aeration of the right lower and middle lobes in which were to be seen dilated bronchi

Discussion

The present investigation confirms the work of others in this country and abroad that in the course of primary tuberculous infection enlarged caseous broncho-pulmonary and tracheo-bronchial lymphnodes frequently interfere with the normal patency of the bronchi In the series of 28 cases with active primary tuberculosis associated with radiographic abnormalities in the lung fields, nine revealed evidence of local lymphnode pressure on the bronchial wall, in five cases a lymphnode had eroded into the tissues of the bronchial wall but had not perforated the mucous membrane, and in 12 cases the mucous membrane had been eroded Only two patients (Cases 24 and 25) failed to provide bronchoscopic evidence of bronchial obstruction These two exceptions are regarded as indicative of the diagnostic limitations of bronchoscopic examination, limitations which are already well recognized in the study of bronchogenic carcinoma In five cases of the series, tubercle bacilli were obtained through the bronchoscope (Cases 2, 3, 5, 20, and 26), and in five cases typical tuberculous tissue was demonstrated histologically (Cases 2, 3, 5, 6, and 26)

Pathologists have differed widely in the frequency with which they have found erosion of bronchi by tuberculous lymphnodes at autopsy Ghon (1912) found bronchial rupture in 30 cases (17 7 per cent) out of 184 autopsies On the other hand, Blacklock (1932) working in the same hospital as the writer found bronchial rupture in only four cases (2 3 per cent) out of 173 autopsies There are several possible explanations of this discrepancy Firstly, the great majority of Blacklock's cases were infants who had died during the first or second years of life, when tuberculosis most often runs a rapidly progressive course Clinical experience suggests that in infancy tuberculosis either proves fatal within the first six months after primary infection, or else it tends to heal It seems possible, therefore, that in Blacklock's series the young patients died

son, 1947) to be reconciled with the views of those who have described a non-caseating tuberculous pneumonia (Rubinstein, 1928, Reichle, 1933, Oppenheimer, 1935, Cameron and De Navasquez, 1936, Macgregor and Alexander, 1937) At the same time, it indicates that absorption collapse is the essential pathogenesis of epituberculosis

Cases 29 and 30 of the present series show that bronchiectasis and bronchial fibro-stenosis may result from epituberculosis These sequelae might be expected to be of not infrequent occurrence in a condition of pulmonary collapse caused by tuberculosis of the hilar lymphnodes and bronchial wall The patients described by Lightwood and Wilson (1936), Kent (1942), and Jones, Peck, and Willis (1946) suggest that this is the case

Finally, it is suggested from the findings reported here that it is possible in the majority of cases of epituberculosis to demonstrate that absorption collapse is present Absorption collapse need not be associated with much diminution in the volume of the affected part of the lung if the causal bronchial occlusion is produced slowly, and especially if there is, in addition, disease of the lung parenchyma Segmental collapse will be demonstrated only by the use of lateral and oblique views as well as antero-posterior (or postero-anterior), and accurate interpretation requires a knowledge of bronchial anatomy (Foster-Carter and Hoyle, 1945, Brock, 1946) The underlying bronchial occlusion and its nature can be demonstrated by tomography, lipiodol bronchography (although this carries subsequent disadvantages in the interpretation of future radiographs), and bronchoscopy, which is virtually free from risk and moreover enables the physician to exclude pulmonary collapse due to inhalation of a foreign body.

Summary

1 The nature of epituberculosis is discussed and the various hypotheses found in the literature are quoted

2 A bronchoscopic investigation of 30 children is described which indicates that in the majority of cases of epituberculosis an essential factor is bronchial obstruction with absorption collapse

3 Bronchial obstruction is due to pressure upon the wall by enlarged tuberculous lymphnodes, which may merely distort the lumen, invade the bronchial wall itself with the production of submucosal caseous prominences, or rupture into the lumen with the appearance of tuberculous granulations therein

4 Incomplete bronchial occlusion may cause the production of obstructive emphysema, which has been described in two of the patients

5 Two of the cases demonstrate that sequelae such as bronchiectasis and bronchial fibro-stenosis may result from epituberculosis

Thanks are due to Professor Stanley Graham (in whose wards the majority of the patients were treated) for his constant interest and encouragement This investigation would have been much more difficult without the active co-operation and anaesthetic perfection of Dr William Auld The coloured drawings of bronchoscopic appearances were executed by Mr Gabriel Donald

It seems reasonable to conclude, therefore, that absorption collapse affecting a segment, a lobe, or an entire lung, caused by compression or erosion of the bronchial wall by an adjacent tuberculous hilar lymphnode, is an essential factor in epituberculosis Westermark (1941) suggested that epituberculosis due to atelectasis could be distinguished from that due to a 'proliferative type' of pulmonary tuberculosis with a tendency to clear by the different radiographic appearances, the former type produces the classical signs of pulmonary collapse, whereas the latter does not This contention cannot be substantiated by the findings reported here Cases 3 and 28 demonstrate that when an eroding tuberculous lymphnode so distorts the bronchial lumen as to produce a 'check-valve' instead of a 'stop-valve' effect, the result will be obstructive emphysema instead of epituberculosis or absorption collapse

The present investigation does not reveal whether the area of atelectasis produced by extrinsic lymphnode compression of a bronchus differs histologically from the atelectasis caused by plugging of a bronchus with tuberculous granulation tissue which has eroded its wall It seems possible that in the former event the lung might show only atelectasis without other disease In the latter event, however, tubercle bacilli and caseous tissue can be removed through the bronchoscope, and presumably they must also, on occasions, be aspirated into the atelectatic zone which is in communication with the obstructed bronchus It is difficult to imagine that any extensive tuberculous pneumonia is present in such cases As already stated, they differ clinically in no way from the more simple cases of bronchial compression The studies of Rubinstein (1928), Cameron and De Navasquez (1936), Macgregor and Alexander (1937), and others indicate the probability that tuberculous pulmonary lesions of a non-caseating and non-fibrotic type can resolve more or less completely It is reasonable to suppose, then, that in the cases of absorption collapse associated with actual bronchial perforation histological changes such as those described by Macgregor and Alexander (1937) or by Pagel (1932) may be superimposed upon those of simple atelectasis This raises the question as to what conditions prevent the occurrence of progressive fatal bronchopneumonia when a caseous lymphnode discharges its contents or erodes into the lumen of a bronchus Two obvious factors are the resistance of the host and the number of tubercle bacilli actually aspirated into the alveoli Rich (1944) pointed out that caseous material is often very poor in tubercle bacilli and the material that escapes into the bronchus may contain relatively few bacilli It may be, also, that the bronchial occlusion itself renders aspiration of material into the distal alveoli less likely and less effective than when bronchial rupture occurs without causing occlusion of the bronchial lumen

The concept of epituberculosis as a state of absorption collapse with, in some instances, superimposed resolving parenchymal tuberculosis enables the views of those who have regarded epituberculosis as identical with pulmonary collapse (Morlock and Pinchin, 1933, Rössle, 1936, Brock, Cann, and Dickinson, 1937, Macpherson, 1939, Kent, 1942, Jones, Rafferty, and Willis, 1942, Guillermo and Alberto, 1945, Görgényi-Göttche and Kassay, 1947, Graham and Hutchi-

Prosoroff, A (1929) *Beitr Klin Tuberk* **72**, 566
Reichle, H. S (1933) *Amer J Dis Child* **45**, 307
Rich, A R (1944) *The Pathogenesis of Tuberculosis*, Balt
Rössle, R (1936) *Virchows Arch f path Anat* **296**, 1
Rubinstein, H (1928) *Beitr Klin Tuberk* **70**, 773
Scobie, R B (1934) *Amer J Dis Child* **48**, 373
Spence, J C (1932) *Arch Dis Childh* **7**, 1
Spivek, M. L (1936) *Amer J Dis Child* **51**, 69
Stoloff, E G (1928) *Ibid* **35**, 239
Wallgren, A (1926) *Acta radiol* **7**, 595
Weil, A (1874) *Deutsch Arch klin Med* **14**, 89, quoted by Loeb
Westcott, W (1881) *Brit Med J* **1**, 386
Westermark, N (1941) *Acta radiol* **22**, 501
Widerhofer, and Frühwald, F (1885) *Jahrb f Kinderh* **23**, 422
Willis, H. S (1934) *Amer J Roentgen* **31**, 721

REFERENCES

Baldwin, E R, and Gardner, L U (1921–2) *Amer Rev Tuberc* 5, 429
Barsby, B (1941) *Lancet*, 1, 627
Bird, G (1842–3) *Ibid* 182
Blacklock, J W S (1932) *Med Res Council Spec Rep Series*, No 172
Brailey, M (1937) *Johns Hopkins Hosp Bull* 61, 258
Brock, R C (1946) *The Anatomy of the Bronchial Tree*, Lond
—— Cann, R J, and Dickinson, J. R (1937) *Guy's Hosp Repts* 87, 295
Burke, H E (1935) *Amer Rev Tuberc* 32, 382
Cameron, H C, and De Navasquez, S (1936) *Guy's Hosp Repts* 86, 366
de Bruin, M (1936) *Arch Dis Childh* 11, 65
Dufourt, A, and Mounier-Kuhn, P (1946 *a*) *Paris Méd* 1, 43
—— —— (1946 *b*) *Rev de la tuberc* 10, 172
Ehrsberg, H, and Neuland, W (1920) *Jahrb f Kinderh* 93, 88
—— —— (1921) *Ibid* 94, 102
Erwin, G S (1939) *Brompton Hosp Repts* 8, 43
Faust, O A (1936) *Amer J Dis Child* 51, 118
Foster Carter, A F, and Hoyle, C (1945) *Dis of Chest*, 11, 511
Friedenberg, W (1926) *Z Kinderh* 40, 493
Fuller (1861) *Lancet*, 2, 348
Gairdner, W T (1850) *Monthly J Med Sci* 11, 122
Gee, S (1877) *St Bart Hosp Repts* 13, 63
Gerstenberger, H J, and Burhans, C W (1927) *Amer J Dis Child* 33, 54
Ghon, A (1912) *Der primäre Lungenherd bei der Tuberkulose der Kinder*, Vienna, quoted by Görgényi Göttche and Kassay
Görgényi Göttche, O, and Kassay, D (1947) *Amer J Dis Child* 74, 166
Görter, E, and Lignac, G O E (1931) *Acta Paediat* 10, 87
Graham, S, and Hutchison, J H (1947) *Arch Dis Childh* 22, 162
Guillermo, L B, and Alberto, G (1945) *Rev chilena de pediat* 16, 97
Jackson, C (1918) *Amer J Med Sci* 156, 625
—— (1930) *J Amer Med Ass* 95, 639
Jones, E M, Peck, W.M, and Willis, H S (1946) *Amer J Dis Child* 72, 296
—— Rafferty, T N, and Willis, H S (1942) *Amer Rev Tuberc* 46, 392
Kayne, G G, Pagel, W, and O'Shaughnessy, L (1939) *Pulmonary Tuberculosis*, Lond.
Kent, E M (1942) *Amer Rev Tuberc* 46, 524
Kidd, P (1885) *Brit Med J* 1, 435
Laënnec, R T H (1821) *A Treatise on the Diseases of the Chest*, translated by John Forbes, 1st Ed, Lond
Lancet (1885) Annotation, *Lancet*, 2, 395
Langer, H (1922) *Z Kinderh* 34, 142
Lightwood, R, and Wilson, R (1936) *Arch Dis Childh* 11, 321
Loeb, M (1886) *Jahrb f Kinderh* 24, 353
Macgregor, A R, and Alexander, W A (1937) *Edinb Med J* 44, 561
Macpherson, A M C (1939) *Brompton Hosp Repts* 8, 30
Meneghello, J, and Smith, C A (1943) *J Pediat* 22, 265
Morlock, H V, and Pinchin, A J S (1933) *Lancet*, 1, 1114
Oppenheimer, E H (1935) *Johns Hopkins Hosp Bull* 57, 247
Pagel, W (1932) *Beitr Klin Tuberk* 79, 383
Parker, R W (1890) *Brit Med J* 2, 899
Parsons, L G (1934) *Lancet*, 1, 1101
Peshkin, M M, and Fineman, A H (1926) *J Amer Med Ass* 86, 1429
Peterson, F (1885) *Deutsch med Wschr* 11, 145
Philibert, A, and Cordey, F (1925) *Ann de Méd* 17, 5
Pray, L G (1944) *J Pediat* 25, 253

			then low fever and dry cough No localizing signs Mantoux test positive.	gram showed complete block of right middle-lobe bronchus at origin	bronchus, growing into and obstructing middle-lobe bronchus *Histology* Connective tissue, polymorphs, and mononuclear cells No tubercle follicles seen	
5	2 9/12 yrs	F.	Duration one year Morning cough Few weeks before admission—anorexia, loss of weight, vomiting Local signs present Mantoux test positive Erythrocyte sedimentation rate 20 mm in 1 hr	Collapse of right lower and middle lobes with marked mediastinal shift	Carina major normal Right main bronchus closed by friable granulation tissue masses, which were removed by suction and forceps *Histology* Tubercle follicles, giant cells present Abundant tubercle bacilli present	Partial re-expansion right lower and middle lobes Bronchi appear to be dilated
6	3 3/12 yrs	M	Duration one year Severe cough, 'like whooping cough' Wheeze + Mantoux test positive Local signs present	*30 3 47* Collapse of left lower lobe with mediastinal shift *8 5 47* Complete re expansion of left lower lobe *7 7 47* Complete collapse of left lung *23 8 47* Partial re expansion of left lung	*3 4 47* Carina widened Bulge left main bronchus reducing lumen to a slit, ? layer of granulation tissue distal to bulge *Smear* No tubercle bacilli seen *7 7 47* Granulation tissue in left main bronchus, below this a submucosal tuberculoma Upper-lobe bronchus all filled with tissue Suction applied *25 8 47* Narrowing left main bronchus, but mucosa now intact Yellow tissue pulled from upper-lobe bronchus, it felt gritty *Histology* Caseous calcifying lymphnode containing few lymphocytes No tubercle bacilli seen	*13 10 47* Left lung almost fully re expanded Spinal caries developed To sanatorium

APPENDIX

Summary of the Author's 30 Cases

Case number	*Age*	*Sex*	*Clinical features*	*Radiograph*	*Bronchoscopy*	*Course*
1	3 2/12 yrs	F	Duration 10 days Fever, malaise, erythema nodosum Mantoux test positive Erythrocyte sedimentation rate 87 mm in 1 hr Local signs absent	On admission hilar lymph-nodes ++ Two weeks later, collapse of left upper lobe No mediastinal shift	(Plate 5, Fig 1) Carina major normal Bulge in lateral wall of left bronchus, with rotation of bronchus to right Left upper lobe bronchus much narrowed, and plugged with mucus	Re-expansion of left upper lobe slowly Onset of tuberculous meningitis 3½ months after first symptoms
2	2 6/12 yrs	F	Duration 5 weeks Fever, drowsiness, irritability, and 'wheezy cough' Localizing signs minimal Mantoux test positive Erythrocyte sedimentation rate 87 mm in 1 hr	Collapse of right middle lobe and anterior basal segment of right lower lobe No mediastinal shift	Carina major swollen Mucus in right bronchus, which was narrowed by bulge on postero medial wall On bulge several yellow 'papules' One had ruptured and caseous material flooded into the lumen—removed *Histology* Lymphnode with coagulative necrosis Tubercle bacilli abundant	Gradual re-expansion of lung Steady gain of weight four months after bronchoscopy
3	7 2/12 yrs	M	Duration six months Loss of weight, listless Wheeze ++ previous six weeks Hard spasmodic cough Marked localizing signs (see text) Mantoux test positive Erythrocyte sedimentation rate 11 mm in 1 hr	Obstructive emphysema all right lung, save segmental collapse of right lower lobe Mediastinal shift to left ++ (Plate 6, Fig 5)	(Plate 5, Fig 2) Carina major pulled to right Two large sub mucosal 'tuberculomata' in right main bronchus Check-valve action seen in operation Masses removed *Histology* (Plate 6, Fig 6) Tubercle bacilli present	Emphysema cleared after bronchoscopy, mediastinum central Child doing well two months after bronchoscopy
4	8 yrs	M	Duration four months Acute onset with high fever and dyspnoea	Collapse of right middle lobe No mediastinal shift Lipiodol broncho-	(Plate 5, Fig 4) Red bleeding, granulation tissue lower right main	Very well 11 months later, but radiograph unchanged

			cough, anorexia No local signs Mantoux test positive		medial bulge and filled with muco-pus — aspirated Lingula and anterior basal bronchus plugged by tenacious muco pus—could not be cleared by suction *Smears* No tubercle bacilli seen	
12	3 11/12 yrs	M	Duration 10 months Spasmodic cough, wheezing ++, and undue breathlessness on exertion Vomiting with cough Loss of weight Onset with pertussis 11 months previously Local signs present Mantoux test positive Erythrocyte sedimentation rate 18 mm in 1 hr	Complete collapse of left lung with mediastinum to left Small fluid layer present.	Normal carina Left bronchus much narrowed by extrinsic pressure Left upper lobe bronchus narrowed to a slit by swollen carina minor, on which seen a layer of yellow granulation tissue Muco pus ++ in all bronchi	Initial partial re expansion of left upper lobe Two months later again complete left lung collapse
13	4 yrs	M	Duration three months Acute onset with fever Since then hard spasmodic cough and loss of weight Admitted 28 7 47 with right pleural effusion, aspirated, X ray showed then collapse of right middle and lower lobes Erythrocyte sedimentation rate 60 to 90 mm in 1 hr Mantoux test positive Slow recovery after long stay in country branch Radiographs showed re expansion of middle and lower lobes and collapse of apical segment of right upper lobe On 12 1 48 erythrocyte sedimentation rate 10 mm in 1 hr, and general condition excellent	*9 1 48* Apical segment collapse of right upper lobe only Pleural thickening ++ of transverse and oblique fissures No mediastinal shift	*12 1 48* Much swollen carina major, and all minor carinae greatly swollen, which narrowed origins of the upper, middle, anterior, and axillary basal bronchi No muco-pus present Carina between main bronchus and upper lobe bronchus showed a large reddish submucosal swelling (? lymphnode which had failed to penetrate mucous membrane)	Discharged home 23 1 48 in good general health and over expected weight for age

			Clinical features	Radiograph	Bronchoscopy	Course
7	4 10/12 yrs	F	Duration five months of cough, 'like whooping cough' Tired and listless some months previously Local signs present Mantoux test positive	Collapse of right lower lobe with mediastinal shift Dilated bronchi clearly seen	Carina major widened Muco pus in right bronchus Right bronchus blocked by freely bleeding granulation tissue, partially removed by suction Main piece lost in sucker apparatus *Histology* Old blood clot, polymorphs, and mono nuclear cells only.	No change in radiograph No follow-up
8	8 yrs	F	Duration seven months Listlessness, evening fever, headaches, cough Slight hypoproteinaemic oedema on admission Mantoux test positive No localizing signs	Collapse of right middle lobe No mediastinal shift	Carina major normal Carinae minores of upper- and mid lobe bronchi grossly swollen with oedematous mucosa Bulge into main bronchus Middle lobe bronchus a slit-like opening closed by tenacious muco pus *Smear* Pus cells ++, no tubercle bacilli found	No change in radiograph Oedema steadily increased Died at home four months later
9	6 3/12 yrs	M	Duration four months Acute onset with fever and severe abdominal pain Then listlessness and cough Mantoux test positive No localizing signs	Collapse pectoral segment of right upper lobe No mediastinal shift	Marked narrowing of right main bronchus by bulge on medial wall Layer of granulation tissue overlying bulge	General condition good two months later, but radiograph unchanged
10	2 9/12 yrs	M	Duration at least one year Onset with weakness and wasting left hand (Pancoast syndrome) Listlessness + Mantoux test positive Local signs present	Complete collapse of left upper lobe, partial collapse of left lower lobe No mediastinal shift	Left main bronchus much narrowed by extrinsic pressure Upper lobe bronchus blocked by muco pus and layer of granulation tissue on floor	No immediate change in radiograph No follow-up
11	4 3/12 yrs	F	Pneumonia on four occasions since aged two years Duration of present illness seven weeks Fever, pain left chest	Collapse of lingula and anterior basal segment of left lower lobe	Normal carina Just inside right main bronchus several yellow 'papules' under mucosa Left bronchus narrowed by	No change six weeks later

17	2 5/12 yrs	M	Duration three months 'Whooping cough type' of cough with loud wheeze Local signs absent Mantoux test positive	Complete collapse of right upper lobe No mediastinal shift	Carina major grossly widened and origin of right main bronchus displaced upwards and narrowed to a slit Mucosal oedema ++ Muco-pus ++ Ulcer on posterior wall at origin of right bronchus covered with granulation layer *Smear* Clumps of mononuclears—no tubercle bacilli seen	One month later general health seemed better Radiograph unchanged
18	4 6/12 yrs	M	Duration 12 months Fever in evenings, listless, losing weight No local signs Mantoux test positive	Collapse of lingula No mediastinal shift, ? early obstructive emphysema of remainder of left upper lobe	Carina major widened Left main bronchial lumen much narrowed by extrinsic lymphnode pressure, just below origin of upper lobe bronchus Mucosal oedema ++ Muco pus ++ Entry to lingula could not be seen	Lipiodol bronchogram one month after admission showed narrowed tortuous irregularly filling lingula Three months after admission radiograph showed complete collapse of left lung with heart to left General health fairly good
19	12 3/12 yrs	M	Duration 12 months Recurrent attacks of fever and persistent dry cough Local signs present Mantoux test positive	Completely collapsed and shrunken left upper lobe, bronchi dilated Mediastinum central Lipiodol bronchogram showed complete occlusion of left upper-lobe bronchus at origin	Large bulge in lateral wall of left main bronchus reducing lumen by two thirds and causing closure of origin of left upper-lobe bronchus Mucosal oedema ++	One year later general health excellent Left upper lobe re expanded completely one month after bronchoscopy
20	9 yrs	F	Duration two months Onset with fainting attack, followed in one month by erythema nodosum For one week prior to admission fevered, drowsy, headache, vomiting No local signs Mantoux test positive	Complete collapse of right middle lobe Lipiodol bronchogram showed mid lobe stem bronchus narrowed, tortuous, and filled irregularly with lipiodol Lateral division occluded	Bulge into infero lateral wall of mid-lobe bronchus, covered with swollen, hyperaemic mucous membrane which bled readily Probe passed into mid lobe bronchus and smears made *Smears* Scanty tubercle bacilli seen	No immediate change in radiograph No follow-up

Case number	Age	Sex	Clinical features	Radiograph	Bronchoscopy	Course
14	2 10/12 yrs	M	Collapse of right lower lobe diagnosed radiologically 10 months previously, regarded as bronchiectasis Wheeze ++, with hard spasmodic cough 'Pneumonia' one month before admission to hospital Local signs present — dullness, defective breath sounds, râles Mantoux test positive Erythrocyte sedimentation rate 25 mm in 1 hr	Complete collapse of right lower lobe, with marked mediastinal shift	Anterior part of carina swollen Right upper-lobe bronchus normal Just below this, main bronchus narrowed to a slit by large bulges on either side On pressure of bronchoscope on this stenosis muco pus welled up from the distal side	No change in radiograph after bronchoscopy
15	7 6/12 yrs	M	Duration 12 months Bouts of fever, listlessness, loss of weight, dry cough Mantoux test positive Local signs minimal	Complete collapse of left upper lobe, with marked shrinkage, but no mediastinal or tracheal shift	Carina major much swollen Carina minor of left upper lobe bronchus grossly swollen and bronchial origin closed into a slit Left main bronchus at this level much narrowed with small area of granulations on mucosa of floor of bronchus *Histology* Bronchial mucosa, histiocytes, polymorphs, and mononuclears, no giant cells or tubercle follicles	No immediate change in radiograph Six months later complete expansion left upper lobe and child's general health excellent
16	1 7/12 yrs	F	Operation for right empyema eight months previously Since then cough and listlessness Fever one week before admission Local signs minimal Mantoux test positive	Complete collapse of right upper lobe, with marked mediastinal shift	Carina major widened Large bulge on posterior walls of main right bronchus with submucosal yellow lymphnodo shining through Lumen reduced by two thirds Carina minor of right upper lobe bronchus much widened, and narrowed bronchus blocked by muco pus	Four months later general health good Radiograph showed marked re expansion of right upper lobe

25	10 yrs	M	Admitted to hospital on 13 6 46 with left sided pleural effusion On 1 8 46 fluid absorbed and general health good No local signs in chest at that time Mantoux test positive Fluid was straw coloured, and contained lymphocytes	*13 6 46* Left pleural effusion with mediastinal shift to right. *1 8 46* Fluid absorbed Collapse of pectoral segment left upper lobe *24 10 46* Dilated bronchi clearly seen in left pectoral segment	*7 11 46* No abnormality in left main bronchus or opening of left upper-lobe bronchus	One year later general health excellent Back at school Symptomless Bronchiectasis of left pectoral segment still clearly seen
26	1 9/12 yrs	M	Admitted to hospital on 10 3 47 with tuberculous meningitis, and treated with streptomycin Patient slowly went downhill and died on 22 11 47	*11 3 47* Large mass of lymphnodes at right hilum and collapse of right middle lobe *21 4 47* Middle lobe expanded *11 6 47* Collapse of right lower lobe with mediastinal shift *30 8 47* Lower lobe expanded *21 10 47* Collapse of right upper lobe, and also partial collapse of left lower lobe *3 11 47* As on 21 10 47 Collapse of anterior and middle basal segments of right lower lobe	*6 11 47* Trachea kinked by paratracheal lymphnodes Carina major widened and left bronchus much narrowed and blocked by muco-pus —aspirated — mucosa healthy Right main bronchus filled with pinkish granulation tissue, which was removed *Histology* Tuberculous granulation tissue, follicular arrangement not very marked Numerous tubercle bacilli present	Radiograph on 7 11 47 showed complete expansion both lungs Bronchoscopic appearances shown at autopsy to be due to erosion of right tracheo bronchial lymphnodes into right bronchus	
3 yrs		F	Duration two and a half years Loose cough, general health good X-rayed only because of history of contact with open tuberculosis No local signs Mantoux test positive		Carina major much widened, right bronchus greatly narrowed and full of muco pus—aspirated Upper lobe bronchus normal Mid-lobe bronchus much narrowed by bulging of carina minor and swollen hyperaemic mucosa Below origin of apical lower bronchus a layer of granulation tissue on wall of main bronchus *Smear* Polymorphonuclears ++, no tubercle bacilli	No immediate change in radiograph, but gradual re expansion of collapse complete by six months later, when general health excellent	

Patient	Age	Sex	Clinical features	Radiograph	Bronchoscopy	Course
21	7 yrs	M	Duration three months Fever, anorexia, breathlessness on exertion, headaches Signs of rheumatic mitral valvular disease Mantoux test positive No local chest signs	Collapse of lateral segment of right middle lobe	Carina major widened Large lateral bulge into main bronchus distorting carina minor and closing orifice of the right mid lobe bronchus into a slit	Slow re expansion of right middle lobe, complete in two months General health good
22	6 6/12 yrs	F	Duration four months Evening fever, listlessness, dry cough No local signs Mantoux test positive	Collapse of pectoral segment of right upper lobe	Carina normal Origin of right upper lobe bronchus puckered and irregular, ? early fibrostenosis Inside upper-lobe bronchus red granulation tissue bleeding easily *Histology* Tissue contained only mononuclears, lymphocytes, and a few polymorphs No tubercle follicles seen	General health good four months after bronchoscopy Radiograph unchanged
23	6 10/12 yrs	F	Duration nine months Undue dyspnoea on exertion, spasmodic cough, anorexia Local signs detectable Mantoux test positive	Partial collapse of left upper lobe and segmental (? anterior basal) collapse of left lower lobe	Carina major widened with narrowed origin to left bronchus Entry to left upper bronchus filled with pinkish granulation tissue exuding muco pus Anterior basal bronchus narrowed by red swollen mucosa and filled with muco pus Middle and posterior basal bronchi open and separated by sharp normal carina minor Suction cleared much muco pus from occluded bronchi	Radiograph after bronchoscopy showed marked re-expansion of collapsed lobes Two months later radiograph almost normal General health good
24	5 yrs	M	Duration nine months of spasmodic cough, loss of weight, anorexia, vomiting with cough No local signs Mantoux test positive	Collapse of pectoral segment of right upper lobe	No abnormality seen in main bronchus or primary divisions Pectoral bronchus, of course, not visible through bronchoscope	Four months later general health good, but radiograph unchanged

30	9 10/12 yrs	F	History of frequent exposure in infancy First seen aged 9/12, with collapse of right lower lobe Lung puncture on two occasions produced caseous material and tubercle bacilli Treated at home Slow recovery in general health Serial radiographs showed healing by widespread calcification in right lower lobe and in right hilum At age 9 10/12 yrs general health good, 85 per cent of average weight for age Slight clubbing Scanty sputum Bronchial breath sounds at right base	*31 10 46* Collapse of right lower lobe, with marked mediastinal shift No calcification now obvious *10 11 46* Lipiodol bronchogram showed cylindrical bronchiectasis of right lower lobe	*18 11 46* Right bronchial tree patent Healthy mucous membrane Marked distortion of basal bronchial origins with fibrotic white carinae *Histology* Bronchial walls and mucous membrane intact Alveoli almost entirely replaced by fibrous tissue No evidence remaining in lung parenchyma or at lung root of tuberculosis or calcification.	Lobectomy February, 1947 Finger clubbing and cough gone Radiograph shows no abnormality save raised right diaphragm.

Case number	Age	Sex	Clinical features	Radiograph	Bronchoscopy	Course
28	3 yrs	M	Duration three weeks on admission to hospital on 28 1 47 Wheeze ++ Local signs present Erythrocyte sedimentation rate 25 mm in 1 hr Mantoux test positive Local signs varied with X ray appearances	*28 1 47* Collapse of left lower lobe with mediastinum to left *5 2 47* Hilar shadows ++ Obstructive emphysema marked in left lung Mediastinum central *13 8 47* Almost complete collapse of left lung with mediastinal shift	*6 2 47* (Plate 5, Fig 3) Carina major swollen Left bronchus narrowed Muco pus ++ was aspirated Submucosal tuberculoma on posterior wall main bronchus just distal to origin of anterior basal bronchus —seen to act as a check-valve *14 8 47* Carina major swollen and covered with a layer of granulation tissue Left main bronchus completely blocked by granulation tissue arising from both lateral and medial walls—removed with forceps Bronchial wall felt much indurated *Histology* Granulation tissue masses, but no definite tubercle follicles seen No tubercle bacilli seen	Radiograph on 7 2 47 showed no change in emphysema On 3 3 47 lung fields normal save for large lymphnode mass at left hilum Radiograph on 16 8 47 showed no change, but on 10 10 47 showed marked degree of re-expansion of left lung, which was even more marked but not complete on 30 10 47 General health good Erythrocyte sedimentation rate 20 mm in 1 hr
29	7 5/12 yrs	F	Two months history of attacks of 'bronchitis' with wheezing No local signs Asthmatoid wheeze ++ Erythrocyte sedimentation rate 5 mm in 1 hr Mantoux test positive	Collapse and dilated bronchi of right middle lobe —also a calcified primary focus and calcified right hilar glands Lipiodol bronchogram showed occlusion of right mid-lobe bronchus 1 cm from its origin	Carina major normal Right bronchus filled with very sticky muco-pus through which air bubbled Aspirated with difficulty Opening of mid lobe bronchus narrowed and puckered by fibro stenosis	No change in condition or radiograph one year later

Fig 1

Fig 2

Fig 3

Fig 4

Fig 1 Bronchoscopic view of the left main bronchus, which is narrowed by an infero lateral bulge The bronchus is rotated clockwise by glandular pressure The upper lobe bronchus is much narrowed and arising from the anterior aspect The carina between the anterior and middle basal bronchi is seen (Case 1)

Fig 2 A composite bronchoscopic view of the carina major, the lower pole of which is pulled to the right, and the right main bronchus in which are two submucosal 'tuberculomata' The picture was made during inspiration During expiration the narrow slit like lumen on the right was obliterated by the 'tuberculomata' meeting the lateral bronchial wall (Case 3)

Fig 3 Bronchoscopic view of the left bronchus The carina between the anterior and middle basal bronchi is widened by glandular pressure A submucosal 'tuberculoma' is seen in the main bronchus distal to the origin of the anterior basal bronchus During expiration the narrowed lumen between the 'tuberculoma' and bronchial wall was obliterated (Case 28)

Fig 4 Bronchoscopic view of the right main bronchus Red, bleeding granulation tissue is shown growing up the anterior wall of the bronchus and occluding the mid lobe bronchus which is seen as a depression above granulation tissue The bronchial mucosa is swollen and hyperaemic (Case 4)

Fig 1

Fig 2

Fig 3

Fig 4

Fig 1 Bronchoscopic view of the left main bronchus, which is narrowed by an infero lateral bulge The bronchus is rotated clockwise by glandular pressure The upper lobe bronchus is much narrowed and arising from the anterior aspect The carina between the anterior and middle basal bronchi is seen (Case 1)

Fig 2 A composite bronchoscopic view of the carina major, the lower pole of which is pulled to the right, and the right main bronchus in which are two submucosal 'tuberculomata' The picture was made during inspiration. During expiration the narrow slit like lumen on the right was obliterated by the 'tuberculomata' meeting the lateral bronchial wall (Case 3)

Fig 3 Bronchoscopic view of the left bronchus The carina between the anterior and middle basal bronchi is widened by glandular pressure A submucosal 'tuberculoma is seen in the main bronchus distal to the origin of the anterior basal bronchus During expiration the narrowed lumen between the 'tuberculoma' and bronchial wall was obliterated (Case 28)

Fig 4 Bronchoscopic view of the right main bronchus Red, bleeding granulation tissue is shown growing up the anterior wall of the bronchus and occluding the mid lobe bronchus, which is seen as a depression above granulation tissue The bronchial mucosa is swollen and hyperaemic (Case 4)

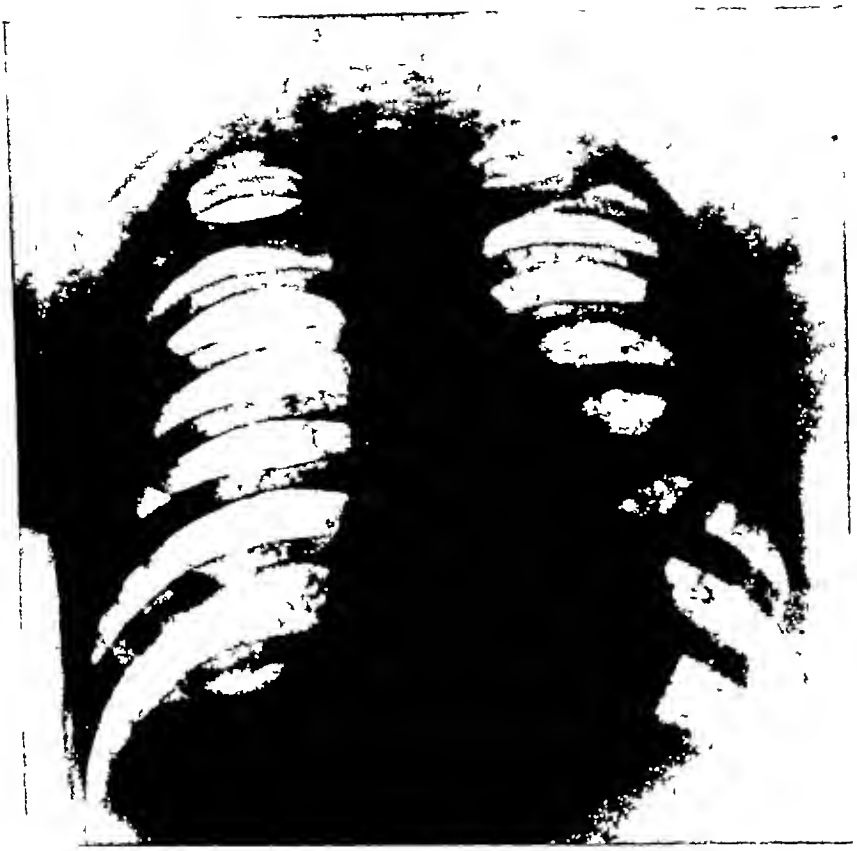

FIG 5 The film shows obstructive emphysema of the right lung, with mediastinal shift to the left, and segmental collapse of the right lower lobe (Case 3)

FIG 6 Photomicrograph, showing the histological appearances of tissue from Case 3 (Figs 2 and 5), including typical tuberculous follicles

612 463.1 · 615 783 22

THE EFFECT OF SMOKING ON WATER DIURESIS IN MAN[1]

By J M WALKER

(From the Department of Pharmacology, Oxford)

NICOTINE is the most widely used drug in this country and its effects when continually exerted over years are therefore of medical importance It is generally known that nicotine stimulates sympathetic ganglia causing a rise of blood-pressure and heart-rate, and various observers (Hesse, 1907, Roth, McDonald, and Sheard, 1944) have shown that the amount absorbed from one or two cigarettes is sufficient to raise the blood-pressure by 20 mm and the heart-rate by 10 to 20 beats per minute Recently a different effect, the liberation of the antidiuretic hormone, has been described by Burn, Truelove, and Burn (1945) Their work followed the demonstration by Pickford (1939, 1947) that acetylcholine injected into dogs inhibited a diuresis produced by giving water by mouth She proved that acetylcholine exerted its action by stimulating the supra-optic nucleus, for she injected acetylcholine into the neighbourhood of the nucleus and observed the antidiuretic action only when the injection entered the nucleus Since this action did not occur after removal of the posterior lobe of the pituitary, Pickford concluded that the acetylcholine stimulated the nucleus to send impulses along the fibres to the posterior lobe, causing a discharge of the hormone This action of acetylcholine was unaffected by atropine and was therefore a nicotine-like action. It was thus not surprising that Burn and his colleagues found that nicotine itself had the same effect in rats, and that the effect was no longer seen after hypophysectomy They showed in addition that either the intravenous injection of nicotine or the smoking of one or two cigarettes had a similar antidiuretic action in man

The present work has been done (1) to investigate the variation in the effect of smoking in man in a larger group of subjects, (2) to see whether the antidiuretic action is accompanied by a rise in total chloride excretion, as it should be if due to a liberation of posterior lobe hormone, (3) to estimate the amount of posterior lobe hormone liberated by smoking one or two cigarettes, and (4) to compare the effect of injections of morphine with those of nicotine

Results

Diuresis experiments were carried out on 16 students Each subject emptied his bladder and drank 900 c c of warm water Urine was collected and measured at intervals of 15 minutes, until the final inhibition of diuresis had passed off The cigarette was smoked, or the injection given, 45 minutes after the subject had drunk the water

[1] Received August 19, 1948

Effect of cigarette-smoking Out of 13 students seven had an inhibition of diuresis after one cigarette, and the remaining six required two cigarettes to produce an effect The results are given in Table I The figures are the number of minutes between the two peaks of diuresis (see figure) It will be seen that of those in whom only one cigarette was effective the majority were non-smokers, while of those who required two cigarettes to produce an effect the

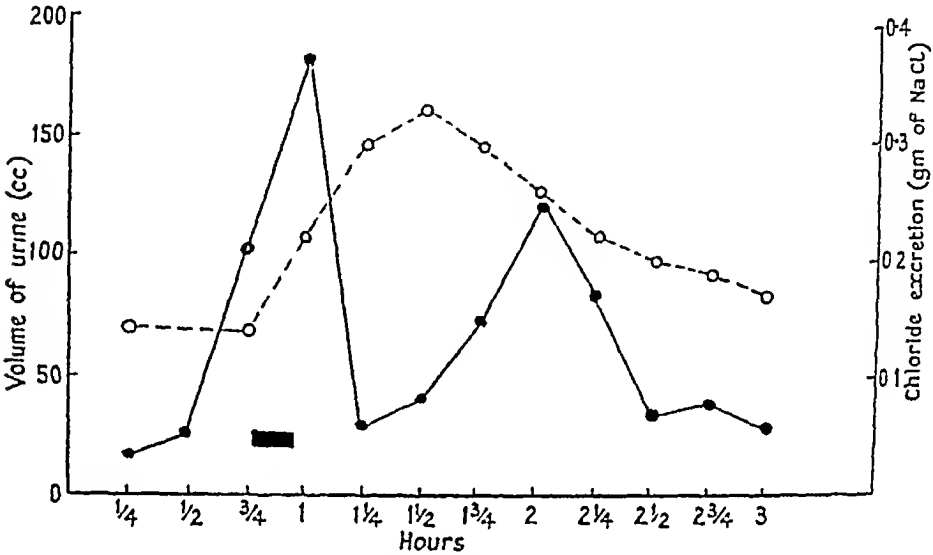

The subject drank 900 c c of water at zero He emptied his bladder at 15 min intervals The continuous line shows the volume of urine excreted After 45 mins he smoked one cigarette, which produced the inhibition shown in the graph The broken line shows the total chloride excretion Note the rise in total chloride coincident with the inhibition

majority were smokers Five students (A, B, C, D, and H) felt slight nausea during the experiments

Change in excretion of total chloride In Pickford's (1939) experiments the inhibition of diuresis caused by acetylcholine was accompanied by an increased excretion of total chlorides, an effect which is characteristic of the posterior pituitary hormone In two of the students therefore (Subjects G and J) total chlorides were estimated on each specimen of urine In both cases there was a rise in total chloride excretion coinciding with the inhibition of diuresis The result in Subject G is given in the figure

Effect of injections of nicotine Three students were given intravenous injections of nicotine acid tartrate with the results shown in Table II It will be seen that the dose of nicotine acid tartrate required to cause an inhibition of diuresis in these subjects was 1 6 to 3 0 mg Since the amount of nicotine present in the salt is approximately 50 per cent , it follows that the amount of nicotine required to cause an inhibition of diuresis in the subjects in Table II was from 0 8 to 1 5 mg Recently Ling and Wynn Parry have estimated the amount of nicotine which enters the mouth when one cigarette is smoked, and

have found that it lies in the range 0 66 to 1 2 mg The amount of nicotine which enters the blood will be the proportion of this which is inhaled Hence the effect of injected nicotine agrees quantitatively with the effect of nicotine inhaled in the smoke of one or two cigarettes It is also interesting to note that nausea may accompany the injection of nicotine without there being an inhibition of diuresis (Subject G, dose 2 0 mg of nicotine acid tartrate) and also that

TABLE I

Duration of Inhibition of Water Diuresis by Cigarette-Smoking

Subject (N)=*non-smoker* (S) = *smoker*	*By one cigarette (time in minutes)*	*By two cigarettes (time in minutes)*	*Nausea*
A (N)	165	..	+
B (N)	165	..	+
C (N)	120	..	+
D (N)	105	.	+
E (S)	75		—
F (S)	60		—
G (S)	60	..	—
H (S)	0	180	+
J (S)	0	120	—
K (N)	0	90	—
L (S)	0	90	—
M (S)	0	60	—
N (S)	0	45	—

TABLE II

Inhibition of Water Diuresis by Nicotine

Subject	*Amount of nicotine acid tartrate (mg)*	*Period of inhibition (time in minutes)*	*Nausea*
G	1 0	0	—
,,	2 0	0	+
,,	3 0	60	+
J	2 0	45	—
O	1 6	90	+

an inhibition may occur without nausea being felt (Subject J). The inhibition of diuresis must therefore be caused by the nicotine and not merely by nausea In all three subjects the inhibition of diuresis caused by the injection of nicotine was accompanied by an increased total excretion of chlorides, the peak of chloride excretion coinciding with the inhibition of diuresis

The effect of pituitary (posterior lobe) extract Injections of pituitary (posterior lobe) extract were given to six students The results are shown in Table III, where they can be compared with the effects of cigarette-smoking in the same subjects The doses of pituitary extract have been expressed in milliunits (mU) The ordinary pharmacopoeial extract contains 10 units per c c and 1 unit is equal to 1,000 milliunits It will be seen that in one case (Subject M) the period of inhibition caused by two cigarettes was almost the same as that caused by 50 mU of pituitary extract intravenously, in three cases (Subjects F, K, and L) one or two cigarettes had less effect than 50 mU, and in two cases (Subjects A and B) one cigarette had a greater effect than 50 mU The effect of

pituitary extract lasted longer when it was given subcutaneously than when given intravenously No significant difference could be detected between the effects of 50 and 100 mU given intravenously

The effects of morphine De Bodo (1944) found that large doses of morphine inhibited water diuresis in dogs It was of interest therefore to see whether therapeutic doses of morphine had the same effect in man Seven students,

TABLE III

A Comparison of the Effects of Cigarette-Smoking and Injections of Pituitary (Posterior Lobe) Extract on Water Diuresis

The figures give the duration of inhibition in minutes

			By 50 mU of pituitary extract		By 100 mU of pituitary extract	
Subject	*By one cigarette*	*By two cigarettes*	*subcutaneously*	*intravenously*	*subcutaneously*	*intravenously*
A	165			90	195	105
B	165	.		120	180	120
F	60	..	.	90	165	
K	0	90	180	135		
L	0	90	..	135	180	120
M	0	60	150	75		

45 minutes after drinking 900 c c of water, received a subcutaneous injection of 20 mg of morphine sulphate, and the effect on diuresis was noted In no case was there any inhibition of diuresis, which proceeded in a normal manner It was interesting to note that four of the students suffered from nausea as a result of the injection and of these two were severely affected, and vomited several times This confirms the conclusion already made from the nicotine experiments, that nausea does not itself necessarily lead to inhibition of water diuresis

Discussion

The experiments on cigarette-smoking confirm and extend Burn, Truelove, and Burn's (1945) findings, that the smoking of one or two cigarettes causes an inhibition of water diuresis, and suggest that non-smokers are more susceptible to this effect than habitual smokers (Table I) Nicotine injections, in amounts of the same order as those absorbed from cigarettes, also caused an inhibition of water diuresis (Table II) From Pickford's (1939) work and from Burn, Truelove, and Burn's finding that nicotine did not inhibit water diuresis in rats if the pituitary were removed, it is likely that the inhibiting effect of cigarette-smoking and nicotine is exerted through the pituitary This is further supported by the fact that in the experiments described in the present paper, the inhibition due to smoking or nicotine injection was accompanied by an increased total excretion of chlorides, an effect characteristic of the action of the posterior lobe hormone If cigarette-smoking liberates the antidiuretic hormone from the posterior lobe of the pituitary, it is important to know how much hormone is being liberated Table III gives the results of injection of

pituitary (posterior lobe) extract compared with that of cigarette-smoking It will be seen that the smoking of one or two cigarettes has an antidiuretic effect of about the same magnitude as that of the intravenous injection of 50 milliunits of pituitary extract Nausea frequently accompanies smoking and the injection of nicotine, and it is therefore important to know whether the inhibition of diuresis is a non-specific effect of nausea Table I shows that cigarette-smoking may have an antidiuretic effect even in the absence of nausea Table II shows that the injection of nicotine may cause nausea without inhibiting diuresis, and may inhibit diuresis without there being any nausea Finally, the experiments with morphine show that nausea and even vomiting may occur without there being any inhibition of diuresis The inhibition must therefore be due to the cigarette-smoking or injection of nicotine and not merely to the nausea

Summary

1 Experiments on 13 students showed that an inhibition of water diuresis was caused by the smoking of one cigarette (in seven subjects) and of two cigarettes (in six subjects) Non-smokers were more susceptible to the effect of smoking than smokers

2 In three students the intravenous injection of 1 6 to 3 0 mg of nicotine acid tartrate inhibited water diuresis

3 The inhibitory effects of smoking and nicotine were both accompanied by a rise in the total chloride excretion and were probably due to the liberation of posterior pituitary hormone

4 The effect of the smoking was of the same order as that of the intravenous injection of 50 milliunits of pituitary (posterior lobe) extract

5 There is evidence that the inhibition of water diuresis was not due to a non-specific effect of the nausea that often accompanied smoking or the injection of nicotine

6 Morphine, in therapeutic doses, does not inhibit water diuresis in man

This work was done during the tenure of a personal grant from the Medical Research Council

REFERENCES

Burn, J H , Truelove, L H , and Burn, I (1945) *Brit Med J* **1**, 403
de Bodo, R C (1944) *J Pharmacol and Exper Therap* **82**, 74
Hesse, E (1907) *Dtsch Arch Klin Med* **89**, 565
Ling, H W , and Wynn Parry, C B (unpublished)
Pickford, M (1939) *J Physiol* **95**, 226
—— (1947) *Ibid* **106**, 264
Roth, G M , McDonald, J B , and Sheard C (1944) *J Amer Med Ass* **125**, 761

546 815–099 616 155 15

ON THE NATURE AND SIGNIFICANCE OF STIPPLING IN LEAD POISONING, WITH REFERENCE TO THE EFFECT OF SPLENECTOMY[1]

By A J S McFADZEAN and L J DAVIS

(From the University Department of Medicine, Royal Infirmary, Glasgow)

With Plates 7 and 8

Introduction

In a recent paper (McFadzean and Davis, 1947) we described a series of cases of acquired haemolytic anaemia characterized by the presence of basophilic iron-positive erythrocytic inclusion bodies similar to those previously described by Pappenheimer, Thompson, Parker, and Smith (1945) We showed that although these inclusion bodies were abundant in the peripheral blood only after splenectomy, they were present in a high proportion of the red cell precursors in the bone-marrow both before and after this operation Since the red cells containing these inclusion bodies frequently presented an appearance similar to that seen in the punctate basophilia of lead poisoning, some observations were made which showed that in this condition the granules in the stippled cells not infrequently give a positive reaction for iron The present communication is concerned with certain subsequent and more detailed observations which we believe may throw a new light on the causation and significance of the stippling of lead poisoning

Material and Methods

The human material was provided by four men exposed to lead risk in the course of their employment as 'burners' in shipbreaking yards Three of the patients were admitted to hospital with acute lead colic, but the fourth had no symptoms of lead intoxication The animal material was obtained from guinea-pigs given varying doses of lead acetate, lead nitrate, or lead carbonate by mouth The lead salt was dissolved or dispersed in water and intimately mixed with the food in such a way as to ensure as far as possible that the full dose was consumed When single doses were given they were administered directly by a pipette Specimens of bone-marrow were obtained from the human patients by sternal puncture, and from the guinea-pigs by the method of McFadzean (1948) from the ilium or femur Smears were made by the squash method described by Davidson, Davis, and Innes (1943) The blood and bone-marrow films were fixed or stained immediately after preparation For the demonstration and enumeration of stippled cells Leishman's stain was

[1] Received August 17, 1948

employed and diluted with a buffer solution of pH 7 2 For the demonstration of iron, films were fixed in formalin vapour and treated with equal parts of 2 per cent potassium ferrocyanide and 2 per cent hydrochloric acid in distilled water, and counterstained with dilute carbol fuchsin.

The Morphological Characters of Stippling

The peripheral blood The morphology of stippled erythrocytes in the peripheral blood in human cases of lead poisoning has been the subject of a voluminous literature and will not be dealt with further here Although the stippling in animals experimentally poisoned with lead has also been described by several writers, we wish to emphasize certain points observed by us In guinea-pigs, when lightly poisoned, stippling in the peripheral blood was similar to that seen in human cases of lead intoxication, but normoblasts were often seen and many of these showed stippling In more severely poisoned animals a constant feature was the presence in many of the stippled cells of large and scanty granules (Plate 8, Fig 7) Frequently these were irregular in outline, and fine threads were sometimes seen linking the individual granules This coarse stippling was commonly associated with changes in the haemoglobin content of the affected normoblasts and erythrocytes In such cells the visible cytoplasm was often reduced to form a thin rim, or consisted of irregular trabeculae giving an appearance of coarse vacuolation It is of interest to note that similar changes in the haemoglobin content of coarsely stippled cells were noted by Bell, Williams, and Cunningham (1925) in the peripheral blood of patients given organic lead compounds intravenously

The bone-marrow References in the literature to stippling in the bone-marrow are scanty, and we believe that the description given below has not previously been recorded Punctate basophilia was invariably present in bone-marrow smears stained with Leishman's stain both from the human cases and the experimental animals It was seen, however, only in red cells showing evidence of haemoglobination, namely, normoblasts of varying degree of ripening, and erythrocytes The earliest cell showing recognizable stippling was the early polychrome normoblast In this cell well-defined basophil granules were seen usually in contact with the nucleus In the more mature normoblast the granules were present usually throughout the cell cytoplasm, although occasionally stippling was restricted to well-defined granules closely surrounding the nucleus The size of the individual granules showed considerable variation In coarsely stippled normoblasts a constant feature was the appearance of defective haemoglobination Not infrequently the cell cytoplasm was represented by a scanty zone, containing stipples, surrounding the nucleus In other normoblasts the cytoplasm was disposed as a narrow peripheral rim with irregular trabeculae crossing the cell, the stipples being visible in the rim and trabeculae (Plate 7, Figs 3, 4, and 5) In addition to the clearly recognizable stippling just described, certain other abnormalities were also seen within the cytoplasm of the red cell

precursors In non-haemoglobinated basophilic normoblasts a fine granularity of the cytoplasm was frequently observed in both the human and animal material Occasional cells were also seen which were unusual in that although the cytoplasm stained a deep blue, the nuclei were well condensed, resembling those of late normoblasts

In the erythrocytes in the bone-marrow preparations the stippling was in the main similar to, but coarser than, that seen in the peripheral blood The commonest forms were erythrocytes containing very coarse irregular stipples, frequently bar-shaped, and usually linked together by interlacing threads Such forms have been described by Brookfield (1928) in the peripheral blood of patients given organic lead compounds intravenously Microcytes showing stippling were also frequent A large proportion of stippled erythrocytes in the bone-marrow showed the abnormalities in haemoglobination already described (Plate 7, Fig 5) Deeply staining polychrome erythrocytes, which frequently contained dense granules, were also a feature

Large phagocytic cells with pale-staining vesicular nuclei were numerous in the guinea-pig bone-marrow smears Within the cytoplasm of these cells rounded blue-staining masses of varying size occurred, as well as fragments of red cells apparently indicative of erythrophagocytosis Similar cells, although less frequent, were also seen in the human bone-marrow films The presence of these cells in the bone-marrow of guinea-pigs poisoned with lead has already been noted by Klima and Seyfried (1937)

The Iron-staining Properties of Stippling

The application of the potassium ferrocyanide and hydrochloric acid technique to blood and bone-marrow films revealed that a variable proportion of the granules of stippling give a positive reaction for iron This was done by orientating individual cells in Leishman-stained films, de-staining, and applying the iron stain In the peripheral blood, in the human cases of lead poisoning, only a small proportion of the granules within an individual cell gave the iron reaction It was evident, moreover, that not all the stippled cells contained iron-positive granules, since comparative counts showed that the number of erythrocytes containing iron-positive granules was usually about half the number of stippled cells shown by Leishman's stain In the lead-poisoned guinea-pigs the proportion of iron-positive granules within individual stippled cells in the peripheral blood varied widely. In general, it may be stated that the more severe the intoxication, and the coarser the granules, the higher was the proportion giving an iron reaction An iron reaction was consistently given by the threads joining coarse stipples, and by the coarse granules in contact with the nuclei in normoblasts in the peripheral blood of severely poisoned animals (Plate 8, Fig 8)

In bone-marrow films iron-positive bodies were found within normoblasts, erythrocytes, and phagocytic cells Within the majority of affected red cells these bodies were multiple, but occasionally they were solitary (Plate 7, Fig 6)

employed and diluted with a buffer solution of pH 7 2 For the demonstration of iron, films were fixed in formalin vapour and treated with equal parts of 2 per cent potassium ferrocyanide and 2 per cent hydrochloric acid in distilled water, and counterstained with dilute carbol fuchsin

The Morphological Characters of Stippling

The peripheral blood The morphology of stippled erythrocytes in the peripheral blood in human cases of lead poisoning has been the subject of a voluminous literature and will not be dealt with further here Although the stippling in animals experimentally poisoned with lead has also been described by several writers, we wish to emphasize certain points observed by us In guinea-pigs, when lightly poisoned, stippling in the peripheral blood was similar to that seen in human cases of lead intoxication, but normoblasts were often seen and many of these showed stippling In more severely poisoned animals a constant feature was the presence in many of the stippled cells of large and scanty granules (Plate 8, Fig 7) Frequently these were irregular in outline, and fine threads were sometimes seen linking the individual granules This coarse stippling was commonly associated with changes in the haemoglobin content of the affected normoblasts and erythrocytes In such cells the visible cytoplasm was often reduced to form a thin rim, or consisted of irregular trabeculae giving an appearance of coarse vacuolation It is of interest to note that similar changes in the haemoglobin content of coarsely stippled cells were noted by Bell, Williams, and Cunningham (1925) in the peripheral blood of patients given organic lead compounds intravenously

The bone-marrow References in the literature to stippling in the bone-marrow are scanty, and we believe that the description given below has not previously been recorded Punctate basophilia was invariably present in bone-marrow smears stained with Leishman's stain both from the human cases and the experimental animals It was seen, however, only in red cells showing evidence of haemoglobination, namely, normoblasts of varying degree of ripening, and erythrocytes The earliest cell showing recognizable stippling was the early polychrome normoblast In this cell well-defined basophil granules were seen usually in contact with the nucleus In the more mature normoblast the granules were present usually throughout the cell cytoplasm, although occasionally stippling was restricted to well-defined granules closely surrounding the nucleus The size of the individual granules showed considerable variation In coarsely stippled normoblasts a constant feature was the appearance of defective haemoglobination Not infrequently the cell cytoplasm was represented by a scanty zone, containing stipples, surrounding the nucleus In other normoblasts the cytoplasm was disposed as a narrow peripheral rim with irregular trabeculae crossing the cell, the stipples being visible in the rim and trabeculae (Plate 7, Figs 3, 4, and 5) In addition to the clearly recognizable stippling just described, certain other abnormalities were also seen within the cytoplasm of the red cell

in peripheral blood-films made on the same date It should be noted that only cells containing discrete basophilic granules were regarded as stippled cells The proportion of haemoglobinating normoblasts in the bone-marrow showing stippling was invariably higher than the proportion of erythrocytes in the peripheral blood showing stippling Furthermore, in the bone-marrow the

TABLE II

Guinea-pigs Experimentally Poisoned with Lead Salts

Incidence of Stippled Cells in Peripheral Blood and Bone-Marrow

(Leishman's Stain)

	Peripheral blood		*Bone marrow*		
Guinea-pig number	*Stippled cells (per cent)*	*Red cells (millions per c mm)*	*Polychrome normoblasts, percentage showing stippling*	*Erythrocytes, percentage showing stippling*	*Remarks*
1	5 7	2 9	80	14	Severely poisoned, prolonged dosage
2	3 1	2 4	80	9	Severely poisoned, prolonged dosage
3	4 7	3 1	80	11	Severely poisoned, prolonged dosage
4	0·2	4 6	40	1	Lightly poisoned
	1 1	3 5	80	5	Severely poisoned
5	0 5	4 4	60	3	100 mg of lead acetate daily for 5 days
6	0·2	4 8	60	8	100 mg of lead nitrate daily for 8 days
7	0	5 1	40	+	22 hours after a single dose of 75 mg of lead acetate
8	0	5 4	50	0·03	22 hours after a single dose of 75 mg of lead acetate
9					Single dose of 100 mg of lead acetate
	0		0	0	4 hours later
	0		+	+	7 hours later
	0		9	+	11 hours later
	+		60	0 1	34 hours later Killed

'+' = Seen after prolonged search

frequency of stippled erythrocytes was significantly higher than in the peripheral blood On no occasion were stippled cells seen in the peripheral blood and not in the bone-marrow On the contrary, after the disappearance of stippled cells from the peripheral blood, stippled normoblasts and erythrocytes were still found in the bone-marrow It should be noted that in Case 4 (Table I) no stippled cells were seen in the peripheral blood, although in the bone-marrow approximately 3 per cent of the haemoglobinating normoblasts showed stippling Furthermore, in both of the guinea-pigs given a single dose of 75 mg of lead acetate, stippled normoblasts and erythrocytes were seen in bone-marrow smears 22 hours later, when no stippled erythrocytes were seen in peripheral

The proportion of normoblasts containing iron-positive granules approximated closely to the proportion of normoblasts showing stippling in Leishman stained preparations By orientating individual cells in Leishman-stained films, destaining, and applying the iron stain, it was established that it was the granules of stippling which gave this reaction, although within an individual cell the proportion which did so was variable Employing this technique it was possible to show that the iron-staining granules were restricted, in the red cell series, to haemoglobinating normoblasts and erythrocytes In stippled normoblasts the granules in contact with the nuclei consistently stained for iron, whereas only a varying proportion of the granules scattered throughout the cell cytoplasm did so Occasional normoblasts were seen in which the cytoplasm was almost completely replaced by iron-staining material These cells were apparently the same as those already described as having well-condensed nuclei and cytoplasm staining deep blue with Leishman's stain

Frequency of Stippling in Bone-marrow and Peripheral Blood

The frequency of stippling in the different types of cell in bone-marrow films is set out in Tables I and II, and is compared with the incidence of stippled cells

TABLE I

Human Cases of Lead Poisoning

Incidence of Stippled Cells in Peripheral Blood and Bone-Marrow (Leishman's Stain)

		Peripheral blood			*Sternal marrow*		
Case number	*Date*	*Stippled cells (per cent)*	*Red cells (millions per c mm)*	*Reticulocytes (per cent)*	*Polychrome normoblasts, percentage showing stippling*	*Erythrocytes, percentage showing stippling*	*Remarks*
1	Aug 25, 1947	0 9	3 46	3 1	42	2 7	Symptoms of acute poisoning
	Sept 9, 1947	0	4 12	2 0	7	0 06	Symptomless
2	Sept 4, 1947	0 4	4 0	3 2	28	1 3	Symptoms of acute poisoning in week preceding admission
	Sept 12, 1947	0	3 9	2 3	4	0 04	Symptomless
3	Dec 22, 1947	0 3	3 81	3 6	60	4 3	Symptoms of acute poisoning
	Jan 5, 1948	0	3 64	4 2	3	0 01	Symptomless
	Jan 27, 1948	0	3 90	1 2	0	0	Symptomless
4	Mar 2, 1948	0	4 9	0·1	3	+	Exposed to lead risk, but symptomless

'+' = Seen after prolonged search

TABLE III

The Red Cell and Reticulocyte Counts and the Incidence of Stippled Cells in the Peripheral Blood and Bone-Marrow of Splenectomized and Non-Splenectomized Guinea-Pigs given 100 mg per kg of Lead Carbonate by Mouth Daily

		Splenectomized guinea pigs						Control guinea pigs					
		Peripheral blood			Bone marrow			Peripheral blood			Bone-marrow		
Animal number	Days after starting lead	Stippled cells (per cent)	Red cells (millions per c mm)	Reticulocytes (per cent)	Polychrome normoblasts, percentage showing stippling	Erythrocytes, percentage showing stippling	Animal number	Days after starting lead	Stippled cells (per cent)	Red cells (millions per c mm)	Reticulocytes (per cent)	Polychrome normoblasts, percentage showing stippling	Erythrocytes, percentage showing stippling
1	0	0	5 4	1			1	0	0	5 8	0 8		
	15	5	5 1					15	0 1	5 8			
	22	14						22	0 3				
	26	20	5 4	4	..			26	0 5	4 3	5		
	33	32						33	0 5	4 1	7		
	38							38	3 0				
	40	36	4 8		60	40		40	1 0	4 0		50	4
	47	36	5 0	4				47	0 3	4 2	6		
	57	42						57	0 3				
2	0	0	5 2	2			2	0	0	5 5	0 2		
	15	12	4 9					15	0·1	4 6			
	22	28			50	32		22	1 0			40	2
	26	25	5 0	7				26	1 3	4 1	4		
	33	30	4 6	6	70			33	1 5	3 4		80	3
	40	40						40	2 0				
	43	36						43	3 5				.
	47	44	4 8	3				47	1 5	3 3	9		.
3	0	0	5 1	0 5			3	0	0	5 5	1		
	15	3	5 3					15	1 5	4 0			
	22	8		6				22	7 5		16		
	26	19	5 4		80	30		26	3	3 8		60	8
	33	19	5 2	3				33	1 0	3 6	9		
	40	29			60			40	0 4	3 2		70	5
	47	45	4 6					47	0 3	3 5			
	57	48						57	0·3				

blood (Table II, Nos. 7 and 8) In a third guinea-pig given 100 mg of lead acetate stippled cells were detected in marrow smears seven hours later, and not until 34 hours later, when 60 per cent of the haemoglobinating normoblasts in marrow smears showed stippling, were stippled erythrocytes found in the peripheral blood (Table II, No 9)

The Effect of Splenectomy in Guinea-pigs Poisoned with Lead

In view of the effect of splenectomy upon the incidence in the peripheral blood of the erythrocytic inclusions in the cases of acquired haemolytic anaemia

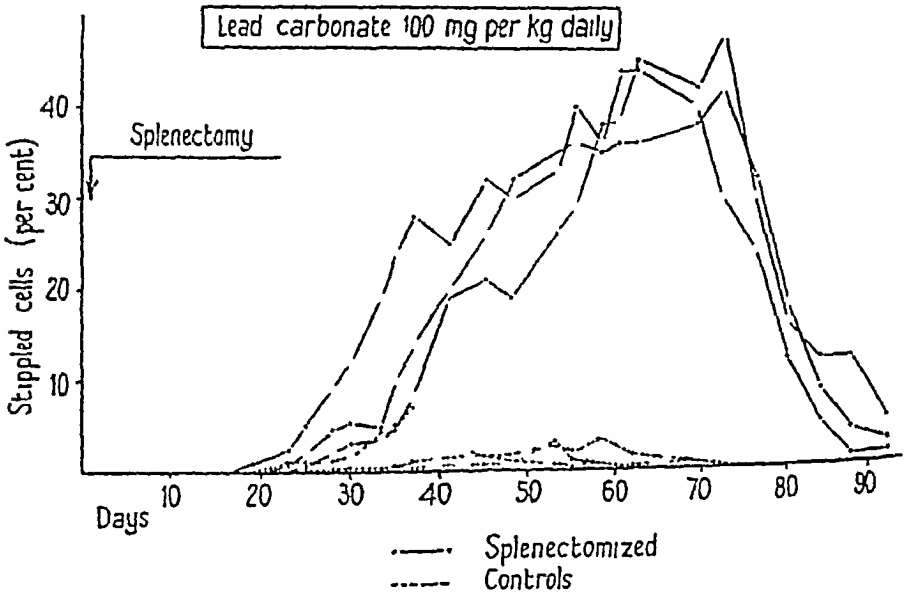

FIG 1 The effect of splenectomy upon the incidence of stippled cells in the peripheral blood of guinea pigs subsequently poisoned with lead

described by us (McFadzean and Davis, 1947), it appeared desirable to determine the effect of this operation in experimental lead poisoning Observations were made in the first place on three recently splenectomized guinea-pigs, with three intact guinea-pigs of approximately the same age serving as controls Before commencing the experiment repeated blood-films were examined and no stippled cells were found in any of the guinea-pigs The administration of lead carbonate, in daily doses of 100 mg per kilogram of body-weight, was commenced 14 days after splenectomy The stippled cell counts in the peripheral blood of the splenectomized and control animals are depicted in Fig 1 It will be seen that in all the splenectomized animals there was a progressive climb in the stippled cells until they constituted some 40 per cent of the erythrocytes in the peripheral blood In the control animals the proportion of stippled cells was significantly lower, the highest figures being 7 5 per cent in one animal, while in the other two the maximum incidence was 3 5 per cent

animals the downward trend in the red cell counts was arrested and a rise occurred. In one animal the red cell count rose from 3,550,000 to 4,650,000 per c mm in 20 days, and in the remaining two from 3,960,000 and 4,550,000 to 5,070,000 and 5,100,000 per c mm respectively in 11 days In the last two animals there was subsequently a fall in the red cell counts, but coincident with this fall the picture was complicated by bleeding from the abdominal wounds,

TABLE IV

The Effect of Splenectomy upon the Red Cell Counts and upon the Incidence of Stippled Cells in the Peripheral Blood of Guinea-Pigs given 100 mg of Lead Nitrate by Mouth Daily

Days after starting lead	Animal No 1		Animal No 2		Animal No 3	
	Red cells (millions per c mm)	Stippled cells (per cent)	Red cells (millions per c mm)	Stippled cells (per cent)	Red cells (millions per c mm)	Stippled cells (per cent)
0	5 40	0	5 91	0	5 89	0
6	5 20	+	5 76	+	5 88	0
15	4 90	0·01	5 47	0 1	5 75	0·02
18	4 80	0 2	4 98	0 05	4 93	0 3
20	4 10	0 5	4 41	0 01	4 47	0 9
23	3 80	1 5	4 73	0 3	3 91	1
25	3 55	4	4 55	0 3	3 96	1
	Splenectomy		Splenectomy		Splenectomy	
27	4 03	12	5 19	15	4 59	10
29			4 70	18	4 46	12
32	4 33	24	4 73	18	4 61	15
34	4 15	22	5 02	26	4 44	24
36			5 10	24	5 07	28
39	4 42	30	5 04	34	4 57	38
41			4 41	40	4 04	40
43	4 60	34	4 40	46	4 00	44
46	4 65	39	4 40	50	4 17	40
48	Died		4 30	52	4 44	46
			Killed		Killed	
	Control No 1		Control No 2		Control No 3	
0	5 20	0	5 68	0	5 58	0
6	5 40	0	5 69	+	5 88	0
15	4 80	+	5 98	+	6 19	+
18	4 50	0·5	5 74	0·01	5 83	+
20	4 70	2	4 58	0·05	5 21	+
23	4 35	2 5	4 03	0·1	4 92	+
25	4 34	3	4 06	0 06	4 90	0 05
27	4 35	4	4 21	0·6	5 35	0·1
29			4 18	0·9	4 93	0·01
32	3 68	3	3 81	3	5 20	0·5
34	3 34	2 5	3 46	4	5 17	0·5
36			3 41	3	5 00	1
39	3 09	6	3 30	2	5 14	2
41			3 23	7	5 05	1
43	2 80	7 5	3 00	6	4 46	2 5
	Died					
46			Died		4 50	2
48					4 00	2 5

'+' = Seen after prolonged search

and 3 per cent On withdrawal of the lead 45 days after its commencement, stippled cells persisted in the peripheral blood of the splenectomized animals for periods significantly longer than in the controls The incidence of stippling in the bone-marrow is set out in Table III It will be seen that there was little difference between the incidence of stippled haemoglobinating normoblasts in the splenectomized and the control groups. In a second experiment six guinea-

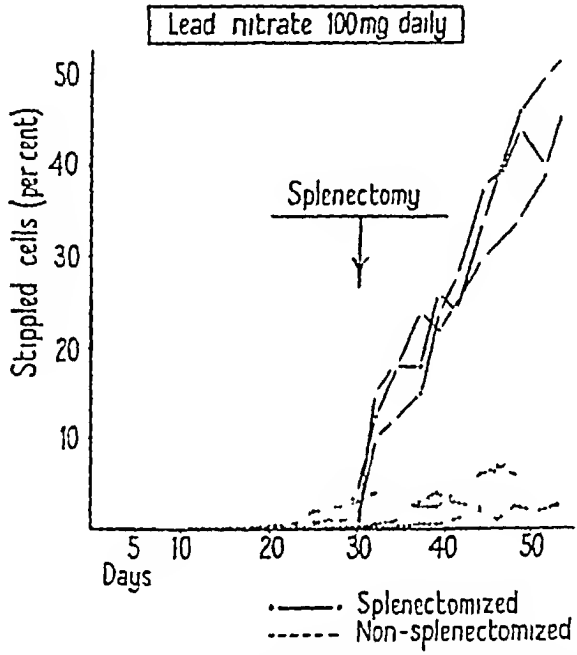

FIG 2 The effect of splenectomy upon the incidence of stippled cells in the peripheral blood of guinea-pigs already poisoned with lead

pigs of the same age were each given a daily dose of 100 mg of lead nitrate throughout the experiment Twenty-five days later when stippling and anaemia had developed, splenectomy was performed on three of the animals, the remaining three acting as controls The stippled cell counts in the peripheral blood are set out in Fig 2 It will be seen that splenectomy was followed by a rapid and progressive increase in the stippled cells which rose from the pre-splenectomy levels of 4, 0 3, and 1 per cent to 39, 52, and 46 per cent respectively In the control animals the highest counts recorded were 7 5, 7, and 2 5 per cent respectively The bone-marrows were not examined in this experiment since it was considered desirable to avoid trauma and loss of blood

With regard to the effect of splenectomy upon the anaemia, it will be seen from Table III that the control animals developed anaemia while the splenectomized animals showed only a slight reduction in the red cell counts The red cell and stippled cell counts in the second experiment are set out in Table IV. Coincident with the increase in the stippled cells after splenectomy, in all three

granules were seen in normoblasts in the bone-marrow of lead-poisoned guinea-pigs irrespective of whether they were splenectomized or not Comparison of bone-marrow smears from the splenectomized animals with those from controls showed no fundamental difference in respect of the stippling in the normoblasts The changes in the red cell series were similar to those already described, but there was an increase in the number of stippled erythrocytes in the splenectomized animals, presumably occasioned by admixture with systemic blood in which there was a high stippled cell count

The spleens removed from guinea-pigs which had been poisoned with lead were obviously abnormal Splenomegaly was a constant finding Thus, in the second experiment described above, the weights of the spleens were respectively 1 8, 2 0, and 2 5 gm whereas in normal guinea-pigs of about the same age the spleen weights ranged from 0 5 to 1 gm On histological examination it was apparent that the splenomegaly was due mainly to engorgement of the pulp with red cells, although hyperplasia of the reticulum cells was also evident Haemosiderosis was a marked and constant feature In sections treated with potassium ferrocyanide and hydrochloric acid, iron-staining material was abundant It occurred in the form of small granules as well as in larger masses In sections stained with haematoxylin and eosin, eosinophilic cytoplasmic inclusions, resembling diminutive erythrocytes, were seen in many of the endothelial cells We are tempted to regard this as evidence of erythrophagocytosis, but, since we find it difficult to interpret this phenomenon with certainty in histological sections, we are reluctant to draw any definite conclusions in this respect Sections stained with methylene blue and other stains were searched for stippled cells, but none could positively be identified The difficulty in recognizing stippling in histological sections is probably the reason why earlier investigators failed to find it in the bone-marrow in patients and animals poisoned with lead It will be appreciated that the above findings are similar to those seen in the spleen in haemolytic anaemia in general, and indicate that the spleen is concerned with the disposal of the products of erythrocyte destruction, if it is not actually a site of their destruction

Discussion

Although much has been written concerning the stippling of lead poisoning in the peripheral blood, relatively little information is available concerning its occurrence in the bone-marrow Key (1924) reported that the bone-marrow of rabbits experimentally poisoned with lead revealed no stippling, although large numbers of stippled cells were present in the peripheral blood He concluded that stippling represented a change in the basophilic substance of the young red cell which took place after its entry into the peripheral circulation Bell, Williams, and Cunningham (1925) failed to find stippled cells in the marrow of animals dying of lead poisoning More recently, however, the presence of stippled cells in the bone-marrow of man has been reported by Klima and Seyfried (1937), Henning and Keilhack (1940), Bentsáth and Varga (1940),

which subsequently broke down, necessitating their being killed In two of the control (non-splenectomized) animals of this group the red cell counts fell progressively throughout the period of the experiment and the levels reached were 2,800,000 and 3,000,000 per c mm when the animals died In the third control the degree of anaemia which developed was slight and the lowest count reached was 4,000,000 per c.mm

Reticulocyte counts were made in the first experiment and are set out in Table III In the splenectomized animals the stippled cells greatly exceeded the reticulocytes, whereas in the controls the reticulocytes were invariably more numerous than the stippled cells

Splenectomy was followed not only by an increased frequency of the stippled erythrocytes in the peripheral blood, but also by morphological changes in the stippling in many of these cells Although a minority of the stippled erythrocytes after splenectomy were indistinguishable from those seen in the control animals which had not been splenectomized, the majority displayed certain features which were seen only in the splenectomized animals This type of stippling, which we believe to be characteristic of splenectomy, presents the following appearances as compared with the stippling seen in the non-splenectomized controls (Plate 8, Fig 9) The granules are smaller, they tend to be aggregated together rather than dispersed throughout the erythrocyte, and they are often seen to be connected by fine threads In Leishman-stained films the individual granules present a purplish colour rather than the bluish-black colour seen in the non-splenectomized animals Although in some erythrocytes the aggregations of stippled granules are composed of large numbers of individual granules, in others the granules may be relatively scanty, but they still display the tendency to aggregation In some erythrocytes the granules are distributed in a peculiar circular fashion, similar to the perinuclear distribution seen in certain normoblasts in the bone-marrow (Plate 8, Figs 9 and 11) A constant and characteristic feature of blood-films in the splenectomized guinea-pigs is that, when stained with potassium ferrocyanide and hydrochloric acid, the great majority of the granules of stippling give a positive reaction for iron, whereas in the control animals this reaction is given only by a minority of the individual granules of stippling in the peripheral blood (Plate 8, Fig 10) In erythrocytes displaying these features characteristic of splenectomy the cytoplasm usually stains a full pink with Leishman's stain and seldom shows the vacuolation or other morphological signs of defective haemoglobination Furthermore, when stained supravitally with brilliant cresyl blue, such cells do not show reticulum It is inferred, therefore, that they represent more mature types of cell than the stippled cell seen in the non-splenectomized animal

Another finding in the peripheral blood after splenectomy was the presence of erythrocytes containing solitary granules which stained purplish with Leishman's stain and invariably gave a positive iron reaction Whether these solitary granules are identical with the granules of stippling is an open question, but it should be noted that they were not considered to be such in performing the stippled cell counts It is significant, however, that solitary iron-positive

30344.

(McFadzean and Davis, 1947) In that paper we advanced the view that the inclusion bodies resulted from defective haemoglobin synthesis The possibility therefore arises that the iron-containing stipples of lead poisoning may result from a similar defect

Dustin (1942) has adduced evidence that the granules of stippling in lead poisoning contain ribonucleic acid, which is normally present in the cytoplasmic basophil substance of immature red cells, but not in haemoglobinated cells (Thorell, 1944, White, 1947) It seems probable (Brachet, 1942) that the ribonucleoprotein particles in the cytoplasm are concerned with protein synthesis, presumably including the formation of haemoglobin in the case of normoblasts The abnormal occurrence of ribonucleic acid in close association with stainable iron, especially in cells showing defective haemoglobination, therefore suggests some interference with the incorporation of the iron into the protoporphyrin nucleus In this connexion it should be noted that Rimington (1938) has suggested that lead inhibits haemoglobin synthesis by preventing the incorporation of iron into the protoporphyrin nucleus, and Kark and Meikle-john (1942) concluded that the stippling of lead poisoning results from faulty haemoglobin synthesis causing an accumulation of porphyrin in the erythro-cytes On the other hand, Kench, Gillam, and Lane (1942) and Falconer (1942) considered that it interferes with the formation of protoporphyrin

The effects of splenectomy in guinea-pigs poisoned with lead closely parallel those previously observed by us in certain of our cases of acquired haemolytic anaemia, namely, a marked increase in the peripheral blood of erythrocytes containing iron-positive inclusions, unaccompanied by recognizable changes in the frequency or character of the inclusion bodies in the normoblasts of the sternal marrow Splenectomy in these cases was also followed by rises in the total red cell counts, which could be accounted for by the actual increases in the number of erythrocytes containing inclusion bodies These considerations caused us to suggest that, in the type of acquired haemolytic anaemia studied by us, the actual cause of the anaemia was the removal of the abnormal erythro-cytes from the peripheral blood by the spleen shortly after their entry into the circulation, and that the beneficial effect of splenectomy was attributable to the cessation of this mechanism Although the number of guinea-pigs subjected to splenectomy was small, the effect of this operation was so striking and so constant that we consider that it may be accepted as significant The operation was invariably followed by a rise in the frequency of stippled cells in the peri-pheral blood to a level considerably in excess of that seen in control animals Splenectomy was, moreover, without apparent effect upon the incidence or character of stippling in the red cell precursors in the bone-marrow

With regard to the effect of splenectomy upon the red cell counts in the guinea-pigs, we feel that our data, while not conclusive, are suggestive that the operation exerted a similar effect to that observed by us in the human cases of acquired haemolytic anaemia In the animals that were splenectomized before the administration of lead the rise in the stippled cell counts was accompanied by relatively high red cell counts, in contrast with the definite anaemia that

and Movitt (1945) Albahary (1945), to investigate the origin of stippled cells, gave lead acetate intravenously to human volunteers and found stippled cells in the marrow before they appeared in the peripheral blood. None of these authors give details of the types of cell in the marrow displaying the stippling, although some of them refer to stippled normoblasts, and Klima and Seyfried (1937) gave photographs of bone-marrow smears showing stippling in nucleated red cell precursors

We consider that our own observations provide reasonably good evidence that the phenomenon of stippling in lead poisoning results primarily from the effect exerted by the lead upon the red cell precursors in the bone-marrow rather than upon the erythrocytes in the peripheral circulation In support of this contention it may be emphasized that the frequency in the bone-marrow of normoblasts with well-marked stippling was invariably considerably higher than that of stippled erythrocytes in the peripheral blood. Although a variable proportion of erythrocytes in bone-marrow smears obtained by biopsy is derived from the peripheral blood circulating in the marrow, it should be noted that the proportion of stippled erythrocytes in our bone-marrow preparations was also significantly higher than that in the peripheral blood-films Moreover, in guinea-pigs receiving a single dose of lead, numerous stippled normoblasts and erythrocytes were seen in the bone-marrow before stippling was evident in the peripheral blood

With regard to the developmental stages of the red cell in which stippling occurs, it may be stated that clearly recognizable punctate basophilia is seen in polychrome normoblasts at the stage of early haemoglobination, and that the stippling apparently develops in intensity as the cytoplasm of the normoblast undergoes ripening Since stippling when it occurs in erythrocytes is invariably present in normoblasts, and in a relatively high proportion of them, it seems probable that its early development may be confined to these cells Nevertheless, it must be admitted that our observations do not justify the rejection of the possibility that stippling may also occur *de novo* in non-nucleated red cells Reference has been made to the peculiar granular appearance of cytoplasm in basophil normoblasts Whether this is caused by the lead, and whether it is related to the occurrence of stippling, are questions we are at present unable to answer

The demonstration of iron in connexion with the stippling of lead poisoning does not appear to have previously been recorded, apart from our own preliminary communication (McFadzean and Davis, 1947) The validity of our belief that the granules revealed by the iron stain are identical with the basophil granules is based upon the technical considerations already dealt with, and need not be considered further here The occurrence of the coarser, iron-positive, granules in normoblasts was usually accompanied by the morphological appearances of defective haemoglobination already described In this respect, as well as in respect of their morphology, staining reactions, development, and occurrence, the granules seen in the stippled cells of lead poisoning closely resemble the erythrocytic inclusions described by us in certain acquired haemolytic anaemias

(McFadzean and Davis, 1947) In that paper we advanced the view that the inclusion bodies resulted from defective haemoglobin synthesis The possibility therefore arises that the iron-containing stipples of lead poisoning may result from a similar defect

Dustin (1942) has adduced evidence that the granules of stippling in lead poisoning contain ribonucleic acid, which is normally present in the cytoplasmic basophil substance of immature red cells, but not in haemoglobinated cells (Thorell, 1944, White, 1947) It seems probable (Brachet, 1942) that the ribonucleoprotein particles in the cytoplasm are concerned with protein synthesis, presumably including the formation of haemoglobin in the case of normoblasts The abnormal occurrence of ribonucleic acid in close association with stainable iron, especially in cells showing defective haemoglobination, therefore suggests some interference with the incorporation of the iron into the protoporphyrin nucleus In this connexion it should be noted that Rimington (1938) has suggested that lead inhibits haemoglobin synthesis by preventing the incorporation of iron into the protoporphyrin nucleus, and Kark and Meikle-john (1942) concluded that the stippling of lead poisoning results from faulty haemoglobin synthesis causing an accumulation of porphyrin in the erythro-cytes On the other hand, Kench, Gillam, and Lane (1942) and Falconer (1942) considered that it interferes with the formation of protoporphyrin

The effects of splenectomy in guinea-pigs poisoned with lead closely parallel those previously observed by us in certain of our cases of acquired haemolytic anaemia, namely, a marked increase in the peripheral blood of erythrocytes containing iron-positive inclusions, unaccompanied by recognizable changes in the frequency or character of the inclusion bodies in the normoblasts of the sternal marrow Splenectomy in these cases was also followed by rises in the total red cell counts, which could be accounted for by the actual increases in the number of erythrocytes containing inclusion bodies These considerations caused us to suggest that, in the type of acquired haemolytic anaemia studied by us, the actual cause of the anaemia was the removal of the abnormal erythro-cytes from the peripheral blood by the spleen shortly after their entry into the circulation, and that the beneficial effect of splenectomy was attributable to the cessation of this mechanism Although the number of guinea-pigs subjected to splenectomy was small, the effect of this operation was so striking and so constant that we consider that it may be accepted as significant The operation was invariably followed by a rise in the frequency of stippled cells in the peri-pheral blood to a level considerably in excess of that seen in control animals Splenectomy was, moreover, without apparent effect upon the incidence or character of stippling in the red cell precursors in the bone-marrow.

With regard to the effect of splenectomy upon the red cell counts in the guinea-pigs, we feel that our data, while not conclusive, are suggestive that the operation exerted a similar effect to that observed by us in the human cases of acquired haemolytic anaemia In the animals that were splenectomized before the administration of lead the rise in the stippled cell counts was accompanied by relatively high red cell counts, in contrast with the definite anaemia that

developed in the non-splenectomized animals receiving the same doses of lead In the animals splenectomized after the development of anaemia there was arrest of the downward trend in the red cell counts, followed by a rise which coincided with the increase in the stippled cells in the peripheral blood It must be admitted that the interpretation of this experiment is obscured by the subsequent fall in the red cell counts in two of the animals despite a continued increase in stippled cells We believe that this may be explained by bleeding from the abdominal wounds, which broke down, but since alternative mechanisms cannot be excluded, our findings obviously need confirmation by repetition of the experiment on a larger scale The morphological changes in the stippled cells which accompanied their increased incidence in the peripheral blood after splenectomy may be explained by the suggestion that this operation results in the persistence in the circulation of cells that would otherwise have been removed by the spleen, thus allowing changes akin to maturation to occur, *namely, the progressive disappearance of iron-free basophilic material* and reticulum from stippled cells

Our interpretation of the findings presented in this communication may be summarized as follows One of the toxic effects of lead is exerted upon the red cell precursors in the bone-marrow, resulting in defective haemoglobination and the persistence of basophilic substance in a granular form associated with demonstrable iron Cells derived from these precursors, after their entry into the circulation, are rapidly taken up by the spleen, and presumably also by the reticulo-endothelial system elsewhere The more grossly defective cells with coarse or numerous iron-positive granules are eliminated from the circulation with greater avidity than cells containing no or few iron-positive granules Consequently only the latter type of cell is usually seen in the peripheral blood when the spleen is intact This mechanism results in a haemolytic type of anaemia, the severity of which will vary with the intensity and duration of the lead poisoning It will be seen that this hypothesis would reconcile the two opposing views that have been advanced concerning the nature of the anaemia of lead poisoning The belief that the anaemia is haemolytic in type has gained general acceptance, but more recently the view that it is dyshaemopoietic resulting from a fault in haemoglobin synthesis has received support from the authors already quoted (Rimington, 1938, Kark and Meiklejohn, 1942, Kench, Gillam, and Lane, 1942, Falconer, 1942) It will be recalled that the histological appearances of the spleens removed from guinea-pigs during lead poisoning were similar to those seen in haemolytic anaemia Although there is no conclusive evidence that the stippled erythrocytes are actually destroyed in the spleen, the histological findings are compatible with this possibility

If the hypothesis advanced above concerning the stippling in lead poisoning and its relation to the associated anaemia is correct in its broad outline, its wider significance will be evident Apart from its bearings upon the haematological manifestations in lead poisoning, it may possibly lead to an explanation of the aetiological mechanism of the idiopathic acquired haemolytic anaemias displaying the erythrocytic inclusion bodies already referred to An obvious

suggestion is that this type of anaemia may result from the action of some toxic substance, either endogenous or exogenous in origin, which exerts an effect upon the red cell precursors similar to that of lead.

Summary and Conclusions

1 The stippling of lead poisoning has been studied in human patients and in experimental guinea-pigs

2 Stippling is readily demonstrable in the bone-marrow, both in erythrocytes and in normoblasts of varying stages of haemoglobination The intensity of stippling in the bone-marrow is invariably considerably higher than in the peripheral blood

3 A variable proportion of the granules of stippling give a positive reaction for iron This reaction is seen more frequently in the bone-marrow than in the peripheral blood, and is often associated with the appearance of defective haemoglobination in the affected cells

4 In guinea-pigs poisoned with lead, splenectomy results in a very considerable increase in the frequency of stippling in the peripheral blood This is accompanied by morphological changes in the stippling in the peripheral blood, and in an increased frequency of granules giving a positive iron reaction, but it is not associated with apparent changes, either quantitative or qualitative, in the stippling in the red cell precursors in the bone-marrow Splenectomy is also followed by an amelioration of the anaemia induced by lead poisoning

5 The significance of these observations is discussed It is suggested that lead exerts its haematological effect primarily upon the nucleated red cell precursors in the bone-marrow, resulting in defective haemoglobination consequent upon a partial failure in the incorporation of iron into the protoporphyrin nucleus The view is also advanced that the defective erythrocytes produced are normally removed from the circulation by the spleen, and probably also by the reticulo-endothelial system in general Attention is drawn to the possible bearing of this hypothesis upon the pathogenesis of certain idiopathic acquired haemolytic anaemias

We have pleasure in recording our indebtedness to Professors J W S Blacklock and G M Wyburn for providing facilities in their departments, and to Dr L Crombie for sending us patients suffering from lead poisoning Part of the expenses incurred were provided by the Rankin Fund of Glasgow University

REFERENCES

Albahary, C (1945) *Le Sang*, **16**, 341
Bell, W Blair, Williams, W R, and Cunningham, L (1925) *Lancet*, **2**, 793
Bentsáth, A, and Varga, S (1940) *Deutsche med Wchnschr* **66**, 1194
Brachet J (1942) *Ann Soc Roy Zool Belg* **73**, 93
Brookfield, R W (1928) *J Path Bact* **31**, 277
Davidson, L S P, Davis, L J, and Innes, J (1943) *Edin Med J* **50**, 226
Dustin, P (1942) *Le Sang*, **15**, 193
Falconer, E H (1942) *Amer J Med Sci* **203**, 857

Henning, N , and Keilhack, H. (1940) *Deutsche med Wchnschr* 66, 323
Kark, R , and Meiklejohn, A P (1942) *J Clin Invest* 21, 91
Kench, J E , Gillam, A E , and Lane, R E (1942) *Biochem J* 36, 384
Key, J. A (1924) *Amer J. Physiol* 70, 86
Klima, R , and Seyfried, H (1937) *Fol haematol* 57, 283
McFadzean, A J S (1948) *J Path Bact* 60, 332
—— and Davis, L J (1947) *Glasgow Med J* 28, 237
Moritt, E R. (1945) *Amer J Clin Path* 15, 557.
Pappenheimer, A M , Thompson, W P , Parker, D. D , and Smith, K E (1945) *Quart J Med* N S 14, 75.
Rimington, C (1938) *C R Lab Carlsberg, Ser. Chimique*, 22, 454
Thorell, B (1944) *Acta Med Scand* 117, 334
White, J C (1947) *J Path Bact* 59, 223



FIG 3 Sternal marrow film from a human case of lead poisoning, showing stippling in normoblasts and erythrocytes (Leishman)



FIG 4 Bone marrow film from a guinea pig poisoned with lead, showing stippling in normoblasts and erythrocytes (Leishman)

FIG 5 Bone marrow film from a guinea pig poisoned with lead, showing defective haemoglobination in stippled normoblasts and erythrocytes (Leishman)

FIG 6 Sternal marrow film from the same case as Fig 3, stained with potassium ferrocyanide and hydrochloric acid, showing iron positive granules in normoblasts and erythrocytes (carbol fuchsin counterstain)



Fig 7 Peripheral blood film from a guinea pig poisoned with lead showing stippling (Leishman)



Fig 8 Peripheral blood film from guinea pig poisoned with lead showing iron positive granules in a normoblast and erythrocyte (potassium ferrocyanide and hydrochloric acid, counterstained with carbol fuchsin)

Fig 9 Peripheral blood film from a splenectomized guinea pig poisoned with lead showing high incidence of stippled erythrocytes (Leishman)

Fig 10 Peripheral blood film from a splenectomized guinea pig poisoned with lead, showing iron positive granules (potassium ferrocyanide and hydrochloric acid, counterstained with carbol fuchsin)

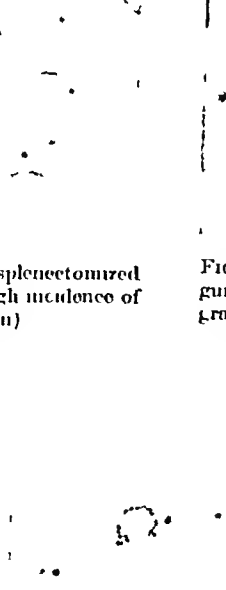

Fig 11 Peripheral blood film from a splenectomized guinea pig poisoned with lead, showing iron positive granules arranged in circular fashion (potassium ferrocyanide and hydrochloric acid, counterstained with carbol fuchsin)

612 492.8 611 132 2 . 615 783.22

REDUCTION IN CORONARY FLOW BY PITUITARY (POSTERIOR LOBE) EXTRACT IN RELATION TO THE ACTION OF NICOTINE AND TO SMOKING[1]

By EDITH BÜLBRING, J H BURN, AND J M WALKER

(From the Department of Pharmacology, Oxford)

EVIDENCE has been published (Burn, Truelove, and Burn, 1945, Walker, 1948) that the inhalation of nicotine in cigarette smoke causes the liberation in the blood of the antidiuretic hormone of the pituitary lobe The hormones of the pituitary posterior lobe have been separated into two fractions by Kamm, Aldrich, Grote, Rowe, and Bugbee (1928), which are known as oxytocin and vasopressin Vasopressin contains both the principle which causes vasoconstriction and also the antidiuretic principle Since no one has succeeded in separating these two principles there is a general belief that they are identical If this view is correct then the nicotine in cigarette smoke will liberate a substance which has not only an antidiuretic effect, but a vasoconstrictor effect as well Even if the antidiuretic hormone is not identical with the vasoconstrictor hormone, it remains possible that nicotine causes the liberation of both hormones from the posterior lobe If vasoconstriction occurred not only in the systemic vessels but in the coronary arteries also, this would affect the heart

We have therefore carried out experiments in dogs to investigate the action of nicotine on the coronary circulation. Though it is generally believed that the direct action of nicotine on the coronary vessels is to dilate them, we were anxious to discover if there might be a more prolonged constriction such as would follow the liberation of the vasoconstrictor hormone from the pituitary body We have also carried out other experiments in the heart-lung preparation to determine the lowest concentration of posterior lobe extract in the blood capable of reducing the coronary blood-flow It was clearly important not only to know if nicotine could cause coronary constriction, but also whether the concentration of the pituitary hormone present in the blood of man as a result of smoking was sufficient to produce a measurable effect on coronary blood-flow.

Methods

Experiments were carried out on dogs anaesthetized with chloralose or Nembutal, and on heart-lung preparations The coronary blood was collected by means of a Morawitz cannula inserted into the coronary sinus, and continuous records of flow were obtained either with Gaddum's (1929) recorder or with recorders recently described by Stephenson (1948) With the latter method

[1] Received August 19, 1948

changes in flow can be seen instantaneously, while with Gaddum's recorder small transient changes may pass unnoticed Stephenson's method can be adapted for a very wide range of flows Thus for the coronary flow a very sensitive recorder was used by which slight changes could be detected On the other hand, a less sensitive recorder was used for the cardiac output in order to produce a record of similar size Fig 1 (*a*) shows an effect produced by the addition of 10 μg of adrenaline to the reservoir in the heart-lung preparation The change in the top tracing represents an increase from 53 to 65 c c per min in the coronary flow The middle tracing shows a transitory increase in cardiac output from 685 to 730 c c per min In the experiments on the whole dog the coronary blood flowed through an outflow recorder into a small reservoir, from this it was taken by a pump to another reservoir placed above the dog so that the blood ran back into the femoral vein This upper reservoir was fitted with an overflow tube leading back to the lower reservoir The height of the upper reservoir had to be carefully adjusted to ensure that the amount of blood outside the body remained as small as possible and constant In order to avoid changes in arterial blood-pressure, which are known to affect coronary flow, a reservoir with blood obtained from another dog was connected to a cannula in one femoral artery, from which the blood-pressure was also recorded The reservoir consisted of a 1-litre bottle filled with blood, the air above the blood was connected with a second 20-litre container filled with air under constant pressure This pressure was fixed at the same height as the dog's arterial blood-pressure (Krayer and Verney, 1936) In the heart-lung preparations the coronary blood flowed through an outflow recorder into a reservoir, from which it was taken by a pump into the main venous reservoir This was fitted with an overflow tube leading back to the lower reservoir so that the level of blood in the main venous reservoir remained constant The blood put out by the heart flowed through the resistance into a second flow-recorder and thence into the main venous reservoir

The Action of Nicotine

Earlier work on the effect of nicotine on the coronary arteries appears at first sight to be contradictory In experiments on whole animals evidence of constriction has been obtained Meyer (1912) observed that the large dose of 10 mg of nicotine diminished the coronary flow in curarized dogs Morawitz and Zahn (1914), using the Morawitz cannula in the cat, concluded that nicotine had a constricting action, because although the injection of 5 mg of nicotine increased the coronary flow, this increase was less than would have been expected from the accompanying rise of blood-pressure On the other hand, Mansfeld and Hecht (1933), using Starling's heart-lung preparation, found that when the lungs were inflated with air containing the smoke of cigars and cigarettes, there was a large increase in coronary flow An infusion of nicotine solution into the blood (amount not stated) had the same effect

We found that the intravenous injection of nicotine into the anaesthetized dog had two effects There was first an increase in coronary flow which was still

seen when the suprarenal glands were excluded from the circulation, and therefore was not due to a liberation of adrenaline After this increase there was

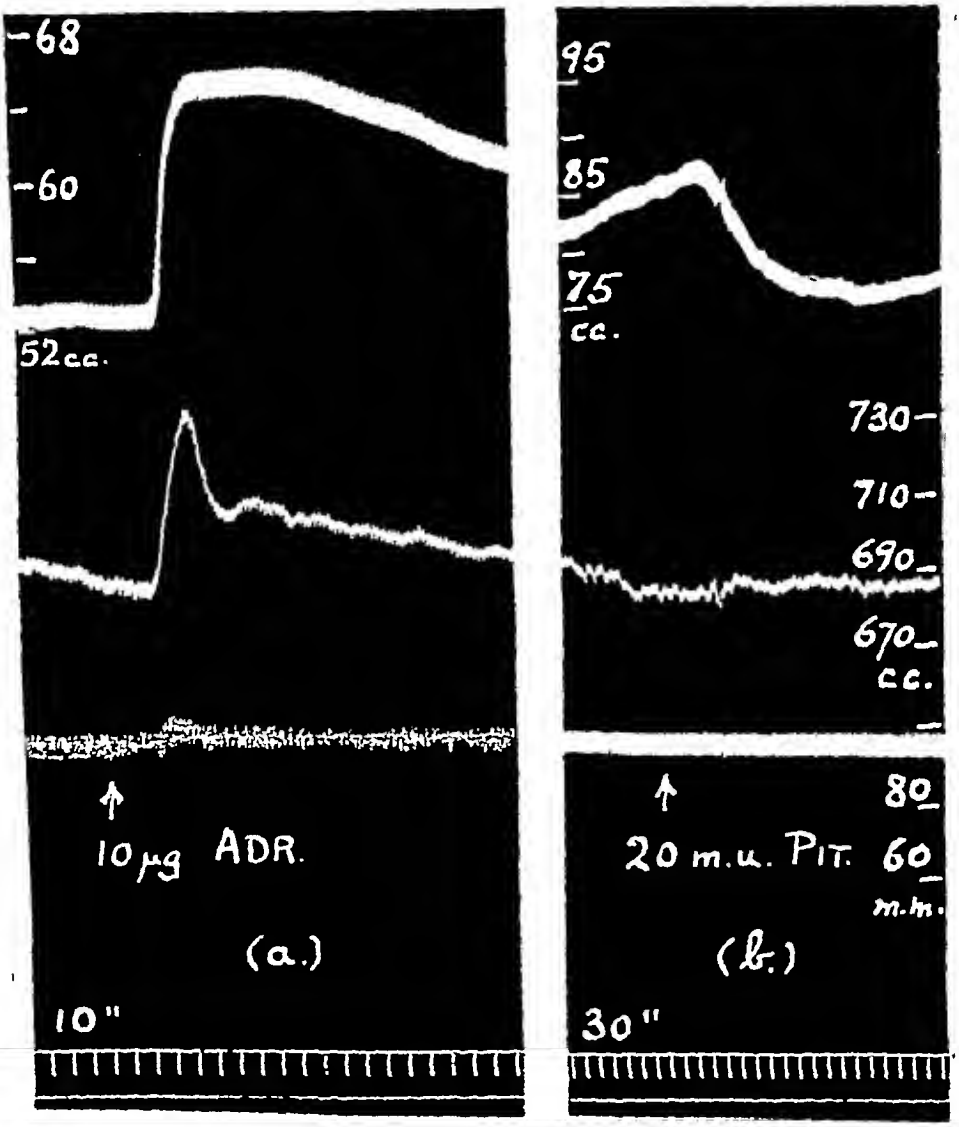

FIG 1 Dog heart lung preparation The records from above downwards show the outflow from the coronary sinus per minute, the cardiac output per minute, and the arterial blood pressure The tracings show the effect on the outflow from the coronary sinus and the cardiac output of (*a*) 10 μg of adrenaline and (*b*) 20 mU of pituitary (*posterior lobe*) extract added to the reservoir Note that the time signal in (*a*) marks 10 sec , but in (*b*) 30 sec The observation in (*b*) was made later in the experiment when the coronary flow was greater, and therefore a less sensitive recorder was used

sometimes a prolonged reduction , for example, the injection of 0 2 mg of nicotine acid tartrate first caused an increase in flow from 69 to 75 c c per min , and this was followed by a reduction to 58 c c per min In an experiment illustrated in

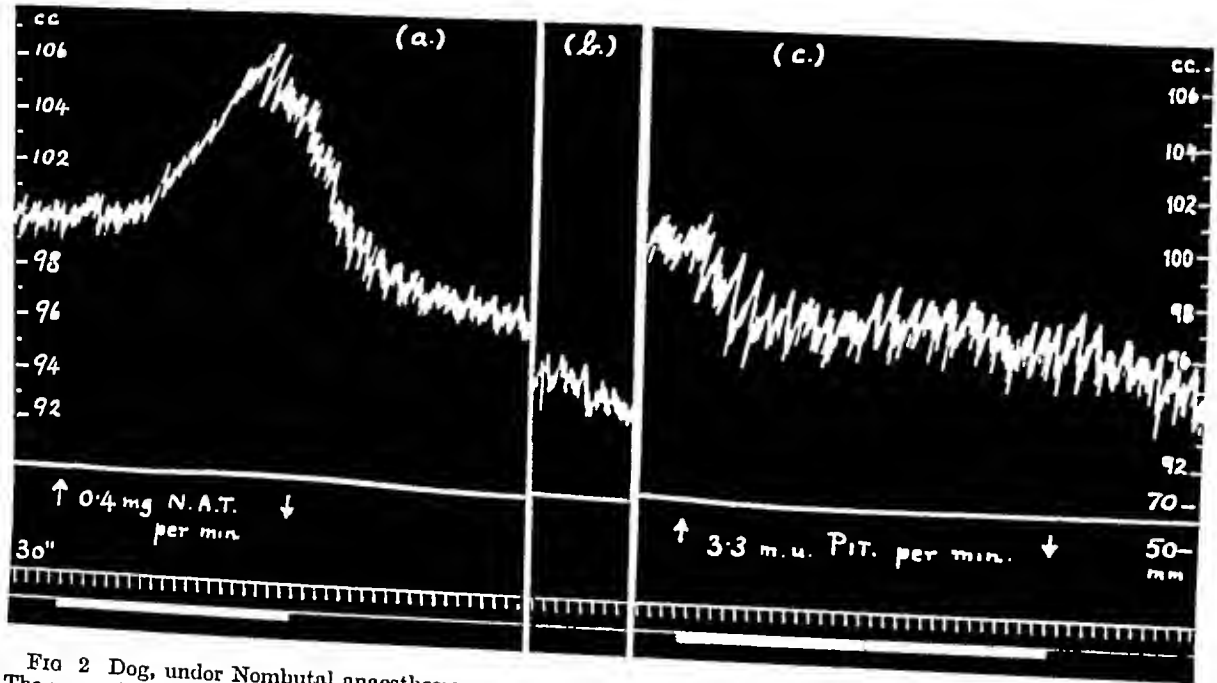

FIG 2 Dog, under Nembutal anaesthesia, eviscerated, with the liver in circulation and the suprarenals tied The upper tracing shows the outflow from the coronary sinus per minute The lower tracing shows the arterial blood pressure (a) Infusion into the reservoir of nicotine acid tartrate (total 4 mg) caused an initial increase followed by a prolonged reduction in coronary flow (b) 20 min later (c) 30 min after (b) Infusion into the reservoir of pituitary (posterior lobe) extract (total 50 mU) caused a similar reaction

Fig. 2 nicotine acid tartrate was not injected in a single dose, but was infused into the venous reservoir during a period of 10 minutes, which is the time taken for the smoking of a cigarette Thus the nicotine was diluted in the blood before it entered the dog The flow first increased from 100 to 107 c c per min , but as soon as the infusion was stopped it fell during the next 20 minutes to 93 c c per min After 30 minutes more the flow returned to 99 c c per min It was then possible to match the diminution of flow by infusing 50 mU of pituitary (posterior lobe) extract into the reservoir during 15 minutes The coronary flow began to fall immediately and the lowest value was 94 c c per min six minutes after the end of the infusion These experiments demonstrated that in the anaesthetized dog, nicotine did in fact cause a reduction in coronary flow in a manner consistent with the view that this reduction was due to a constriction caused by liberation of the pituitary hormone The amount of nicotine necessary to produce this reduction of flow was large The observations made by one of us (J M. W) have shown that in man an amount of nicotine about equal to 1 mg (base), or the smoking of two cigarettes, liberates about 50 mU of posterior lobe hormone Hence in a large dog, about one-fifth of the weight of a man, it would be expected that 0 2 mg of nicotine (base) would liberate a similar concentration of posterior lobe hormone In the experiment shown in Fig 2 the amount of nicotine infused was 10 times this amount, the experiment was, however, made in the anaesthetized animal, and it is probable that the anaesthetic depressed the response of the supraoptic nucleus to nicotine

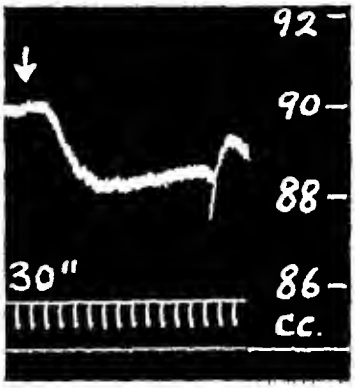

Fig 3 Dog heart-lung preparation The record shows the outflow from the coronary sinus per minute, and the diminution caused by injection of 5 mU of pituitary (posterior lobe) extract The irregularity at the right of the tracing was caused by an extrasystole

The Action of Pituitary (Posterior Lobe) Extract

In five experiments on anaesthetized dogs the threshold dose of pituitary (posterior lobe) extract causing a reduction in coronary flow was found to be 10 to 50 mU For example, in one experiment the intravenous injection of 10 mU caused a reduction of 12 per cent , in another 50 mU reduced the flow by 16 per cent Both effects lasted for about 30 minutes This dose of pituitary extract is of the same order as that causing a similar reduction in the heart-lung preparation (see below)

Heart-lung preparations

Experiments were carried out in 13 heart-lung preparations Continuous records of the coronary flow were obtained in all experiments, in nine experiments the systemic output was recorded continuously in addition The threshold dose

of posterior pituitary extract causing a reduction in coronary flow was found to be 5 mU When this amount was injected into the venous cannula it produced a reduction of 2 to 3 per cent in coronary flow This may be considered an insignificant change, but it lasted for more than five minutes As shown in Fig 3 the effect was immediate, although detectable only with this very sensitive recorder The threshold dose in the majority of the experiments was

TABLE

No	Arterial pressure (mm Hg)	Pituitary extract (dose in mU)	Coronary flow (c c per min) Before	After	Percentage change in coronary flow	Change in minute volume (c.c)
1	115	20	60	50	−17	
	115	100	58	47	−19	
2	110	100	120	116	−3	0
3	100	20	44	33	−25	0
	105	20	50	43	−14	0
	95	20	75	68	−9	−24
	95	40	73	55	−25	−15
4	170	20	93	87	−6	+7
	150	40	129	116	−10	0
5	126	40	118	95	−20	+32
6	160	100	132	123	−7	0
7	100	20	53	47	−11	
	105	20	105	97	−8	
	105	10	135	130	−4	
8	100	10	68	66	−3	−5
	100	20	112	98	−12	
9	125	5	90	88	−2	0
	110	10	90	86	−4	0
10	100	5	64	62	−3	0
		10	80	72	−10	0
11	90	5	140	136	−3	0
	90	25 (R)	140	137	−2	0
	90	50	130	122	−6	0
12	90	20 (R)	90	80	−11	0
	90	20 (R)	88	76	−14	0
13	100	20 (R)	153	132	−14	

(R) indicates that the dose was added to the reservoir instead of into the cannula

20 mU, causing a reduction in coronary flow from 6 to 25 per cent, though in two experiments the smallest effective dose was as much as 100 mU

The Table shows the determination of threshold doses in all experiments When more than one injection was made the doses are listed in the order in which they were given In many experiments larger doses of pituitary extract were also given, but they have been omitted from the table The systemic output was not affected in nine out of 13 experiments In only two experiments did the reduction in coronary flow lead to a diminution of the minute volume In two other experiments the minute volume was actually increased, in each case by an amount similar to the amount of decrease in coronary flow This indicates a shunting of coronary blood into the systemic circulation The reduction in coronary flow could be obtained as readily by injecting the posterior pituitary

extract into the venous reservoir as by injecting it directly into the venous cannula Fig 1 (*b*) shows the change in coronary flow caused by adding 20 mU of pituitary (posterior lobe) extract to the reservoir

Discussion

The observations have been concerned with answering two questions First, does nicotine liberate not only the antidiuretic hormone, but also the hormone which causes vasoconstriction ? When a small dose of nicotine (equivalent per kg of body-weight to the amount absorbed from one or two cigarettes) was injected, or a large dose (a total of 2 mg of base) was infused into anaesthetized dogs, it was found that after a preliminary increase there was a reduction in coronary flow This reduction was similar in rate of onset, magnitude, and duration to that produced by infusion of posterior lobe extract

The second question was whether the amount of posterior lobe hormone known to be liberated by cigarette-smoking is sufficient to cause a reduction of coronary flow This point was investigated in the dog heart-lung preparation in which no anaesthetic was present which might obscure the result In man, with a blood volume of 5 litres, the smoking of one or two cigarettes liberates amounts of posterior lobe hormone of the order of 50 mU , this is a concentration of 10 mU per litre In the dog heart-lung preparations with a circulation of 1 litre of blood, it was found that the addition to the reservoir of 5 to 50 mU caused a reduction in coronary flow of 5 to 25 per cent , which lasted in some experiments as long as 30 minutes

These results are thus consistent with the view that smoking, through the action of the inhaled nicotine on the supra-optic nucleus, liberates sufficient posterior lobe hormone to reduce the coronary blood-flow, and suggest that this reduction is likely to be considerable in sensitive individuals who smoke with regularity

Summary

1 In the anaesthetized dog nicotine produces not only an initial increase in coronary flow due to its own direct action, but also a succeeding prolonged reduction This reduction in coronary flow is similar in rate of onset and duration to that produced by posterior lobe extract

2 In the heart-lung preparation of the dog (when the amount of blood in the circulation was about 1 litre), as well as in the whole animal, the threshold dose of pituitary (posterior lobe) extract causing a reduction in coronary flow was found to be 5 to 20 mU This is equivalent to 25 to 100 mU for a man with 5 litres of blood and is of the same order as the amount of posterior lobe hormone liberated in man by smoking one to two cigarettes

We are very grateful to Mr H W Ling for his valuable technical assistance One of us (J M W) was maintained by a personal grant from the Medical Research Council

REFERENCES

Burn, J H, Truelove, L H, and Burn, I (1945) *Brit M J* **1**, 403
Gaddum, J H (1929) *J Physiol* **67**, 16P.
Kamm, O, Aldrich, T B, Grote, I W, Rowe, L W, and Bugbee, E P (1928) *J Am Chem Soc* **50**, 573
Krayer, O, and Verney, E B (1936) *Arch f exper Path u Pharmakol* **180**, 76
Mansfeld, G, and Hecht, K (1933) *Ibid* **172**, 362
Meyer, F (1912) *Arch Anat Physiol* 223
Morawitz, P, and Zahn, A (1914) *Deutsch Arch f klin Med* **116**, 364
Stephenson, R P (1948) *J Physiol* **107**, 102
Walker, J M (1948) *Quart J Med* N S **18**, 51

616 125 2–007 63

MASSIVE DILATATION OF THE LEFT AURICLE[1]

By RAYMOND DALEY and RAYMOND FRANKS
(From the Cardiac Department, St Thomas's Hospital, London)

With Plates 9 to 14

Introduction

PROBABLY the first description of massive dilatation of the left auricle in association with mitral valvular disease was by Owen and Fenton in 1901 Since that time the condition has become relatively familiar, although only some 30 case reports have appeared in the literature Many of these reports refer to 'aneurysmal' dilatation, but as the enlargement is in no sense localized, being merely an exaggeration of the usual symmetrical left auricular dilatation so common in mitral valvular disease, the term 'massive' is preferred here. It should be added that although the main body of the auricle is symmetrically dilated, it is unusual for the left auricular appendage to be much increased in size and to share in the general enlargement There have been very few reports of localized aneurysms of the auricular wall and these have been associated with auricular infarction, specific arteritis, or adjacent pulmonary tuberculous abscess, and are not discussed in the present paper Our main purpose is to describe some of the clinical phenomena which accompany massive left auricular dilatation, and in particular to analyse those which result from pressure on surrounding structures. The present study is based on 15 patients who have attended the Cardiac Department at St Thomas's Hospital during the past five years

General Clinical Features

The diagnosis of massive left auricular dilatation is essentially radiological, but there are a number of features which, when assessed together, should suggest a correct clinical diagnosis There is usually a history of multiple attacks of rheumatic fever or of one severe and prolonged attack This was obtained in 11 of our patients, and two of the remainder had had chorea in childhood After the rheumatic infection, activity had been little restricted by dyspnoea, and the ability of these patients to carry out a full day's work was often remarkable Parkinson (1936), when discussing massive left auricular dilatation, made the following pertinent observations—'It possesses clinical features of great interest, such as the moderate symptoms which may accompany a heart so hugely dilated, a clinical contrast with the patient so ill with a comparable ventricular enlargement, as from hypertension ' These facts are in keeping with

[1] Received July 24, 1948

the common lack of pulmonary hypertension. If pulmonary hypertension does supervene, the clinical state differs little from that found in the more usual types of mitral valvular disease, and progressive dyspnoea is then the rule There is a great contrast between the bed-ridden patient with pulmonary hypertension and little left auricular enlargement, and the active patient with small pulmonary arterial trunks and massive left auricular dilatation.

In the present series of patients with massive left auricular dilatation, the extremities were cold and the peripheral arterial pulsation poor The malar flush of mitral stenosis was usually absent Auricular fibrillation is almost universal in the recorded cases and was present in all our adult patients Two patients (Cases 7 and 12), however, reverted spontaneously to normal rhythm for short periods Case 11, a boy of 11 years, was the only patient who, as far as is known, had never shown fibrillation The jugular venous pressure, often stated to be little raised, was elevated in six patients, and almost to the angle of the jaw in three Venous pulsation was of normal amplitude, a point of importance in the clinical differentiation between a massive left auricle and a pericardial effusion Other manifestations of cardiac failure, such as hepatic enlargement, dependent oedema, hydrothorax, and ascites, were late in appearance Visible pulsation was present in all cases to the left of the sternum and in five also to the right Right-sided pulsation was felt in the second to the fourth intercostal spaces and from one and a half to two inches from the right sternal edge Dullness to the right of the sternum, although frequently found, did not extend more than one and a half to two inches from the right sternal border Dullness anteriorly extending as far as the right axilla has not often been recorded, and its rarity is due to the fact that the enlarging left auricle lies posteriorly It does not come into close contact with the right anterior chest-wall until it becomes enormous An impaired percussion note was almost always present at the right lung base posteriorly and sometimes extended to the right axilla Rarely, an impaired note was detected to the left of the spine, but it never extended more than two inches lateral to the ninth, tenth, and eleventh thoracic spines All patients had early mitral systolic as well as diastolic murmurs The systolic murmurs were loud and harsh In only one patient was there an apical systolic thrill The diastolic murmurs were localized to a small area in the region of the apex beat The systolic murmurs were heard not only in the left axilla and left scapular area, but also to the right of the sternum In most cases the heart-sounds were easily audible well to the right of the sternum, and in some even out as far as the right axilla, a point noted several times in the previously recorded cases

Special Clinical Features

Dysphagia Dysphagia is not a common symptom of cardiovascular disease, but its occasional occurrence in association with massive dilatation of the left auricle is indicated by the papers of Shaw (1924), Rösler and Weiss (1925), Bedford (1927), Nichols and Ostrum (1932), Bishop and Babey (1936), and Parsonnet, Bernstein, and Martland (1946) The dysphagia is probably due to

angulation and flattening of the oesophagus over the dilated left auricle Five of our patients complained of difficulty in swallowing solid food and two of these also complained of difficulty in swallowing liquids One had painful dysphagia, but only after swallowing a large bolus, a small bolus merely causing a mild choking sensation A surprising feature in two patients was their inability to localize the site of the obstruction One pointed to the suprasternal notch and the other to the xiphisternum, whereas in all, fluoroscopy after a barium swallow showed the obstruction to be a few centimetres below the tracheal bifurcation (Plate 9, Fig 1)

Hoarseness Schwedel (1946) described a male patient aged 35 years in whom massive left auricular dilatation was associated with hoarseness and a partial left recurrent laryngeal nerve palsy One of our patients (Case 12), a woman aged 58 years, suffered from intermittent hoarseness for three years, and during one of the attacks a complete left recurrent laryngeal nerve palsy was seen by laryngoscopy Anatomical considerations make it doubtful whether a massive left auricle ever exerts direct pressure on the left recurrent laryngeal nerve On the rare occasions when dilatation spreads to the appendage, direct pressure is a possible cause of palsy More likely the palsy is due to pressure either from the pulmonary artery or veins This pressure by the pulmonary artery may be due to its dilatation or to its upward displacement by an enlarged right ventricle In our patient there was considerable right ventricular enlargement

Erosion of the spine Erosion of the spine by an enlarged left auricle must be a great rarity and only one record has been found in the literature Ashworth and Jones (1946) described the case of a woman aged 38 years who complained of intractable pain in the vicinity of the right scapula and axilla Radiographs in the postero-anterior and right anterior oblique positions failed to show any erosion, but at autopsy the bodies of the fifth to the ninth thoracic vertebrae were found to be eroded by pressure from a massive left auricle The seventh thoracic vertebra was the most affected, and all the intervertebral disks were spared Erosion was present only on the right anterior aspect of the spine and the authors made the suggestion that radiographs in the left anterior oblique position might have demonstrated the abnormality in life This procedure was carried out in our 15 patients and in one (Case 8) erosion of the seventh, eighth, and ninth thoracic vertebrae was seen in the left anterior oblique view, but not in any other view (Plates 9 and 10, Figs 2 and 3). It is interesting that this patient had no pain

Pain Chest pain in patients with massive left auricular dilatation has been reported by many authors and some of its unusual features discussed by a few (Owen and Fenton, 1901, East, 1926, Bedford, 1927, Cassidy, 1930, Steel, 1931, Nichols and Ostrum, 1932, Bishop and Babey, 1936, Parsonnet, Bernstein, and Martland, 1946, Ashworth and Jones, 1946) In the present series of 15 patients, 10 complained of chest pain Because three (Cases 2, 7, and 14) also had aortic valvular disease they are excluded from this discussion The type of pain in the remaining seven showed considerable variation from patient to patient and some variation in the individual In general, it was situated deeply

Summary of

Case	*Sex*	*Age (years)*	*History of rheumatic fever*	*Number of pregnancies*	*Age at first onset of cardiac failure (years)*
1	Female	49	As a child	9	33
2	Female	52	At 25 years	2	52
3	Female	46	At 20 and 21 years	3	37
4	Female	62	At 29, 41, and 44 years	1	55
5	Female	35	As a child	None	28
6	Female	62	At 16 years	2	55
7	Female	28	At 19 years	1	24
8	Female	57	Chorea as a child	1	42
9	Female	Died at 36	None	2	28
10	Female	27	As a child	None	23
11	Male	11	Chorea at 7 years		•
12	Female	Died at 61	None	2	59
13	Female	36	As a child and at 32 years	1	36
14	Male	Died at 38	Two attacks of chorea and one of rheumatism as a child		34
15	Female	Died at 44	At 7, 14, and 34 years	1	43

in the right side of the chest and radiated to the right scapula and shoulder, with occasional radiation to the left side of the chest and left arm At its height it was described as aching in quality, but when of milder degree was felt as a sensation of fullness or oppression In a few instances the pain was phasic, several months' pain being followed by months of freedom, but in the majority it was present almost constantly There was a variety of aggravating factors, the most frequent being exertion There was no possibility of confusion with angina pectoris because, although in the individual patient a similar amount of exercise always caused pain, rest did not bring relief for at least 15 minutes In one patient (Case 9), standing for 10 minutes precipitated a severe attack of pain, and complete relief was not obtained until she had lain down for 10 minutes Another patient (Case 15) frequently developed pain when lying or sitting back She found that sitting forward gave relief In Case 3 attacks of coughing, as well as exertion, produced pain. In two patients (Cases 1 and 6) pain bore no relationship to exertion, but came on for no accountable reason,

Case Histories

Case	Valvular defect (clinical diagnosis)	Rhythm	Special features
1	Mitral stenosis Mitral incompetence	Auricular fibrillation	Pain in right chest, collapse of right middle lobe
2	Mitral stenosis Mitral incompetence Aortic stenosis	Auricular fibrillation	Angina pectoris
3	Mitral stenosis Mitral incompetence	Auricular fibrillation	Pain in right chest, dysphagia
4	Mitral stenosis Mitral incompetence Aortic incompetence	Auricular fibrillation	Dysphagia
5	Mitral stenosis Mitral incompetence	Auricular fibrillation	Pain in right chest
6	Mitral stenosis Mitral incompetence	Auricular fibrillation	Dysphagia, pain in right chest, blood-pressure 235/130
7	Mitral stenosis Mitral incompetence Aortic incompetence	Auricular fibrillation	Dysphagia, angina pectoris, reverted to normal rhythm for 1 year
8	Mitral stenosis Mitral incompetence	Auricular fibrillation	Erosion of thoracic vertebrae
9	Mitral stenosis Mitral incompetence	Auricular fibrillation	Pain in right chest, narrowing of left main bronchus
10	Mitral stenosis Mitral incompetence Later tricuspid incompetence	Auricular fibrillation	Pain felt deeply in chest, repeated pulmonary emboli, 'cardiac' jaundice
11	Mitral stenosis Mitral incompetence Aortic incompetence	Regular	Elevated left nipple without scoliosis.
12	Mitral stenosis Mitral incompetence	Auricular fibrillation	Reverted to normal rhythm for a few weeks, left recurrent laryngeal nerve palsy
13	Mitral stenosis Mitral incompetence Aortic incompetence	Auricular fibrillation	
14	Mitral stenosis Mitral incompetence Aortic incompetence	Auricular fibrillation	Pain in right chest *
15	Mitral stenosis Mitral incompetence	Auricular fibrillation	Pain felt deeply in chest and down left arm to elbow, relieved by sitting forward; dysphagia

* At the post-mortem examination, the heart weighed 909 gm and there was a small pericardial effusion The mitral valve was fibrotic and calcified, and was clearly stenotic and incompetent The other valves were normal The pericardium was adherent round the orifice of the great veins and the left auricle had a capacity of 700 c c For the following histological report we are grateful to Dr J Bamforth—'There is thickening of the pericardium with the formation of a definite layer of fibrous tissue The muscle fibres, which are cut transversely, appear smaller than normal and in some the nuclei are pyknotic Little of the outer elastic layer remains The inner elastic layer is swollen and hyaline in appearance The connective tissue on the inner aspect of the auricle is looser than normally occurs and contains some small blood-vessels These changes may be due to pressure atrophy'

and sometimes lasted for hours These unusual types of pain occurred sufficiently often to suggest the presence of a massive left auricle in patients known to be suffering from mitral valvular disease

The cause of the pain remains obscure, but a number of possibilities may be considered Spinal erosion by a massive left auricle is always a possible cause of chest pain, but our one patient with demonstrable erosion was free from pain Erosion is so rare that, while existing as a possible cause, it is most improbable

that it ever plays any substantial part in pain production It is inconceivable that active pericarditis could be a cause of pain which often persists for many years Rheumatic arteritis might be postulated, although it is usually limited to the acute stage of rheumatic carditis In autopsies of patients dying with massive dilatation of the left auricle, where there has been careful histological study (Bramwell and Duguid, 1928, Bishop and Baboy, 1936), the sectioned coronary vessels have been reported as normal The only exception to this is in a case of Semans and Taussig (1938) in which there was found to be a congenital anomaly of the left circumflex coronary artery Although the coronary arteries may be anatomically normal, stretching of the left auricular wall probably leads to considerable narrowing Furthermore, any temporary additional auricular dilatation, such as might occur during exercise, could increase this mechanical factor. The resulting disproportion between available blood supply and the metabolic demands of the residual auricular muscle may give rise to ischaemic pain

It is almost impossible to provide proof of such a mechanism, but tests carried out in one patient (Case 3) indicate the part played by ischaemia in this particular instance This patient was free from aortic disease, hypertension, and peripheral arteriosclerosis Her pain was situated deep in the right side of the chest and when severe spread to the right shoulder and anterior surface of the right arm as far as the tips of all fingers, but sparing the thumb It regularly stopped her after walking 100 yards on the level and was relieved by about 15 minutes' rest It had on occasion occurred when she had slipped down in bed in her sleep, but otherwise had never come on at rest When she was given tablets of glyceryl trinitrate to chew at the onset of the pain, not only was it rapidly relieved, but she was also able to walk a further 300 or 400 yards before it recurred Control tablets, free from vasodilators, had no such effect She now chews four or five tablets of glyceryl trinitrate (gr 1/100) a day and is able to do her shopping and visit friends, activities previously denied to her In order to demonstrate more effectively the relationship of ischaemia to the production of pain she was asked to breathe a mixture containing 10 per cent of oxygen and 90 per cent of nitrogen After six minutes typical pain developed Pure oxygen was then directed into the circuit without her knowledge and the pain subsided in one minute This experiment was twice repeated with identical results Electrocardiograms taken before the pain developed and when it was at its height showed no change This suggests that ventricular ischaemia is not playing a predominant part in pain production The presence of auricular fibrillation precluded the demonstration of any changes in the auricular T wave

Fluoroscopic Appearances

Angiocardiographic studies indicate that, with the possible exception of the auricular appendage, the left auricle does not form part of the left cardiac border in the postero-anterior view Enlargement initially takes place in a posterior direction and the auricle is sometimes seen as a dense circular shadow

lying within the cardiac shadow in the postero-anterior view. This posterior enlargement is, of course, best seen in the right anterior oblique view and to some extent in the left Further enlargement takes place towards the right and is responsible for the so-called 'double contour' in the postero-anterior view This is due to the superimposition of the left and right auricular shadows at the right border of the heart At a later stage the right border is entirely formed by the left auricle An enlarging right ventricle causes counter-clockwise rotation of the heart, as seen from above, and as a result increases the prominence of the left auricular shadow In greater degrees of dilatation, upward enlargement occurs and is responsible for the upward displacement of the main bronchi Finally, only when grossly enlarged does the left auricle encroach on the left cardiac border A massive left auricle never reaches the left axilla, whereas it is occasionally in contact with the right

Usually, left auricular enlargement displaces the barium-filled oesophagus posteriorly, the displacement being well seen in both oblique views With mild degrees of enlargement, fluoroscopy in the postero-anterior view shows the oesophagus in the middle part of its course to be vertical or to have a normal slight deviation to the right Increasing enlargement of the left auricle accentuates the backward oesophageal displacement seen in the oblique views, and at the same time deviation to the right in the postero-anterior view becomes more marked The latter exaggeration of the normal right-sided deviation may be assisted by enlargement of the right ventricle causing counter-clockwise rotation of the heart Rarely, the oesophagus is deviated to the left rather than to the right (Rösler and Weiss, 1925, Schwedel, 1946) It is apparent that if this is so the oesophagus cannot be a guide to left auricular size in the oblique views, since the auricle enlarges posteriorly and to the right Three of our patients (Cases 3, 4, and 6) had displacement of the oesophagus to the left Two of them had mitral valvular disease only, and the third mitral and aortic disease. As age advances 'uncoiling' of the aorta due to atherosclerosis is common, and it is probable that the adhesions normally present between the oesophagus and aorta are strong enough to drag the oesophagus to follow the course of the aorta It was noteworthy that in these three cases the oesophagus followed a descending aorta which was displaced to the left (Plate 10, Fig 4)

Enlargement of the right ventricle was found in all cases and was best seen in the left anterior oblique view Fluoroscopy in this position revealed that in all patients there was also some enlargement of the left ventricle This was to be expected in those who had aortic as well as mitral valvular disease, but in those without aortic disease it was almost certainly the result of mitral incompetence Paradoxical filling of the left auricle during ventricular systole was not seen and it was our experience that the size of the auricle was in inverse proportion to its degree of pulsation Really massive left auricles were virtually still throughout the cardiac cycle, and paradoxical filling was seen only in relatively small auricles

Pressure effects on the bronchi In 1838 King described the post-mortem appearances of flattening of the left main bronchus in a patient dying from mitral

stenosis In 1889 Taylor described a similar appearance in a boy aged 16 years, and in this instance the antero-posterior compression was of sufficient degree to lead to collapse of the left lower lobe Other examples of similar post-mortem findings occur in the early literature, but bronchial distortion and compression were not accurately diagnosed in life until Gäbert in 1924, using high-penetration X-rays, demonstrated marked widening of the carinal angle in some cases of mitral stenosis. He was the first to stress that this widening was largely due to elevation of the left main bronchus, a point generally but not necessarily always true, because when left auricular dilatation becomes really massive the right main bronchus may also be raised, and the two bronchi come to lie in almost a straight line, as in Cassidy's (1930) case In 1928 Steele and Paterson, using six-foot postero-anterior radiographs, attempted to make actual measurements of the angle between the main bronchi (the bronchial angle) They found that in normal subjects the angle varied from 40° to 70°, or even more Schwedel (1916) also measured the bronchial angle in the left anterior oblique view with subjects turned 45° to the X-ray screen and concluded that the maximal angle for vertical hearts was 22°, and for horizontal hearts 45° He stated that an enlarging left auricle frequently causes elevation (Plate 11, Fig 5) and sometimes posterior displacement (Plate 11, Fig 6) of the left main bronchus, but actual bronchial compression he believed to be a rarity except in childhood Massive left auricles, therefore, rarely give rise to lobar collapse, but bronchiectatic changes distal to partially occluded bronchi are common, and occasionally small areas of segmental collapse develop as a result of auricular pressure on terminal bronchi

Following on the work of Steele (1928) lipiodol bronchograms were carried out on 12 of our patients In all there was marked widening of the bronchial angle, the greatest recorded being 120° in both postero-anterior and left anterior oblique views Elevation of the left main bronchus occurred either at its point of origin or within three centimetres of the carina Elevation of the right main bronchus was seen in patients with very large auricles, but this bronchus did not angulate so acutely as the left, and described a more gentle curve extending almost to the origin of the right upper lobe bronchus (Plate 12, Fig 7) In only one patient (Case 9) was actual compression of the left main bronchus easily demonstrable in the postero-anterior view (Plate 12, Fig 8), but it was not of sufficient degree to cause pulmonary collapse Compression of the right middle-lobe bronchus in another patient (Case 1) provided one of the most unusual radiographic appearances of the series In the postero-anterior view a large oval shadow was seen lying horizontally in the chest, the right extremity running out to a sharp point (Plate 13, Fig 9) Further examination in the lordotic position translated this point into the apex of a collapsed middle lobe extending laterally from the right border of a massive left auricle (Plate 13, Fig 10) Bronchograms confirmed the obstruction of the right middle-lobe bronchus almost at its point of origin, and showed upward and backward displacement of the right main bronchus (Plate 14, Figs 11 and 12) In order to shed further light on the mechanism of the obstruction, bronchoscopy was carried out by

Mr W A Mill, who reported—'The carina was very broad and pulsated strongly, this was transmitted pulsation The right main bronchus passed sharply to the right and downwards and it was difficult to get a clear view down it The right upper lobe bronchus was normal The right middle lobe bronchus was blocked by the apposition of its walls because of a swelling to its left, this swelling was continuous with that seen in the broadened carina Frothy mucus, without movement, was lying in the middle lobe bronchus The walls of the bronchi were not infiltrated and moved on respiration.' It is probable that the bronchus was displaced so far backwards and to the right by the left auricle that the resulting flattening and angulation were sufficient to lead to its obstruction

In common with many cases previously described, the majority of our cases had abnormal physical signs at the right lung base Breath sounds were diminished or absent and the percussion note frequently impaired In Case 3, so closely did the physical signs mimic those of pleural effusion that an enthusiastic diagnostician attempted aspiration, unlike a similar incident described by Owen and Fenton (1901), the attempt was unsuccessful, and on the following day fluoroscopy revealed a massive left auricle In summary, massive left auricular dilatation may cause complete or incomplete bronchial obstruction, leading to either complete or partial lobar collapse or bronchiectatic change The auricle itself may so approximate to the chest-wall that the resultant physical signs are confused with pleural or pulmonary disease

Aetiology

Massive dilatation of the left auricle is more common in female than in male patients, a distribution conforming to that of mitral valvular disease In our small group of 15 cases there were only three male patients The time-interval from the original infection to the full development of a massive left auricle varies enormously The longest interval cannot be assessed from the present series, but some indication of the shortest interval can be derived from Case 11, a boy of 11 years, who had his first attack of chorea aged 7 years, and in three years developed a very large left auricle The exact mechanism of production of massive left auricular dilatation is unknown and only speculation is possible As has been stressed, a history of severe or recurrent attacks of acute rheumatism is very common It is believed that the nature of the residual lesion or lesions is to some extent conditioned by the site of the main brunt of the infection in the heart Since the rheumatic process affects the entire heart-wall it is probable that the chambers where the overlying pericardium is adherent were involved in the original infection, and in all recorded autopsies the pericardium has been either universally or partially adherent over the left auricle Also myocardial fibrosis is always very marked in the left auricular wall, disappearance of the muscle being almost complete We believe that this destruction of the normal tissue of the left auricular wall is the primary cause of weakness and consequent loss of elasticity In all our cases, and in every recorded case studied, loud mitral systolic murmurs have been present In the majority of the recorded autopsies,

and in our patient who was examined *post mortem* (Case 14), mitral stenosis and incompetence were demonstrated, but in a minority there was mitral incompetence only. The left auricular pressure is always raised in mitral stenosis and the addition of mitral incompetence is likely to raise this pressure even farther The burden thrown on the left auricular wall is therefore considerable, and the sudden increase in intra-auricular pressure occurring during each ventricular systole is probably the main cause of gross dilatation With this distension it is possible that relative ischaemia of the residual muscle fibres, a theory which was postulated in the discussion on the causation of pain, may play a secondary role by causing further destruction of muscle and replacement by fibrous tissue

Summary

1. Fifteen cases of massive left auricular dilatation associated with mitral valvular disease are described

2 The condition is characterized clinically by the late onset of exertional dyspnoea and peripheral oedema, the almost invariable presence of auricular fibrillation, and the frequent finding of pulsation and impaired percussion note to the right of the sternum Impairment of percussion note and diminished breath-sounds posteriorly, extending from the dorsal spine to the right axilla, have caused diagnostic confusion with pleural effusion Clinical mitral incompetence as well as stenosis was present in all our patients and often the heart-sounds were heard in the right axilla

3 Dysphagia was present in five patients and is believed to be due to angulation and flattening of the oesophagus by the dilated left auricle Hoarseness occurring in one patient was shown to be the result of a left recurrent laryngeal nerve palsy, but pressure from upwardly displaced pulmonary vessels, rather than direct pressure from a massive left auricle, was probably the cause Erosion of the spine from a massive left auricle was demonstrated in a left anterior oblique radiograph in one patient Pain of an aching character, deeply situated in the chest and often precipitated by exercise, was a complaint of seven patients, who had no complicating aortic valvular disease Evidence has been provided that this pain, at least in one patient, was due to left auricular ischaemia

4 A massive left auricle usually displaces the oesophagus to the right and posteriorly, but in three patients the oesophagus closely followed the course of the descending aorta and deviated to the left In the latter circumstances the deviation of the oesophagus does not serve as a guide to the size of the left auricle

5 Bronchography has been employed to demonstrate upward and posterior displacement mainly of the left but also of the right main bronchus by a massive left auricle Compression of the left main bronchus was present in one patient In another, the right middle lobe bronchus was so distorted by a massive left auricle that it became occluded, with consequent middle-lobe collapse

6 The aetiology is obscure, but there is evidence that the main brunt of the initial rheumatic infection is borne by the auricle The presence of mitral

valvular disease, especially incompetence, leads to increased pressure in the left auricle and consequent stretching of an already fibrotic auricular wall

Our thanks are due to Dr Evan Jones for valuable advice, and to Drs J. W McLaren, J O Y Cole, and H A R Hamilton of the X-ray Department of St Thomas's Hospital

REFERENCES

Ashworth, H , and Jones, A M (1946) *Brit Heart Journ* **8**, 207
Bedford, D E (1927) *Amer Heart Journ* **3**, 127
Bishop, L F , and Babey, A (1936) *Journ Amer Med Assoc* **106**, 462
Bramwell, J C , and Duguid, J B (1928) *Quart Journ Med* **21**, 187
Cassidy, M A. (1930) *Proc Roy Soc Med* **23**, 955, 1275
East, C F T (1926) *Lancet*, **1**, 1194
Gübert, E (1924) *Fortschr a d Geb d Röntgenstrahlen*, **32**, 410
King, T W (1838) *Guy's Hosp Rep* **3**, 175
Nichols, C F , and Ostrum, H W (1932) *Amer Heart Journ* **8**, 205
Owen, I , and Fenton, W J (1901) *Clin Soc Trans* **34**, 183
Parkinson, J (1936) *Lancet*, **1**, 1391
Parsonnet, A E , Bernstein, A , and Martland, H S (1946) *Amer Heart Journ* **31**, 438
Rösler, H , and Weiss, K (1925) *Fortschr a d Geb d Röntgenstrahlen*, **33**, 717
Schwedel, J B (1946) *Clinical Röntgenology of the Heart*, New York
Semans, J H , and Taussig, H B (1938) *Bull Johns Hopkins Hosp* **63**, 404
Shaw, H. B (1924) *Lancet*, **2**, 493
Steel, D (1931) *Amer Journ Röntgenol* **26**, 66
Steele, J M (1928) *Amer Heart Journ* **4**, 53
—— and Paterson, R (1928) *Ibid* **4**, 692
Taylor, H H (1889) *Trans Path Soc Lond* **40**, 58

and in our patient who was examined *post mortem* (Case 14), mitral stenosis and incompetence were demonstrated, but in a minority there was mitral incompetence only. The left auricular pressure is always raised in mitral stenosis and the addition of mitral incompetence is likely to raise this pressure even farther The burden thrown on the left auricular wall is therefore considerable, and the sudden increase in intra-auricular pressure occurring during each ventricular systole is probably the main cause of gross dilatation With this distension it is possible that relative ischaemia of the residual muscle fibres, a theory which was postulated in the discussion on the causation of pain, may play a secondary role by causing further destruction of muscle and replacement by fibrous tissue.

Summary

1. Fifteen cases of massive left auricular dilatation associated with mitral valvular disease are described

2 The condition is characterized clinically by the late onset of exertional dyspnoea and peripheral oedema, the almost invariable presence of auricular fibrillation, and the frequent finding of pulsation and impaired percussion note to the right of the sternum Impairment of percussion note and diminished breath-sounds posteriorly, extending from the dorsal spine to the right axilla, have caused diagnostic confusion with pleural effusion Clinical mitral incompetence as well as stenosis was present in all our patients and often the heart-sounds were heard in the right axilla

3 Dysphagia was present in five patients and is believed to be due to angulation and flattening of the oesophagus by the dilated left auricle Hoarseness occurring in one patient was shown to be the result of a left recurrent laryngeal nerve palsy, but pressure from upwardly displaced pulmonary vessels, rather than direct pressure from a massive left auricle, was probably the cause Erosion of the spine from a massive left auricle was demonstrated in a left anterior oblique radiograph in one patient Pain of an aching character, deeply situated in the chest and often precipitated by exercise, was a complaint of seven patients, who had no complicating aortic valvular disease Evidence has been provided that this pain, at least in one patient, was due to left auricular ischaemia

4 A massive left auricle usually displaces the oesophagus to the right and posteriorly, but in three patients the oesophagus closely followed the course of the descending aorta and deviated to the left In the latter circumstances the deviation of the oesophagus does not serve as a guide to the size of the left auricle

5 Bronchography has been employed to demonstrate upward and posterior displacement mainly of the left but also of the right main bronchus by a massive left auricle Compression of the left main bronchus was present in one patient In another, the right middle lobe bronchus was so distorted by a massive left auricle that it became occluded, with consequent middle-lobe collapse

6 The aetiology is obscure, but there is evidence that the main brunt of the initial rheumatic infection is borne by the auricle The presence of mitral

FIG 1 Case 7 Left anterior oblique radiograph showing that barium paste swallowed half an hour before the exposure still remains in the oesophagus, which is flattened by the enlarged left auricle The left main bronchus, outlined by lipiodol, is displaced upwards by the left auricle

FIG 2 Case 8 Right anterior oblique radiograph showing that the barium filled oesophagus is displaced posteriorly by the enlarged left auricle No erosion of vertebrae is seen in this view

FIG 6 Case 1 Right lateral bronchogram showing posterior displacement of the bronchial tree by the massive left auricle

FIG 7 Case 1 Left anterior oblique radiograph showing indentation of the barium filled oesophagus by the left main bronchus This bronchus is displaced upwards by the massive left auricle

FIG 3 Case 8 High penetration left anterior oblique radiograph for comparison with Fig 2 There is erosion of the bodies of the seventh, eighth and ninth thoracic vertebrae The firm rounded line is breast shadow Low penetration films showed that the heart shadow extended much farther downwards and backwards than appears from this radiograph

FIG 4 Case 6 High penetration postero anterior radiograph showing an enlarged left auricle and displacement of the barium filled oesophagus to the left The oesophagus appears to follow the course of the descending aorta

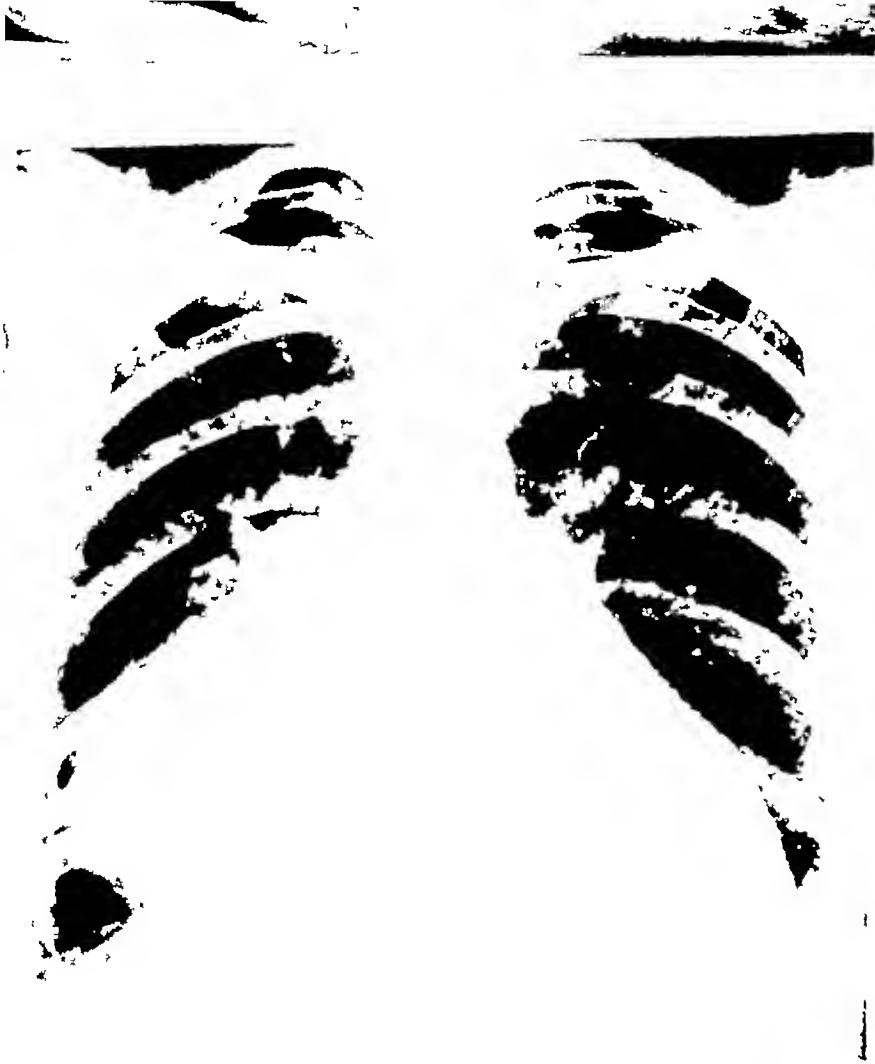

FIG 9 Case I Postero anterior radiograph showing a massive left auricle, an enlarged left ventricle, and depression of the right lesser fissure

FIG 10 Case I High penetration postero anterior bronchogram taken in the lordotic position and showing obstruction of the right middle lobe bronchus by the massive left auricle The dense triangular shadow represents the collapsed right middle lobe

FIG 7 Case 2 Postero anterior bronchogram showing splaying of the main bronchi due to an enlarged left auricle The bronchial angle is 120°

FIG 8 Case 9 Postero anterior bronchogram showing compression of the left main bronchus due to an enlarged left auricle

616 833–006 383 616 833 12

PRIMARY OPTIC ATROPHY IN VON RECKLINGHAUSEN'S DISEASE (MULTIPLE NEUROFIBROMATOSIS)[1]

By E DRESNER and D A D MONTGOMERY

(From the Department of Medicine, Postgraduate Medical School of London)

With Plates 15 and 16

The association of primary optic atrophy with von Recklinghausen's disease (multiple neurofibromatosis) is a rare occurrence, which cannot be regarded as fortuitous, as a sufficient number of cases of the two conditions manifest in the same individual have now been reported to prevent any doubt as to their connexion The cause of the optic atrophy has been ascribed to 'neurofibromatosis' of the optic nerves (Van der Hoeve, 1925, Mayer, 1937, Fuchs, 1937), but Goldmann (1893) first demonstrated the relation between von Recklinghausen's disease and glial tumour of the optic chiasm and nerves Since then, a number of cases of the syndrome have been recorded Davis (1940), in a survey of the literature, collected 32 cases, and to these added five of his own, in which detailed observations were made of the clinical features and pathology. He showed that the eye condition is due to a primary tumour of the optic chiasm or of one or both nerves, and that in those cases subjected to critical histological scrutiny the tumour was always a glioma We have found records since that date of a further nine cases, details of which are given in the Table Amongst these are three cases, all in young children, reported by Davis in the discussion following a paper by Gomes (1941) on optic-nerve gliomas, which are additional to those reported in his 1940 paper cited above The first of these was that of Rand, Irvine, and Reeves (1939), reported merely as a case of optic-nerve glioma The patient was subsequently examined by Davis, who was able to demonstrate in addition coffee-coloured patches in the skin typical of von Recklinghausen's disease, and overlooked in the original report The second case was hitherto unreported, but the third had been reported by Tanner and Hertzog (1940) as a case of fibrosarcoma of the optic nerve There was a strong familial history of von Recklinghausen's disease, including two siblings, but no evidence of this in the patient Davis made extensive histological studies of the tumour removed, and showed it to be a fairly advanced glioma Brinton's (1937) case is not included in Davis's (1940) survey We have recently studied three new cases of primary optic atrophy occurring in subjects with von Recklinghausen's disease, two of which were in identical twins, a hitherto-unrecorded occurrence In the third case the clinical diagnosis of primary optic nerve glioma was confirmed at autopsy

[1] Received August 25, 1948

Fig 11 Case 1 Postero anterior bronchogram showing splaying of the main bronchi (angle 120°) and obstruction of the right middle lobe bronchus due to the massive left auricle

Fig 12 Case 1 Left anterior oblique bronchogram showing upward displacement of the left main bronchus crowding of the left lower lobe bronchi and obstruction of the right middle lobe bronchus all due to the massive left auricle

all respects The mother, aged 45 years, and one maternal uncle showed well-marked signs of von Recklinghausen's disease, with multiple cutaneous tumours and skin pigmentation Both, however, had excellent vision and normal fundi The maternal grandfather died at the age of 65 years from an unknown cause, but was reported to have been 'covered with tumours' all his life All other relatives, as far as can be ascertained, on both the paternal and maternal sides were normal as regards their eyesight and skin condition

Case 3, a man aged 28 years, complained of lifelong headaches, cough with sputum for 12 years, effort-dyspnoea for two years, and swelling of the ankles for one month At the age of 12 years, it had been discovered that he was blind in the left eye He had had, in addition, a chronic productive cough for many years Examination showed him to be dyspnoeic, orthopnoeic, and blue, with gross deformity of the chest due to kyphoscoliosis The jugular venous pressure was raised and the liver enlarged. The heart was enlarged, with a displaced apex-beat The lungs were emphysematous, with basal râles The skin of his chest was covered with fibromas of varying size, typical of von Recklinghausen's disease There was no exophthalmos or ophthalmoplegia There was no vision in the left eye, and the fundus showed optic atrophy with no other lesion in fundus or media He was treated with digitalis and mercurial diuretics, but died nine days after admission to hospital The ante-mortem diagnosis was von Recklinghausen's disease and cor pulmonale with congestive failure, due to severe kyphoscoliosis and chronic bronchitis

At autopsy the cause of death was established as pulmonary heart disease due to advanced kyphoscoliosis with severe reduction of available bulk of the chest-cavity The lungs were collapsed, congested, and emphysematous, and the abdominal viscera showed chronic venous congestion The heart weighed 480 gm It was enlarged, with considerable right ventricular hypertrophy, but without valvular lesion or deformity In addition, there was a tumour of the pre-chiasmal portion of the left optic nerve which had not extended through or enlarged the optic foramen The right optic nerve and the rest of the central nervous system was normal The left optic nerve showed a fusiform swelling just distal to the chiasm On transverse section, the outer part was pale white and oedematous, and the central part yellowish Microscopically, an enlarged nerve stem was seen to be surrounded by a thick mass of tumour which was covered by dense fibrous layers of dura (Plate 16, Fig 3) The section could be roughly divided into five zones, the central area consisting of the enlarged nerve stem The arrangement of the bundles of nerve fibres was preserved, although the fibres themselves were largely atrophic (Plate 16, Fig 4) The connective-tissue septa were much thickened by fibrous tissue, but normally arranged There was a great increase of glial cells with accentuation of the glial framework. This glial proliferation extended outwards and largely replaced the pial sheath, which was recognizable only in a few places where it formed the second layer. The third zone included the main mass of the tumour which occupied the subarachnoid space and was covered by a narrow layer of hyperplastic arachnoid cells Outside this again was the dura, greatly thickened by dense fibrous tissue. Between the two outer zones were a few roughly spherical areas of calcification The tumour mass appeared to have risen from the glial cells within the nerve and to have invaded the pia and extended into the subarachnoid space

Case Reports

Case 1, a girl aged 13 years, had had failing vision in both eyes since the age of 4 years, of a steadily progressive nature, and more marked in the right eye than in the left When first seen, there was no useful vision in the right eye, and sight in the left was poor Her skin showed lesions characteristic of von Recklinghausen's disease (Plate 15, Fig 1). Scattered over the neck and trunk were numerous pigmented patches of the well-known *café-au-lait* colour The larger spots had an oval shape, and tended to lie in the lines of skin cleavage In addition, she had many fibromas (mollusca fibrosa), mainly confined to the trunk, but a few were found on the arms, and one on the chin Inquiry from the girl's mother revealed that the pigmentation, which was not present at birth, had first been noted at the age of 4 years, although the subcutaneous nodules were of more recent origin In addition, the girl had a concomitant convergent strabismus, with full range of movements in each eye There was no exophthalmos or ptosis. Ophthalmoscopic examination revealed advanced optic atrophy of the right disk, which showed the typical pallor and clean-cut edges of primary atrophy The vessels were normal, and no other changes in the fundus or media could be detected Vision in this eye was reduced to hand movements only The left optic disk was also atrophic, but not to such an advanced degree as the right, and vision in this eye could be corrected with glasses to 6/12 Perimetry was unsuccessful for the right field, but whilst the left visual field was normal in shape, it showed a concentric constriction of moderate degree. Full neurological examination revealed nothing of note, and hearing was unimpaired. Examination of the other systems also showed no abnormalities. Lumbar puncture demonstrated a cerebrospinal fluid that was normal in all respects, and the Wassermann reaction was negative in blood and cerebrospinal fluid Radiographs of the skull showed no abnormality The deformity of the sella and optic foramina described by Cushing (1930) was absent Radiographs of the spine, long bones, and chest were normal, and histological study of a biopsy specimen of one of the skin tumours confirmed the clinical diagnosis of multiple neurofibromatosis A diagnosis of von Recklinghausen's disease with glioma of the intracranial portion of the optic nerves and chiasm was made

Case 2, the twin-sibling of Case 1, was also examined This girl was in an institution for the blind on account of her defective vision, which had gradually deteriorated since the age of 4 years, the same age as her sister's vision commenced to fail The twins were uniovular, the presence of a single placenta being recorded at birth The physical resemblance between the sisters was striking, although the second patient to be described was more obese than her sister

On examination, the skin-changes noted in Case 2 were almost identical with those of her sister (Plate 15, Fig 2), and although slightly less advanced, the pigmented patches and fibromata were in general of the same character and distribution Vision was practically lost in each eye, and the fundi showed bilateral primary optic atrophy of an advanced degree There were no other abnormal changes in fundi or media Ocular movements were full, and there was no proptosis or ptosis Clinical examination was otherwise negative, as also was full radiological investigation The blood Wassermann reaction was negative Lumbar puncture was not performed Mentally, the patient was alert, intelligent, and as co-operative as her sister Perimetry was not possible in this case owing to the defective vision A diagnosis of von Recklinghausen's disease with glioma of the chiasm was made, as in Case 1

Other members of the family were examined and the following details obtained There were two other siblings, girls aged 17 and 19 years, both normal in

fibromatosis were found by Davis only after careful re-examination of the patient The skin lesions of von Recklinghausen's disease have been classified by Weber (1909), pigmentation being the commonest feature This may be minimal, and may be the only manifestation of the disease, but pigmented spots of the *café-au-lait* variety are as much an indication of this disease as is the neurofibromatous nodule itself (Thannhauser, 1944) The importance of the associated cutaneous signs of neurofibromatosis in making the diagnosis of optic-nerve glioma more certain has been stressed by Jefferson (1940) and Brown (1938) Conversely, Gomes (1941) agreed with Davis (1940) in believing that in the absence of cutaneous signs, optic-nerve tumour may be the sole manifestation of von Recklinghausen's disease

Radiography of the skull shows, in advanced cases of chiasmal glioma, apparent extension of the sella under the anterior clinoids from distension of the optic foramina (Martin and Cushing, 1923) Direct views of the foramina may show them to be enlarged if the tumour extends forward to involve them An enlarged optic foramen associated with a glioma of the intra-orbital part of the nerve indicates backward extension of the growth into the cranial cavity However, an intact foramen in these cases does not preclude such backward extension, since cases of this nature have been described (Rand, Irvine, and Reeves, 1939) Occasionally, optic atrophy is due to a diffuse gliosis or early tumour formation, and in these cases associated radiological signs are absent For example, Bailey and Herrmann (1938) recorded a patient with failing vision and multiple tumours of the peripheral nerves When first seen, the optic disks were normal, but a diagnosis of glioma of the optic chiasm was made on clinical grounds Later, pallor of the optic disks appeared, and at subsequent autopsy, a tumour of the chiasm was demonstrated Histologically, the optic nerves showed a dense gliosis, whilst the tumour of the chiasm was a spongioblastoma Similarly, in our first two cases, no radiological signs could be found to account for the advanced optic atrophy and visual defects. We believe that these patients have a glioma of the optic chiasm and adjacent nerves which has not yet reached a sufficient size to produce definite radiological changes In the fifth case in Davis's (1940) series, a similar pre-operative diagnosis of chiasmal gliomatosis was made on the physical signs and slight radiographic changes This probably represents a slightly more advanced stage than that found in our cases It should be noted that Davis's patient was aged 26 years when seen, and it is conceivable that radiographs taken at the age of 13 years might have been normal.

Diagnosis

The recognition of this syndrome of optic-nerve tumour in von Recklinghausen's disease may be difficult but, in general, the signs and symptoms present certain features which, when taken in conjunction with the cutaneous lesions and X-ray studies of the skull, help to establish the diagnosis with reasonable certainty in most cases When the tumour is intra-orbital, the diagnosis presents no difficulties The slowly progressive proptosis and visual failure,

Analysis of the Clinical Features

Sex incidence Of the 49 recorded cases, including the present three, 18 were in male and 30 in female patients, and in one case the sex was not recorded. There appears, therefore, to be a preponderance in the female sex

Age As the presenting and often the only symptom is progressive loss of vision commonly starting in childhood, the commencement of visual failure is the only clinically recognizable onset of the syndrome This varies in the recorded instances from two years in Aegerter and Smith's (1937) case to 52 years in the case of Goldstein and Wexler (1932) The age of onset of 48 cases is tabulated (the age of one case was not recorded).

Onset below 5 years of age		17 cases	(35%)
,, from 6 to 10	,,	15 ,,	(31%)
,, ,, 11 to 20	,,	8 ,,	(17%)
,, above 20	,,	8 ,,	(17%)

It will be seen that two-thirds of the patients were under 10 years of age at the onset, which agrees with the figures of Willis (1948), who gives the peak incidence of gliomas in general as occurring in the second hemi-decade This, then, is a disease of children and young people

Fundal appearances Optic atrophy is the usual finding and may be unilateral or bilateral depending on whether the pre-chiasmal portion of one nerve only or the chiasm and both nerves are involved Papilloedema in the latter cases is rare, but it may be superimposed on atrophy through involvement of the third ventricle by a chiasmal neoplasm with the production of internal hydrocephalus When the tumour lies within the orbit, papilloedema is a frequent occurrence In these cases there is often progressive exophthalmos which usually follows the onset of deterioration of vision, but may proceed *pari passu* with it

Exophthalmos is common with intra-orbital tumours and rare when the tumour is situated entirely within the skull, but when the growth extends through the optic foramina to a sufficient degree to displace the orbital contents exophthalmos ensues A glioma is the only lesion affecting the chiasm which does extend forward in this manner, and the occurrence of exophthalmos in a case of chiasmal tumour is pathognomonic of a glioma (Brown, 1938)

Visual fields Field defects in chiasmal lesions are variable Atypical hemianopic defects may occur (Martin and Cushing, 1923), or the defect may be bizarre and the blind areas ill-defined (Williamson-Noble, 1939) Frequently the fields are generally constricted, as in our first case and Brinton's (1937) case Generally contracted fields were also demonstrated by Dandy (1922) in two cases of prechiasmal lesion of the optic nerve, and by Mayer (1937)

Cutaneous lesions These are not complained of by the patient and may, if slight, be easily overlooked In the case reported by Rettelbach and Schutzbach (1942) peripheral neurofibromatosis was found only at autopsy, although, in view of its presence in the child's father, it was sought during life In the patient of Rand, Irvine, and Reeves (1939) signs of multiple peripheral neuro-

The treatment of intra-orbital tumours is, of course, surgical removal, and although it may not be possible to remove the whole tumour, even partial ablation may produce satisfactory results For the chiasmal lesions, little can be done, and operation is contra-indicated, although in doubtful cases exploration may be required X-ray irradiation may be attempted, but as in cases of other benign tumours cannot be expected to achieve much

Pathology of the Optic-nerve Tumours

Hudson (1912) classified tumours of the optic nerve into three types, gliomas arising from the nerve proper, endotheliomas arising from the nerve sheath, and fibromatosis of the dural sheath Later (Hudson, 1940), he stated that the majority of these tumours could be classified histologically according to their origin in the glial tissue of the nerve or in the tissues of the sheath Of the latter, the great majority are meningo-endotheliomas A marked difference in age incidence is noticeable between the two types of tumour, 60 per cent of the glial tumours being manifest in the first decade as against only 24 per cent. of the meningeal Davis (1940) found glial tumours to be twice as common as endothelial He believed that the fibroma in Hudson's (1912) classification was a very rare lesion, and suggested that the term 'neurofibroma' as applied to tumours of the optic nerve should be abandoned, since it conveys the erroneous impression that the lesion resembles or is identical with neurofibroma of the peripheral nerves He stated that the tumour is most often a glioma, or sometimes an endotheliomа, although he admitted the possibility that the finer twigs of the peripheral or sympathetic nerves which penetrate the optic nerve with the blood-vessels might be the source of neurofibromatosis in the strictest sense Moore (1944) recognized only two types of optic-nerve tumour, the astrocytoma and the meningeal fibroma, arising in the sheath of Schwalbe

In the monograph already referred to, Davis (1940) described five stages in the gliomatous process In the first stage, there is general hyperplasia of neuroglia within the nerve-stem, with early fibre-formation by fibrous astrocytes Aegerter and Smith (1937) called this stage 'semi-neoplastic glial proliferation' or 'astrocytosis'. In the second stage, the glial proliferation is continued, with extension through the pia The arachnoid is much thickened from hyperplasia of arachnoid cells This is a separate proliferative reaction, and is not part of the gliomatous tumour in the nerve-stem The next stage in the process is an extension of the growth in the intervaginal space farther out in the sheath, with penetration and invasion of the mass of proliferated arachnoid cells which remain as a thin layer on the outer surface of the gliomatous tumour. In the fourth stage, the growth has destroyed most of the sheath including the hyperplastic arachnoid, and the entire nerve-stem and coverings are replaced by the glioma, whose cells, at this stage, may become spindle-shaped and closely packed, and hence the report of some of these tumours as 'gliosarcomas' The histological appearances in our third case correspond closely to the third stage of Davis and also to a description of a glioma of the

with disturbance in the motility of the eye, sometimes combined with ptosis, form a well-recognized syndrome (Braendstrup, 1944, Mannheimer, 1946) Ophthalmoscopy in these cases may show either papilloedema or optic atrophy, or the nerve-head may be displaced forward by the growth, as in Pugh's (1946) case The growth may even be seen extending through into the globe as in the cases of Stallard (1938), Marks, Willis, and Anderson (1939), and Rettelbach and Schutzbach (1942) According to Gomes (1941), pain is rarely present unless the growth involves the ciliary nerves Extension of the growth backwards into the cranial cavity may occur, and can usually be detected radiographically by enlargement of the corresponding optic foramen, although absence of such evidence, as already pointed out, is no proof that this has not taken place When the tumour is confined to the intracranial portion of the optic nerves or to the chiasm, the local signs of tumour formation are absent, and it is in these cases that diagnostic difficulties arise Presented with such a case of progressive visual failure and optic atrophy, and with no localizing signs to explain the blindness, it is tempting to postulate an obscure optic neuritis as the cause But if, in addition, the subject has signs of peripheral neurofibromatosis, the diagnosis is almost certainly a glial tumour of the optic nerves or chiasm, and this diagnosis may be supported by finding characteristic X-ray changes in the skull The condition is an explanation of some of the more obscure cases of retrobulbar neuritis, and primary atrophy of the disks in cases of generalized neurofibromatosis, however slight the manifestations, should be suspected as being due to a gliomatous process in the chiasm or its adjacent nerves

Course

In general, glial tumours and especially astrocytic gliomas are of slow growth and relatively benign nature. Gliomas of the optic nerve (commonly astrocytomas) do not metastasize (Duke-Elder, 1940) Jefferson (1940) has drawn attention to the extraordinary attenuation of the malignancy of the tumours, in recording the case of a boy on whom he had operated at the age of 12 years for a glioma of the chiasm Removal of the tumour was not attempted Five years later the boy was still able to get about, although vision had deteriorated. Subjects of incomplete operation for intra-orbital optic-nerve tumours have been found free of recurrence 15, 18½, 19, and 24 years (two cases) after operation It is clearly evident that in certain cases the lesion is very slowly progressive, and in the absence of signs pointing to a space-occupying lesion, either intracranial or intra-orbital, the neoplastic nature of the lesion may not be recognized In Cases 1 and 2 vision started to fail at the age of four years, and yet there was no evidence nine years later of tumour formation which could be clinically diagnosed as such In Case 3, blindness was complete at the age of 12 years, yet at autopsy 17 years later, a strictly localized growth was found, death being due to unrelated causes Other evidence of the relatively benign nature of the condition and its tendency to remain localized to the structures of the chiasm and optic nerve over very many years has been supplied by many writers

two, although stated to be neurofibromatous, were not examined microscopically Their histology, therefore, remains unknown. Of the later 12 cases summarized in the Table, histological examination was made in six, all of which were gliomas Thus, in the total of 49 recorded cases, histological examination of the tumours was made in 41 Thirty-five (85 per cent) of these were gliomas, and four were endotheliomas Only two were reported as being 'neurobromata' It is possible that the proportion of glial tumours may be even higher, as, in the later stages, the cellular elements may present an atypical anaplastic appearance Unless one is familiar with this type of glioma, and in the absence of differential stains for neuroglia, these cells may be regarded as sarcomatous (as in the case reported by Tanner and Hertzog, 1940), or the elongated closely packed cells may simulate the palisading of a neurofibroma

It should be stressed that there is no pathological or nosological difference between gliomas situated in the optic chiasm, with or without involvement of the adjacent nerves, and those confined to a single nerve

Incidence of Optic Glioma in von Recklinghausen's Disease

The incidence of manifestations of peripheral neurofibromatosis in chiasmal and optic-nerve tumours is about 10 per cent Davis (1940) stated that the total recorded number of these tumours is approximately 380 Of these 38 (10 per cent) had cutaneous neurofibromatosis Six (33 per cent) of Cushing's (1930) 18 cases of chiasmal glioma had von Recklinghausen's disease Probably the syndrome may be more common than Davis's figures suggest, as the optic gliomas occur most often in childhood, at a time when the skin lesions may be minimal and not fully developed On the other hand, references to visual defects and optic atrophy in von Recklinghausen's disease do occur in the literature, and Davis mentioned that he found 35 such instances, in none of which was it suggested that a tumour of the optic nerve or chiasm might be the cause Our experience has been similar During the period 1938 to March 1948, the diagnosis of von Recklinghausen's disease has been entered on the case-sheets of eight patients admitted to the Postgraduate Medical School of London for some other condition Of these, the three cases recorded in the present paper had visual symptoms and optic atrophy No conclusions can be drawn from such a small series, but we feel that if the syndrome is borne in mind, careful examination may reveal more cases of optic atrophy with von Recklinghausen's disease than has hitherto been recorded

Heredity

The hereditary nature of von Recklinghausen's disease is generally accepted Von Recklinghausen (1882) himself pointed out that multiple neurofibromatosis could not be considered a purely acquired disease, and Thomson (1900) proved the hereditary background of the disorder Numerous cases of hereditary central neurofibromatosis have been recorded Amongst them, Gardner and Frazier (1930) reported a family in which von Recklinghausen's disease, in the

optic nerve by Oberling and Nordmann (1927), although these writers maintained that the glial tumours arise from the 'meningioblasts' of the pia arachnoid Davis produced convincing evidence that this is not so, and that these tumours arise from glial cells in the nerve proper, and our case supports the view that this explanation is the correct one

TABLE

Author	Sex and age (years)	Age at onset (years)	Family history of von Recklinghausen's disease	Optic atrophy	Clinical diagnosis	Histological diagnosis
Brinton (1937)	F 7	4½	Not stated	Bilateral	Chiasmal glioma	
Rand, Irvine, and Reeves (1939)*	M 4½		Present		Optic nerve tumour	Spongioblastoma
Tanner and Hertzog (1940)*	M 3	2	Present	Unilateral	Fibrosarcoma of optic nerve	Advanced glioma
Davis (1940)*	M 'Young child'	?	Present	?	Glioma of optic nerve	
Goldmann and Grünthal (1941)	M 6	?	Present	Absent	Tumour of optic nerve	Glioma (Stage III of Davis, 1940)
Rettelbach and Schutzbach (1942)	F 3	2½	Present	Bilateral	Tumour of chiasm and optic nerves	Glioma
Bruendstrup (1944)	F 10		Present	Not stated	Optic nerve tumour	Oligodendroglioma
Pugh (1946)	F 2 9/12	2 4/12	Present	Unilateral	Bilateral optic-nerve tumours	
Meadows (1948)	F 19	Not known 'Many years ago'	Absent	Bilateral	Chiasmal tumour	
Dresner and Montgomery (1949)	F 13	4	Present	Bilateral	Chiasmal glioma	
,,	F 13	4	Present	Bilateral	Chiasmal glioma	
,,	M. 28	12	Not known	Unilateral	Optic nerve tumour	Astrocytoma (Stage III of Davis, 1940)

* Cited by F A Davis in a paper by Gomes (1941)

The nature of the small areas of calcification lying beneath the much-thickened dura (Plate 16, Fig 3) is obscure A similar appearance is shown in a section of the optic-nerve glioma from the case of Rettelbach and Schutzbach (1942)

Of the 37 cases of von Recklinghausen's disease with associated optic-nerve tumours collected by Davis all except eight were classified as gliomas Of the remainder, four were endotheliomas, two were stated to be neurofibromas, and

We wish to thank Prof E P Sharpey-Schafer for permission to publish Case 1, and for help in the preparation of this paper, and Dr J G Scadding for permission to publish Case 3 The photomicrographs were prepared by Mr E. V Willmott

REFERENCES

Aegerter, E E, and Smith, L W (1937) *Am J Cancer*, **31**, 212
Bailey, P, and Herrmann, J D (1938) *Am J Path* **14**, 1
Blotevogel, H (1933) *Dermat Wchnschr* **96**, 361
Braendstrup, P (1944) *Acta Ophth* **22**, 72
Brinton, D (1937) *Proc Roy Soc Med* **30**, 855
Brown, T H (1938) *Tr Ophth Soc U Kingdom*, **59** (Part II), 961
Cushing, H (1930) *Arch Ophth* **3**, 505 and 704
Dandy, W E (1922) *Am J Ophth* **5**, 169
Davis, F A (1940) *Arch Ophth* **23**, 735 and 937
Duke Elder, Sir W S (1940) *Textbook of Ophthalmology*, Lond, vol 3, p 3088
Fuchs, A (1937) *Wien klin Wchnschr* **50**, 291
Gardner, W J, and Frazier, C H (1930) *Arch Neurol and Psychiat* **23**, 266
—— and Turner, O A (1940) *Ibid* **44**, 76
Goldmann, E E (1893) *Beitr z klin Chir* **10**, 13
Goldmann, H, and Grünthal, E (1941) *Ophthalmologica*, **102**, 79
Goldstein, I, and Wexler, D (1932) *Arch Ophth* **7**, 259
Gomes, J P (1941) *Am J Ophth* **24**, 1144
Grill, J., and Kuzma, J F (1942) *Arch Path* **34**, 902
Hoekstra, G (1922) *Virchows Arch f path Anat* **237**, 79
Hudson, A. C (1912) *Roy London Ophth Hosp Rep* (Part 3), **18**, 317
—— (1940) *Proc Roy Soc Med* **33**, 685
Jefferson, G (1940) *Ibid* **33**, 688
Leers, H (1936) *Ztschr f menschl Vererb u Konstitutionslehre*, **19**, 721
Loftis, E L (1940) *Arch Dermat and Syph* **42**, 657
Mannheimer, M (1940) *Am J Ophth* **29**, 323
Marks, E O, Willis, R A, and Anderson, J R (1939) *Trans Ophth Soc Australia*, **1**, 46
Martin, P, and Cushing, H (1923) *Arch Ophth* **52**, 209
Mayer, H J (1937) *California and West Med* **46**, 261
Meadows, S P (1948) Personal communication
Moore, R A (1944) *Textbook of Pathology*, p 1202
Oberling, C, and Nordmann, J (1927) *Ann d'oculi* **164**, 561
Preiser, S A, and Davenport, C B (1918) *Am J Med Sci* **156**, 507
Pugh, R J (1946) *Proc Roy Soc Med* **39**, 695
Rand, C W, Irvine, R, and Reeves, D L (1939) *Arch Ophth* **21**, 799
Rettelbach, E, and Schutzbach (1942) *Arch f Ophth* **145**, 179
Siemens, H W (1926) *Virchows Arch f path Anat* **260**, 234
Stallard, H B (1938) *Brit J Ophth* **22**, 11
Tanner, J W, and Hertzog, A J (1940) *Wisconsin Med J* **39**, 29
Thannhauser, S J (1914) *Medicine*, **23**, 105
Thomson, A (1900) *Neuroma and Neuro Fibromatosis*, Edin
Turner, O A, and Gardner, W J (1938) *Am J Cancer*, **32**, 339
Van der Hoeve, J (1925) *Am J Ophth* **8**, 101
von Recklinghausen, F (1882) *Ueber die multiplen Fibrome der Haut und ihre Beziehung zu den multiplen Neuromen*, Berl
Weber, F P (1909) *Brit J Dermat* **21**, 49
Williamson Noble, F A (1939) *Tr Ophth Soc U Kingdom* (Part 2), **59**, 627
Willis R A (1948) *Pathology of Tumours*, Lond, p 802

form of bilateral acoustic nerve tumours, was transmitted as a Mendelian dominant through five generations. At that time, the diagnosis was confirmed histologically in only two cases, although 38 members were affected. Subsequently, Gardner and Turner (1940) summarized the gross and histological observations in four additional affected members of the same family. Turner and Gardner (1938) described another family in which one or more tumours of the sheaths and enveloping membranes of the nervous system appeared as a hereditary trait, and were transmitted as a Mendelian dominant, seven cases of peripheral and central neurofibromatosis occurred in a family of 14, of which three were verified at autopsy Preiser and Davenport (1918) in a study of 115 offspring of 20 patients with multiple neurofibromatosis found 43 5 per cent to be affected, which again suggested the inherited trait to be a Mendelian dominant Furthermore, they found that there appears to be a familial relationship in the manifestations of the disease, as to both its type and distribution Hoekstra (1922) also reported a congenital inclination to neurofibromatosis in four generations, and increasing through them, and the hereditary aspects of neurofibromatosis have also been dealt with by Grill and Kuzma (1942)

In a study of twins, Siemens (1926), on the other hand, came to the conclusion that von Recklinghausen's disease is not a simple dominant hereditary disease The symptoms could develop in various members of one family, but, of uniovular twins, one may show the disease and not the other Its occurrence in identical twins is very rare It has been recorded in Germany by Blotevogel (1933) and Leers (1936) and in the United States of America by Loftus (1940), but so far as we are aware no case of either peripheral or central neurofibromatosis in uniovular twins has been previously recorded in this country Central neurofibromatosis manifesting itself as glioma of the optic chiasm in uniovular twins with von Recklinghausen's disease has never previously been reported. In our own patients (Cases 1 and 2), whilst the hereditary nature of the peripheral neurofibromatosis is clear and appears to be transmitted as a Mendelian dominant factor, there is no such evidence as regards the chiasmal lesions, which appear to have arisen in this family for the first time

Summary

1. Three cases are recorded in which primary optic atrophy was associated with multiple neurofibromatosis Two of the cases occurred in uniovular twins In the third case, the cause of the optic atrophy was demonstrated *post mortem* to be an astrocytic glioma of the optic nerve

2 A survey of the literature has revealed the occurrence of primary optic atrophy in subjects of von Recklinghausen's disease in 46 previously recorded instances It has not hitherto been described in identical twins

3 In the 41 cases in which histological study of the optic-nerve lesions was made, 35 (85 per cent) were primary gliomas of the nerves or chiasm

4 The clinical, diagnostic, and hereditary aspects of the syndrome are briefly reviewed

FIG 1 Case 1 Showing cutaneous lesions of von Recklinghausen s disease

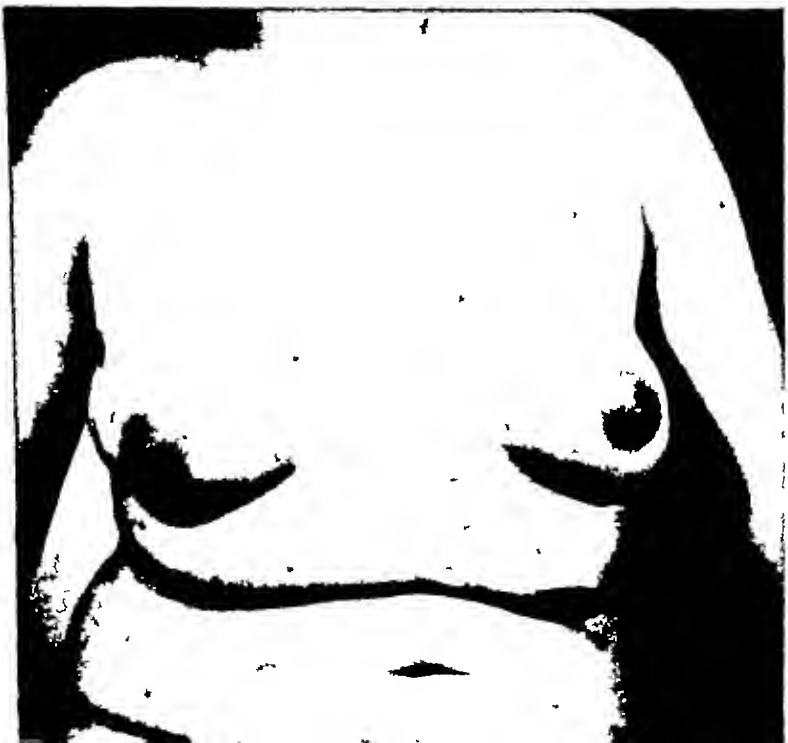

616 633 786 452 1

THE MARCHIAFAVA MICHELI SYNDROME

(Paroxysmal Nocturnal Haemoglobinuria)[1]

By JOHN MARKS

(From the Department of Medicine, University of Cambridge, and the Bland-Sutton Institute of Pathology, Middlesex Hospital, London)

Introduction

HAEMOGLOBINURIA is generally recognized to be a classical sign of an acute haemolytic process, and descriptions of the various haemolytic agents which may cause haemoglobinuria have made a vast literature The subject has been reviewed by Ross (1945), Mackenzie (1929), Hegglin (1944), and Hoffman and Kracke (1943 *b*) One of the rarer types of haemoglobinuria is the disorder known as the Marchiafava Micheli syndrome, which is characterized by the usual features of a haemolytic anaemia, together with hepato-splenomegaly and bouts of haemoglobinuria A distinctive feature of the syndrome is that the haemoglobin is either present in the urine only during sleep or else increases greatly during the period of sleep as compared with the waking period. The symptom of nocturnal haemoglobinuria in association with jaundice was first described by Chauffard and Troisier (1908), but in spite of the many subsequent reports (van den Bergh, 1911, Marchiafava and Nazari, 1911, Biffis, 1915, Sisto, 1915, Griffin, 1923, Panton, Maitland-Jones, and Riddoch, 1924, Scheel, 1925, Manini, 1927, Salén, 1927, Enneking, 1928) the nature of the disease was not appreciated until Marchiafava (1928) gave the first clear account, which was later followed by Micheli's (1931) excellent paper on the subject About 73 cases of the syndrome have so far been described (Chauffard and Troisier, 1908, van den Bergh, 1911, Marchiafava and Nazari, 1911, Biffis, 1915, Case 5, Sisto, 1915, Case 3, Griffin, 1923, Panton, Maitland-Jones, and Riddoch, 1924, Scheel, 1925, Manini, 1927, Salén, 1927, Enneking, 1928, Villa, 1928, Saxl, 1928, Barta and Görög, 1929, Donati, 1930, Marchiafava, 1931, Micheli, 1931, Hitzenberger, 1931, Nazari, 1931, Bergmark, 1931, Lasch, 1931, Rosenthal, 1932, Eastwood and Smyth, 1932, Meyer, 1933, Weir, 1933, Lolli, 1933, Iglauer and St Frenreisz, 1934 *a*, *b*, Falkiewicz and Musial, 1935, Schally, 1935, Trestini, 1935, Mackenzie, 1935, Witts, 1936, Hamburger and Bernstein, 1936, Calabresi, 1937, Cain, Catton, Harrispe, and van den Boijen, 1937, Israëls and Wilkinson, 1938, Scott, Robb-Smith, and Scowen, 1938, Jordan, 1938, Brule, Hillemand, and Gaube, 1938, Sega, 1938, Ham, 1939, Villaret, Justin-Besançon, Rubens-Duval, and Sikorav, 1939, Valke and van den Bergh, 1939, Casolo and de Colle, 1939, Arndal, 1940, Ham and Horack, 1941; Buell and

[1] Received August 26, 1948

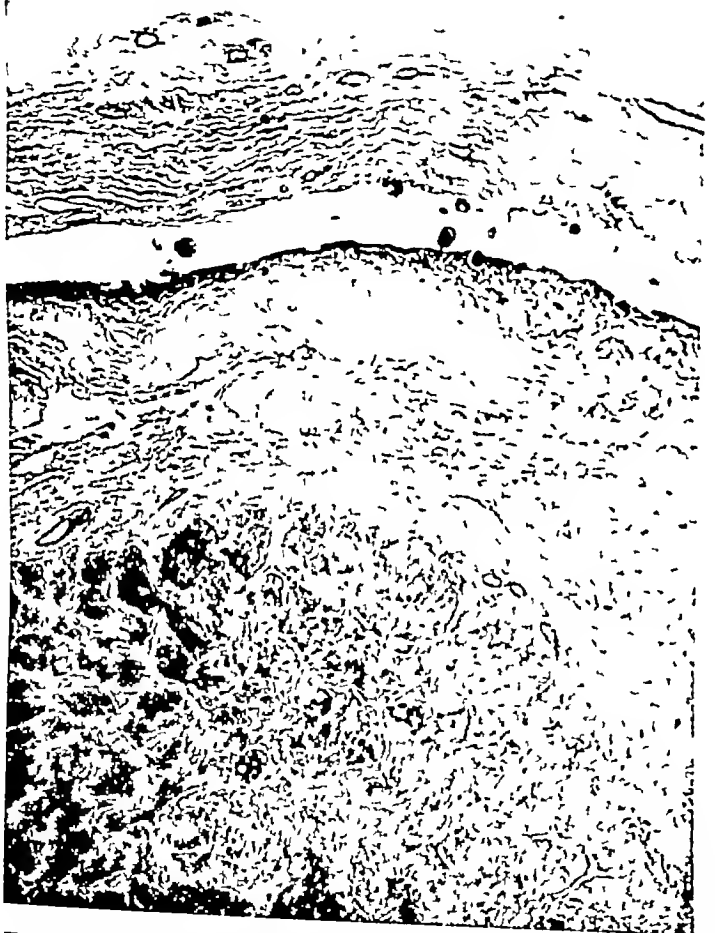

FIG 3 Section of optic nerve in Case 3 Low power view showing the enlarged nerve stem surrounded by tumour and covered by thickened dura (haematoxylin and eosin ×40)

FIG 4 Same section as in Fig. 3 High power view of the nerve showing atrophy of the nerve fibres, increased glial tissue, and thickened fibrous septa (haematoxylin and eosin ×200)

admission, though nocturnal haemoglobinuria still persisted. Soon after, the patient felt sick and this feeling continued for some days, culminating in a severe bout of vomiting which lasted all night A drip blood transfusion of 2,500 c c of fresh blood was given, after which the urine contained much haemoglobin day and night for 48 hours A little later the patient complained of shooting pain behind the eyes and developed herpes labialis, whereupon, remarkably, the

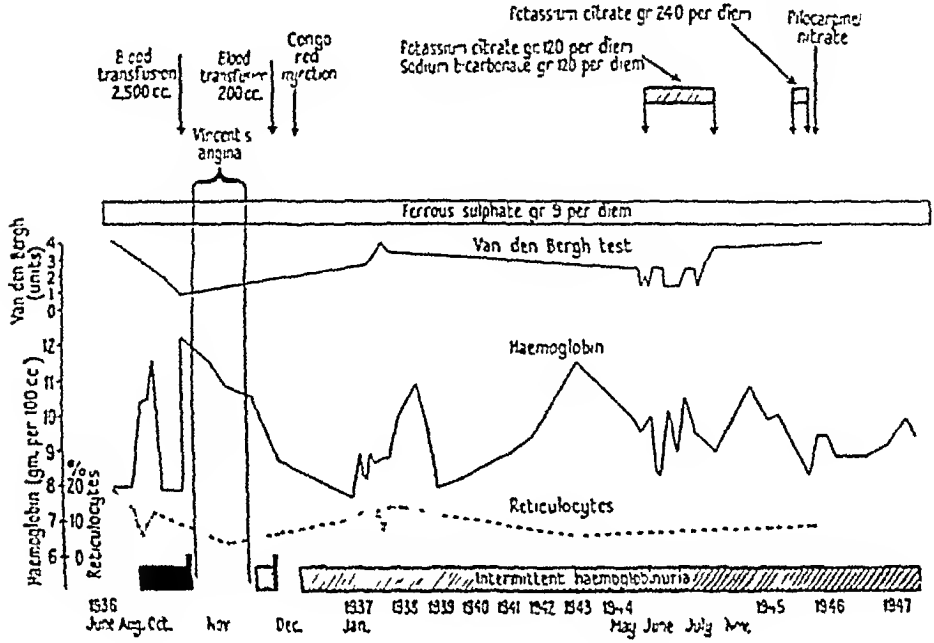

FIG 1

urine was free from haemoglobin for five weeks despite an attack of Vincent's angina which was present during much of the period Nevertheless, the blood count fell gradually and she suffered from bouts of right epigastric pain mainly at night A blood transfusion of 200 c c was given on November 22 This was again followed by a remission in the haemoglobinuria, but the blood count did not rise An intravenous injection of Congo red on December 2 diminished the haemoglobinuria for six days, but during this time the patient had further bouts of abdominal pain and on December 29 developed an acute *E coli* pyelitis During the acute stage of this complication the urine remained free from haemoglobin The infection eventually cleared satisfactorily, and the patient was discharged after a five-months stay in hospital with a haemoglobin of 9 0 gm per 100 c c Between 1937 and 1944, she was seen regularly as an out-patient, remaining fairly well and at work most of the time Haemoglobinuria persisted in the early morning specimens, and was present throughout the 24 hours during crises, which were usually associated with infections of the upper respiratory tract She frequently experienced upper abdominal pain of biliary type The haemoglobin varied from 8 0 to 11·8 gm per 100 c c , and the reticulocyte count from 7 to 16 per cent (Fig 1) During the early part of 1944 the spleen became palpable and extended to 7 cm below the costal margin On May 29 the patient was given a mixture of potassium citrate gr 30 and sodium bicarbonate gr 30 four times a day The alkaline mixture produced no lasting diminution in either

Mettier, 1941, Brendstrup, 1941, Hegglin and Maier, 1941, De Marval and Bomchil, 1942, Olivarius, 1942, Dameshek, 1942, Hoffman and Kracke, 1943a, b, Dacie and Firth, 1943; Pierce and Aldrich, 1943, Dacie and Gilpin, 1944, Flynn, 1945, Milne, 1945, Manchester, 1945, Alzona and Viale, 1946, Meyer, 1946, Fisher, 1947; Hickey and Malley, 1948) The diagnosis, however, could never be established with certainty until Ham (1939) showed that in this disorder the patient's cells are haemolysed by his own and by normal serum, and that the reaction is sensitive to changes in pH This specific diagnostic serological test is known as Ham's test The present paper contains a report of three examples of the condition seen in the Middlesex Hospital during the past few years, and reviews all the references to be found in the literature

Case Report

Case 1 A woman aged 36 years, a telephone operator, was first admitted to the Middlesex Hospital on August 20, 1936, complaining of pallor and jaundice, palpitations and dyspnoea on exertion, and that she sometimes passed dark urine. At the age of 13 years she had been admitted to the Bolingbroke Hospital with menorrhagia and anaemia There, investigations showed an erythrocyte count of 950,000 per c mm, haemoglobin 20 per cent, and leucocytes 1,400 per c.mm, with neutrophils 476 per c mm and lymphocytes 882 per c mm She improved on iron therapy Three months before admission to the Middlesex Hospital the patient had noticed icterus of the sclerae and pains in the back which had recurred one month later, the pain being then mainly between the shoulder-blades She rested for a month, but without improvement, and a month before admission a blood count showed haemoglobin 8·0 gm per 100 c c., erythrocytes 2,610,000 per c mm, mean corpuscular haemoglobin 30 6 $\gamma\gamma$, reticulocytes 19 per cent, icterus index 20 units, and leucocytes 3,000 per c mm, with neutrophils 1,560 per c mm, lymphocytes 1,380 per c mm, and monocytes 60 per c mm The red-cell fragility in hypotonic saline was normal On admission she was a well-nourished woman with a sallow skin and icterus of the sclerae The cardiovascular and respiratory systems were normal and the blood pressure 130/90 The spleen and lymphnodes could not be felt, but the liver was enlarged and firm The central nervous system showed no abnormality

Investigations The haemoglobin was 8 0 gm per 100 c c, erythrocytes 2,720,000 per c mm, mean corpuscular haemoglobin 29 0 $\gamma\gamma$, mean corpuscular volume 96 cu μ, mean corpuscular haemoglobin concentration 30 per cent, mean corpuscular diameter 7 24 μ, mean corpuscular thickness 2 3 μ, and reticulocytes 13 per cent Films showed polychromasia, slight anisocytosis, and poikilocytosis Total leucocytes were 4,000 per c mm, with neutrophils 2,040 per c mm, lymphocytes 1,880 per c mm, and monocytes 80 per c mm The red cell fragility was normal The Price-Jones curve was normal The platelets were 100,000 per c mm The van den Bergh reaction was direct delayed—very faintly positive, indirect—very faintly positive A fractional test meal was normal The Wassermann and Donath–Landsteiner reactions were negative The urine contained oxyhaemoglobin and methaemoglobin, from 8 a m to 8 p.m total haemoglobin excreted 1 98 gm and from 8 p m to 8 a m total haemoglobin excreted 2 69 gm The urine contained neither urobilin nor bilirubin. Cystoscopy showed a normal bladder with a blood-stained ureteric efflux

Progress The patient was given massive doses of iron and improved for a time, the haemoglobin being raised to 11 6 gm per 100 c c one month after

admission, though nocturnal haemoglobinuria still persisted Soon after, the patient felt sick and this feeling continued for some days, culminating in a severe bout of vomiting which lasted all night A drip blood transfusion of 2,500 c c of fresh blood was given, after which the urine contained much haemoglobin day and night for 48 hours A little later the patient complained of shooting pain behind the eyes and developed herpes labialis, whereupon, remarkably, the

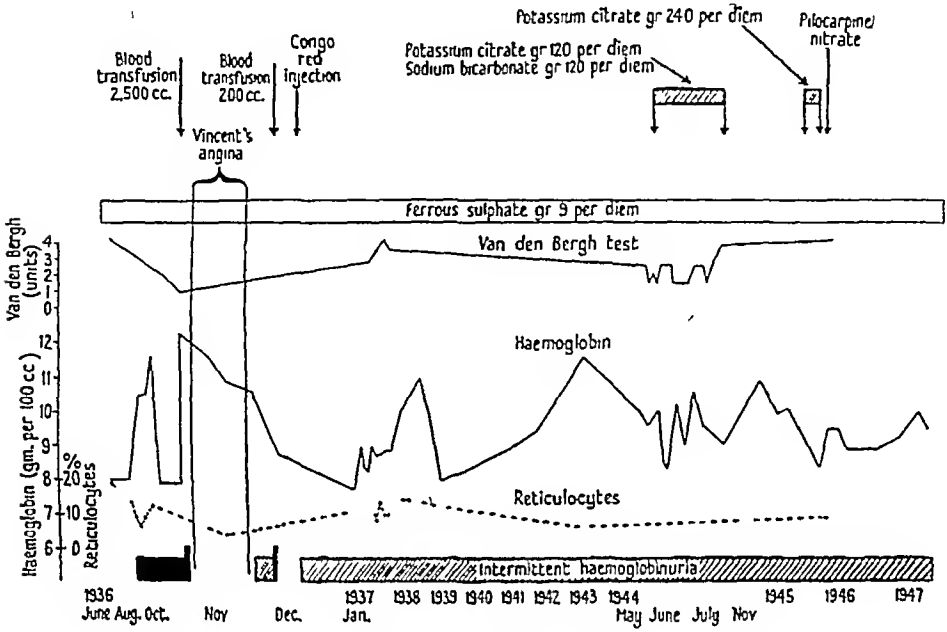

FIG 1

urine was free from haemoglobin for five weeks despite an attack of Vincent's angina which was present during much of the period Nevertheless, the blood count fell gradually and she suffered from bouts of right epigastric pain mainly at night A blood transfusion of 200 c c was given on November 22 This was again followed by a remission in the haemoglobinuria, but the blood count did not rise An intravenous injection of Congo red on December 2 diminished the haemoglobinuria for six days, but during this time the patient had further bouts of abdominal pain and on December 29 developed an acute *E coli* pyelitis During the acute stage of this complication the urine remained free from haemoglobin The infection eventually cleared satisfactorily, and the patient was discharged after a five-months stay in hospital with a haemoglobin of 9 0 gm per 100 c c Between 1937 and 1944, she was seen regularly as an out-patient, remaining fairly well and at work most of the time Haemoglobinuria persisted in the early morning specimens, and was present throughout the 24 hours during crises, which were usually associated with infections of the upper respiratory tract She frequently experienced upper abdominal pain of biliary type The haemoglobin varied from 8 0 to 11 8 gm per 100 c c , and the reticulocyte count from 7 to 16 per cent (Fig 1) During the early part of 1944 the spleen became palpable and extended to 7 cm below the costal margin On May 29 the patient was given a mixture of potassium citrate gr 30 and sodium bicarbonate gr 30 four times a day The alkaline mixture produced no lasting diminution in either

the haemoglobinuria or the jaundice, and the blood count showed no improvement Alkali therapy in varying dosage was continued for nine weeks without effect

On October 10 the patient was admitted to the Royal Hampshire Hospital with biliary colic, and while there had several haemolytic crises Blood counts showed haemoglobin varying between 40 and 70 per cent, reticulocytes 12 per

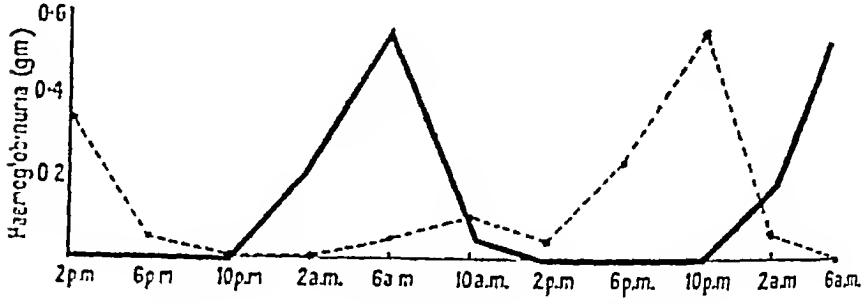

FIG 2 Effect of reversal of sleep on haemoglobinuria
Continuous line = Asleep 10 p.m to 6 a.m
Interrupted line = Asleep 10 a m to 6 p.m

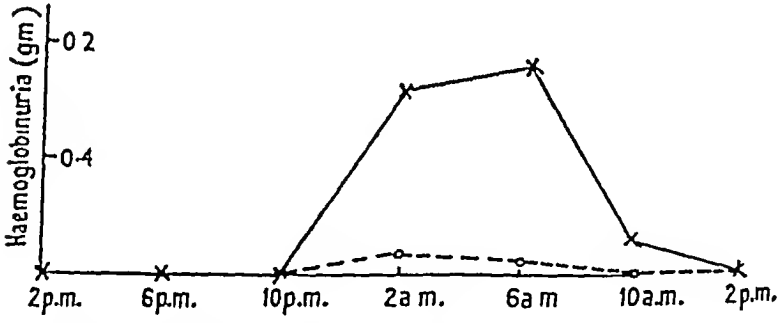

FIG 3 Effect of pilocarpine nitrate on degree of haemoglobinuria
Continuous line = Control
Interrupted line = Pilocarpine nitrate gr $\frac{1}{10}$ at 8 p.m and 2 a.m

cent, and icterus index 30 units A cholecystogram was normal Later at the Middlesex Hospital a strongly positive Ham serological test confirmed the diagnosis, and she was admitted on November 8, 1945, for further trial of possible therapeutic agents Investigations showed a blood count essentially the same as before with a haemoglobin of 9 6 gm per 100 c c The blood group was O, Rh phenotype 1234 (Murray, 1944) The plasma-proteins (copper sulphate method) were 5 85 gm per 100 c c The icterus index was 27 units The Price-Jones curve showed a mean cell diameter of 7 83 μ, with standard deviation 0 6, coefficient of variation 7 8 per cent, and macrocytosis 7 per cent The red-cell fragility was normal The effect of the reversal of sleep was tried Typical days are shown in Fig 2 The haemoglobinuria always occurred during sleep whether by night or day, and was absent during waking periods Pilocarpine nitrate was tried (Fig 3) and a dose of gr 1/10 at 8 p m and 2 a m caused a great decrease in the nocturnal haemoglobinuria The drug was not continued because a dosage which had any effect on the haemoglobinuria caused great drowsiness, and upon

one occasion a fainting attack She was discharged on December 22, 1945 She had remained in good health during 1946 and 1947, being last seen in the middle of June 1947 During this interval there were periods lasting some weeks of complete freedom from haemoglobinuria

Case 2 A housewife, aged 54 years, was admitted to the Middlesex Hospital on March 11, 1937, complaining of weakness There was nothing relevant in the family history The first record of urinary trouble was in March 1933, when the patient passed dark urine, in which her private doctor found haemoglobin The urine was darker in the early mornings and cleared during the day She was admitted to the Bradford Royal Infirmary in March 1933 and treated with iron, oral liver, marmite, and a stomach preparation, without any improvement During the next few weeks her urine became clear of haemoglobin Liver injections administered at home caused nausea, followed by jaundice and haemoglobinuria lasting about a week and eventually led to her admission to Burnley Hospital She was there treated with iron and malt with some improvement From 1934 to 1937 despite several courses of different medicines she continued to have bouts of nocturnal haemoglobinuria On admission to the Middlesex Hospital in 1937 there was slight icterus of the skin and the sclerae, whilst the mucosa of the mouth was pale A systolic murmur was audible at the pulmonary area, but otherwise the cardiovascular system was normal The liver and spleen were just palpable All the other systems were normal

Investigations The haemoglobin was 5 1 gm per 100 c c, erythrocytes 2,700,000 per c mm, mean corpuscular haemoglobin 17 $\gamma\gamma$, mean corpuscular haemoglobin concentration 25 per cent, mean corpuscular thickness 1 6 μ, mean corpuscular diameter 7 2 μ, and films showed anisocytosis, poikilocytosis, hypochromia, polychromasia, and reticulocytes 6 per cent The leucocytes numbered 1,980 per c mm, with neutrophils 678 per c mm, lymphocytes 1,050 per c mm, monocytes 232 per c.mm, and eosinophils 20 per c mm The platelets were 210,000 per c mm The sedimentation rate (Wintrobe method) corrected to a packed-cell volume of 45 per cent was 3 mm in one hour The red-cell fragility was normal The icterus index was 9 units The van den Bergh reaction, direct and indirect positive, quantitative 1 unit The Takata Ara reaction was negative The faeces did not contain occult blood The Wassermann reaction was negative The urine was normal on admission and blood was not present

Progress On March 22 a blood transfusion of 500 c c was given, the urine at this time being normal That night the temperature rose to 100° F and night specimens of urine contained much haemoglobin, but no red cells The haemoglobinuria continued for three days One week later, Mr Gordon Taylor removed the spleen, a blood transfusion of 1,000 c c being given during the operation The haemoglobin at the end of the operation was 13 7 gm per 100 c c and the erythrocytes 4,700,000 per c mm On the evening of the operation the temperature rose to 101° F and once again the urine was found to contain large amounts of haemoglobin, which persisted throughout the next day and night Tho patient died within 48 hours of the operation Permission for a post-mortem examination was refused Although the specific serological reaction was not performed on this patient, she was almost certainly an example of the Marchiafava Micheli syndrome, in that haemolytic anaemia, hepato-splenomegaly, a normal red-cell fragility, and bouts of nocturnal haemoglobinuria accentuated by parenteral administration of liver and by blood transfusion permit of no other diagnosis

Case 3 A male child aged 3 years 8 months was first admitted to the Middlesex Hospital under the care of Dr. Monerieff on June 7, 1936, with a history of 'the passage of dark urine since midnight the previous night' There was no family history of similar trouble The parents were both well and their Wassermann reactions negative The patient had not had previous illnesses The dark urine was first passed at midnight on June 6–7 without apparent pain, though the child was irritable for several hours afterwards. He had been given a box of chemicals at the previous Christmas, but contact with known haemolytic agents was not established When first seen the urine did not reveal any abnormality, whilst examination showed a normally built intelligent boy whose liver was just palpable Other abnormalities were not detected

Investigations. The night specimen of urine was very dark coloured and contained amorphous urates with an occasional red cell, the guaiacum test was strongly positive, and spectroscopic examination showed the presence of oxyhaemoglobin X-rays of the urinary tract did not reveal opaque calculi The haemoglobin was 6 16 gm per 100 c c , erythrocytes 1,920,000 per c mm , and mean corpuscular haemoglobin 30 5 $\gamma\gamma$ Films showed polychromasia and basophil punctation The total leucocytes were 13,500 per c mm , with neutrophils 7,300 per c mm , lymphocytes 5,400 per c mm , monocytes 675 per c.mm , and myelocytes 135 per c mm The platelets appeared normal in the film The Price-Jones curve showed slight microcytosis with a mean cell diameter of 6 68 μ

Progress On the following day haemoglobin was still present in the urine The patient looked ill and had slight fever The haemoglobinuria persisted throughout the 24 hours, but was greatest during the night A blood transfusion of 300 c c was given Three days later the haematological condition had improved, the haemoglobin then being 8 4 gm per 100 c c and the erythrocytes 2,510,000 per c mm The urine still contained haemoglobin which persisted till the following day The red-cell fragility was normal, the Wassermann reaction negative, and the Donath–Landsteiner reaction negative The patient improved rapidly on iron and ammonium citrate gr 10 thrice daily, and was discharged on January 25 with a blood count of haemoglobin 9 7 gm per 100 c c , erythrocytes 2,890,000 per c mm , and reticulocytes 7 5 per cent He was re-admitted to the Middlesex Hospital six years later having had another bout of haemoglobinuria which had commenced three days before admission There had been no other attacks since the original one and there had been no exposure to cold during the previous days Only the night specimens had been dark coloured Physical examination on admission showed a few enlarged lymphnodes in the neck and a palpable liver A blood count showed haemoglobin 13 7 gm per 100 c c and erythrocytes 4,700,000 per c mm A specimen of urine taken on the day of admission showed occasional red and white cells only, and no haemoglobin spectroscopically However, in the specimen passed the following morning there was a large amount of haemoglobin The haemoglobinuria continued for two more nights, the day specimens being free of pigment The red-cell fragility was normal and the Donath–Landsteiner reaction negative The Ham serological test for paroxysmal nocturnal haemoglobinuria was positive The patient was discharged well two weeks after admission and has not returned. It has not been possible to trace him since This is a very mild case of serologically proved Marchiafava Micheli syndrome The patient is the youngest case so far reported

Aetiology

Nocturnal haemoglobinuria is neither hereditary nor racial, nor is it related to occupation Male and female patients are affected equally The disease may

begin at any age, but is most common between 20 and 40 years Three cases in childhood have been recorded (Pierce and Aldrich, 1943, Dacie and Gilpin, 1944, and the third case of the present report) The average age of onset in the series here reviewed was 28 years for male and 30 years for female patients

Symptomatology

The disease does not always present primarily with haemoglobinuria, for other symptoms may be much more prominent In some patients this feature has not appeared for years after other haemolytic manifestations have been noticeable The presenting symptoms in the 73 cases recorded were

Haemoglobinuria	33 cases	Anaemia, or dependent symptoms	36 cases.
Jaundice	27 ,,	Abdominal pain	5 ,,
Lumbar pain	7 ,,	Splenomegaly	2 ,,

It is clear therefore that in haemolytic anaemia the absence of haemoglobinuria does not exclude the Marchiafava Micheli syndrome When the disease presents with haemoglobinuria there may be long intervals of freedom, sometimes lasting years, though with such intermittent types the haemoglobinuria is usually strictly nocturnal It is therefore advisable to include the specific serological test in the investigation of any obscure haemolytic anaemia, irrespective of the presence of haemoglobinuria In text-books, descriptions of the condition commonly concern only the later phases of the disease, when periods of haemoglobinuria are accompanied by the typical haemolytic crises, jaundice, and pallor These crises are often associated with pain in the right hypochondrium and with the lumbar pain so commonly found with haemoglobinuria During the later stages of the disease crises tend to become more frequent and the haemoglobinuria eventually persists throughout the 24 hours Crises are often associated with minor infections of the upper respiratory tract, whereas infections elsewhere, in strong contrast, usually produce no exacerbation This is particularly the case with acute pyelitis, during which haemoglobinuria usually clears The reason for this is unknown During the late stages, bouts of abdominal pain may so dominate the picture that appendicectomy and cholecystectomy have been performed (Chauffard and Troisier, 1908, Marchiafava and Nazari, 1911, Bergmark, 1931, Brulé, Hillemand, and Gaube, 1938) The situation of the pain, which is accentuated by fatty foods, suggests a biliary origin, and indeed is probably related to the excess production of biliary pigments from the haemolysis Cholecystograms have usually shown a poorly filling gall-bladder, but biliary stones have rarely been found Icterus is moderate, though the skin has a peculiar dark colour despite the anaemia The mucous membranes are very pale, and are not pigmented There is usually a moderate degree of hepatomegaly and splenomegaly The spleen was reported as being enlarged in 50 per cent of the cases and the liver in 60 per cent The liver and spleen both tend to be enlarged in the later stages of the disease and often reach the umbilicus terminally, enlargement may also occur acutely during the haemolytic crises The size of the liver and spleen gives no indication of the immediate or ultimate prognosis

Complications

The main complications are thrombosis, which may occur in many parts of the body and is discussed more fully in the section on pathology, there are three reports of hemiplegia (Manchester, 1945, Pierce and Aldrich, 1943, Arndal, 1940), biliary colic, pyelonephritis; and intercurrent infection by reason of the chronic anaemia and granulocytopoenia The last is not uncommon and is often terminal

Pathology

The cause of the disease is unknown The main contributions to knowledge have been made by Ham (1937), Jordan (1938), Dacie, Israëls, and Wilkinson (1938), Ham (1939), Ham and Dingle (1939), Ham and Horack (1941), Hoffman and Kracke (1943 *a*, *b*), Dacie and Firth (1943), and Dacie and Richardson (1943)

Inherent abnormality The primary fault appears to be in the erythrocytes, there being no evidence of inherent abnormality in the serum Autogenous cells are haemolysed by autogenous serum and by normal serum to the same extent, whilst autogenous serum does not haemolyse normal red cells Previous exposure to cold is not necessary to initiate haemolysis The red-cell sensitization test (Coombs, Mourant, and Race, 1946) has been reported to be negative in this disorder (Hickey and Malley, 1948)

Effect of acid-base reaction on the degree of haemolysis The haemolytic reaction is sensitive to changes in pH within the range of changes which may occur in the body Van den Bergh (1911), Dacie, Israëls, and Wilkinson (1938), Jordan (1938), Arndal (1940), and Brendstrup (1941) have demonstrated increased haemolysis in the presence of carbon dioxide Dacie and Richardson (1943) found that the haemolysis was inhibited above pH 8, rose to a maximum about pH 7 2, and fell again to zero at pH 6 2, the whole curve being symmetrical. The effect did not depend entirely on pH, since the degree of haemolysis varied with different acids, thus, for the same pH change, carbon dioxide caused greater haemolysis than hydrochloric acid (Hegglin and Maier, 1941, Brendstrup, 1941)

Relation of the serum haemolysin to complement The haemolysin is thermolabile, and heated serum will inactivate normal serum (Ham and Dingle, 1939, Dacie, Israëls, and Wilkinson, 1938, Hickey and Malley, 1948) The addition of guinea-pig serum increases the degree of haemolysis by normal serum over the same pH range, but guinea-pig serum fails to reactivate heated serum (Dacie and Richardson, 1943) Ham and Dingle (1939) suggested that the haemolytic factor is very similar to, but not identical with, complement

Theories for the nocturnal character of the haemoglobinuria The haemolysis increases greatly during normal sleep whatever the time of day Case 1, for example, for a period was kept awake all night and slept during the day There was then no nocturnal haemoglobinuria, but haemoglobin was passed in the urine during the period of daytime sleep (Fig 2) The haemolysis is not due to the reduction in food intake during sleep, for continuous gastric feeding

does not change the intensity of the haemoglobinuria. Most authorities assume, but have never proved, that during sleep there is a change in the serum rather than in the red cells Cells and serum from blood samples taken from Case 1 during waking and sleeping periods were separated as soon as possible after withdrawal, air being excluded with paraffin The blood samples were then reconstituted and incubated Unfortunately, the degree of haemolysis was great in all the tubes, and with the means of haemoglobin estimation available no significant difference could be found. An increase in the blood acidity during sleep has been suggested as the salient feature of the disease, although the evidence is contradictory Hoffman and Kracke (1943 *a*) found the blood in patients to be more alkaline when asleep than awake, and Ham (1939) found no change in arterial blood pH In normal subjects, Collip (1920) found no change or a slight decrease in alkali reserve, Hastings (1939) a decrease in blood pH during sleep, and Kunze (1928) an increase in blood acidity, Endres (1923), Bass and Herr (1922), and Gollwitzer-Meier and Kroetz (1924) found the alkali reserve of the blood unchanged, although the alveolar carbon dioxide tension rose considerably Hoffman and Kracke (1943 *a*) believed that the changes in blood pH may be greater in deeper parts of the body including the spleen, and attributed the reported abatement of the nocturnal character of the haemoglobinuria following splenectomy to this

Changes in blood and urine chemistry during sleep Gollwitzer-Meier and Kroetz (1924) found a decrease in protein, no change in bicarbonate, potassium, and calcium, and an increase in chlorides, phosphates, and sodium salts in the blood Haldane, Wigglesworth, and Woodrow (1924) confirmed the rise in phosphates, while Demole (1927) found a decrease in blood calcium, and Heilig and Hoff (1925) detected an increase in the calcium level. Campbell and Webster (1921, 1922), Kleitman and Kroetz (1926), Kleitman (1923, 1925), Simpson (1924), Wordell (1924), and Fontès and Yovanovitch (1923) showed that there was an increase in urinary acidity, ammonia excretion, and phosphate excretion, though urinary chlorides were diminished during sleep These urinary changes may reflect as yet undetected blood changes occurring during sleep

Haemolysis *in vitro* is inhibited by sodium citrate 1 to 3 mg per c c , potassium oxalate 2 to 8 mg per c c , potassium cyanide 1 3 mg per c c , heparin 0 2 to 0 8 mg per c c , and 'liquoid' 0 1 mg per c c (Dacie and Richardson, 1943 , Ham, 1939) A change in the concentration of these substances in the plasma in the body might have a similar influence on the degree of haemolysis Changes in the concentration of many of the ions found to have an effect *in vitro* are present during sleep, and these changes rather than pH changes may be the salient factor in the increased haemolysis during sleep

Brendstrup's hypothesis of the primary cause Haemolytic crises are commonly associated with upper respiratory tract infection, and Brendstrup (1941), who noted a reduction in haemolysis after tonsillectomy, suggested that antibodies formed against the bacterial products of focal sepsis sensitize the erythrocytes to haemolysins normally present in the serum Unfortunately he did not specify the organism present in the tonsils

Haematology and chemical pathology There is usually a macrocytic normochromic anaemia (haemoglobin usually 5 to 8 gm per 100 c c), with moderate anisocytosis and poikilocytosis, a marked neutropenia, and thrombocytopenia The red cell fragility in hypotonic saline is within the normal range or only slightly increased. During the phases of active haemolysis there is a rise in serum-bilirubin with a positive indirect van den Bergh reaction The rise in bilirubin probably results from red-cell breakdown, rather than circulation of free haemoglobin in the plasma (Bushby, Kekwick, Marriott, and Whitby, 1940) Oxyhaemoglobin and methaemalbumin are present in the serum Plasma proteins, urea, non-protein nitrogen, potassium, sodium, sugar, creatine, calcium, chlorides, and cholesterol are normal The kidney function and renal blood flow are normal (Bradley, 1945) During the crises the urine contains oxyhaemoglobin and sometimes methaemoglobin, either during periods of sleep only, or during the whole day with nocturnal accentuation Urinary crystals containing haemosiderin are often found in the urine between the crises

Morbid Anatomy

Sixteen post-mortem examinations have been reported (Marchiafava and Nazari, 1911, Biffis, 1915, Sisto, 1915, Panton, Maitland-Jones, and Riddoch, 1924, Salén, 1927; Enneking, 1928, Barta and Görög, 1929, Marchiafava, 1931, Micheli, 1931, Bergmark, 1931, Eastwood and Smyth, 1932, Witts, 1936, Scott, Robb-Smith, and Scowen, 1938, Ham, 1939, Arndal, 1940, Ham and Horack, 1941, Flynn, 1945). In a further 10 cases there has been a report on the spleen removed at operation (Lasch, 1931, Rosenthal, 1932, Schally, 1935, Hamburger and Bernstein, 1936, Cain, Catton, Harrispe, and van den Bosjen, 1937, Israëls and Wilkinson, 1938, Ham, 1939, Pierce and Aldrich, 1943; Dacie and Gilpin, 1944) The main features in the morbid anatomy have been as follows.

Thrombosis. Thrombosis in various parts of the body has been found in 10 post-mortem examinations, while effects of thrombosis, such as hemiplegia, have also been noted during life No one site appears to be more prone to thrombosis than any other. Thrombosis has been the direct cause of death in at least one patient (Enneking, 1928) Two explanations could account for the frequency of thrombosis, firstly that there is a roughening of the vessel intima, but no evidence of roughening of the intima has been found in any of the vessels when sectioned, while the intravenous injection of pure haemoglobin does not cause thrombosis, and secondly that the thrombus is formed round a nidus of red-cell stroma in the lumen of the vessels The latter appears the more probable theory and suggests that in the Marchiafava Micheli syndrome cell breakdown occurs in the circulating blood, furthermore, since thrombosis is found in any vessel in the body, haemolysis probably occurs equally throughout the vascular bed

Lungs There has often been oedema of the lungs with hyaline thrombi in the capillaries A pleural effusion has been a common finding

Liver The size has been normal in 40 per cent In the abnormal cases the average weight has been 2,100 gm , the largest liver weighing 2,500 gm The

liver has usually shown central zonal necrosis with thrombosis of small portal veins, congestion of the central veins, and commonly hyperplasia of the Kupffer cells which may contain haemoglobin derivatives Free iron is not usually present Similar changes have been produced experimentally in dogs and rabbits (Pearce, 1904, Stephens, 1937, DeGowin, Warner, and Randall, 1938) by the intravenous injection of haemoglobin, and have followed mismatched blood transfusion in human beings (Lemke, 1925, Lindau, 1928, Bordley, 1931, Goldring and Graef, 1936, Terplan and Javert, 1936)

Spleen The size of the spleen has been normal in 50 per cent In the remainder the average weight has been 375 gm with the largest 840 gm The spleen has shown hyperplasia of the endothelial tissues and congestion of the pulp, normal Malpighian corpuscles, and no free iron

Kidneys The kidneys were usually enlarged, with scars of old infarcts, and invariably an extreme siderosis of the convoluted tubules Similar changes have been found in dogs after intravenous injections of haemoglobin (Stephens 1937, DeGowin, Warner, and Randall, 1938) and in human beings after mismatched blood transfusions (Lindau, 1928, Witts, 1929, Bordley, 1931, Terplan and Javert, 1936)

The bone-marrow has shown a moderate degree of normoblastic hyperplasia

The Haemoglobinuria

Lichty, Havill, and Whipple (1932), DeGowin, Warner, and Randall (1938), and Monke and Yuile (1940), by the intravenous injection of haemoglobin in dogs, found that the renal threshold could be gradually reduced to a lower value by keeping the blood levels continuously above the renal threshold Gilligan, Altschule, and Katersky (1941) also found that when haemoglobin was injected into normal human beings there was an initial threshold of 130 to 150 mg per 100 c c before haemoglobinuria occurred, but that as the plasma level fell later to a level of 30 to 50 mg per 100 c c the haemoglobinuria persisted These facts may explain why Ham (1939) could find no constant threshold for haemoglobinuria Yuile (1942) concluded that haemoglobin is excreted in exactly the same manner as other substances and that tubular haemosiderosis occurs during reabsorption Baker and Dodds (1925) showed in rabbits injected with haemoglobin that precipitation of excreted haemoglobin was reduced by decreasing the concentration of sodium chloride and raising the pH above 6 They noted, however, that precipitation did not occur to any great degree in paroxysmal haemoglobinuria

Treatment

No cure has been reported and no treatment has so far been found that gives lasting improvement Many forms of treatment have been tried and the following have been found to give temporary benefit in individual cases The periodicity of the disease renders assessment of any therapeutic procedure difficult

Blood transfusions and other measures to combat anaemia The bone-marrow

needs adequate amounts of iron and haematinic principle to replace the continuous severe loss of red cells Although both liver and iron occasionally produce exacerbation of the condition (Sega, 1938; Valke and van den Bergh, 1930, Hickey and Malley, 1948), they should be given in full therapeutic dosage throughout the course of the disease Blood-transfusion often produces a temporary exacerbation of the haemoglobinuria due possibly to a haemolysin in the plasma Recently Dacie (1948), using transfusions of washed red cells, raised the haemoglobin level of two patients to normal without temporary exacerbation, and produced a remission in the haemoglobinuria for five weeks Transfusion should, however, be reserved for severe haemolytic crises

Administration of alkalies in an attempt to change the blood pH Ham (1939) found an improvement, Buell and Mettier (1941) found an exacerbation, and Arndal (1940) no improvement after alkalies Case 1 of the present series did not improve on alkalies

Animal sera Griffin (1923) found improvement after injection of ox and horse serum, but Brendstrup (1941) could not confirm this Hickey and Malley (1948) found that a transfusion of heated serum stopped the haemoglobinuria for a period of 36 hours

Administration of ammonium chloride Arndal (1940) and Brendstrup (1941) have reported benefit after ammonium chloride therapy, although *in vitro* haemolysis is increased in acid serum

Parasympathomimetic drugs and adrenal extracts Hess (1929, 1932) suggested that sleep was a parasympathetic function Since haemolysis increases during sleep, Hoffman and Kracke (1943 *a*) tried the effect of natural epinephrine and found a decrease in the haemolysis Synthetic epinephrine was ineffective Parasympathomimetic drugs were therefore tried, and a decrease of haemoglobinuria for 24 hours after an injection of Prostigmine (1 c c of 1 in 400 solution at 9 p m and 3 a m), eserine (0 7 mg at 9 p m and 3 a m), and pilocarpine 3 mg was found In Case 1 (Fig 3) pilocarpine nitrate gr 1/10 (6 mg) at 8 p.m and 2 a m was effective in clearing the haemoglobinuria, but owing to undesirable side effects, had to be discontinued Although the reason for this improvement is unknown, parasympathomimetic drugs seem worthy of further trial

'Focal sepsis ' Brendstrup (1941) recommended removal of foci of sepsis during a remission, in view of the exacerbation of haemolysis associated with infection

Hyperventilation Ham (1939) produced a decrease in haemoglobinuria by artificial hyperventilation in a Drinker apparatus during sleep

Substances which have no effect on the condition are yeast, desiccated hog's stomach, Coagulen Ciba, potassium iodide, arsenic, calcium, peptone shock, many forms of antisyphilitic treatment, olive oil, autolysed yeast, high fluid intake at night, anti-malaria therapy, ascorbic acid, ultra-violet light, and continuous glucose feeding Intravenous ascorbic acid (Ham, 1939) and an inoculation with typhoid vaccine (Scott, Robb-Smith, and Scowen, 1938) have produced an exacerbation.

Course and Prognosis

The disease is characterized by crises and remissions with a downhill course Twenty-one of the recorded patients were dead (the average duration of life from the time of onset to death was 6 6 years) Eleven died as the result of operation, six died from other apparently unrelated diseases, and four deaths may be attributed directly to the Marchiafava Micheli syndrome Of the 52 living patients recorded, the report was made on an average six years after the onset of symptoms Rosenthal's (1932) patient died as the result of splenectomy 33 years after the onset of symptoms, and 13 of the patients lived for more than 10 years The expectation of life after the onset is thus about seven to 10 years Splenectomy seems to be contra-indicated Seven patients have died as a direct result of the operation, one death was probably accelerated by the operation, one died from a different and unrelated disease, 10 who survived the operation showed no change in their condition, clinically or serologically Thus, there is an immediate mortality rate of 40 per cent from the operation, whilst no one who has survived has been cured or demonstrably improved

Diagnosis

Two specific tests for the Marchiafava Micheli syndrome are now available, and in view of the diverse clinical features of the disorder at the onset and later in its course these tests should be performed in the diagnosis of this and any obscure haemolytic anaemia

The acid serum haemolysis test (*Ham, 1939*) Venous blood obtained without haemostasis from the patient and a normal control of the same blood group is defibrinated with glass beads The cells are separated and washed three times in saline, and 5 per cent suspensions in saline of each are made One c c samples of the test cell suspension, and 1 c c samples of the control cell suspension are measured into each of eight tubes and are centrifuged. The supernatant saline is removed and discarded To the first tube of the test and control series is added 1 c c of the test serum, to the second of each 1 c c of the control serum, to the third 0 95 c c of test serum and 0 05 c c of one-third normal hydrochloric acid, and to the fourth 0 95 c c of normal serum plus 0 05 c c of one-third normal hydrochloric acid The contents of the tubes are then mixed thoroughly, incubated at 37° C for one hour, then centrifuged, and finally examined for haemolysis None of the tubes containing normal cells should show haemolysis In a positive test all the tubes containing the patient's cells will show haemolysis, which is moderate with unacidified patient's serum or control serum and marked in the tubes to which acid has been added

The heat test of Hegglin and Maier (*1941, 1944*) Five c c of the patient's blood in a clean, dry tube under paraffin is allowed to clot in the incubator at 37° C , and the degree of haemolysis measured at six and 24 hours by any convenient method In the Marchiafava Micheli syndrome the degree of haemolysis at six hours exceeds 500 mg of haemoglobin per 100 c c of blood Normal cells

show hardly any haemolysis, whilst the maximum in other haemolytic disorders is less than 100 mg and usually below 50 mg per 100 c c

The following haemolytic disorders may give difficulty in diagnosis if the specific test for the syndrome is not performed, for in the early stages it may simulate any haemolytic disease congenital haemolytic anaemia (acholuric jaundice), syphilitic paroxysmal haemoglobinuria, march haemoglobinuria, acute idiopathic haemolytic anaemia (Lederer), transfusion of incompatible blood, and toxaemia due to various poisons Mackenzie (1929) has reviewed the chemical substances that may cause a haemolytic anaemia of sufficient severity to cause a haemoglobinuria

Summary

1 Three cases of the Marchiafava Micheli syndrome are reported in detail, bringing the total number of patients reported to 76 A review of the literature is given

2 The disease is not hereditary, and is characterized by a haemolytic anaemia with bouts of haemoglobinuria occurring mainly while the patient sleeps The primary abnormality lies in the red cells, which undergo lysis by a thermolabile fraction of normal serum The haemolysis is sensitive to changes in pH, and may be inhibited *in vitro* by the presence in the plasma of the following substances sodium citrate, potassium oxalate, potassium cyanide, and heparin The concentration of the ions of some of these substances changes during sleep, and these changes rather than pH changes may be responsible for the nocturnal character of the haemoglobinuria

3 No cure for the disease is known, but the value of pilocarpine nitrate reported by some authors has, in our experience, been confirmed The course is irregularly downhill over a period of about seven to 10 years, with death usually from intercurrent infection Splenectomy is contra-indicated, the operation has a mortality of 40 per cent and has never been reported as effecting a cure

4 Since at the onset the disease may present as a haemolytic anaemia without haemoglobinuria, the necessity of performing the specific serological tests for this disease in any obscure haemolytic anaemia irrespective of the presence of haemoglobinuria is stressed, and the two tests available are described in detail

I wish to express my thanks to Sir Lionel Whitby for his very valuable help in the preparation of this review, to Professor R Scarff for permission to publish the results of investigations carried out in the Bland-Sutton Institute of Pathology, and to Dr G E Beaumont, Sir Gordon Gordon-Taylor, and Professor A A Monerieff for permission to publish details of their cases The work was done during the tenure of an Elmore Research Studentship

REFERENCES

Alzona, L , and Viale, L (1946) *Arch E Maragliano pat e clin* **1**, 160
Arndal, P (1940) *Ugesk f laeger*, **102**, 115
Baker, S L , and Dodds, E C (1925) *Brit J Exp Path* **6**, 247
Barta, I , and Görög, D (1929) *Virch Arch f path Anat* **273**, 266
Bass, E , and Herr, K (1922) *Ztschr f Biol* **75**, 279
Bergmark, G (1931) *Acta med Scand* **77**, 224
—— (1932) *Svenska läk tidning* **29**, 119
Biffis, P (1915) *Riforma med* **31**, 11, 42, 64, 95
Bordley, J (1931) *Arch int Med* **47**, 288
Bradley, S E (1945) Quoted as personal communication by Ross (1945)
Brendstrup, P (1941) *Ugesk f laeger*, **103**, 938
Brule, M , Hillemand, P , and Gaube, R (1937) *Bull et Mém Soc méd d hôp de Paris*, **53**, 197
—— —— —— (1938) *Presse méd* **46**, 1329
Buell, A , and Mettier, S R (1941) *J Lab and Clin Med* **26**, 1434
Bushby, S R M , Kekwick, A , Marriott, H L , and Whitby, L E H (1940) *Lancet*, **2**, 414
Cain, A , Catton, R , Harrispe, J V , and van den Boijen, G B (1937) *Bull et Mém Soc méd d hôp de Paris*, **53**, 70
Calabresi, M (1937) *La Malattia di Marchiafava–Micheli Anemia emolitica*, Messina
Campbell, J A , and Webster, T A (1921) *Biochem J* **15**, 660
—— —— (1922) *Ibid* **16**, 507
Casolo, G , and de Colle, U (1939) *Gazz de Osp* **60**, 642
Chauffard, A., and Troisier, J (1908) *Bull et Mém Soc méd d hôp de Paris*, **24**, 411
Collip, J B (1920) *J Biol Chem* **41**, 473
Coombs, R R A , Mourant, A E , and Race, R R (1946) *Lancet*, **1**, 264
Dacie, J V (1948) Personal communication
—— and Firth, D (1943) *Brit Med J* **1**, 626
—— and Gilpin, A (1944) *Arch Dis in Child* **19**, 155
—— Israëls, M C G , and Wilkinson, J F (1938) *Lancet*, **1**, 479
—— and Richardson, N (1943) *J Path and Bact* **55**, 375
Dameshek, W (1942) *Bull New Eng Med Center*, **4**, 324
DeGowin, E L , Warner, E D , and Randall, W L (1938) *Arch int Med* **61**, 609
De Marval, I , and Bomchil, G (1942) *Semana med* **1**, 401
Demole, V (1927) *Arch f Exper Path u Pharm* **120**, 229
Donati, A (1930) *Folia Clin et Biol* , Number 6
Eastwood, C G , and Smyth, G G E (1932) *Lancet*, **2**, 895
Endres, L (1923) *Biochem Ztschr* **142**, 53
Enneking, J (1928) *Klin Wchschr* **7**, 2045
Falkiowicz, A., and Musial, W (1935) *Ibid* **14**, 1078
Fisher, J A (1947) *Quart J Med* , N S , **16**, 245
Flynn, J E (1945) *J Iowa Med Soc* **35**, 255
Fontès, G , and Yovanovitch, A (1923) *Compt Rend Soc Biol* **88**, 456
—— (1938) *Thèse de Paris* Summary in *Presse méd* **46**, 1602
Gilligan, D R , Altschule, M D , and Katersky, E M (1941) *J Clin Invest* **20**, 177
Goldring, W , and Graef, I (1936) *Arch int Med* **58**, 825
Gollwitzer Meier, K , and Kroetz, C (1924) *Biochem Ztschr* **154**, 82
Griffin, H Z (1923) *Arch int Med* **31**, 573
Haldane, J B S , Wigglesworth, V B , and Woodrow, C E (1924) *Proc Roy Soc Lond* Sect B, **96**, 1
Ham, G C , and Horack, H M (1941) *Arch int Med* **67**, 735
Ham, T H (1937) *New Eng J Med* **217**, 915
—— (1939) *Arch int Med* **64**, 1271

Ham, T H., and Dingle, J H (1939) *J Clin Invest.* 18, 657
Hamburger, L P , and Bernstein, A (1936) *Am J Med Sci* 192, 391
Hastings, A. B (1939) Personal communication quoted by Ham (1939)
Hegglin, R (1942) *Ergebn d Med u Kinderh* 63, 153
—— (1943) *Helvet Med Acta*, 10, 27
—— (1944) *Schweiz med Jahrb* 74, 17
—— and Maier, C (1941) *Klin Wchnschr* 2, 956
—— —— (1944) *Am J Med Sci* 207, 624
Heilig, R , and Hoff, H (1925) *Klin Wchnschr.* 4, 2104
Hess, W R (1929) *Amer J Physiol* 90, 386
—— (1932) *Lancet*, 2, 1199
Hickey, M D , and Malley, L K (1948) *Quart J Med* N S 17, 1
Hitzenberger, R (1931) *Wien med Wchnschr* 81, 1189
Hoffman, B J , and Kracke, R R (1943 *a*) *J Lab Clin Med* 28, 817
—— —— (1943 *b*) *Climes*, 2, 179
Iglauer, K , and St Frenreiser (1934 *a*) *Klin Wchnschr* 13, 889
—— —— (1934 *b*) *Orvosi Hetil* 78, 817
Israëls, M C G , and Wilkinson, J F (1938) *Quart. J Med* N.S 7, 137
Jordan, F L J (1938) *Acta med Scand* 95, 319
Kleitman, N (1923) *Amer J Physiol* 66, 67
—— (1925) *Ibid* 74, 225
—— and Kroetz, C (1926) *Ztschr f d ges exp Med* 52, 770
Kunze, J (1928) *Ibid* 59, 248
Lasch, D (1931) *Wien med Wchnschr* 81, 1505
Lemke, R (1925) *Virch Arch f path Anat* 257, 415
Lichty, J A , Havill, W H , and Whipple, G H (1932) *J exp Med* 55, 603
Lindau, A (1928) *Acta path et microbiol Scand* 5, 382
Lolli, N (1933) *Riforma med* 49, 1313
Mackenzie, G M (1929) *Medicine*, 8, 159
—— (1935) *Clin Misc Mary I Bassett Hosp* 2, 100
Manchester, R C (1945) *Ann int Med* 23, 935
Manini, L (1927) *Gior di clin med* 2, 51
Marchiafava, E (1928) *Policlinico, sez med* 35, 109
—— (1931) *Ibid* 38, 105
—— and Nazari, A (1911) *Ibid* 18, 241
Meyer, A (1946) *Praxis*, 35, 381
Meyer, R (1933) *Inaug Dissert Hamburg*
Micheli, F (1931) *Haematologica*, 12, 101
Milne, J A (1945) *Brit Med J* 2, 84
Monke, J V , and Yuile, C L (1940) *J exp Med* 72, 149
Murray, J (1944) *Nature*, 154, 701
Nazari, A (1931) *Bull e atti d Accad Med di Roma*, 57, 99
Olivarius, B de F (1942) *Nord Med* 15, 2443
Panton, P N , Maitland-Jones, A G , and Riddoch, G (1924) *Lancet*, 1, 529
Pearce, R M (1904) *J Med Res* 12, 329
Pierce, P P , and Aldrich, C A (1943) *J Pediat* 22, 30
Rosenthal, F (1932) *Ztschr f Klin Med* 119, 449
Ross, J F (1945) *New Eng J Med* 233, 732
Salén, E B (1927) *Acta med Scand* 66, 566
Saxl, P (1928) *Wien Ges inn Med*, p 523
Schally, A O (1935) *Ztschr f Klin Med* 127, 697
Scheel, O (1925) *Norsk mag f Laegevidensk*, 86, 248
Scott, R B , Robb-Smith, A. H T , and Scowen, E F (1938) *Quart J Med*, N S 7, 95
Sega, A (1938) *Arch di pat e clin Med* 19, 82
Simpson, G E (1924) *J Biol Chem* 59, 107

Sisto, P (1915) *Policlinico, sez med* **22**, 389
Stephens, J W W (1937) *Blackwater Fever*, Liverpool
Terplan, K L , and Javert, C T (1936) *Journ Amer med Ass* **106**, 529
Trestini, S (1935) *Policlinico, sez med* **42**, 550
Valke, G , and van den Bergh, L (1939) *Ann Soc belge de Méd trop* **19**, 235
van den Bergh, A A H (1911) *Rev de Méd* **31**, 63
Villa, L (1928) *Cuore e circolaz* **12**, 465
Villaret, M , Justin-Besançon, L , Rubens Duval, A , and Sikorav, H (1939) *Bull et mém Soc méd d hôp de Paris*, **55**, 493
Weir, J F (1933) *Proc Staff Meet Mayo Clin* **8**, 110
Witts, L J (1929) *Lancet*, **1**, 1297
—— (1936) *Ibid* **2**, 115
Wordell, H (1924) *Ztschr f d ges exp Med* **42**, 389
Yuile, C L (1942) *Physiological Rev* **22**, 19

616 13-002

THE OCULAR MANIFESTATIONS OF POLYARTERITIS NODOSA[1]

By R N HERSON and R SAMPSON

With Plate 17

Though a wider knowledge of the main clinical features of polyarteritis nodosa is enabling a correct diagnosis to be made during life with increasing frequency, the disease is protean and many difficulties arise Little attention has been drawn to the help which may be obtained by careful and repeated examination of the fundus of the eye Since Sampson (1945) made ophthalmic observations in a case of polyarteritis nodosa, three further cases with similar eye signs have occurred within our knowledge, and in the present communication we shall attempt a review of these four cases

Case Reports

Case 1 An airman, aged 20 years, was admitted to a Royal Air Force hospital on July 7, 1943, with generalized clonic convulsions There was no past history of fits, but during the preceding two months he had had recurrent headaches and aching pains in the abdomen Examination of the chest showed scattered rhonchi There were no abnormal physical signs in the heart and the blood-pressure was 150/100 A patch of oedema was found over the lumbar spine His white blood count was 13,200 per c mm , with a normal differential count The urine contained a trace of albumin The blood Wassermann reaction was negative, and the cerebrospinal fluid normal On July 9 he had further convulsions Thereafter he complained intermittently of pains in the abdomen, muscles, and joints, and showed irregular fever with tachycardia By July 20 the blood-pressure had risen to 180/120, but the systolic reading fell later and varied between 140 and 160 throughout the rest of the illness The blood-urea was 25 mg per 100 c c and the erythrocyte sedimentation rate 22 mm in one hour All other investigations were negative At the end of August a nodule removed from the right biceps was found to be an organized thrombus He was emaciated and his condition had deteriorated The haemoglobin had fallen to 9 9 gm per 100 c c , while the white blood-cells had risen to 15,400 per c mm , still with a normal differential count Early in September he developed nocturnal dyspnoea An apical presystolic gallop rhythm was heard and a teleradiograph showed cardiac enlargement and pulmonary congestion The urine contained a heavy cloud of albumin, a few hyaline and granular casts, and a moderate number of red and white blood-cells The erythrocyte sedimentation rate was 64 mm in one hour On September 15 a series of clonic convulsions occurred, followed by unconsciousness In spite of treatment the pulmonary oedema increased, systemic congestion developed, and he died on October 10 Pathological examination demonstrated polyarteritis nodosa affecting arteries

[1] Received October 29, 1948

in all systems, and particularly the coronary arteries There were infarcts in both kidneys

Ophthalmoscopic examination was made late in the disease, four weeks before death At the first examination of the fundi a large globular retinal detachment of exudative type was seen in the left eye, and several smaller shallow detachments in both eyes There were no intraretinal exudates and no haemorrhages, and the retinal vessels appeared normal An interesting feature was the presence of a number of small yellowish-white nodules beneath areas of greyish oedematous retina in both fundi near and lateral to the maculae Subsequent observations made during the remaining three weeks of life revealed a constantly changing picture, the choroidal nodules gradually being transformed into white, lightly pigmented scars Detachments of the retina appeared in various parts of the fundi and then rapidly became absorbed, the largest in a fortnight Retinal oedema caused blurring of the edges of both disks, and both maculae at one time lost their usual reflexes from the same cause, but just before death the ophthalmoscope did not show any abnormalities other than the white scars in the situation of the choroidal nodules

Histological examination of the eyes, kindly performed by Professor A J Ballantyne, made it clear that wide areas of shallow subretinal exudate still existed *post mortem*. Many of the choroidal vessels had thickened walls, and some had a hyaline character One cicatricial nodule, apparently due to organization of a thrombus in a large vessel, occupied the entire thickness of the choroid The retinal vessels were unaffected except for hyalinization of their walls in the papillae

Comment. The ophthalmic appearances are those of the exudative phase of choroidal arteritis in the absence of albuminuric retinopathy.

Case 2 [2] An airman, aged 31 years, under treatment for syphilis received 5 85 gm of neoarsphenamine and 2 4 gm of bismuth between February and May, 1945 Arsenical treatment was then stopped on account of severe joint pains, but the bismuth was continued During August he was given 0 3 and 0 45 gm of neoarsphenamine, and after the second dose complained of severe epigastric pain, aching in the legs, and fleeting pains in the joints Examination showed that there had been considerable loss of weight and that he was tender in the epigastrium Despite treatment his abdominal pain increased A barium meal, gastric analysis, occult blood tests, and tests for pancreatic function were all negative The cerebrospinal fluid was normal and the erythrocyte sedimentation rate 8 mm in one hour Occasionally his evening temperature rose to 99° F A generalized epileptic fit followed by severe headache and vomiting occurred on September 14, and his blood-pressure was found to be 210/120 Radiological examination of the skull, chest, and abdomen, and blood chemistry were not informative At this time the leucocyte count had risen to 10,000 per c mm and albumin and occasional red and white cells were found in the urine Within a few days the margins of the left optic disk became blurred and a slight haemorrhage appeared in the retina On September 26 a series of epileptic fits were followed by prolonged coma On recovery the knee and ankle reflexes could not be obtained The erythrocyte sedimentation rate was 45 mm in one hour, white blood count 32,000 per c mm , and the differential count normal The hypertension and albuminuria persisted Gross ophthalmoscopic ab

[2] This case was first described by Miller and Nelson in a letter in the *Lancet* of March 23, 1946, and we are indebted to them for permission to follow closely their report of the general clinical features

normalities became evident on October 2 Over large areas of both fundi the characteristic retinal reflex was lost, suggesting shallow subretinal exudation, and in several areas retinal detachments could be seen Here and there, mostly adjacent to the maculae, deep intraretinal exudates and a few haemorrhages in both the superficial and deep layers of the retina appeared, and the disks became blurred by oedema The detachments varied from time to time both in position and extent, an interval of three or four days sufficing to produce a new ophthalmoscopic picture By October 10 there was more evidence of affection of the retina itself, haemorrhages and exudates appeared in the neighbourhood of the vessels, and one very small arterial twig became occluded On October 20 the characteristic picture of an albuminuric retinopathy was established, and the retinal detachments had all but disappeared A diagnosis of polyarteritis nodosa was confirmed by examination of a biopsy specimen of calf muscle Weakness and cachexia became severe and death occurred on October 30

Autopsy showed acute and subacute polyarteritis nodosa involving the kidneys, mesentery, peripheral nerves, and skeletal muscles, but sparing the central nervous system As in Case 1, we are indebted to Professor A J Ballantyne for a report on the pathology of the eyes, and the following are the salient features The retinal changes were similar to those found in renal and hypertensive cases No macular star was seen, but there were granular fatty exudates mostly localized near the macula Subretinal exudate was present in great quantity and resembled the appearance seen in severe retinopathy of pregnancy No changes were seen in the central vessels of the retina In the choroid one vessel was found with a thick hyaline, and probably fatty, wall, and another vessel had its lumen filled with proliferated endothelium

Comment This case corresponded very closely to Case 1 In the early stages subretinal exudates were the most striking feature, whereas the retinal involvement as evidenced by haemorrhages and 'woolly' exudates was much less than is usually found in malignant hypertension or in albuminuria of pregnancy which the retinal detachments call to mind

Case 3 A 35-year-old dock labourer, with no significant past history or family history, began to complain of pain and weakness of the legs in March 1946, and soon became unable to stand About 10 days later he experienced parasthesiae in the right hand, and flexion of the fingers and wrist became feeble After a further three days his left fourth and fifth fingers felt dead and movements of the left hand were weak Slowly other muscle groups in the upper limbs became affected, and his general condition deteriorated He was admitted to Southmead Hospital on May 6, 1946 He was wasted and his skin pigmented The retinal arteries were narrow and the veins slightly dilated The heart size and sounds were normal There was no venous engorgement or hepatic enlargement, and the lungs were clear The blood-pressure was 210/140, the brachial and radial arteries were thickened and tortuous There was severe asymmetrical weakness and wasting of the muscles in all four limbs, and glove and stocking anaesthesia The urine contained a trace of albumin and an excess of urobilinogen, occasional red and white blood-cells and a few hyaline and granular casts were found in the centrifuged sediment A blood count showed red cells 4,670,000 per c mm, haemoglobin 98 per cent, white cells 19,200 per c mm, and a differential count of neutrophils 79 per cent, lymphocytes 16 per cent, monocytes 4 per cent, eosinophils 0 5 per cent, and basophils 0 5 per cent The erythrocyte sedimentation rate was 50 mm in one hour, the blood Wassermann reaction negative, and the cerebrospinal fluid normal The

combination of wasting, tachycardia, leucocytosis, hypertension, red cells and casts in the urinary sediment, and the asymmetry of the weakness and wasting of the muscles of the limbs strongly suggested polyarteritis nodosa From May 7 to June 4 his evening temperature varied between 98 6° and 100° F , thereafter it remained practically normal, although the pulse seldom dropped below 90 and frequently reached 120 The leucocytosis persisted, but eosinophils never formed more than 1 per cent of the total The teleradiograph and electrocardiogram remained normal On May 23 slight generalized adenopathy was found Four days later he complained of blurred vision in the right eye, and retinal oedema and a shallow detachment near the ora serrata were found On June 11 the vision in the left eye was hazy, and the retinal picture resembled that of the right eye The appearance of the fundi on June 18 is shown in Plate 17, Fig 1 Bilateral retinal oedema and exudative detachments involving the lower half of each retina were seen The margins of the disks were blurred and the arteries narrowed A short distance from the disk margin on the lower right temporal artery there was a small swelling surrounded by haemorrhage The vessel beyond this point was extremely narrow Hillocks of white choroidal exudate were seen There were scattered haemorrhages In the lower temporal quadrant of the left fundus a short distance from the disk there was a white scar with pigmented borders and small haemorrhages along its upper and lower edges Mr Anthony Palin confirmed these findings At this time, apart from the visual disturbance, the patient was complaining of backache His skin was dry and scaly and showed increasing pigmentation His legs were very wasted By June 26 the detachment of the left retina had decreased considerably while that in the right had increased It was difficult to make out the nodule on the right lower temporal artery as it had decreased in size and become partially hidden by surrounding oedema Five days later an artery obliterated by clot was seen a short distance from the left disk margin Fresh areas of exudate had appeared in both eyes On July 6 a nodule was found on a branch of the left lower temporal artery with narrowing of the vessel beyond Oedema of the disks and retinae had increased and there were fresh haemorrhages and numerous pigmented choroidal scars By July 11 the periarterial nodule in the right eye could no longer be seen Its position was marked by an almond-shaped area of haemorrhage, and the vessel on which it arose was not visible The nodule in the left eye was partly obscured by a small haemorrhage in and around it, and the vessel beyond it was obliterated Continuous with the nodule there was a large white area of exudate mottled with haemorrhage Some of the previous exudates and haemorrhages had been absorbed and fresh ones had appeared The detachment in the right eye was slightly smaller, and that in the left eye was no longer visible The blood-pressure was 205/130, and the liver just palpable Voluntary flexion of the fingers of the left hand and extension of the left elbow had improved. The urinary sediment still contained a few red blood-cells and hyaline and granular casts The blood-urea was 30 mg per 100 c c , and the urea clearance 71 per cent of normal in the first hour and 51 per cent in the second hour The total serum-protein was 6 68 gm per 100 c c , the albumin–globulin ratio 1 1 08, free cholesterol 71 mg per 100 c c , and cholesterol esters 103 mg per 100 c c On July 17 he was seen again by Mr Anthony Palin who found diffuse multiple haemorrhages and plaques of exudate in both retinae There were patches of arterial thrombosis, and, where the vessel concerned was a large one, there was retinal ischaemia distal to the block The right detachment still ballooned out over most of both inferior quadrants On July 21 he started to vomit after meals and to complain of frequent occipital headaches radiating down the back of the neck These symptoms became pro-

gressively more troublesome By July 29 he was cachectic and very weak. Retinal oedema was marked, and exudates and haemorrhages were scattered profusely over both fundi The left detachment had increased and the right had decreased The blood-pressure was 195/130 On the evening of August 1 he had two epileptiform convulsions After three further fits early in the morning of August 2 he died

Comment As in Case 1 the main ophthalmoscopic findings before the terminal stages were transient retinal detachments and tubercle-like choroidal lesions which disappeared after some days, leaving white pigmented scars In this case direct evidence of arteritis of the retinal vessels, with aneurysm formation on two of them, was obtained

Report of Pathologist (Dr Norman McLetchie) The typical naked-eye appearances of polyarteritis nodosa were present, affecting in descending order of severity the following vessels the mesenteric vessels, the branches of the renal arteries from the pelves of the kidney into the renal substance, the branches of the hepatic artery, the coronary arteries and their branches, and the branches of the splenic artery in the pulp near the hilum The vessel walls between the nodules and in unaffected branches did not show any conspicuous abnormality, and the changes noted in longstanding hypertension in vessels just within the range of naked-eye vision were not present Histologically the small arteries presented a great variety of lesions, including focal destruction of the elastic and muscular coats leading to fibrocellular nodule formation, thromboses, aneurysms, and the formation of cuffs of fibrin in the adventitial region, apparently from the dilated periadventitial capillaries The arterioles, including those in the choroidal coat of the eye, showed focal acute necrotizing lesions, often indistinguishable from those in malignant hypertension In some the vessel was dilated, the wall being necrotic and replaced by a ring of inspissated fibrin, though the intima was still intact In others the lumen was almost obliterated by an oedematous swelling of the vessel wall and fibrin infiltration The affected areas were surrounded by a zone of interstitial oedema, round-cell infiltration, and exceptionally fibrin infiltration A few thrombotic lesions of small veins were found, with distension and destruction of the walls These were encountered in the boundary zone of the kidney, the portal tracts, and the choroidal coat of the eye They were exceptional relative to the arterial damage

Right eye Only the posterior half could be examined In addition to a gross retinal detachment there was extensive oedema of the choroid with fibrin deposition in the interstitium and in the chorio-capillary bed In the sections examined, one arteriole of the choroid showed a nodular expansion consisting of great dilatation of the lumen which was empty of blood, and complete fibrin infiltration of the wall (Plate 17, Fig 2) The vessel was surrounded by a zone of oedema, round-cell infiltration, and fibrin deposition with foci of necrosis At the same level a lesion of similar type was present in a venule There was also a layer of fibrin outside the layer of rods and cones In the retina there were numerous small foci of fibrinous exudate and a few small focal haemorrhages Some venules were dilated and surrounded by oedema and round-cell infiltration In the many sections examined no nodular lesions were found in the retinal vessels corresponding with those seen in life

Comment The pathological changes were thus those of polyarteritis nodosa A remarkable feature, considering the extensive involvement of vessels in an

obliterating or near-obliterating process, is the absence, except for small recent areas in the spleen, of infarction No doubt this was due to an extensive development of collateral channels Such a process would require time to develop Secondary to this, hypertension had supervened with a malignant termination. While the nodular lesions of small arteries properly belong to the morbid process of polyarteritis nodosa, many of the acute lesions in small vessels are not to be distinguished from those of malignant hypertension, though it is probable that the one shown in Plate 17, Fig 2, belongs in part to the polyarteritis nodosa process since the intima is still intact despite the severity of the lesion

Case 4 An airman, aged 24 years, was admitted to Snowdon Road Hospital on January 1, 1947 After the detection of seropositive asymptomatic syphilis 11 months previously, he had been given 2 4 mega units of penicillin in seven days, and then over a period of 12 months 5 58 gm of neoarsphenamine and 2 0 gm of bismuth No further treatment was given until November 29 Between that date and December 18 he received 0 36 gm of mapharside and 2 4 gm of bismuth Two weeks after the second course of organic arsenic and bismuth he complained of loss of appetite and pain in the right hypochondrium and epigastrium His temperature was found to be 101 1° F and he was admitted to hospital He was then very thin, having lost four stone in the preceding seven months He was not jaundiced, but the liver was just palpable and tender There was a gradual improvement, and by January 25 he was getting up On February 6 he had a small haemoptysis At 12 10 a m on the following day he complained of dyspnoea and severe pain in the precordial region On examination he was pale and sweating The neck veins were distended, the apex beat was diffuse and not easily detected, and the cardiac dullness was increased to the left Pulsation could be felt in the second left space near the sternum, the heart was beating regularly at the rate of 136 a minute, gallop rhythm was audible at the apex, the pulmonary second sound was accentuated, and all over the praecordium there was a continuous friction rub The blood-pressure was 150/115, and alternation of the pulse was present There was dullness at the right lung base with diminished air entry, and crepitations were heard over both lower lobes The liver was enlarged and tender The urine contained albumin, and red cells and casts were seen in moderate numbers in the centrifuged deposit The leucocytes numbered 16,300 per c mm , of which 83 per cent were neutrophils, 10 per cent lymphocytes, 6 per cent monocytes, and 1 per cent eosinophils The blood-urea was 54 mg per 100 c c and the Wassermann reaction of the blood strongly positive The cerebrospinal fluid was normal and not under increased pressure The pain in the chest gradually passed off On February 13 patches of erythema developed on both hypothenar eminences, but no nodules could be found The fundi were examined by Mr Ramsey Garden on February 16, the edge of the right optic disk was blurred and a haemorrhage was situated near its margin, the retinal arteries were extremely narrow A whitish sheath of these vessels near their origin was considered possibly to be a congenital peculiarity Towards the periphery of both fundi numerous old choroidal pigmentary changes were seen A week later both disks were much congested and the edges blurred There was no measurable swelling of the disks beyond about 1 5 diopters Haemorrhages were seen near the right disk In both eyes there were many scattered rounded patches of yellowish-white colour with indefinite edges, suggesting active areas of choroiditis The friction rub disappeared and the areas of erythema faded,

but the signs of heart failure increased in spite of treatment with digitalis The eyes were re-examined on March 2 There was severe papilloedema and oedema of the retina The pigmentary deposits were more evident In the lower part of the fundus of the right eye near the periphery there was a small area of retinal detachment and in the lower part of the left eye there were two large retinal detachments The patient did not complain of his sight By March 9 the patient was wasted and weak, the skin was pigmented and sweated excessively The apex beat could be felt in the anterior axillary line and an X-ray confirmed gross cardiac enlargement Gallop rhythm and pulsus alternans were present, and the signs of pulmonary and venous congestion had increased The blood-pressure was 170/140 The reflexes were normal The leucocytes numbered 21,200 per c mm When Mr Garden again saw the fundi on March 16 the detachments had practically disappeared Many of the exudates had been absorbed and replaced by coarse deposits of pigment, no fresh exudates had appeared Macular pigmentary changes were seen Oedema steadily increased and by March 25 was massive At this time he was very weak and drowsy The leucocytes numbered 13,000 per c mm with neutrophils 71 per cent, eosinophils 2 per cent, lymphocytes 26 per cent, and monocytes 1 per cent The blood-urea was 62 mg per 100 c c The total serum-protein was 5 01 gm per 100 c c, of which 1 21 gm per 100 c c was albumin and 3 36 gm per 100 c c was globulin Albumin, red cells, and casts were still found in the urine, and urobilinogen was present in a dilution of 1 in 90, as estimated by the method of Wallace and Diamond The fundal appearances were unchanged The pulse ranged between 90 and 120 per minute, but except for a very occasional rise of temperature to 100° F he was afebrile On April 11 papilloedema was noted to be subsiding Generalized fits began to occur and he died at the end of the month Pathological examination showed polyarteritis nodosa in all organs Unfortunately the eyes were not examined

Comment Again the main ophthalmoscopic findings were transient retinal detachments and choroidal lesions which ended in the formation of pigmented scars

Discussion

The ophthalmoscopic signs in all four cases began with blurring of the edges of the disk and one or two small haemorrhages adjacent to it Soon afterwards wide areas of retinal oedema appeared and detachments of the retina of various sizes occurred, with a tendency to spontaneous recovery, sometimes in less than two weeks The fluctuating nature of these exudative detachments can be correlated with the known transient nature of the localized areas of oedema in other situations In three of the cases nodules of choroiditis were found, soon progressing to scar formation In Case 3 the retinal arteries were directly affected by the polyarteritic process, and it was possible to observe as they occurred the typical sequence of arteritis, obstruction of the lumen, aneurysmal dilatation, and scar formation Unfortunately none of the pathologist's sections happened to pass through the affected retinal vessel In two of our cases the choroidal nature of the ophthalmoscopic picture became obscured and almost obliterated by the retinal changes associated with malignant hypertension, which are the ocular signs most commonly described in the recorded cases of polyarteritis nodosa

An exact correlation of the ophthalmoscopic and histological appearances is rendered difficult by the scarring of the nodules of choroiditis before death in all our cases, and the only confirmation that we were indeed observing choroidal polyarteritis is the repeated discovery of late lesions of the choroidal vessels Clinically, however, the picture we have described is exactly what we should expect to see during the acute stages of these lesions, and their occurrence at any time in the course of an illness presenting so many diagnostic problems should be of great value to the physician While nodules of choroiditis and retinal detachments occur in other diseases, their rapid onset and retrogression and changing location over the fundi are features which appear to be characteristic of polyarteritis nodosa It is their clinical course rather than their presence which is most suggestive, and necessitates close observation over a period of weeks

The fundus may be affected in polyarteritis nodosa either indirectly by the effects of hypertension or directly by the involvement of the choroidal and retinal vessels There are but few published cases where more than the ordinary hypertensive retinopathy has been seen, in spite of the frequent reports by pathologists of polyarteritis of the choroidal vessels Böck (1932) reported having seen progressive total detachments attributed to choroidal polyarteritis which became re-attached spontaneously with improvement in the general condition In Goldstein and Wexler's (1937) case there was bilateral optic atrophy, with considerable pigmentary disturbance, which at autopsy was found to be the result of involvement of the ciliary and choroidal vessels Occlusion of the central retinal artery has been seen once (Bernstein, 1935) The only report we have been able to trace of aneurysm formation on a retinal artery observed ophthalmoscopically is that of Goldsmith (1946) In this case there is no reference to the clinical observation of choroidal polyarteritis, although the pathologist found the choroid irregularly thickened by inflammatory vascular changes and the retina partially detached with serous exudate beneath It has been our experience that more subretinal exudate has been found by the pathologist than was suspected from clinical observation, the fluid may be so widespread and shallow that the ophthalmoscope does not readily detect it Its presence, however, can be suspected from a peculiar loss of the choroidal reflex.

Until the fundi are thoroughly examined with the pupil dilated in a sufficiently large series of cases, it would be idle to speculate on the frequency of the ocular signs of direct involvement of vessels In the majority of the many recorded cases of polyarteritis nodosa there is only passing reference, if even that, to the eyes, and this may be due to the comparative mildness of the symptoms produced by such gross eye lesions, amounting in our cases to no more than slight mistiness of vision We can only record that in our very limited acquaintance with this disease, amounting to a total of six or seven cases within the last three years, we have observed these eye changes in four

The prognostic significance of the ocular findings appears to be grave The average duration of life in our four cases was just over six weeks after the discovery of the first eye signs

There is much evidence which suggests that polyarteritis nodosa should be regarded as a non-specific reaction on the part of small vessels to a large variety of antigens The ophthalmoscope can hardly be expected to throw any light on the aetiology of this bizarre condition, but necrotizing inflammatory lesions of the choroidal vessels have been reported in streptococcal septicaemia (Friedenwald and Rones, 1931) and in gonococcal endocarditis (Helpern and Trübek, 1933) In the former case nodular choroidal exudates were seen during life In the related syndromes of disseminated lupus erythematosus, dermatomyositis, and Libman Sach's disease, although it is the retinal rather than the choroidal vessels which are directly involved, there are, as is only to be expected from the analogous nature of the conditions, occasional reports of fundal appearances somewhat similar to those described by us Miller and Nelson (1945) have implicated organic arsenicals as possible sources of sensitizing antigen leading to the development of polyarteritis nodosa, and in this connexion it is of interest that our Cases 2 and 4 had had courses of this class of compound.

It is helpful to consider the eye changes in polyarteritis nodosa with those found in temporal arteritis, where the common lesion is an occlusion of the central retinal artery No choroidal damage or retinal detachment has been described in temporal arteritis, and although the retinal vessels are directly affected by the disease, no aneurysms have been seen. Ocular involvement, although productive of grave symptoms, seems to have no bearing on the prognosis, which is usually favourable as regards life There are great similarities between the two pathological processes, but since temporal arteritis affects older patients, it may be that the retinal vessels are more vulnerable for that reason The relative frequency of choroidal lesions in polyarteritis nodosa is due probably to its predilection for vessels of medium size, and to there being a greater number of such vessels in the choroid than in the retina

Summary

Ophthalmoscopic observations in four cases of polyarteritis nodosa, which came to autopsy, are described On the basis of our findings an attempt has been made to delineate and discuss the significance of the fundal appearances considered to be characteristic of polyarteritis of the choroidal and retinal vessels

We wish to thank Dr A J Ballantyne and Dr Norman McLetchie for the autopsy reports, and Mr Anthony Palin and Mr Ramsey Garden for their reports on the eye condition in Cases 3 and 4 respectively Our thanks are also due to Dr Phillips, Medical Superintendent, Southmead Hospital, Bristol, for permission to publish Case 3, and to Dr McLachlan for permission to publish Case 4 Air-Vice-Marshal P C Livingston, Director-General, Royal Air Force Medical Services, has kindly permitted the publication of the first two cases The fundal paintings are the work of Miss Dulcie Pillars The section of the

choroid was photographed by Mr S A. Edwards and coloured by Dr Norman McLetchie

REFERENCES

Bernstein, A (1935) *Am J med Sc* 190, 317
Böck, J (1932) *Ztschr f Augenh* 78, 28
Friedenwald, J S, and Rones, B (1931) *Arch Ophth* 5, 175
Goldsmith, J (1946) *Am J Ophth* 29, 435
Goldstein, I, and Wexler, D (1937) *Arch Ophth* 18, 767
Helpern, M, and Trubek, M (1933) *Arch Path* 15, 35
Miller, H G, and Nelson, M G (1945) *Lancet*, 2, 200
Sampson, R (1945) *Brit J Ophth* 29, 282



FIG 1a Case 3 Right fundus June 18 Retinal detachment, oedema of disk and retina, choroidal exudates, and haemorrhage There is a nodule on the lower temporal artery



FIG 1b Case 3 Left fundus June 18 Retinal detachment, oedema of disk and retina, choroidal exudate, and haemorrhages There is a choroidal scar with pigmented edges in the lower temporal quadrant near the disk

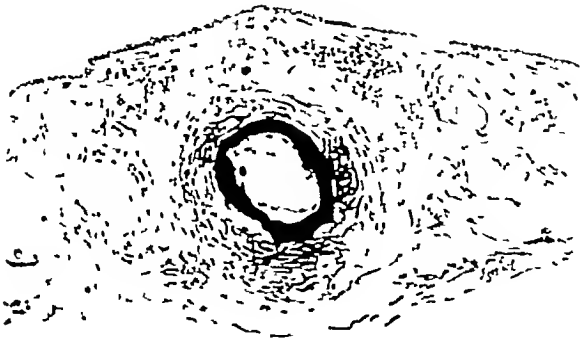

FIG 2 Case 3 Choroid coat of eye (× 160) In the centre there is a dilated arteriole The intimal endothelium is intact though partially retracted The remainder of the wall is ringed by a cuff of fibrin (stained red) There are foci of necrosis above and below the vessel The surrounding tissue shows oedema and round cell infiltration

616 831.42 616 43–006

CUSHING'S SYNDROME AND THYMIC CARCINOMA[1]

By DOUGLAS HUBBLE

With Plates 18 to 20

Introduction

In 1931 Teel reported the first example of a syndrome with a complex symptomatology associated with a basophilic adenoma of the pituitary Cushing (1932) quickly followed with a description of 12 similar cases, 11 of which were collected from reports of other workers in America and Europe In some of these cases a basophilic adenoma was discovered and it was to an excess of basophilic secretion that Cushing attributed the syndrome His paper was accepted as a triumph of deductive reasoning and its author was immediately accorded eponymous distinction in all medical indices There are some paragraphs in this classic article to which little attention was given at the time, but which illustrate well the soundness of Cushing's judgement For example, he wrote 'And if the acidophilic adenomas of acromegaly inevitably cause hyperplasia, not infrequently associated with actual adenomata of the adrenal cortex, it is reasonable to assume that basophilic adenomas may well enough do the same Hence if further study should prove that adrenal tumours in the absence of any demonstrable change in the pituitary body may cause a polyglandular syndrome in many respects similar to that under discussion it may well enough be assumed that, when the same features characterize the syndrome of a basophilic adenoma, they in all probability are secondarily ascribable to a hypersecretory influence of adrenal cortex even in the absence of any histologically appreciable abnormality . '

It will be seen from this quotation that Cushing, even while describing the new syndrome as associated with a basophil adenoma, anticipated the modern view that its features were directly caused by hypercorticism Hypercorticism will be used in the present paper to denote an excessive secretion of hormones from the adrenal cortex There are many other words used embodying the same notion This term is both simple and short, it describes function and does not dogmatize on structure, and it is in keeping with traditional endocrine nomenclature, as hyperthyroidism Cushing wrote of 'the absence of any demonstrable change in the pituitary', but the next considerable advance in our knowledge of this syndrome was provided by Crooke (1935), who was able to demonstrate that there was in Cushing's syndrome an invariable change in the basophil cells of the pituitary This change, which is known as hyalinization, is characterized by swelling of the cells, ballooning of the nuclei, disappearance of basophilic

[1] Received December 2, 1948

granules, and hyalinization of the cytoplasm The change was demonstrated by Crooke in 12 cases of Cushing's syndrome, six cases with a basophilic adenoma of the pituitary, two with an adrenocortical carcinoma, one with adrenocortical hyperplasia, and three cases of thymic carcinoma The significance of the change is discussed below During these few years the pituitary origin of Cushing's syndrome was receiving much support, but a few observers, especially Bauer (1936) and Kepler, Kennedy, Davis, and Walters (1934), had stressed the importance of the adrenal cortex in its pathogenesis From then on a steadily increasing knowledge of the adrenocortical hormones reinforced their ideas Anderson and Haymaker (1937) reported that extracts of the blood and urine of patients with Cushing's syndrome prolonged the lives of adrenalectomized rats beyond the survival-period of untreated controls, while the urine of a 5-year-old girl with virilism showed no significant amount of cortin-like substance It was Haymaker and Anderson (1938) too who, in a long review of these adrenocortical syndromes, elaborated the theory that the syndromes could be reasonably divided into two groups (1) the adreno-genital syndrome, associated with virilism in girls and women and with macrogenitosomia praecox in boys, related to an excessive production of androgens, and (2) the adrenocortical or Cushing's syndrome, with its characteristic features, related to excessive production of 'cortins' Although the distinction is not absolute, since there are many examples intermediate between the two syndromes—virilism in women, for example, associated with hypertension or glycosuria, and cases of Cushing's syndrome showing skin changes which are now associated with androgen excess—yet this concept received support when biochemical assays of urinary hormones became practicable and it was demonstrated that while there was a considerable excess of 17-kotosteroids in the urine (taken as evidence of increased androgen formation) in the adreno-genital syndrome, yet in Cushing's syndrome the values were normal or only slightly increased Recently it has been shown (Scowen and Warren, 1946) that the excretion of corticosterones in Cushing's syndrome may be enhanced fiftyfold Cushing's syndrome should then present an exact antithesis of Addison's disease, and although this contrast is not immediately apparent, yet the results of recent observation and research have done much to elucidate it

Albright, in a lecture to the Harvey Society of New York (1942), which is an ingenious and stimulating mixture of fact and speculation, suggested that the dominating clinical feature in Cushing's syndrome is a deficiency of protein synthesis as shown by the 'thin skin, weak muscles, osteoporosis, and easy bruisability' This tissue defect he concluded from studies of nitrogen, calcium, phosphorus, and potassium balance is not due to increased protein breakdown, but to a failure of synthesis This he takes to be the effect of excessive production of the 'sugar' hormones, whose action he regards as anti-anabolic rather than katabolic Although it is now agreed that the major symptoms of Cushing's syndrome are due to the excessive production of corticosterones, yet most observers consider that these hormones act by promoting the conversion of proteins into sugar (gluconeogenesis) and by inhibiting the

oxidation of glucose at the periphery, the twin actions amply accounting for the hyperglycaemia and the insulin-resistance shown by patients with Cushing's syndrome The exact mechanism of the tissue-wasting must be regarded as still uncertain, but Albright has shown that testosterone propionate (which increases the excretion of 17-ketosteroids in the urine) and methyl testosterone (which does not do so) will both stimulate tissue synthesis and correct in some degree the clinical and biochemical changes of Cushing's syndrome He regarded the raised 17-ketosteroid excretion which occurs in some cases of Cushing's syndrome as a compensatory increase of androgen secretion to offset the excess of corticosterone It seems more reasonable to assume that in hypercorticism all groups of hormones may be quantitatively increased, but in varying degree This is also suggested by the numerous intermediate cases between the adrenogenital and adrenocortical syndromes already mentioned On the same theory, Albright suggested that methyl testosterone therapy, which decreases the output of 17-ketosteroids in the urine in Cushing's syndrome, acts by diminishing the demand for excessive production of androgens Again, it seems more probable that this effect depends on an inhibition of cortical function by testosterone, which is known to occur Thompson and Eisenhardt (1943) collected 98 cases of Cushing's syndrome confirmed by autopsy up to 1940, and a further 25 later Of these 98 cases, 60 showed a pituitary adenoma, 22 an adrenal tumour, one an arrhenoblastoma of the ovary, three a thymic carcinoma, and 12 had no tumour of any endocrine gland The following case is an example of thymic carcinoma occurring with Cushing's syndrome

Case Report

E F was a locomotive designer aged 45 years, and was admitted to the Derbyshire Royal Infirmary on January 14, 1948 He complained of increasing fatigue, loss of libido, a greasy and flushed skin, gain in weight, increased frequency of micturition, depression, and irritability

History Eighteen months before admission he had noticed that he was getting stouter He had previously been of spare build, but had gained 21 lb in the succeeding year The fat was limited to his face, neck, and trunk, and his collar requirements had increased by one inch This caused him no anxiety as it was sufficiently explained by an enhanced appetite, six months before admission his appetite had diminished and he had gained no more weight During the previous year he had been aware of increasing fatigue, and while on holiday in August, 1947, impairment of physical capacity, with shortness of breath on activity During the four months prior to admission his health had steadily deteriorated His legs first became stiff and he had had difficulty in getting in and out of a chair and up and down stairs He had developed aching discomfort in the back, worst at the end of the day's work His skin became greasy, blackheads were numerous on his face, chest, and back, and his complexion became florid He required more fluid and was disturbed twice each night to pass urine He had had no sexual connexion with his wife and had lost all libido His work became more difficult to accomplish and his intellectual capacity notably diminished A man of sanguine and equable temperament, he had become moody, irritable, and depressed

Family history His sister had three children The first child was thought to be a girl at birth, on account of a tiny penis and an ill-developed scrotum It was later decided that the child was a boy and he died in 1922, aged 9 months, from internal haemorrhage associated with whooping-cough The second boy appeared to be normal until he was 3½ years of age, when he developed pubertal enlargement of his sexual organs with growth of pubic hair and an extremely rapid skeletal growth, so that at the age of 5 years he was the height of a boy of 10 years He also developed whooping-cough and died in 1929 of pneumonia, at the age of 5 years and 7 months The third child, a girl, was normal There was no other history of endocrine disturbance in the family The patient himself had three children, two girls and a boy, none said to shew endocrine abnormality

Examination (Plate 18, Figs 3 and 4) His weight was 9 st 5 lb , and height 5 ft 9 in The base of the neck measured 16½ in , the chest at the nipple level 36 in , and the abdomen at the umbilicus 34 in

Dr P Kinmont reported on the skin as follows 'A rather greasy skin of normal thickness and elasticity Severe acne of chest and back with very numerous comedones Stellate telangiectasia on thighs No cutis marmorata Diffuse fine telangiectasia on cheeks Body hair within normal limits, moderately hirsute The scalp shows a mild male alopecia ' No striae atrophicae were present Hess's test was positive He showed obesity of characteristic 'buffalo' type, with a full face, double chin, supraclavicular pads, and lower posterior cervical pads There were increased deposits of fat on the trunk, especially on the lower abdomen The arms and legs remained thin No enlargement of the breasts and no evidence of feminism were present There was a lumbar scoliosis, probably postural and of long standing Muscular weakness was well shown by the difficulty in rising from a horizontal to a sitting position There was no sign or symptom of myasthenia gravis

The blood-pressure was 185/110, pulse-rate 80 to 90, and the heart not clinically enlarged The aortic second sound was accentuated The retinal arteries were narrow but no other retinopathy was noted There was no venous congestion or cyanosis An electrocardiogram showed T1 ill marked, T2 diphasic, T3 inverted, and QRS3 notched The visual fields were normal (Mr J Coates) The urine showed a slight reduction with Benedict's solution No testicular tumour was present

Clinical diagnosis Hypertension 'Buffalo obesity' Acne Increased capillary permeability Glycosuria Cushing's syndrome

Investigations X-rays of the thoracic and lumbar spine showed generalized osteoporosis The pituitary fossa was normal In the chest there was a 'large dense sharply-defined opacity in the upper anterior mediastinum It displaces the trachea backwards and to the right, and also displaces the oesophagus slightly backwards and the arch of the aorta slightly downwards It does not extend beyond the sternal notch into the neck Its transverse diameter is broader than its vertical Screen examination shows no movement on swallowing The most likely diagnosis is a thymoma' (Dr S J Johnson) (Plate 18, Figs 5 and 6) Intravenous pyograms showed no evidence of a suprarenal tumour

The Wassermann and Meinicke reactions were negative The erythrocyte sedimentation rate was 56 mm in one hour A blood-count showed haemoglobin 13 7 gm per 100 c c , red cells 5,300,000 per c mm , white cells 15,200 per c mm , and differential count—old metamyelocytes 3 per cent , neutrophils 76 per cent , lymphocytes 18 per cent , and monocytes 3 per cent The platelets numbered 300,000 per c mm The red cells showed slight anisocycosis The

prothrombin time was 21 5 sec (23 6 per cent) The serum-proteins were 5 0 gm per 100 c c, albumen 3 3 gm per 100 c c, and globulin 1 7 gm per 100 c c

A glucose-tolerance curve (50 gm of glucose) gave the following result

Fasting	½ hr	1 hr	1½ hr	2 hr
0 081 gm per 100 c c	0 105	0 132	0 170	0 170 (Fig 1)

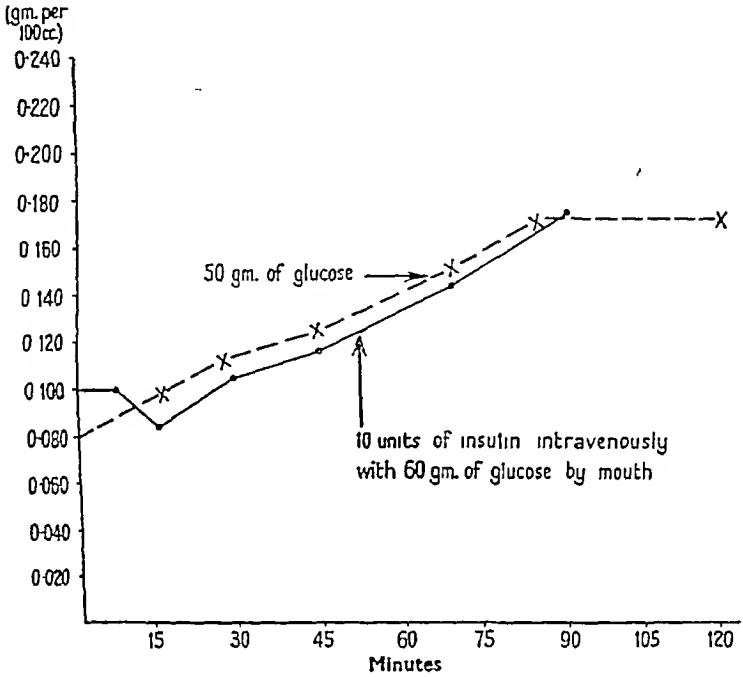

FIG 1 Glucose tolerance and insulin-sensitivity curves

An insulin-sensitivity test (10 units of insulin intravenously and 60 gm of glucose by mouth) gave the following result

Fasting	5 min	20 min	35 min	50 min	65 min	95 min
0 100 gm per 100 c c	0 100	0 085	0 109	0 119	0 135	0 171 (Fig 1)

The serum-calcium was 10 9 mg per 100 c c, and serum-phosphorus 2 2 mg per 100 c c (Ca × P 23 98) The serum-phosphatase (Bodansky) was 4 2 units, serum-cholesterol 194 mg per 100 c c, serum-sodium 325 mg per 100 c c, serum-chlorides 573 mg per 100 c c, and serum-potassium 12 5 mg per 100 c c A 24-hours specimen of urine contained inorganic phosphate 0 76 gm, creatinine 1 04 gm, and creatine 0 24 gm The Ascheim-Zondek test was negative The urinary 17-ketosteroids were 24 5 mg in 24 hours (Dr A M Hain)

Diagnostic summary There was no evidence of a pituitary or adrenal tumour, but a radiological diagnosis of thymic tumour was made The rapid sedimentation rate supported a diagnosis of a malignant thymoma The urinary excretion of 17-ketosteroids, while above the upper normal limit for men given by most authorities (21 mg per 24 hours), was yet within normal

limits according to Hain (personal communication) and in the experience of Scowen and Warren (1946) In any case it was strongly against the diagnosis of an adreno-cortical carcinoma No polycythaemia, no striae atrophicae, and no hyperglycaemia were demonstrated, but occasional glycosuria was present The glucose-tolerance curve was within normal limits, but showed a diabetic pattern, the levels continuing to rise at 1½ and 2 hours, and the insulin-sensitivity test showed an increased resistance to insulin The positive subjective features were increased fatiguability, loss of libido, and depression The positive objective features were acne, greasy skin, increased capillary fragility, hypertension, osteoporosis, muscular weakness, and 'buffalo' obesity Interesting chemical findings were the low serum-potassium and the increased urinary creatine on repeated examination

Final diagnosis Cushing's syndrome associated with a thymic tumour

Progress Following Albright's suggestion, testosterone propionate was first used in treatment The patient was given 600 mg of testosterone propionate in six injections during a fortnight This produced an improvement in libido (? suggestion), but had no influence on the weakness, fatiguability, or depression The pain in the back grew steadily more severe and the acne increased. The following alterations in his blood and urine chemistry were apparently associated with the testosterone therapy (previous findings in parentheses)

Serum-chloride	mg per 100 c c	538 0	(573)
,, sodium		311 0	(325)
,, potassium		18 0	(12 5)
,, calcium		11 1	(10 9)
,, phosphorus		2 5	(2 2)
,, phosphatase		1 7 units	(4 2)
Urinary creatinine (24 hours)		1 10	(1 04)
,, creatine	,,	None	(0 24)

The electrocardiogram showed a slight improvement in T-waves which might be attributed to the rise in serum-potassium, and to elucidate this finding the patient was given 8 gm of potassium citrate and another electrocardiogram was taken 90 minutes later This produced a further improvement in the T-waves (Fig 2) On two occasions the patient developed paroxysmal auricular tachycardia with the heart beating at 160 to 170 per minute, the attacks persisting on the first occasion for a few hours and on the second for 36 hours Because the thymic tumour was growing rapidly and was probably malignant it was decided to have it removed, although it was not expected that this would cause a reversal of the adrenocortical syndrome

The operation was performed on 6 3 48 by Mr L G Cruickshank, anaesthetist Dr F L Turner. Pentothal, nitrous oxide and oxygen, and cyclopropane anaesthesia with endotracheal intubation were employed The skin was infiltrated with 0 5 per cent procaine A short 'collar' incision was made above the suprasternal notch, and a central incision over the sternum carried down to the level of the fourth rib The sternum was split with a Lebsche chisel to the level of the fourth rib, no lateral cuts were necessary A rib-spreader was inserted to separate the halves of the sternum A firm, but friable and highly vascular tumour was exposed, apparently well encapsulated It was removed by blunt dissection without undue difficulty, but with considerable haemorrhage Two large veins left the tumour posteriorly, apparently draining into the right innominate vein Both pleural cavities were opened, the tumour being adherent to both pleurae No attempt was made to close the pleural

cavities The wound was closed in layers without drainage, the lungs being kept fully expanded during closure A blood-transfusion of two pints was given during the operation The patient's condition at the end of the operation was fair After the operation he quickly regained consciousness and there was no evidence of peripheral circulatory failure, but the blood-pressure did not rise above 54 mm systolic, and 10 c c of cortin produced no rise, the cardiac sounds were very feeble and the heart-rate 120 per minute Death occurred eight hours after the operation was completed and appeared to be due to cardiac failure

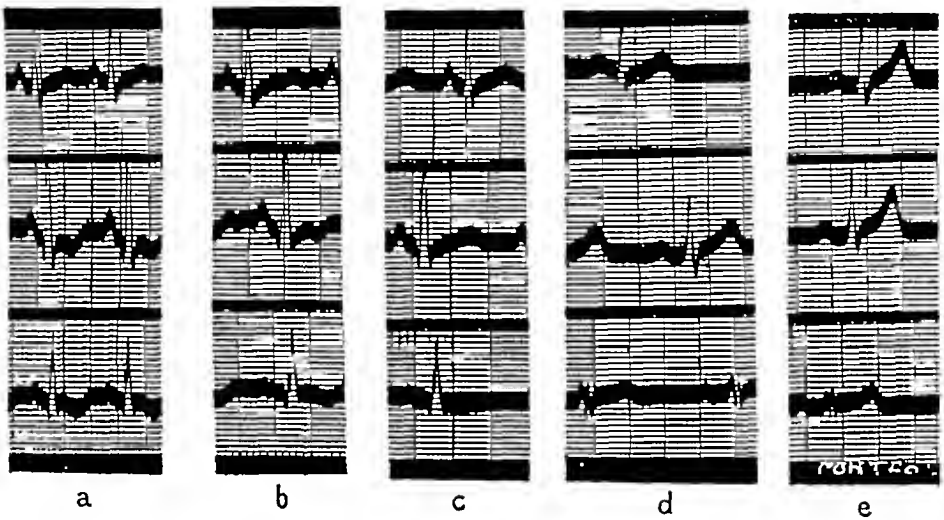

FIG 2 Electrocardiograms

a Inverted T2 and T3 on first examination.
b After testosterone therapy, little change
c After 8 gm of potassium citrate, T2 positive and T3 flat
d Normal subject
e The same subject after 8 gm of potassium citrate

Post-mortem report (Dr G R Osborn) The skull, meninges, and brain appeared normal, and the pituitary was of normal size The thyroid weighed ¾ oz, it was small and free from nodules There was no significant haemorrhage in the region from which the thymic tumour (weight 8 oz) had been removed Both lungs were partly collapsed The trachea and bronchi were free from excessive secretion The heart weighed 16 oz, there was little coronary arteriosclerosis, and the valves were normal The liver showed passive congestion, the gall-bladder was normal The stomach and bowels were normal The spleen was normal except for a few tiny purpuric haemorrhages on the peritoneal coat The kidneys appeared normal, and were not appreciably congested The suprarenals each weighed almost ½ oz, and showed a number of fine superficial nodules The pancreas was nearly twice the normal size, but otherwise appeared normal The bladder and prostate were normal There was no enlargement or obvious tumour in either of the testes, but they were unusually hard

Death was the result of an operation for the removal of a thymic carcinoma

Histology (Plates 19 and 20, Figs 7 to 11) The pituitary shows an increase in large basophil cells The thyroid does not show any significant degree of hyperplasia The stroma is normal and does not support collections of lymphocytes The tumour of the thymus is a carcinoma The cells grow in relatively

large sheets They tend to have a rounded hyperchromatic nucleus with only occasional mitotic figures, and a moderate amount of eosinophilic cytoplasm Occasional groups are necrotic, especially in the central parts of the larger sheets No collagen or reticulum fibrils have been demonstrated between the tumour cells Multiple sections around the carcinoma have failed to demonstrate thymic tissue The pulmonary collapse is well shown microscopically Groups of phagocytic cells laden with exogenous pigment are abundant in parts The heart muscle appears normal

There is some passive congestion of the liver with a minor degree of central-zone necrosis Fatty changes are scattered throughout, but are mostly slight There is a minor degree of congestion of the splenic pulp, but no significant lesion No significant lesion was demonstrated in the kidneys The suprarenals show a number of small nodules 1 to 2 mm in diameter outside the capsule These reproduce the structure of the zona glomerulosa and zona fasciculata The pattern of the suprarenal cortex is well maintained throughout In the zona glomerulosa the cytoplasm tends to be foamy and gives a strong reaction with Sudan III This fat reaction is mostly confined to cells relatively close to the capsule The majority of the cortex is composed of columns of 'androgenic' cells with eosinophilic cytoplasm and a positive fuchsinophil reaction This fuchsinophil reaction has, however, been given by a normal control No significant lesion was demonstrated in the medulla

The pancreas shows focal necroses which are probably post-mortem autolysis. Apart from these, no significant abnormality is shown The testes show generally normal architecture, but interstitial cells are very infrequent Some seminiferous tubules show a notable degree of atrophy, but this is not the rule Mature spermatozoa are formed in relatively few of the tubules

Dr A C Crooke has kindly reported on the pituitary gland as follows 'The majority of the basophil cells show hyaline change, which in some cases is extreme Some are multinucleate I should guess that the cells are present in approximately the normal numerical proportions' (Plate 19, Fig 7)

Discussion

This patient showed nearly all the classical signs and symptoms of Cushing's disease There were no striae, no polycythaemia, and no hyperglycaemia, although there was evidence of increased insulin resistance The absence of polycythaemia is not remarkable since this is not an invariable association, but the absence of purple striae in Cushing's syndrome is very unusual Had striae atrophicae been present it is justifiable to assume that they would have been purple since the patient's complexion was dusky and Hess's test was positive, and their absence must be attributed to the fact that the increase in lower abdominal fat was only moderate

The biochemical changes were well marked McQuarrie, Johnson, and Ziegler (1937) were the first to draw attention to the electrolyte disturbances in Cushing's syndrome They have been further investigated by Willson, Power, and Kepler (1940) and Clinton, Bennett, Power, and Kepler (1945) This derangement of electrolytes has now been reported in a few cases, and where it has occurred the initial change is a low serum-potassium level This is usually associated with an increased serum concentration of bicarbonate and a dis-

position towards alkalosis The serum-sodium content remains normal or is increased in value Hypochloraemia has been associated with the alkalosis in a few instances, which is surprising since an antithetic electrolyte pattern would be expected to that occurring in Addison's disease No explanation has been proffered, though it is suggested that it may be directly related to the low serum-potassium 'E F' showed this low serum-potassium (12 5 per 100 c c), but it was temporarily corrected by the testosterone therapy to 18 mg per 100 c c , while at the same time the serum-sodium which was formerly at the high normal level of 325 mg per 100 c c fell to 311 mg per 100 c c Hypochloraemia was not evident until after testosterone, when the serum-chloride fell from 573 mg to 538 mg per 100 c c There was also increased excretion of creatine in the urine, which is usually associated with some inability of the muscles to utilize carbohydrate and therefore may be related to insulin resistance in 'E F' It is well known that injections of testosterone propionate will eliminate creatinuria and this was demonstrated in 'E F' Creatinuria does not occur in myasthenia gravis and despite the presence of both fatiguability and a thymoma there was no evidence of this disease in 'E F' The simplest explanation of all these chemical changes would be that testosterone therapy depresses the excretion of adrenocortical hormones, as is known to occur experimentally This therapy undoubtedly produces biochemical results, but in the presence of a neoplastic lesion of the adrenal cortex or other endocrine organ it could not be expected to cure (cf oestrin and prostatic cancer) The correction of the electrocardiographic changes by the administration of potassium citrate has been previously described by Cluxton, Bennett, Power, and Kepler (1945) and was confirmed in 'E F' This same dose of potassium citrate (8 gm) produced a marked elevation of T-waves in a normal subject (Fig 2), but failed to produce any alteration in two other subjects with inverted T-waves of different pathological origin It is reasonable to assume that potassium deficiency causes the electrocardiographic changes in Cushing's syndrome

Morbid anatomy The carcinoma of the thymus was of the same structure as that reported by Leyton, Turnbull, and Bratton (1931) The thymic cell had disappeared and the structure reverted to an epithelial type The basophil cells were numerous in the pituitary and Dr A C Crooke reported the hyaline change as being present in the majority of these cells The structure of the adrenal cortex is difficult to interpret The average weight of the normal adult suprarenal is 10 gm and these two glands together weighed 28 gm , but such increases in size are common in long-continued illness Adenomata are present in the adrenal cortex in 33 per cent of all persons, irrespective of age or sex (Goldzieher, 1944) Whether the fact that some of these adenomata were extracapsular is of significance in the attempt to assess enhanced function is not known It seems possible, but none of the authorities consulted is prepared to give a definite opinion There was no microscopic evidence of increased depth of any of the cortical layers or of cellular hyperplasia One must admit therefore that there was little in the appearance of these adrenal glands to convince the sceptic that the aetiological basis of Cushing's syndrome is hypercorticism

Genetic Aspects. It is a reasonable assumption that the examples of pseudo-hermaphroditism and macrogenitosomia praecox occurring in the family of the patient's sister were associated with adrenocortical hyperplasia Biggs and Rose (1947) have recently reviewed the familial incidence of this abnormality They discovered nine reports of families in which two sisters were pseudo-hermaphrodites, and four families in which both male and female children were affected, the female baby showing hypertrophy of the clitoris and the male child precocious sexual and skeletal development It is now regarded as established that female pseudo-hermaphroditism is associated with an excess of circulating androgen during intra-uterine life The urine of these children has been shown to contain an excess of 17-ketosteroids (Talbot, Butler, and Berman, 1942) and an interesting natural experiment was recorded by Brentnall (1945) in which a woman, aged 26 years, suffering from virilism which developed during her pregnancy associated with an arrhenoblastoma of the ovary, gave birth to a female pseudo-hermaphrodite child The occurrence of female pseudo hermaphroditism is usually related to hypercorticism, and the development of macrogenitosomia praecox in a male member of the same family makes this pathogenesis certain Macrogenitosomia praecox in young boys is occasionally associated with an atypical teratoma in the region of the pineal gland (Russell, 1944), and more rarely still with a tumour of the interstitial cells of the testis (Rowlands, Nicholson, and Weber, 1929), but much more commonly this syndrome (Allibone, Baar, and Cant, 1947) is related to adrenocortical hyperplasia, to a cortical adenoma, or to a cortical carcinoma It should be noted that neither pseudo-hermaphroditism in girls nor macrogenitosomia praecox in boys has been described in association with a thymic tumour It must be assumed that in the family now being described there existed a genetic disposition to adrenocortical excess, operative in the girl during foetal life, in the boy in early childhood, and in 'E F' during middle age That a similar genetic disposition should not have been previously described in Cushing's syndrome is possibly accounted for by the rarity of the syndrome and by the many and well-recognized difficulties in conducting investigations in human genetics

Thymic carcinoma and Cushing's syndrome Up to the present there have apparently been only three[2] recorded cases (Leyton, Turnbull, and Bratton, 1931, Keplor, 1933) of thymic carcinoma occurring in association with Cushing's syndrome If this association, though so rarely described, is more than a coincidence, and if Cushing's syndrome can be explained on the basis of hypercorticism, then the question of the relationship of thymic carcinoma to hypercorticism is acutely raised Thymic carcinoma of similar structure to that described by Leyton, Turnbull, and Bratton and to that in 'E F' commonly occurs without any endocrine disorder There are two further facts in the case of 'E F' which require consideration in the formulation of any theory the first that his genetic disposition towards hypercorticism must be regarded as

[2] There is a case very briefly reported by Dugud and Kennedy (1930) of thymic carcinoma in a woman in whom diabetes and adrenal hyperplasia were present, but none of the other signs and symptoms of Cushing's syndrome were described

the chief aetiological factor in the development of the syndrome, and the second that the time onset of the Cushing's syndrome corresponded approximately with the growth of the thymic carcinoma There are then three possible aetiological theories that the thymic carcinoma had nothing to do with the development of Cushing's syndrome in this patient, that the thymic carcinoma was itself the result of endocrine imbalance initiated by the patient's hypercorticism, and that the thymic carcinoma 'touched off' the predisposition of the adrenal cortex to hyperplasia with the production of Cushing's syndrome None of these theories is susceptible of proof, but it is significant that a fourth theory, that the thymic carcinoma was directly responsible for the development of Cushing's syndrome, is not even included, although it would have been upheld as the most probable theory 20 years ago Had it still been so regarded, 'E F 's' family history would have given it no support, but the notion that the thymus exercises any important endocrine effect on growth and sexual development has now been generally discarded Selye (1947) stated the matter conservatively when he wrote, 'there is fairly good evidence indicating, however, that substances liberated from the bodies of decomposing thymocytes, perform important physiological roles, even if they are not hormones in the original sense of this word The substances thus liberated from the thymus have been claimed to play a role in immunologic reactions and regenerative processes, but the exact nature of their function is still unknown' There is more exact knowledge concerning the effect of other hormones on the thymus. It has been shown experimentally that prevention of thymus involution (whether the normal ageing involution, or that following non-specific damage as in Selye's alarm reaction) can be prevented by adrenalectomy The injection of the cortins induces a full involution of the thymus, but the follicle-stimulating sterones are most effective in this action and the antithymic effect of the other steroids, including corticosterones, appears to depend on their oestrogenic activity This corresponds to the facts of human endocrine balance, for it has long been known that the thymus tends to persist in conditions of adrenocortical insufficiency as in Addison's disease, and that involution is hastened in the alarm reaction and in chronic disease in which adrenocortical excess is postulated In adrenocortical hyperplasia, as in Cushing's syndrome, atrophy of the thymus might therefore be expected, and is indeed frequently found, but Allibone, Baar, and Cant (1947) in their 10 reported cases of the interrenal syndrome in children found marked thymic atrophy in five cases only, and suggested that this might be related to the thymic atrophy of long-continued disease In any case, thymic atrophy of the latter type is obviously due to increased cortical-hormone production, 'since it is prevented by hypophysectomy or adrenalectomy, but can be elicited even in the absence of the hypophysis or adrenals if adequate doses of corticoids are administered' (Selye, 1947) In this change the thymocytes completely disappear and the thymic reticulum reverts to its original epithelial type In the thymic carcinoma described in the present paper, no normal thymus tissue was discovered and the cells were all of the foetal epithelial type

Any theory devised to explain the association of thymic carcinoma and Cushing's syndrome must then embrace the following considerations

(a) That thymic carcinoma of the type encountered in 'E F' has occurred in association with Cushing's syndrome only with extreme rarity

(b) That in 'E F' the genetic disposition to hypercorticism may explain this unusual association

(c) That, whatever disease may be present in pituitary, thymus, or ovary, hypercorticism is established as the immediate determining cause of Cushing's syndrome

Crooke (1946b) has described the case of a woman aged 28 years who died of Cushing's syndrome, and in whom a carcinoma of the pancreas was discovered at autopsy. He collected three similar cases from the literature, and in view of the extreme rarity of carcinoma of the pancreas in young women, suggested that there is in Cushing's syndrome a disposition to carcinoma Such a suggestion had been previously made by McLetchie (1944) Crooke regarded this carcinogenic tendency as dependent either on the growth-stimulating hormone from the pituitary or on the production of steroids, since some steroids are known to be carcinogenic in certain strains of mice

In 'E F' with his genetic hypercorticism it might then be postulated that the second hypothesis suggested above is correct and that the thymic carcinoma resulted from the excessive production of corticosterones It seems reasonable to extend Crooke's suggestion and say that this carcinogenic tendency is shown only in endocrine glands, and only in those endocrine glands such as the pancreas and thymus against which the corticosterones appear to exert some opposing action

The pituitary and Cushing's syndrome Although hypercorticism is generally accepted as the immediate cause of Cushing's syndrome, there is still much discussion as to the role of the pituitary Forsham, Thorn, Prunty, and Hills (1948) have recently shown that the injection of pituitary adrenocorticotrophic hormone (ACTH) into normal human subjects produces an enhancement of the known functions of the adrenal cortex It is therefore still a reasonable hypothesis that Cushing's syndrome may depend primarily on excessive production of the adrenocorticotrophic hormone Such an hypothesis could be established only by the demonstration of this hormone in excess in the blood or urine of patients suffering from the disease and, in default of this finding, it is natural that discussion should occur as to the exact meaning of the hyalinization of the basophil cells Thompson and Eisenhardt (1943) found Crooke's hyaline change present in 58 out of 63 reported cases of Cushing's syndrome in which they were permitted to examine the pituitary On a later review of the five cases in which Crooke's change was not present, they concluded that the patients were not wholly satisfactory as clinical examples of the syndrome This nearly absolute association of hyalinization with Crooke's syndrome has also been confirmed by other observers Mellgren (1945) established it in 16 cases, which included both the adrenocortical (Cushing's) and the adrenogenital (virilism) syndromes Crooke's change is usually said to be absent in the latter cases Kepler (1945)

was the main protagonist of the view that the hyalinization represents a secondary and regressive change, while Crooke (1946*a*) still maintained that it is to be regarded as evidence of basophilic overactivity Recent observers who have continued to support Crooke's view are Mellgren (1945) and McLetchie (1944) Kepler (1945) was generally mistrustful of the attempt to correlate function with the histological appearances of endocrine glands and he instanced the occurrence of thyroid hyperplasia from thiouracil and thiocyanate with myxoedema, adrenocortical hyperplasia in the presence of acute adrenocortical insufficiency, hyperplasia of the interstitial cells of the testis associated with eunuchoidism, and so on His strongest argument is that the hyaline change is found at autopsy when Cushing's syndrome is due to an adrenocortical cancer, and yet when the tumour is successfully removed, as in several instances in the Mayo Clinic, the patient is cured (one patient in 1945 had remained well for 11 years after the operation), and that cure could hardly result if the hyaline change represented the primary lesion Even if Kepler's view is accepted and the hyaline change is regarded as secondary to the hypercorticism, this does not mean that excessive production of the adrenocorticotrophic hormone is never the cause of Cushing's syndrome Many observers have noted that where basophil adenomata are present in the anterior-pituitary the hyaline change is not found in the adenoma, but only in the pituitary outside it It is evident that exact knowledge must wait upon assays of the adrenocorticotrophic hormone Meanwhile it can be concluded that although hypercorticism is the immediate cause of Cushing's syndrome it may be initiated in several different ways Hypogonadism has been regarded as the primary lesion by some observers, and Heinbecker (1946) has demonstrated that a puncture of the hypothalamic nuclei in dogs produces a loss of basophil cells in the glandular hypophysis He has also found atrophy of these nuclei in a case of Cushing's syndrome He suggested that the primary lesion, for example carcinoma of the adrenal cortex or the thymus, depresses the function of the normal hypophysis, which results in depression of the basophil elements and dominance of the eosinophil elements, with increased secretion of adrenocorticotrophic hormone and consequent hypercorticism The links in this aetiological chain are too many and too uncertain to inspire confidence in its strength

Summary and Conclusions

1 A historical review of the aetiology of Cushing's syndrome is made and support is given to the modern view which states that whatever endocrine disease is discovered, whether in pituitary, adrenal cortex, ovary, or thymus, the immediate cause of the syndrome is related to an excessive secretion of adrenocortical hormones

2 The case of a man with Cushing's syndrome is reported For the fourth time the syndrome is described as associated with a carcinoma of the thymus The patient's family history showed a disposition to hypercorticism, a niece having died in infancy as a pseudo-hermaphrodite and a nephew having died

at the age of five years with macrogenitosomia praecox These latter conditions, together with virilism in girls and women, constitute the adrenogenital syndrome, while Cushing's disease is described as the adrenocortical syndrome, different adrenocortical hormones being predominantly concerned in each syndrome. It is suggested that while this distinction is useful, there are many instances of overlapping between the two syndromes

3 The patient described showed some disturbance of electrolytes, particularly in a reduced serum-potassium level, as has been previously reported by a few authors This was reversed by testosterone therapy Electrocardiographic changes were presumably related to this low serum-potassium, since they were corrected by the ingestion of 8 gm of potassium citrate

4 The relationship of carcinoma of the thymus to Cushing's syndrome is discussed Crooke's view that there is a carcinogenic disposition in Cushing's syndrome is accepted This idea is extended, and it is suggested that the carcinogenesis is limited to the action of corticosterones on endocrine glands such as the thymus and the pancreas to which the adreno-cortical function is normally opposed.

5 The nature of the hyaline change in the basophil cells and the whole concept of pituitary basophilism are discussed, and it is concluded that elucidation must be awaited until assays of the adrenocorticotrophic hormone are practicable

I am indebted to Dr A C Crooke for a report on the pituitary gland, to Dr G R. Osborn for the post-mortem and histological reports, to Dr Michael Atkinson for many of the ward-observations, to Mr J W Allen and Miss D A. Matthews for the biochemical investigations, and to Mr J S Fayers for the photographs

REFERENCES

Albright, F (1942–3) *The Harvey Lectures*, 38, 123
Albibene, E C, Baar, H S, and Cant, W H P (1947) *Arch Dis Childh* 22, 210
Anderson, E M, and Haymaker, W (1937) *Science*, 86, 545
Bauer, J (1936) *Schweiz med Wschr* 66, 938
Biggs, R, and Rose, E (1947) *J Obstet Gynaec* 154, 369
Brentnall, C P (1945) *J Obst and Gynaec Brit Emp* 52, 235
Cluxton, H E, Bennett, W. A, Power, M H, and Kepler, E J (1945) *J Clin Endocrin* 5, 61
Crooke, A C (1935) *J Path Bact* 41, 339
—— (1946a) *Proc R Soc Med* 40, 43
—— (1946b) *J Path Bact* 58, 667
Cushing, H (1932) *Bull Johns Hopk Hosp* 50, 137
Duguid, J B, and Kennedy, A M (1930) *J Path Bact* 33, 93
Forsham, P H, Thorn, G W, Prunty, F T G, and Hills, A G (1948) *J Clin Endocrin* 8, 15
Goldzieher, M A. (1944) *The Adrenal Glands in Health and Disease*, Phila
Haymaker, W, and Anderson, E (1938) *Int Clin* 4, 244
Heinbecker, P (1946) *Ann Surg* 124, 252
Kepler, E J (1933) *Proc Mayo Clin* 8, 102

Kepler, E J (1945) *J Clin Endocrin* 5, 70
—— Kennedy, R L J, Davis, A C, and Walters, W (1934) *Proc. Mayo Clin* 9, 169
Leyton, O, Turnbull, H M, and Bratton, A B (1931) *J Path Bact* 34, 635
McLetchie, N G B (1944) *J Clin Endocrin* 4, 553
McQuarrie, I, Johnson, R M, and Ziegler, R M (1937) *Endocrinology*, 21, 762
Mellgren, J (1945) *Acta path et microbiol Scandinav* Supp 60.
Rowlands, R P, Nicholson, G W, and Weber, F P (1929) *Guy's Hosp. Rep* 79, 401
Russell, D S (1944) *J Path Bact* 56, 145
Scowon, E F, and Warren, F L (1946) *Proc R Soc Med* 40, 39
Selye, H (1947) *Textbook of Endocrinology*, Montreal.
Talbot, N B, Butler, A M, and Berman, R A. (1942) *J Clin Invest* 21, 559
Teel, H M (1931) *Arch Neurol and Psychiat* 26, 593
Thompson, K. W, and Eisenhardt, L (1943) *J Clin Endocrin* 3, 445
Willson, D M, Power, H M, and Kepler, E J (1940) *J Clin Invest* 19, 701

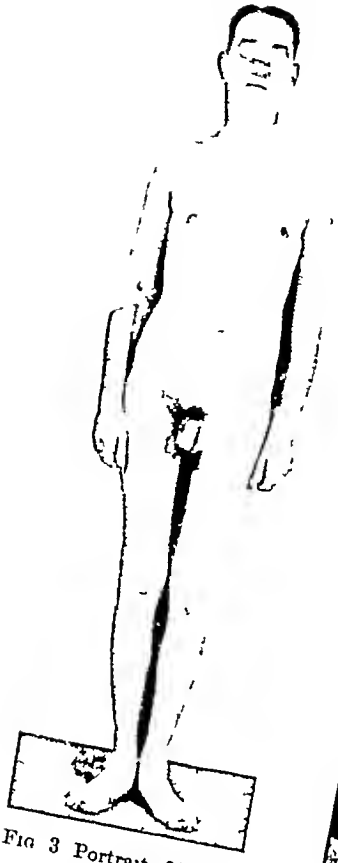

FIG 3 Portrait of 'E F'

FIG 4 Portrait of 'E F'

5 X ray of patient s chest postero anterior view

FIG 6 X ray of patient s chest lateral view



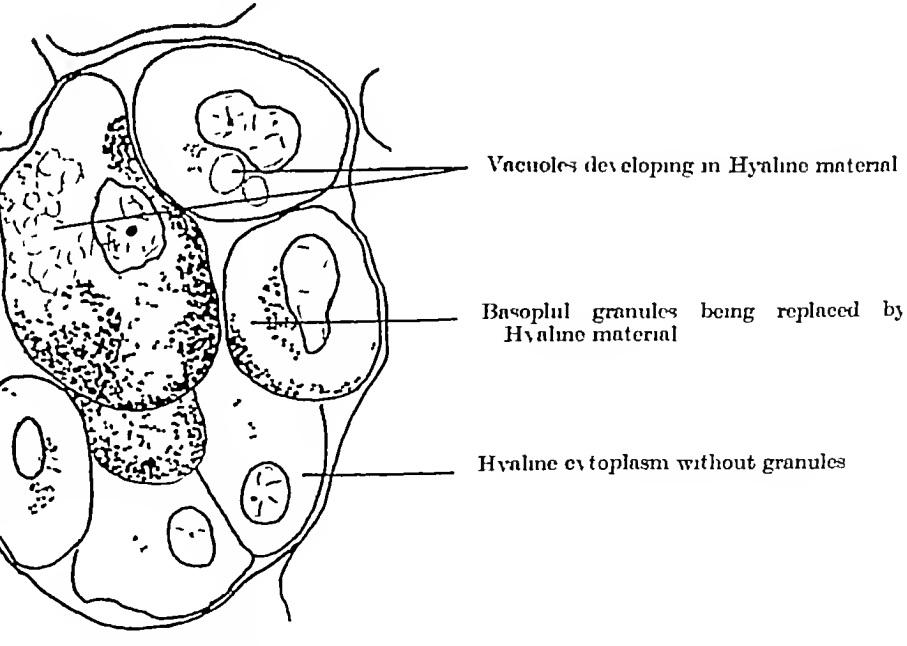

Enlarged Basophil cells

o 7 Pituitary gland to show large basophil cells (× 1300 Mallory's acid fuchsin aniline blue stain) (Dr A C Crooke)

FIG 8 Carcinoma of thymus (× 460, Van Giesen's stain)



FIG 9 Extracapsular suprarenal nodules (× 77, haematoxylin and eosin)

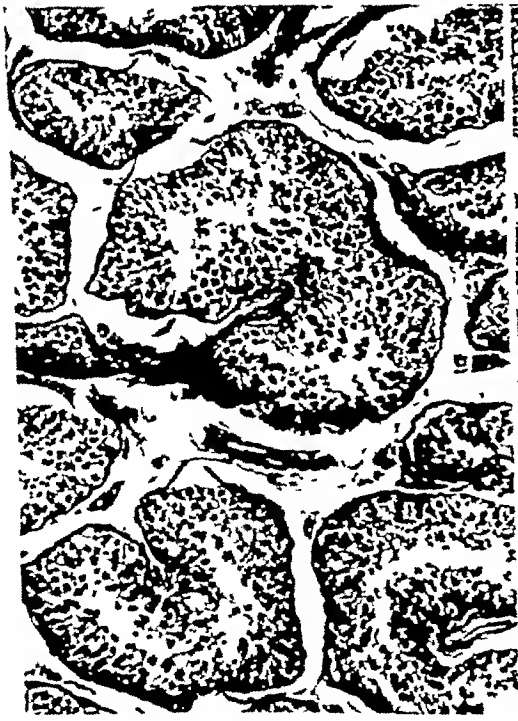

FIG 10 Testis Relative absence of interstitial cells and mature spermatozoa (× 30, haematoxylin and eosin)

FIG 11 Vertebral body showing osteoporosis (× 8 5, haematoxylin and eosin)

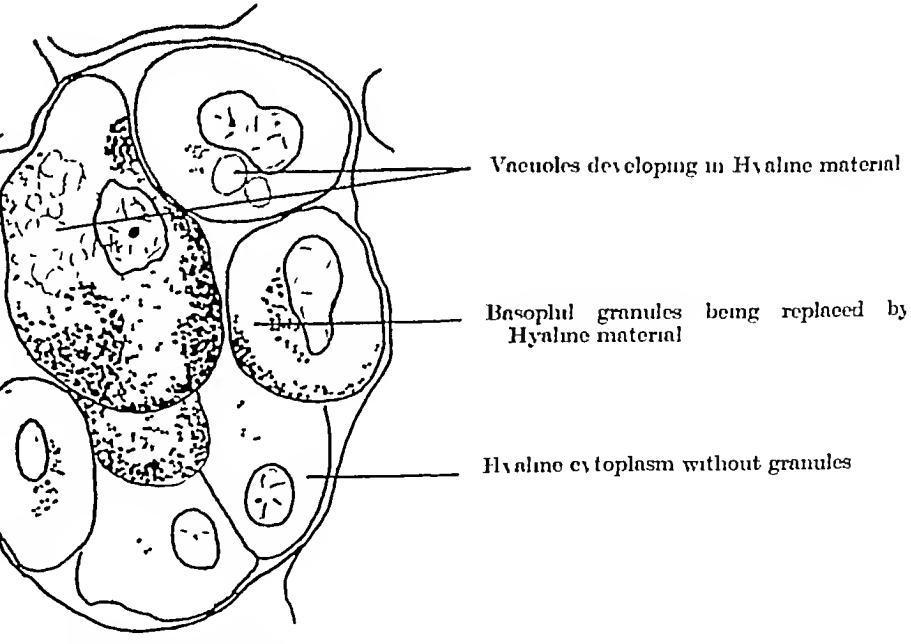

Enlarged Basophil cells

g 7 Pituitary gland to show large basophil cells (× 1300, Mallory's acid fuchsin aniline blue stain) (Dr A C Crooke)

616 61-002

A CLINICAL AND PATHOLOGICAL STUDY OF RENAL DISEASE

PART I NEPHRITIS[1]

By J DAVSON AND ROBERT PLATT

(From the Departments of Pathology and Medicine, Manchester University)

With Plates 21 and 22

Introduction

The various attempts by clinicians and morbid anatomists to achieve a satisfactory classification of nephritis have never been wholly successful, because the distinctions made by clinicians often showed ignorance of the natural history of the disease and were not upheld by pathological evidence, whereas classifications based on histology, such as that of Russell (1929), proved too unwieldy to be serviceable to the clinician A new advance was made by Ellis (1942), when, as the result of close clinico-pathological collaboration, he divided nephritis into two types differing in aetiology, clinical course, and pathological appearance Since the publication over six years ago of this important work no similar investigations tending either to confirm or refute his classification and interpretation of nephritis have appeared The primary purpose of the present paper is therefore to investigate the clinical and pathological features of a large series of cases of renal disease with a view to showing whether the Ellis classification can be upheld The mode of approach has been the same throughout The clinical aspects of the case were studied by one of us (R P) and a diagnosis reached if possible, based on the clinical criteria which Ellis described The pathological aspects were studied independently by the other (J D) and a diagnosis made on the basis of Ellis's descriptions of pathology in nephritis The two diagnoses were then compared, and the measure of agreement assessed, for it was felt that this would be a fair estimate of the validity of the Ellis classification, as it has been the failure of close correspondence between clinical and pathological findings that has constituted the main difficulty in accepting previous classifications of nephritis It was originally intended that this assessment of clinico-pathological correlation should be statistical, but this proved impossible because in many cases pathologist or clinician was obliged to give an alternative diagnosis on the data available and would occasionally have to be open to persuasion after mutual discussion Clinical notes are sometimes inadequate, more often they lack precision in some important detail Pathological material on the other hand represents the end stage of disease, when

[1] Received October 27, 1948

during the first fortnight of the illness 36, or 85·7 per cent, recovered completely and did not relapse These figures agree well with those of Ellis (1942) who recorded an 82 per cent recovery The remainder behave in one of two ways A few run a rapidly progressive course with persistent oedema and hypertension, and die of uraemia within a few months The others make a partial recovery and enter the latent stage, which may last for many years Oedema subsides completely, and does not usually recur except terminally when heart failure and anaemia supervene, and for some years the only signs of disease are persistent albuminuria, slowly deteriorating renal function, and a gradual rise in blood-pressure Only when these conditions have become extreme is the patient again troubled by symptoms, which are then due to uraemia, hypertension, or both He is then said to have entered the terminal stage It is in this stage that chronic cases of Type 1 nephritis are most often seen If there is a clear history of an acute phase with oedema, even though it may have been many years ago, the diagnosis is relatively easy, but a detailed account of the illness should be obtained if possible, because what the patient refers to as 'kidney trouble' or 'nephritis' may actually have been a urinary infection Occasionally the acute stage may have been overlooked, probably because oedema was absent or minimal In such cases the only clinical diagnosis that can be made is 'terminal renal failure with hypertension—cause uncertain' The more clearly it is realized that this latter group, which used to be called chronic interstitial nephritis, is a miscellaneous collection containing examples of chronic pyelonephritis, malignant hypertension, periarteritis nodosa, and so-called surgical renal disorders, the less frequently is a clinical diagnosis of chronic Type 1 nephritis made

Of 23 cases finally diagnosed as Type 1 nephritis in our series, 17 gave a previous history at least suggestive of an acute stage Of six who gave no such history, four were admitted only a few days before death and the records of previous illness are inadequate One, though not admitting an acute attack of nephritis, had had repeated tonsillitis The average age at death in our cases was 31 years, with a range of 15 to 53 years, and death was due to uraemia in all cases Only four patients were over 40 years of age Chronic Type 1 nephritis is therefore not a common cause of uraemia in middle-aged or elderly subjects Of the 23 cases, two were classified as acute nephritis, 11 ran the rapidly progressive course, and 10 the slowly progressive It is probable that the rapid cases are more prone to die in hospital and that these proportions are not true ones On the other hand, the chronic type by reason of its long course is seen more commonly in any medical out-patient department or nephritis clinic, and therefore appears to be commoner than it is There was no significant difference in age of onset between the three groups

Pathological features According to Ellis, increased cellularity of the glomeruli with polymorphonuclear infiltration is the chief lesion in the acute stage of Type 1 nephritis, in the more severe cases acute fibrinoid necrosis of the tufts and arterioles are described, and early epithelial crescent formation may be seen In the present series of Type 1 cases there were but two which appeared to be

evidence of earlier processes may be obliterated by the impress of terminal events In spite of these difficulties it was clear that in the great majority of cases clinico-pathological agreement could be reached, and incompatible diagnoses were rare The paper will deal with cases finally diagnosed as Type 1 or Type 2 nephritis on the Ellis classification In a subsequent paper we propose to record certain observations made on other types of renal disease in the course of these clinical and pathological studies, and to present figures for their incidence in cases coming to autopsy in a large teaching hospital

Material

A 14-year period was arbitrarily selected, beginning in 1934 and ending in 1948. The material in the main consisted of cases that had come to autopsy at the Manchester Royal Infirmary during this period and of which sections of kidney tissue were available A smaller number of cases was obtained from autopsies at the Royal Infirmary, Sheffield, and were part of a large series of cases of renal disease under observation by R P before the war of 1939–45 The selection of the Manchester cases was in the main determined by the autopsy report in which a clinical or pathological diagnosis of some form of nephritis had been recorded Only cases of the Manchester series since 1946 have been seen by one of us during life, so that the clinical aspects of the earlier ones have had to be studied in retrospect In some cases clinical data were insufficient to make any diagnosis possible These were usually excluded The Sheffield cases had all been seen during life The autopsies at Manchester were routine autopsies and were performed by various members of the staff of the Department of Pathology, to whom we are indebted for permission to study the material A small number of cases has been included in which the kidney has been obtained by unilateral nephrectomy for the relief of hypertension Although this pathological material is the basis of our study, the clinician is naturally bound to form his opinions largely upon his experience of living patients When such experience is referred to in a statistical sense it will be made clear in the text All available renal blocks of tissue were sectioned by the paraffin method and stained by haemalum and eosin, and in some cases by the rapid trichrome method, Weigerts's elastic stain and Van Gieson's stain, and by methyl violet for amyloid material Available information included the heart weight, naked-eye description of the kidneys, and all other routine autopsy data

The total number of cases examined was 188, of which 45 were diagnosed as Type 1 or Type 2 nephritis and form the basis of the present paper

Type 1 Nephritis

Clinical features The initial illness is an acute nephritis of abrupt onset characterized by oedema, haematuria, and hypertension Most frequently it occurs in a child or young adult as a sequel of tonsillitis or some other streptococcal infection Death rarely occurs in the acute stage, and the majority of patients make a complete recovery Of 42 cases seen by one of us before 1939,

microscopic form of periarteritis nodosa and have been distinguished on clinical and pathological grounds from the rapidly progressive form of Type 1 nephritis The basis for this distinction has been discussed elsewhere (Davison, Ball, and Platt, 1948) The interesting fact emerges that the number of acceptable cases of the rapidly progressive Type 1 nephritis encountered in a 14-year period (11 cases) is actually less than the number of cases of the microscopic form of periarteritis nodosa seen in the same period (13 cases)

In the slowly progressive form, according to Ellis, gross renal contraction is the rule The glomeruli are greatly reduced in number, interstitial fibrosis is severe, and intervening areas of dilated tubules are present (Plate 21, Fig 4) Fibrinoid necrosis of glomeruli and arterioles may be seen, as well as varying degrees of contraction and fibrosis of glomeruli Arteriosclerosis and endarteritis fibrosa of the intralobular arteries are present Ten of our cases came into this category, four were regarded as fairly late, the kidney weights ranging from 140 to 60 gm , and six as late, with weights from 60 to 20 gm In all 10 cases, disappearance of glomeruli, widespread ischaemic vascular changes, and fibrotic contraction had occurred Concentric hypertrophy of the left ventricle was present in all cases, the heart weights varied between 380 and 600 gm There were four cases in which both the date of the initial acute nephritis and the weights of the kidney were known accurately, and they thus provide some indication of the rate of renal contraction in this group

Duration	4	years,	kidney	weights	140, 140	gm
,,	5	,,	,,	,,	140, 120	,,
,,	10	,,	,,	,,	120, 80	,,
,,	23	,,	,,	,,	20, 20	,,

Discussion on Type 1 cases On the experience of the present series and on a much wider clinical experience of cases which have not come to autopsy, we feel justified in concluding that the Ellis classification is clinically satisfactory in the great majority of cases, and that the clinico-pathological correlation is good When cases are seen early in the acute stage there is rarely any difficulty in diagnosis , the age incidence, the abrupt onset with oedema, haematuria, and hypertension, and the relation to infection are usually decisive From the histological point of view the grouping of Type 1 nephritis cases into acute, rapidly progressive, and slowly progressive types has been satisfactorily achieved in our series, but the number of autopsies on acute cases has been very small and does not provide material for further discussion

The rapidly progressive type with oedema persisting beyond the acute stage may be clinically difficult to distinguish from Type 2 nephritis, and occasionally from periarteritis nodosa, but if the patient is seen from the commencement the diagnosis is usually clear In Type 2 nephritis the onset is insidious, haematuria is minimal or absent, and albuminuria extreme, and there is usually no clear relationship to streptococcal tonsillitis In periarteritis nodosa there are usually some suspicious features such as pyrexia, leucocytosis, tachycardia, asthma, and joint pains The main difficulties in histological differentiation of this group

examples of the acute stage, and neither of these was typical The first (Case 1, see Appendix) showed occasional patchy fibrinoid necrosis in the tufts as well as polymorphonuclear infiltration, purpura had been present during life, and this was probably a case of the Henoch-Schönlein syndrome, the renal lesions in which have recently been described by Gairdner (1948) The second (Case 2), which clinically appeared to be severe acute nephritis, showed relatively slight glomerular changes, but unusual dilated tubules lined with atrophic epithelium and extensive tubular haemorrhage A further four cases which showed fibrinoid necrotic lesions of the glomeruli with polymorphonuclear infiltration and early epithelial crescent formation were found to be examples of the microscopic form of periarteritis nodosa (Davson, Ball, and Platt, 1948) Examples of the acute stage of Type 1 nephritis are therefore rarely seen at autopsy in a teaching hospital

In the rapidly progressive form the characteristic changes according to Ellis are epithelial crescent formation in Bowman's capsule (Plate 21, Fig 1), interstitial fibrosis and tubular atrophy, and organization of epithelial crescents (Plate 21, Fig 2) Later stages show fibroblastic obliteration of the glomeruli, increasing interstitial fibrosis, and dilatation and hypertrophy of surviving tubules (Plate 21, Fig 3) In the present series there are nine cases which appeared to be typical examples of the rapidly progressive form, and in which the histological features closely corresponded with Ellis's description, two were in the earlier stage in which epithelial crescents were widespread, four were in the intermediate stage in which fibrosis of the crescents were prominent, and three were in the late stage in which fibroblastic obliteration of glomeruli was widespread In one of the last group contraction of the kidneys had occurred (weights 80 and 90 gm), but in the remainder enlargement was the rule There were two further cases which presented atypical histological features In the first (Case 3), although the patient progressed rapidly to uraemia after a typical Type 1 onset, the glomeruli showed few epithelial crescents or organizing crescents, the main changes consisting of endothelial cell proliferation and excessive lobulation and degrees of contraction of the tufts In the second case (Case 4), numerous epithelial crescents were present and the tufts showed an unusual type of fibrinoid deposit outlining the capillaries There was in addition a severe subacute pyelitis and some convoluted tubules contained polymorphonuclear cells, so that the histological picture combined the features of pyelonephritis and rapidly progressive Type 1 nephritis Specific reference is made to such cases in order to avoid giving the impression that every case encountered could be readily classified

In his description of the histology of rapidly progressive Type 1 nephritis, Ellis included a number of cases showing 'explosive' lesions of the glomeruli, definite periglomerular inflammatory reaction, and intense inflammatory infiltration of the interstitial tissue In the present series there were nine cases in which necrotizing glomerulitis, epithelial crescents and organizing crescents, and often similar 'explosive' lesions of the glomeruli were present, all occurring in the absence of endocarditis These have been found to be examples of the

than fine, groups of colloid casts in the tubules, and inflammatory changes in the pelvis, together with the clinical history Similarly, some difficulty has been encountered in those cases in which renal rickets has been present and where the kidneys are very small and granular Loss of nephrons is extreme, inflammatory changes may be present in the pelvis, and it may be difficult to decide whether the condition is the late stage of slowly progressive Type 1 nephritis commencing in early life or whether it is due to chronic atrophic pyelonephritis perhaps on the basis of a primary renal hypoplasia These cases have been relegated to a special group to be dealt with in a subsequent paper and are not included under Type 1 nephritis Ellis (1942) pointed out that the kidneys in slowly progressive Type 1 nephritis may show acute arteriolar and glomerular lesions indicating a termination in the malignant hypertensive phase If gross renal contraction is present there is little difficulty in distinguishing the condition from essential malignant nephrosclerosis, in which there is no obvious diminution in the number of glomeruli and the kidney is hardly if at all contracted More difficulty is encountered in occasional cases in young subjects with clinical malignant hypertension and no previous history of acute nephritis, in which the kidneys are somewhat granular, and the histological appearance is typical of malignant nephrosclerosis, but some glomeruli appear to have completely disappeared, so that a previous acute Type 1 nephritis cannot be excluded One or two such cases have been found and have not been included with the Type 1 cases, but will be described in a subsequent paper under malignant hypertension Finally we have encountered a few cases in which the early clinical history was apparently that of Type 1 nephritis and the end-stage and pathology that of Type 2 These will be discussed when our Type 2 cases have been described Case 3 illustrates the rapidly progressive 'stormy' course of Type 1 nephritis and Case 5 is described for comparison as it shows similar clinical and pathological features in periarteritis nodosa Case 6 illustrates Type 1 nephritis with a long latent stage

Type 2 Nephritis

Clinical Features In Type 2 nephritis, Ellis grouped together all those cases of renal disease of insidious onset which run through a long subacute course and in which oedema is persistent and often extreme Albuminuria is gross, but haematuria usually microscopic or absent The group includes cases formerly described as hydraemic nephritis and as nephrosis In some there is a raised blood-pressure from the onset, in others the pressure may remain normal or gradually rise with deterioration in renal function and death in uraemia Oedema may persist to the termination, or may subside leaving a condition indistinguishable clinically from latent or terminal Type 1 nephritis but for the history The disease may occur at any age, our cases ranged from 1½ to 61 years Prognosis is bad and the duration is usually only a few years, but some of the patients with persistently normal blood-pressure recover completely and there is little doubt that the degree of hypertension is some guide in estimating

are again from periarteritis nodosa and also from focal embolic nephritis The presence of endocarditis indicates the correct diagnosis in the latter condition The diagnosis of periarteritis nodosa, in which necrotizing glomerulitis and often widespread epithelial crescent formation are the dominant features, rests on the demonstration of typical arteritic lesions in the kidneys and other organs, together with consideration of the clinical aspects One point which may be brought out is the different age incidence In rapidly progressive Type 1 nephritis the ages of our patients were 15, 18, 19, 23, 23, 24, 24, 25, 26, 30, and 38 years, with an average of 24 0 years In the microscopic form of periarteritis nodosa the ages were 12, 32, 33, 41, 45, 52, 55, 55, 55, 57, 59, 63, and 68 years, with an average of 48·4 years, so that while the majority of rapidly progressive Type 1 cases occur before the age of 30 years, the converse is true for the microscopic form of periarteritis nodosa There is little difficulty in distinguishing rapidly progressive from slowly progressive Type 1 nephritis In the former renal enlargement is the rule, in the latter contraction, which is often gross Histologically the rapidly progressive form shows no loss of glomeruli, though almost all are abnormal, and vascular changes are absent In the slowly progressive form many glomeruli have disappeared, some survivors are enlarged but otherwise normal, and sclerosis of vessels is pronounced

In the slowly progressive type, if seen late in the disease, the clinical diagnosis cannot be made with any assurance unless there is a clear history of acute nephritis in the past In the absence of such a history, renal failure with hypertension in a young subject is more likely to be due to chronic pyelonephritis, and in middle age to malignant hypertension Other rarer causes of renal failure such as periarteritis nodosa and surgical disorders also have to be considered in the differential diagnosis In such cases the knowledge that albuminuria has been found on routine examination many years previously makes a primary renal origin almost certain, but does not establish a diagnosis of Type 1 nephritis A comparison between the degrees of hypertension and renal failure may also be helpful in diagnosis, for cases of chronic Type 1 nephritis can reach an advanced stage of renal failure without extreme rise in blood-pressure Cases of malignant hypertension, on the other hand, never develop renal failure without a very high diastolic pressure (140 at least) In our experience primary malignant hypertension is very rare under the age of 35 years (Platt, 1948) In chronic pyelonephritis careful inquiry, especially when directed to the bladder rather than to the kidney, will usually reveal a history of episodes of frequency and dysuria Positive clinical signs of urinary infection may still be present, but more often organisms can no longer be recovered from the urine at this stage, and even pus cells may be few in number Pathologically also, some difficulty has been encountered in distinguishing slowly progressive Type 1 nephritis from chronic atrophic pyelonephritis in which hypertension has been present In both, contraction may be severe, and loss of nephrons, patchy fibrosis, round-cell infiltration, and vascular sclerosis may all be present Features which when present suggest chronic atrophic pyelonephritis, and are emphasized by Weiss and Parker (1939), are unequal size of the kidneys, coarse granularity rather

In an effort to test Ellis's view that these histological changes represent stages in a continuous sequence from early to late, we related these groups to the duration of illness, where known, as follows

Early 7 weeks, 10 weeks, 5 months, 12 months
Intermediate, Group A 5 months, 11 months, 1½ years, 1½ years, 3 years
Intermediate, Group B 5 months, 8 months, 1 year, 2 years, 9 years
Late 6 months, 2 years, 3 years, 3 years, 4 years, 5 years

Thus, in general, the durations support Ellis's view that the histological changes can be regarded as a true sequence, but no conclusion can be drawn, for instance, as to whether the histological changes in intermediate Group A precede or follow those of Group B It is obvious that differences of rate in progression may occur, so that any attempt to elucidate a progression sequence by comparing duration with histological changes must remain partly conjectural Death from uraemia had occurred in all but one of the six late cases, and on the whole intermediate Group B and the late group showed a greater tendency to hypertension. There was, however, no demonstrable correlation between the amount of albuminuria or oedema and the histological findings

Certain anomalous features must now be described which while not invalidating the main thesis of the Ellis classification are nevertheless of importance Epithelial crescents and partial fibrosis of glomeruli such as characterize Type 1 nephritis were found in three cases in this group In none were such lesions predominant, but their presence suggests that the distinction between Type 1 and Type 2 is not absolute In Case 8, for instance, the clinical history was unequivocally that of Type 2 nephritis, and while most glomeruli corresponded to those of Group B of intermediate Type 2, yet several glomeruli showed partial fibroblastic obliteration, and several others epithelial crescent formation The blood-pressure of 165/100 was not high enough to be regarded as a cause of these glomerular lesions In Case 11 also (described fully later) typical epithelial crescents were present. A second histological feature, not specifically mentioned by Ellis as occurring in Type 2 nephritis, was periglomerular fibrosis This was seen in several cases, usually in the later stages when glomerular hyalinization was severe

Although, as mentioned previously, histological features characteristic of Type 1 nephritis, such as epithelial crescents, partial fibrosis of glomeruli, or periglomerular fibrosis, may occasionally be encountered in kidneys otherwise showing typical Type 2 lesions, yet, in general, the distinction between Type 2 and Type 1 has been readily made, especially when attention is directed to the numerically predominant glomerular lesions The distinction from the rapidly progressive Type 1 cases in which clinically oedema was a pronounced feature is readily made histologically, although an enlarged pale kidney may be found in both conditions The slowly progressive Type 1 shows gross contraction, which was seen in only one of our Type 2 cases This case was clinically typical of Type 2 nephritis and had run a slow course over five years Oedema had disappeared before death and moderate hypertension with advanced renal failure supervened The kidneys weighed 70 and 58 gm , and their surfaces were finely

the probable rapidity of the disease Out of 34 patients who were followed up by one of us (R. P) before 1939, and about whom information has been sought in 1947, 19 are known to be dead, five are untraced, two are ill with renal failure at the present time, and eight are known to be living and well Of the last group, three still have albuminuria, three have none, and in two cases no recent tests have been made as the patients are in regular employment Thus in a follow-up of about 10 years approximately 25 per cent of cases are living and free from symptoms These figures agree closely with those of Rennie (1947) Death in Type 2 nephritis is usually due to uraemia, but may be caused by intercurrent infections such as pneumonia or peritonitis during the stage of oedema Most of the 22 cases in the present series gave rise to little difficulty in diagnosis either clinically or pathologically In 17 cases the clinical features were sufficiently typical to suggest or to establish the diagnosis In two the data were insufficient Three exceptional cases are described later Diagnosis from Type 1 nephritis is usually easy because of the insidious onset, gross albuminuria, and persistent oedema, and although, as we have said, all the cases of rapidly progressive Type 1 nephritis in our series ran an oedematous course, they were clinically distinguishable from Type 2 by their abrupt onset and rapid course The clinical picture of Type 2 nephritis may be indistinguishable from diabetic glomerulosclerosis and from amyloid kidney, but the history of diabetes in the former and of tuberculosis or chronic sepsis in the latter makes confusion unlikely Case 7 illustrates the relentless course of a typical severe case of Type 2 nephritis

Pathological features According to Ellis, the earliest stage of Type 2 nephritis consists of capsular adhesions and occasional bland focal necroses in the glomeruli, and the tubules show fatty changes Later developments consist of accentuated lobulation of the tufts and proliferative glomerulitis Later still, the glomeruli are enlarged, showing focal deposition of hyaline material in the intercapillary stroma or a more diffuse hyaline deposition in the whole capillary basement membrane of the tufts Finally, advanced hyalinization of the whole tufts is present, but there is no diminution in the total number of glomeruli, in contrast with the later stage of Type 1 Hypertensive vascular lesions are rarely seen, and interstitial fibrosis tends to be diffuse rather than focal The 22 cases of Type 2 nephritis conformed histologically with one or other of the above described stages, though several showed additional histological features not specifically mentioned by Ellis as occurring in Type 2 nephritis These features will be mentioned in detail later

The cases can be grouped on histological grounds as follows

Early (glomerular changes slight) 5 cases (Plate 22, Fig 5)

Intermediate, Group A (diffuse increase of intercapillary hyaline material without excessive lobulation or enlargement of glomeruli) 6 cases (Plate 22, Fig 6)

Intermediate, Group B (focal deposition of hyaline material and excessive lobulation of enlarged glomeruli) 5 cases (Plate 22, Fig 7)

Late (massive hyalinization of glomeruli and severe fibrosis) 6 cases (Plate 22, Fig 8)

homogeneous group from which a series of cases could be arranged showing a gradual transition from the mildest to the most severe on both clinical and pathological grounds We agree with Ellis that the artificial separation from amongst these cases of a group having the clinical features of nephrosis is not justified, but we must now refer to three anomalous cases (Nos. 9, 10, and 11) which clinically appeared to start as Type 1 nephritis but to end as Type 2 These cases are described fully in the Appendix In Case 9 the information is hardly adequate, but Case 10 is well documented, and Case 11 was observed by ourselves in the latter part of his course and personally questioned about his initial illness Case 10 had some of the features of Type 2 nephritis, but the sudden onset after an infection, the severe headache, facial oedema, and haematuria strongly suggest a rapidly progressive Type 1 nephritis Histologically, however, inflammatory lesions of the glomeruli, epithelial crescents, or other features of Type 1 nephritis were conspicuously absent, and the only diagnosis acceptable was Type 2 (early stage) Case 11 is the most striking, however, for the history of nephritis with oedema of a few weeks' duration after a sore throat and leading to a latent period of nine years seems to establish the diagnosis of Type 1 nephritis, and only the last nine months of the illness showed the features of Type 2 Pathologically there was no doubt that the macroscopic and microscopic appearances were characteristic of Type 2 nephritis, although some epithelial crescents were present These can scarcely be adduced as evidence of a Type 1 onset, however, since this occurred nine years before death, and they may with more probability be regarded as secondary to the arteriolar and glomerular fibrinoid necrotic lesions which were present in this case It might be argued that this was a rare coincidence in which Type 2 nephritis supervened upon healed Type 1 nephritis, but the finding of albuminuria during the latent stage and the development of nocturia are evidence against healing, and if unhealed, the underlying pathology of slowly progressive Type 1 nephritis should have been demonstrable (contraction, disappearance of glomeruli, interstitial fibrosis, etc) These three cases in which a clinical Type 1 onset is associated with a subsequent Type 2 course and morbid histological findings do therefore provide evidence that the distinction between Type 1 and Type 2 nephritis is not absolute Similarly the occasional occurrence of epithelial crescents and partial glomerular fibrosis in cases otherwise clinically and pathologically Type 2 nephritis further argues against an absolute histological distinction Nevertheless, while we are still in ignorance of the cause of nephritis, we can offer only a provisional conclusion that the Ellis classification is sound in practice and leads in the great majority of cases to clinical and pathological agreement We reserve judgement on the question of whether Type 1 and Type 2 nephritis are separate entities aetiologically, and despite our three doubtful cases we admit that we cannot quote a case of Type 1 nephritis personally observed in the acute stage and followed by the clinical or pathological picture of Type 2 It is clear that the concept so common in text-books, of oedematous nephritis as a usual intermediate stage between the acute and chronic phases, is at variance with clinical experience

granular Many glomeruli, though preserved, were completely hyalinized. Inflammatory changes were present in the pelvis in this case, however, and it may represent a combination of Type 2 nephritis with pyelonephritis

Amyloid disease may produce apparent increase of glomerular intercapillary hyaline material, this is usually more massive than that seen in Type 2 nephritis, and gives the specific stain The lesions of diabetic glomerulosclerosis, described by Kimmelstiel and Wilson (1936), in their typical form of well-defined oval or round hyaline masses, are distinctive enough, but the separation from Type 2 nephritis is more difficult when the diffuse type of glomerulosclerosis is present, since the staining reactions of the two lesions are not necessarily distinguishable Usually in diabetic glomerulosclerosis some glomeruli are completely fibrotic and others are unaffected, while in Type 2 nephritis the glomeruli tend to be involved to a uniform degree A further point is that hyaline arteriolosclerosis is common in diabetic glomerulosclerosis, but is rare in Type 2 nephritis In practice, clinical evidence of diabetes will aid the distinction

The so-called wire-loop lesions in disseminate lupus may somewhat resemble the glomerular lesions of the diffuse kind in Type 2 nephritis, but are usually much more sharply defined Histological changes in other organs such as the spleen confirm the diagnosis of lupus, as well as consideration of the clinical features

In dehydration, such as occurs in diabetic coma, a uniform degree of dilatation of the convoluted tubules with the presence of atrophic epithelium may closely resemble the tubular changes met with in Type 2 nephritis, but the glomeruli show no changes and there is no intertubular fibrosis Similarly the anoxic kidney (Macgraith, Havard, and Parsons, 1945) may show tubular changes similar to those of Type 2 nephritis, but here necrosis of the distal tubules is often a distinguishing feature and the clinical considerations are a valuable aid Three cases were encountered in which oedema and raised blood-urea associated with cardiac failure had been present, and the kidney tubules showed changes similar to those of Type 2 nephritis, but the absence of definite glomerular lesions and knowledge of the clinical course enabled the distinction from Type 2 nephritis to be made

As regards the correlation of histological lesions and clinical data, we can say that all the cases in which the great majority of the glomeruli complied with Ellis's description of Type 2 lesions had had clinical features indicative of Type 2 nephritis during life

Clinico-pathological Discussion on the Distinction between Type 1 and Type 2 Nephritis

The distinction between Type 1 and Type 2 nephritis both clinically and histologically has been in the majority of our cases satisfactorily achieved, and seems to us to represent a real advance in the classification of renal disease The cases which have been grouped together in Type 2, though varying considerably in their course, duration, severity, and age at onset, seem to us to form a fairly

APPENDIX

CASE 1 A girl of 14 years was admitted to the Manchester Royal Infirmary on July 27, 1947 A week before admission she had begun to feel sickly and for three days had vomiting and diarrhoea She had also had right-sided headache During this time bruising of the skin had been noticed, the urine had been dark in colour, and she had become short of breath There had been no dysuria and no relevant previous illness

On examination there was pallor and obvious dyspnoea No abnormal signs were discovered in the chest, heart, or abdomen The blood-pressure was 130/70 There were many bruises on the legs

The blood count showed red cells 1,930,000 per c mm , haemoglobin 38 per cent , colour index 0 99, white cells 10,700 per c mm , and reticulocytes 18 per cent The bleeding time was 4 minutes and clotting time 4½ minutes Repeated blood counts gave similar results The sternal marrow was reported as normal The urine contained many cellular and granular casts with some leucocytes and red cells Chemical tests were positive for blood and albumin

Her general condition deteriorated and spots appeared on the legs, arms, face, and neck. Many of these were raised and urticarial in appearance with haemorrhagic centres On August 6 she complained of loud buzzing in the ears and this was followed by an epileptiform convulsion On recovery she was confused, and the blood-pressure was 160/70 The blood urea was found to be 372 mg per 100 c c She died on August 8 , the mode of death was not recorded.

Comment The clinical findings in this case seem to be compatible with a diagnosis of purpura of the Henoch-Schönlein type, with an accompanying acute nephritis, but it is to be noted that oedema and diastolic hypertension were not found.

Summary of autopsy findings

Heart (280 gm) No abnormality was present

Lungs The right lung contained a small haemorrhagic area in the lower lobe The left lung showed a larger similar area in the lower lobe

The liver, spleen, pancreas, and alimentary tract showed no abnormality

Right kidney (200 gm) The capsule stripped easily, showing a smooth congested cortex On section the cortex was swollen and the pattern obscured The medulla showed patchy congestion

The left kidney (160 gm) appeared similar to the right

Histology

Lungs Extensive areas of intra-alveolar haemorrhage were present Within these areas were foci of polymorphonuclear infiltration and pink-staining exudate No associated arteritis was seen

Kidney The normal number of glomeruli were present and changes appeared relatively slight Most glomeruli showed enlargement and distortion, the capillary loops were prominent and endothelial cells swollen A number of the tufts contained polymorphonuclear cells Several tufts showed intense congestion and dilatation of all capillaries Several afferent arterioles showed fibrinoid necrosis The larger vessels were healthy. The convoluted tubules tended to be dilated and the epithelium was atrophic A number of tubules contained red cells and others contained brownish casts Small foci of lymphocytes were present in the interstitial tissue, but there was no fibrosis The liver, spleen, adrenal gland, and heart-muscle showed no abnormality

Final diagnosis Acute nephritis in a case of purpura of the Henoch-Schönlein type

Note on Acute Focal Nephritis

One of us (R P) has seen 19 cases which had the clinical features of acute focal nephritis, namely, gross haematuria occurring during an infection, with no oedema or hypertension All recovered, and although four cases had recurrences with subsequent infections, none developed signs of chronic renal disease although followed up for several years The ages of these patients were from three to 30 years We are not prepared to discuss the aetiology or pathology of this type of renal disease, but the clinical separation is convenient because of the good prognosis We think it is less common in recent years, perhaps because of the more efficient treatment of pyogenic infections

Summary

1 A clinico-pathological survey of 188 cases of renal disease has been made in order to assess the validity of Ellis's (1942) classification of nephritis

2 Forty-five cases were encountered in which a diagnosis of Type 1 or Type 2 nephritis was made on clinical and pathological grounds

3 These conditions are described and their diagnosis discussed from both the clinical and pathological points of view

4 Histologically, some features of Type 1 nephritis may be found in Type 2 cases

5 Occasional cases have been seen which appeared to start as Type 1 nephritis, although finally showing clinical and pathological features of Type 2

6 The conclusion is reached that as a practical classification of nephritis the Ellis classification is an advance

7 Judgement is reserved as to whether Type 1 and Type 2 nephritis are variations of the same disease

REFERENCES

Davson, J , Ball, J , and Platt, R (1948) *Quart J Med* N S **17**, 175
Ellis, A (1942) *Lancet*, **1**, 1, 34, and 72
Gairdner, D (1948) *Quart J Med* N S **17**, 95
Kimmelstiel, P , and Wilson, C (1936) *Amer J Path* **12**, 83
Macgraith, B G , Havard, R E , and Parsons, D S (1945) *Lancet*, **2**, 293
Platt, R (1948) *Quart. J Med* N S **17**, 83
Rennie, J B (1947) *Ibid* **16**, 21
Russell, D S (1929) *Medical Research Council, Special Report Series, No 142*
Weiss, S , and Parker, F (1939) *Medicine*, **18**, 221

always rapid Pallor was profound' Oedema increased and affected the back and the abdomen, and fluid accumulated in the pleural cavities The urine throughout her illness contained albumin in amounts varying from 3 to 9 gm per litre Blood was present for the first six weeks On April 16 pericardial friction was noticed, and on April 20 there was a small haemorrhage near the left optic disk On April 25 vomiting commenced and there was marked oliguria from then until she died on May 18 The illness terminated with Cheyne-Stokes respiration and coma

The following investigations were made On March 17, the day after admission, the blood-urea was 64 mg per 100 c c The urea clearance was 25 per cent of normal, plasma-albumin 2 6 gm per 100 c c, and globulin 2 6 gm. per 100 c c Blood culture and urine culture were sterile The maximum urinary specific gravity was 1,015 A blood count showed red cells 2,910,000 per c mm, haemoglobin 50 per cent, colour index 0 86, and white cells 16,800 per c mm On March 31 the blood-urea was 162 mg per 100 c c Another blood count showed red cells 2,080,000 per c mm, haemoglobin 36 per cent., and colour index 0 87 On April 8, after transfusion on April 3, a blood count showed red cells 3,200,000 per c mm, haemoglobin 58 per cent, colour index 0 91, and white cells 11,700 per c mm On April 10 the blood-urea was 264 mg per 100 c c, on April 21 126 mg per 100 c c, and on April 27 78 mg per 100 c c., the haemoglobin then was 42 per cent On May 3 the blood-urea was 142 mg per 100 c c and haemoglobin 44 per cent

Comment A diagnosis of Type 1 nephritis with a rapidly progressive course and persistent oedema was made on the clinical features of the illness Unusual features were the very early development of pericarditis, the continued slight pyrexia, and the high leucocytosis In view of the last two findings alternative diagnoses of bacterial endocarditis and periarteritis nodosa were considered, but the original diagnosis was adhered to Penicillin and sulphamezathine were both tried without effect

Summary of autopsy findings

Heart (420 gm) Organizing fibrinous pericarditis was present and slight hypertrophy of the left ventricle

Pleurae Both pleural cavities contained much straw-coloured fluid

Lungs Both lungs showed oedema and partial collapse

The liver showed passive congestion

Kidneys (120 gm each) The capsular surface was smooth, the cortex was of normal thickness, the pattern was partly obscured, and the colour mottled dark red and yellow

Histology

Pancreas Occasional small arteries showed fibroblastic intimal hyperplasia and moderate perivascular round-cell infiltration

Heart An occasional small artery showed fibroblastic intimal hyperplasia

Kidneys The normal number of glomeruli were present and most showed endothelial hyperplasia of the tufts, which also showed exaggerated segmentation and focal adhesions to the capsules A few glomeruli showed epithelial crescent formation and an occasional crescent had undergone fibrosis In some glomeruli, groups of capillary loops were outlined by eosinophilic fibrinoid material Some tubules were dilated, others were atrophic The arterioles showed no abnormality, but a number of intralobular arteries showed intimal fibroblastic hyperplasia similar to the lesions seen in the heart and pancreas, but no evidence of any phase of periarteritis nodosa was encountered Focal fibrosis of the interstitial tissue was present

CASE 2 A man of 46 years had suffered from periodic attacks of pain for 20 years, thought to be due to peptic ulcer, but an X-ray of his stomach was negative Early in April 1946 he developed a rash on his arms and was treated for seborrheic dermatitis Three weeks later he developed haematuria and oedema of the legs, face, and back He was then attending the out-patient department of another hospital His blood-urea was found to be 170 mg per 100 c c, and he was admitted to that hospital on April 21, 1946 On May 7 he was transferred to the Manchester Royal Infirmary He was then vomiting and acutely dyspnoeic The blood-pressure was 200/120 There was no papilloedema There was a little oedema of the ankles, but not elsewhere The urine contained blood and albumin and the urinary deposit showed red cells, leucocytes, and granular casts The blood-urea rose to 530 mg per 100 c c, there was severe oliguria, and he died on May 17 It was ascertained from the other hospital that he had not been given sulphonamides

Comment The clinical findings are consistent with a severe acute Type I nephritis, although in this case there is no clear relation to an infective illness

Summary of autopsy findings

Heart (380 gm) There was hypertrophy of the left ventricle

Lungs The right upper lobe showed extensive pneumonic consolidation, partly grey, partly red The left lung showed oedema and congestion

Liver (1,940 gm) Passive venous congestion was present

Spleen (300 gm) Congestion was present

Kidneys (280 and 240 gm) The surface showed scattered small haemorrhagic areas The cortex was thickened and the cortical pattern slightly obscured. The general architecture was preserved

Histology

Kidneys. The normal number of glomeruli were present Some contained small numbers of polymorphonuclear cells in the tufts, and a few showed fibrinous exudate in the capsular spaces, associated with early epithelial crescent formation The tubules were generally dilated, with atrophic epithelium and most contained red cells Oedema of the intertubular connective tissue was marked There was patchy diffuse round-cell infiltration in the cortex and medulla Some glomerular spaces contained red cells and the source of the widespread intratubular haemorrhage was presumably the glomeruli

Diagnosis Acute nephritis with extensive tubular haemorrhage

CASE 3 A single woman, aged 25 years, was admitted to the Manchester Royal Infirmary under the care of R P on March 16, 1947 At the end of January she had had tonsillitis followed by swollen glands in the neck, and was off work for two weeks She returned to work, but within a fortnight (that is, about the end of February) her face became puffy, and a few days later her ankles were swollen The swelling later extended to the knees, thighs, and abdomen At the time that the oedema was first noticed she had had headache and vomiting, and the urine had been bright red in colour for a few days She had also noticed that the amount of urine had diminished at that time

On examination, which was about a fortnight from the commencement of the oedema, she was very pale and appeared seriously ill Her temperature was 100° F and she was sweating The pulse was 120 and the blood-pressure 160/115 The face was puffy in appearance and there was oedema of the feet and ankles but not elsewhere The optic fundi appeared normal The urine was smoky in appearance and contained blood and albumin

The course of the illness was striking An irregular pyrexia with temperatures reaching 100° or 101° F continued for the first six weeks The pulse was

asthma since she was four years of age, and lately had been more and more troubled by bronchitis In September 1946 she had had a retinal detachment in the right eye She attributed this to a slight blow on the head which she had received 14 days before While she was in hospital for the eye condition she had had rheumatic pains in the ankles and knees, not for the first time On returning from hospital she had noticed swelling of the legs for a few weeks, and since the retinal detachment had had frequent headaches For the previous six months the asthma and bronchitis had been troublesome In March 1948 her son developed a sore throat with enlarged cervical lymphnodes A week later the patient developed similar symptoms, followed by more rheumatic pains in the legs, and a fortnight after the sore throat by swelling of the face and legs accompanied by headache and a change in colour of the urine to a dark red or brown The oedema persisted, and for a few days before admission she had had epigastric pain, nausea, and vomiting

She was a thin, ill-looking woman. There were numerous adventitious sounds at the lung bases and oedema over the ankles and sacrum The blood-pressure was 200/105 The urine contained blood and albumin The lens of the right eye was opaque The left fundus appeared normal

Throughout her stay in hospital the oedema remained, sometimes increasing and sometimes becoming less Irregular pyrexia was present until the last few weeks of the illness The blood-pressure came down to 140/90 a few days after admission, but rose again to levels of about 170/90, where it remained At the end of May there was an attack of what appeared to be broncho-pneumonia, which did not respond to penicillin On June 8 pericardial friction was first heard and this persisted until the end At times there were severe attacks of asthma The patient died on July 1 in a state of uraemia

The following investigations were made The urine contained albumin varying from 2 to 7 gm per litre The blood count on admission showed red cells 3,370,000 per c mm , haemoglobin 60 per cent , and white cells 8,600 per c mm The anaemia gradually increased, and from May 24 there was a constant leucocytosis varying from 18,000 to 23,000 per c mm The serum-albumin was usually 2 4 gm per 100 c c and globulin 2 5 gm per 100 c c The blood urea was 72 mg per 100 c c on admission, but gradually rose to 360 mg on June 28

Comment This was a case in which periarteritis nodosa was suggested as a probable diagnosis when the patient came into hospital Nevertheless the recent illness closely resembled the rapidly progressive form of Type 1 nephritis, which was considered to be the more likely diagnosis

Summary of autopsy findings

Heart (290 gm) The left ventricle was dilated but not hypertrophied. Fibrinous pericarditis was present The mitral valve showed thickening of the anterior curtain and of the chordae tendineae

Lungs The right lung showed fibrinous exudate over the lower lobe Both lungs showed extreme oedema and congestion

Small intestine Numerous submucous haemorrhages were present

Liver (750 gm) The sectioned surface appeared mottled greenish-fawn in colour, and numerous small haemorrhagic areas were present

The pancreas showed irregular areas of haemorrhage

Spleen (60 gm) The surface was covered by a fine fibrinous exudate On section there was no abnormality

Kidneys (100 and 120 gm) The surfaces were smooth and pale, showing occasional small haemorrhages On section the cortical pattern was preserved and the medulla appeared congested

Diagnosis A somewhat atypical case of rapidly progressive Type 1 nephritis in which epithelial crescent formation was scanty Although vascular lesions were present they did not indicate a diagnosis of periarteritis nodosa

CASE 4 A man of 25 years was admitted to the Manchester Royal Infirmary on August 4, 1945, complaining of swelling of the feet and legs, which had been present for six days At the commencement of the illness his face had been puffy The previous history was important Fifteen years before he had had an attack of haematuria and was kept in bed for a month No further investigations seem to have been made and no oedema was noticed at the time Eleven years before there had been another attack of haematuria Five years before he had been discharged from the army for 'nephritis', but it seemed that there was no illness at that time, and in all probability his discharge was due to the finding of albuminuria on a medical examination

On examination there was oedema of both legs as far up as the knees The blood-pressure was 165/95, and the heart appeared normal The urine contained protein varying in amount from 3 to 6 gm per litre, and haematuria was present throughout

The blood-urea on August 6 was 32 mg per 100 c c , serum-albumin 3 0 gm per 100 c c , and serum-globulin 2 0 gm per 100 c c The urine contained many red cells, leucocytes, and casts

His condition deteriorated and on September 14, a week before death, the blood-urea was 292 mg per 100 c c , and the blood count showed red cells 2,440,000 per c mm , haemoglobin 42 per cent , and white cells 6,500 per c.mm

Comment This case was not seen by us during life, and on reading the notes it was thought at first to represent the terminal stage of a Type 1 nephritis which had commenced 15 years ago, but the normal blood-urea on August 6 was against this diagnosis, as was also the oedema which occurred for the first time six days before admission On re-reading the notes after considering the histological findings, the diagnosis appears to be a rapidly progressive Type 1 nephritis with a previous pyelonephritis

Summary of autopsy findings

Heart (300 gm) Slight hypertrophy of the left ventricle was present

Lungs Marked oedema was present in both lungs

Liver The appearances suggested slight fatty change

Spleen (330 gm) There was no abnormality

Kidneys (300 and 345 gm) The capsular surface was smooth, the cortex thickened, and its pattern obscured in parts The pelvis showed haemorrhages The kidneys were similar

Histology

The normal number of glomeruli were present Most showed well-developed epithelial crescents, many of the tufts contained polymorphonuclear cells, and often the capillary loops were outlined by eosinophilic hyaline material which gave a positive fibrin stain A few glomeruli were undergoing fibroblastic obliteration The tubules were atrophic and dilated, and some contained polymorphonuclear cells There was diffuse polymorphonuclear and lymphocytic infiltration of the interstitial tissue The pelvis showed haemorrhage, oedema, and diffuse infiltration by polymorphonuclear cells, lymphocytes, and plasma cells The vessels showed no changes

Diagnosis Rapidly progressive Type 1 nephritis complicated by subacute pyelitis and pyelonephritis

CASE 5 A married woman of 57 years was admitted to the Manchester Royal Infirmary under the care of R P on May 10, 1948 She had suffered from

and its pattern lost, but the demarcation from the medulla was clear The kidneys were similar.

Histology

Many glomeruli had disappeared, occasional groups of small sclerotic glomeruli were present A few enlarged glomeruli appeared normal The tubules showed alternating areas of atrophy and dilatation, and diffuse interstitial fibrosis was present The arcuate and intralobular arteries showed severe intimal fibrosis Hyaline arteriolosclerosis was present

Diagnosis Late stage of slowly progressive Type 1 nephritis

CASE 7 A girl of 19 years was admitted to the Manchester Royal Infirmary under the care of R P on March 20, 1946 Her illness had started 12 months before, with swelling of the ankles This bore no relation to any infective illness and the onset was insidious There was no haematuria The swelling rapidly increased and became generalized, and she was admitted to a hospital in London, where she was then working While in hospital the oedema became extreme and at one time her weight reached 20 st The symptoms gradually improved and she returned to her home in Manchester The oedema never entirely cleared and for a few weeks before admission to the Manchester Royal Infirmary it had become more troublesome, affecting the legs, thighs, back, and abdomen

Examination showed that the disease was already far advanced In addition to the oedema the blood-pressure was 220/145, but there was at that time no retinopathy There was a moderate anaemia, a blood count showed red cells 3,460,000 per c mm, haemoglobin 68 per cent, and white cells 8,400 per c mm The blood-urea was 44 mg per 100 c c The urea clearance was 30 per cent of normal The serum-albumin was 2 5 gm per 100 c c, and globulin 2 8 gm per 100 c c The urine contained from 6 to 12 gm of protein per litre Her general condition deteriorated She developed severe headaches with vomiting, and the blood-pressure remained at about the same level In June papilloedema was noticed and there were a few retinal haemorrhages, but about this time there was an improvement in the headaches and the oedema had practically disappeared She was discharged at her own request on August 14

On September 9, 1946, she was re-admitted on account of recurrence of oedema, shortness of breath, and deterioration in vision The blood-pressure was now at a somewhat lower level, varying between 160/120 and 200/130 There was oedema of the legs and advanced retinopathy with papilloedema, exudates, and haemorrhages Vomiting recurred, the anaemia increased, and the blood-urea rose to 164 mg per 100 c c on January 26, 1947 She died of uraemia and heart failure on February 26

Comment The clinical diagnosis of severe Type 2 nephritis with hypertension and renal insufficiency was never in doubt

Summary of autopsy findings

Heart (640 gm) Early pericarditis was present The left ventricle was hypertrophied and dilated

Lungs Both pleural cavities contained large amounts of clear yellow fluid and both lungs were collapsed

The liver, pancreas, spleen, and intestines showed no abnormality

Kidneys (120 and 140 gm) The surfaces were smooth and pale The cortex appeared normal in thickness, the pattern was somewhat obscured in parts, and lipoid streaking was present in the juxta-medullary zone

Histology

The liver, thyroid, and spleen showed no abnormality

Histology

Liver There were numerous centrilobular areas of haemorrhage and necrosis which were not, however, as widespread as is seen in passive venous congestion Occasional small hepatic artery branches showed fibrinoid necrosis of the wall and thrombotic obliteration of the lumen with surrounding perivascular round-cell infiltration

Pancreas There were scattered areas of haemorrhage and leucocytic infiltration in the interstitial tissue, and an occasional small artery showed fibrinoid necrosis of the wall with perivascular lymphocytic infiltration.

Adrenal A small artery showed fibroblastic obliteration of its lumen

Small intestine Occasional submucosal arterioles showed fibrinoid necrosis and perivascular round-cell infiltration

Kidneys There was no diminution in the total number of glomeruli, but several were completely fibrotic, and others showed partial fibroblastic obliteration The majority showed degrees of capillary collapse and the endothelial nuclei were prominent Occasional epithelial crescents were seen The tubules showed alternating areas of dilatation and atrophy The arterioles showed no definite arteriolosclerosis, but a number of the intralobular arteries showed fibroblastic intimal sclerosis, no acute necrotizing lesions were seen Interstitial fibrosis and round-cell infiltration were widespread

Diagnosis The extra-renal vascular lesions suggest periarteritis nodosa, the renal lesions resemble those of the atypical rapidly progressive Type 1 nephritis seen in Case 3

CASE 6 A woman of 34 years was admitted to the Manchester Royal Infirmary on July 10, 1939 She had recently been suffering from severe headaches which were periodic and accompanied by vomiting On the day of admission she had a convulsion She stated that at the age of 16 years she had had nephritis and had been kept in bed for six months Since that time she had suffered from headaches which were recently more frequent and severe Her blood-pressure was known to have been high for several years

On examination the blood-pressure was 225/115 There was no papilloedema The urine contained small quantities of albumin and the maximum specific gravity was 1,012 The deposit contained some leucocytes and hyaline casts, and cultures were sterile The blood-urea was 42 mg per 100 c c, the urea clearance 22 per cent of normal, and the haemoglobin 86 per cent She improved in hospital and was allowed to return home

Five years later she was re-admitted in her final illness at the age of 39 years on July 14, 1944 For six months or more her condition had been deteriorating, and she had suffered from breathlessness and dimness of vision For the last two weeks there had been oedema of the face and ankles, and during the last three days she had been drowsy and had had frequent vomiting On admission she was semi-comatose and dehydrated Muscular twitching was observed The blood-pressure was 205/100 The blood-urea was 490 mg per 100 c c, and she died in uraemia two days after admission

Comment This is a typical example of the slowly progressive course of Type 1 nephritis, the interval between the initial attack and the terminal illness being 23 years

Summary of autopsy findings

Heart (500 gm) There was marked hypertrophy of the left ventricle

The lungs, liver, and spleen showed passive venous congestion

Kidneys (20 gm each) The surface was finely granular, the cortex very thin,

admission she had suffered from attacks of vomiting Albumin was present in the urine The blood-pressure was 175/105 The blood non-protein nitrogen was 200 mg per 100 c c She died of uraemia

Comment The patient was admitted many years before Ellis's classification was in use, and the description of the initial illness is lacking in detail, but the onset of oedema after a sore throat suggested Type 1 nephritis It must, however, be admitted that the tendency to recurrent attacks of oedema during the next three years was more suggestive of Type 2 nephritis, and the clinical diagnosis must therefore remain in doubt The autopsy findings are not available

Histology

Kidneys The normal number of glomeruli were present, and most showed increased segmentation of the tufts with both focal and diffuse deposition of intercapillary hyaline material Some glomeruli had undergone almost complete hyalinization, but these were a minority, and often showed periglomerular fibrosis An occasional epithelial crescent was seen The convoluted tubules were mainly dilated and lined by hypertrophied epithelium There was diffuse interstitial fibrosis and lymphocytic infiltration The vessels showed no changes

Diagnosis Type 2 nephritis in late stage

CASE 10 A boy of 14 years was admitted to the Manchester Royal Infirmary on April 21, 1946 There was no relevant previous history About seven weeks before admission he had developed a sore throat, but had not gone to bed Two weeks later he had been noticed to be puffy around the eyes in the morning His face had become swollen, he had developed abdominal pain, and within a day or two the legs and arms had also become swollen and he complained of severe headache He was admitted to another hospital where he remained for several weeks On his admission there it was noted that he was breathless and he vomited several times

On transfer to the Manchester Royal Infirmary there was oedema of the face, legs, genitals, abdominal wall, and chest wall The blood-pressure was 130/80 The urine contained blood and albumin, the specific gravity being 1,030 An Esbach's test showed more than 24 gm per litre on admission and later 10 gm. The blood-urea was 92 mg per 100 c c , the serum-albumin 2 0 gm per 100 c c , and globulin 2 0 gm per 100 c c A blood count showed red cells 5,260,000 per c mm , haemoglobin 96 per cent , white cells 12,300 per c mm , and blood-cholesterol 435 mg per 100 c c

He developed an attack of severe abdominal pain suggesting peritonitis and accompanied by a rise in temperature This was apparently the cause of death

Comment This case was not seen by us during life The acute onset after a sore throat and accompanied by haematuria and dyspnoea strongly suggests Type 1 nephritis Nevertheless, when one is informed of the pathological picture and re-reads the notes, several anomalous features suggesting Type 2 nephritis can be seen, such as the large amount of albumin, the absence of anaemia, the high blood-cholesterol, and the terminal attack of peritonitis It does, however, appear to be a case in which the clinical diagnosis between the Type 1 and Type 2 nephritis is difficult, if not impossible

Summary of autopsy findings

Heart (220 gm) The pericardial sac contained about 100 c c of clear fluid. The mitral valve showed several small fibrotic vegetations. No hypertrophy of the left ventricle was found

Lungs Both pleural cavities contained much clear fluid. Both lungs appeared largely collapsed

Kidneys The normal number of glomeruli were present, some were completely hyalinized, but the majority were enlarged, showing diffuse deposition of hyaline material in the tufts, which were often excessively segmented. A few glomeruli showed slight periglomerular fibrosis The convoluted tubules were mainly small and lined by atrophic epithelium Some showed marked fatty change There was diffuse fibrosis and round-cell infiltration of the interstitial tissue An occasional arcuate artery showed elastosis, and an occasional intralobular showed intimal fibrosis, the arterioles showed no abnormality

Diagnosis Fairly late stage Type 2 nephritis

CASE 8 A man of 33 years was admitted to the Manchester Royal Infirmary on September 18, 1946 In April of that year he had noticed swelling of the ankles, which gradually spread to the legs and the abdomen, and was accompanied by shortness of breath on exertion At the commencement there was some swelling of the face There was no preceding infection and no haematuria The condition did not improve and he had been in bed at home for many weeks

On admission oedema was gross and generalized The face was affected as well as the chest wall, abdomen, back, and legs There was bilateral pleural effusion The blood-pressure was 165/100, but later fell to 120/80 The retina showed no papilloedema, haemorrhages, or exudates Pericardial friction developed and he had several attacks of pulmonary oedema, in one of which he died on November 10, 1946

The blood count showed red cells 4,720,000 per c mm, and haemoglobin 92 per cent The blood-urea was 48 mg per 100 c c on admission, but rose later to 124 mg per 100 c c The serum-albumin was 2 6 gm per 100 c c, and globulin 2 7 gm per 100 c c

Comment The extreme generalized oedema with insidious onset could be diagnosed clinically only as Type 2 nephritis

Summary of autopsy findings

Heart (380 gm) Hypertrophy of the left ventricle was present

Lungs Both pleural cavities contained much clear yellow fluid, and both lungs appeared collapsed

The liver, pancreas, and spleen showed no abnormality

Kidneys (210 gm each) The surface was smooth, the cortex was slightly thickened and indistinctly mottled red and pale yellow The medulla was dark red and clearly demarcated from the cortex Both kidneys were similar

Histology

Kidneys The normal number of glomeruli were present, and the great majority showed excessive segmentation with diffuse and focal deposition of intercapillary hyaline material A few glomeruli showed epithelial crescents, and a few others showed partial fibroblastic obliteration The tubules showed little change beyond degrees of dilatation, and intertubular fibrosis was slight The blood-vessels showed no changes

Diagnosis Type 2 nephritis with occasional epithelial crescents and partial glomerular fibrosis as atypical features

CASE 9 A woman of 23 years was admitted to the Royal Infirmary, Sheffield, in August 1936 and died three days after admission The clinical records are unfortunately scanty Three years before she had had a sore throat, which was followed by pain in the back and swelling of the face and feet Albumin was found in the urine at that time and she was kept in bed for several weeks Oedema of the feet had recurred from time to time during those three years and had become more severe during the previous few months Shortly before

suggest Type 1 nephritis with a slowly progressive course The last eight months of the illness, however, had the course of Type 2 nephritis

Summary of autopsy findings

The heart showed pronounced hypertrophy of the left ventricle

Lungs Both lungs showed marked oedema

The liver and spleen showed passive venous congestion

Kidneys Both were enlarged to about twice their normal size The cortex was enlarged and the cortical pattern was obscure and mottled red and yellow

Histology

The normal number of glomeruli were present Most were enlarged showing focal or diffuse increase of intercapillary hyaline material and excessive segmentation Focal adhesions were frequent A few glomeruli showed epithelial crescent formation The tubules were generally dilated and lined by atrophic epithelium There was diffuse interstitial fibrosis and round-cell infiltration The arcuate and intralobular arteries were healthy, but a number of arterioles showed fibrinoid necrosis

Diagnosis Type 2 nephritis Intermediate stage with terminal hypertension.

The liver and spleen showed passive venous congestion

Kidneys (160 and 140 gm) The cortex appeared thickened, but the cortical pattern was preserved, and the demarcation from the medulla was clear The two kidneys were similar

Histology

The normal number of glomeruli were present and most showed slight increase of intercapillary connective tissue with occasional focal adhesions of the tufts to the capsules The tubules showed general dilatation and were lined by swollen epithelial cells with degenerate cytoplasm There was no fibrosis or round-cell infiltration of the interstitial tissue

Diagnosis. Type 2 nephritis, early stage

CASE 11 A young man of 22 years was first seen by R P in the out-patient department in May 1947 He was a physics research student and a highly intelligent witness He stated that in 1938, at the age of 13 years, he had had 'nephritis' The illness consisted of swelling of the face and ankles after a severe cold and sore throat He was kept in bed for four or five weeks After this illness his health apparently returned to normal and he was not examined until 1943, having been quite well during those five years This was a routine examination and albumin was found in the urine He was advised to take a low-protein diet and to have his tonsils removed Tonsillectomy was performed in September 1944 He remained in good health until April 1947, nine years after the initial illness, when he again noticed oedema of the ankles, particularly at the end of the day

Examination showed a man of normal appearance, but with some oedema of the ankles The blood-pressure was 135/90 There was no retinopathy The heart was normal The following investigations were made

A blood count showed red cells 4,720,000 per c mm and haemoglobin 92 per cent The blood-urea was 44 mg per 100 c c , and urea clearance 56 per cent of normal The serum-albumin was 2 6 gm per 100 c c and globulin 2 1 gm per 100 c c The blood-cholesterol was 402 mg per 100 c c The urine contained some leucocytes, red cells, and casts, with 5 gm of albumin per litre The maximum urinary specific gravity was 1,020 The clinical picture at the time therefore suggested a mild Type 2 nephritis, although the previous history with the latent period of nine years indicated Type 1 His subsequent history was that of a Type 2 nephritis of increasing severity

He was given a high-protein diet and seen again in November 1947 Oedema of the ankles had increased and there was some swelling of the face The blood-pressure was 155/90 The blood-urea was 52 mg per 100 c c , serum-albumin 4 5 gm per 100 c c , and serum-globulin 2 4 gm per 100 c c The urinary protein was 6 gm per litre On December 2, 1947, he was admitted to the Manchester Royal Infirmary The blood-pressure was then 170/100, blood-urea 54 mg per 100 c c , and urea clearance 47 per cent of normal He improved temporarily on a high-protein low-salt diet, but was re-admitted on January 12, 1948, as his sight had rapidly deteriorated There was gross general oedema The blood-pressure was 180/115 There was marked retinal oedema with exudates and haemorrhages The blood-urea was 200 mg per 100 c c A blood count showed red cells 1,450,000 per c mm , and haemoglobin 30 per cent The maximum urinary specific gravity was 1,008 The cerebrospinal fluid pressure was 260 mm He died of uraemia on January 17

Comment The initial illness was one of transient oedema after an infection There was then a latent interval of nine years, though we know that in the middle of this period albumin was present in the urine These features strongly

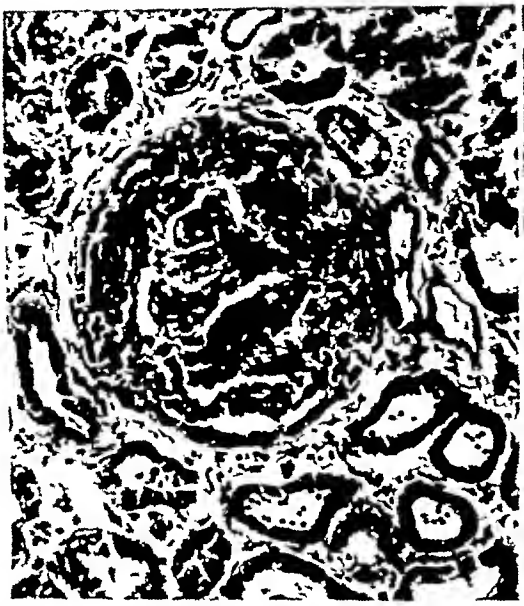

Fig 1

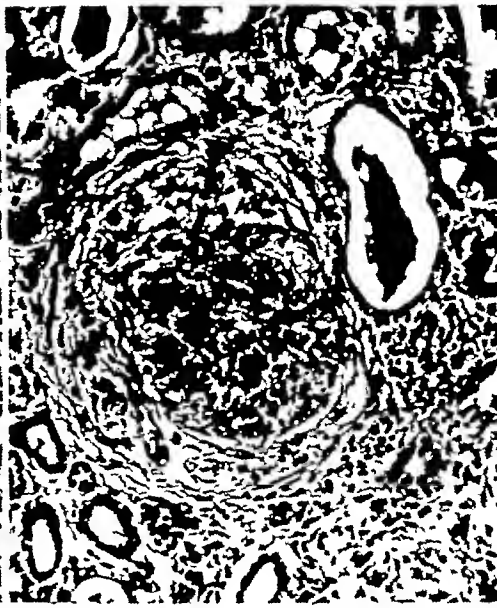

Fig 2

Fig 3

Fig 4

616 155 394

CHRONIC AGRANULOCYTOSIS[1]

By E B ADAMS and L J. WITTS
(From the Nuffield Department of Clinical Medicine,
The Radcliffe Infirmary, Oxford)

Introduction

Osgood, Brownlee, Osgood, Ellis, and Cohen (1939) found that the total leucocyte count of 90 per cent of adult men and women lay between 4,000 and 11,000 per c mm The range of the neutrophil count was 1,500 to 7,500 per c mm We may therefore define leucopenia as a total white blood-cell count below 4,000 per c mm and neutropenia as a neutrophil count below 1,500 per c mm If the reduction in white cells is not secondary to some other well-recognized disorder, it may be called idiopathic leucopenia or essential neutropenia The words agranulocytosis and agranulocytic angina are not so easy to define On historical grounds they should be reserved for the syndrome of acute agranulocytosis which was first described by Schultz (1922), and is usually attributable to sensitivity to drugs Nevertheless, agranulocytosis is often used as a synonym for neutropenia, particularly the essential variety It is preferable to speak of agranulocytic infection when leucopenia is complicated by fever or necrotic inflammation, for the infection is not necessarily confined to the throat, as the word angina would suggest

An inspection of the records of our Clinic over the last few years has revealed the following examples of persistent leucopenia as defined above In addition, there were another six cases of leukaemia, not included in Table I, in which the total white-cell count was between 4,000 and 8,000 per c mm , but the neutrophils were less than 1,500 per c mm It is noteworthy that in the period under review there were no examples of acute agranulocytosis caused by drugs

We have seen agranulocytic infection in most of the conditions listed, and it is probable that all patients with neutropenia, whatever the cause, are liable to this complication Aplastic anaemia comes first in frequency as a cause of leucopenia, the anaemias due to deficiency of liver or iron second Both leucopenia and agranulocytic infection are, in our experience, relatively more common in the macrocytic anaemia of steatorrhoea than in pernicious anaemia In Table I the term reticulosis is used to describe all the progressive hyperplasias of the reticular tissue, including Hodgkin's disease Elsewhere, one of us has discussed leucopenia in the reticuloses and the effect on it of splenectomy (Witts, 1948) Leucopenia can occur in any form of splenomegaly, though it is uncommon in myeloid metaplasia and leukaemia, erythraemia, and septic infections such as subacute bacterial endocarditis, our list includes examples of Banti's disease, Felty's syndrome, sarcoidosis, and kala azar In a paper from

[1] Received November 11, 1948

Fig 5

Fig 6

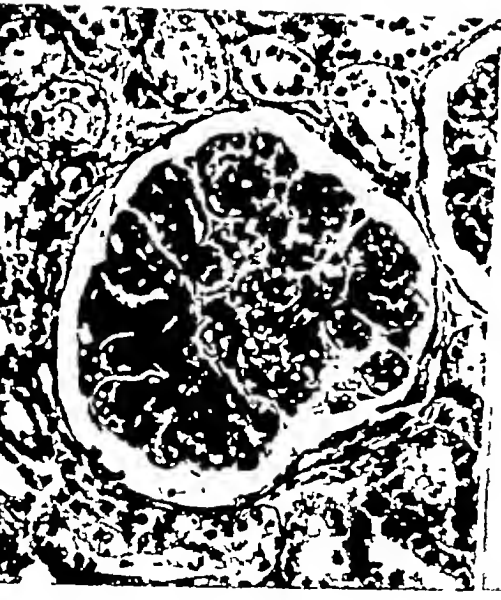

Fig 7

Fig 8

globin was 10 2 gm per 100 c c , red cells 3,900,000 per c mm , and white cells 3,700 (2,516 granulocytes) per c mm

February 1944. She was admitted to St Mary's Hospital with pneumonia after influenza, tonsillitis, and pharyngitis, 15 to 20 gm of sulphonamides were administered, after which a leucopenia of 2,800 (644 granulocytes) per c mm developed The haemoglobin was 10 8 gm per 100 c c , red cells 3,500,000 per c mm , and colour index 1 1 There was no response to pentnucleotide She was transfused There was slow resolution of the pneumonia

May 1944 She was admitted to the Radcliffe Infirmary for investigation The only history of exposure to potentially toxic substances was her use of hair dyes and the sulphonamide administered in February 1944 There was no relevant family history On examination no abnormalities were detected, apart from slight cyanosis of the mucous membranes and prolonged breath sounds at the left base There was no lymphadenopathy, and the liver and spleen were not enlarged clinically The haemoglobin was 10 5 gm per 100 c c , red cells 3,560,000 per c.mm , white cells 2,200 (572 granulocytes) per c mm , platelets 546,000 per c mm , and colour index 1 0 The reticulocytes numbered 2 2 per cent , and the mean corpuscular volume was 95 μ^3 The Price-Jones curve was within the normal range, with a mean corpuscular diameter of 7 03 μ, and standard deviation of 0 44 μ No microcytosis or macrocytosis was present The bone-marrow was very cellular, with considerable leucopoietic and erythropoietic activity, which was normoblastic in type The liver and spleen were normal in size on radiological screening She was discharged taking proteolysed liver.

October 1944 A dental extraction was followed by pyrexia, and she developed an arm infection with lymphangitis An insect bite on the leg was also followed by lymphangitis, rigors, and a large necrotic plaque. The white cells were 1,400 (280 granulocytes) per c mm , haemoglobin 12 4 gm per 100 c c , colour index 1 1, and mean corpuscular volume 103 μ^3 The total plasma-proteins were 8 3 gm per 100 c c (3 9 gm albumin, 4 0 gm globulin) The Takata-ara reaction was strongly positive

April 1945 A vivicillin injection was followed by pyrexia, and a coryza by patchy pulmonary congestion The haemoglobin was 10 2 gm per 100 c c , colour index 1 0, and white cells 4,600 (1,012 granulocytes) per c mm

January 1946 She was admitted to St Mary's Hospital with pneumonia, and treated with penicillin

May 1946 She was admitted to the Radcliffe Infirmary for splenectomy There were no complaints The haemoglobin was 10 8 gm per 100 c c , red cells 3,950,000 per c mm , white cells 2,800 (308 granulocytes) per c mm , platelets 128,000 per c mm , and colour index 1 0 The plasma-bilirubin was 0 3 mg per 100 c c The Price-Jones curve was still within normal limits The sternal marrow was cellular, with considerable leucopoietic tissue, mostly myelocytes and young neutrophils, segmented neutrophils being scanty, there were infrequent mitoses The total plasma-proteins were 9 6 gm per 100 c c (4 45 gm albumin, 4 73 gm globulin) The Takata-ara reaction was strongly positive The spleen and liver were not palpable, and there was no lymphadenopathy Splenectomy was followed by a mild transient rise in white cells (peak 5,300 per c mm) and platelets (peak 593,000 per c mm) The spleen weighed 286 gm Microscopy showed normal anatomy, with congestion A post-operative bone-marrow smear was less cellular than previously She developed persistent furunculosis of the buttocks Six weeks after splenectomy the haemoglobin was 11 6 gm per 100 c c , red cells 4,010,000 per c mm , white cells 4,100 (697 granulocytes) per c mm , and platelets 527,000 per c mm There was no response

this department Fisher (1947) has commented on the relative frequency of neutropenia in acquired haemolytic anaemia, he suggested that there might be a correlation between neutropenia and the occurrence of liver dysfunction in haemolytic anaemia.

Table I includes two unusual cases One case classified amongst the haemolytic anaemias was that of a man with splenopathic neutropenia or splenic

TABLE I

Analysis of 48 Cases of Leucopenia

Aplastic anaemia	13
Liver deficiency anaemia	8
Iron deficiency anaemia	3
Leukaemia	8
Other reticuloses	2
Splenomegaly	6
Haemolytic anaemia	3
Chronic agranulocytosis	5
Total	48

panhaematopenia (Doan and Wright, 1946), who died of agranulocytic infection some weeks after splenectomy, at autopsy a splenunculus was found which accounted for the failure of the operation The other was a man with considerable splenomegaly, a hypoplastic bone-marrow, and an agranulocytic ulcer of the leg for which amputation eventually became necessary This man was alive, still subject to attacks of agranulocytic infection, five years after coming under observation In view of the gross splenomegaly the case was classified as a reticulosis These cases will not be considered further

In the present paper attention will be confined to the last five cases in Table I, in which neutropenia was apparently the primary condition The only constant features were leucopenia and attacks of agranulocytic infection There was no evidence of increased blood breakdown, no deficiency of iron or liver, and no leukaemia or other infiltration A mild degree of anaemia was present in some of the five patients, and the distinction between chronic agranulocytosis and aplastic anaemia is an arbitrary one It is our practice to diagnose aplastic anaemia in cases of this kind if the haemoglobin without treatment is usually below 10 gm per 100 c c The separation of the two groups is usually simple for cases of aplastic anaemia require frequent transfusion, whereas cases of chronic agranulocytosis do not

Case Reports

Case 1 (R I 27685/44) *A housewife of 46 years with persistent leucopenia and numerous attacks of agranulocytic infection, little change in seven years and no response to splenectomy*

The patient's age was 46 years at the (known) onset in 1940

1931 She developed influenza followed by pneumonia After this she had annual protracted attacks of influenza Cuts on the fingers were said always to have suppurated readily

1940 She had influenza, pneumonia, and laryngitis, and was admitted to hospital She developed pyorrhoea and ulceration of the mouth The haemo-

The scabies was treated with benzyl benzoate Granulocytopenia was discovered He had pyrexia ranging between 99° and 103 5° F for 11 days He was given aspirin, phenacetin, caffein, codeine, soluble barbitone, and 16 gm of sulphathiazole The haemoglobin was 13 5 gm per 100 c c , red cells 5,040,000 per c mm , and white cells 3,600 (832 granulocytes) per c mm

August 1943 He was readmitted with persistent furunculosis The white cells were 2,600 (416 granulocytes) per c mm., and haemoglobin 15 0 gm per 100 c c There was no response to pentnucleotide (five injections, each of 10 c c)

September 1943 He was readmitted with the blood findings unaltered.

January 1944 He was admitted to another Military Hospital The spleen was palpable The haemoglobin was 13 5 gm per 100 c c , red cells 5,200,000 per c mm , white cells 1,800 (504 granulocytes) per c mm , platelets 250,000 per c mm , colour index 0 94, and reticulocytes 1 0 per cent Bone-marrow was difficult to obtain and acellular , it showed excess lymphocytes, normal myelocytes, no myeloblasts, and few neutrophils There was no response to a further course of pentnucleotide, and no leucocyte response to the adrenaline test

May 1944 He was admitted to the Radcliffe Infirmary for investigation Examination showed numerous cutaneous scars and that the tip of the spleen was palpable, but otherwise no abnormalities were detected The red cells were 5,820,000 per c mm , white cells 1,800 (144 granulocytes) per c mm , platelets 185,000 per c mm , haemoglobin 14 6 gm per 100 c c , and reticulocytes 0 4 per cent The plasma-bilirubin was 1 2 mg per 100 c c Bone-marrow cellularity was reduced and leucopoiesis diminished X-rays of bones were compatible with mild myelosclerosis, but chronic granulocytopenia was thought to be more likely

January 1945 He was admitted to a London County Council Hospital, where he died in April 1945, from pyaemia, cerebral abscess, acute bacterial endocarditis, and chronic lung abscess, confirmed by autopsy Dr A H T Robb-Smith kindly examined a section of the femoral marrow and reported

> 'The marrow is cellular, with marked congestion of the sinusoids Leukopoiesis is preponderant, the majority of the cells being in the myelocyte and promyelocyte stage, and very few more mature granulocytes are present in the marrow Erythropoiesis is orthoplastic, the majority of the cells being orthochromatic normoblasts, many are pyknotic, but scattered pro-erythroblasts can be made out Megakaryocytes are normal in frequency and in character There is a fair proportion of reticulum cells showing some tendency to plasma cell differentiation and a moderate number of histiocytes containing iron pigment '

The duration of the (known) granulocytopenia was 22 months

Case 4 (R I 62466/46) *A woman of 26 years with chronic agranulocytosis, anorexia nervosa, and chronic pulmonary tuberculosis*

The age of onset was 26 years

1938 She developed mumps, since when there had been amenorrhoea, loss of weight, and loss of energy

December 1944 She developed pneumonia and was found to have a leucopenia of 2,000 (1,260 granulocytes) per c mm , and a macrocytic anaemia with haemoglobin 8 3 gm per 100 c c , red cells 2,700,000 per c mm , and colour index 1 1 There was no response to oral and parenteral liver She was transfused.

March 1945 She developed acute otitis media and a right pleural effusion A guinea pig inoculation test for tubercle bacilli was positive

August 1945 Resolution of the otitis media was at last complete

to folic acid, 5 mg thrice daily, or to vitamin therapy She continued on liver therapy after her discharge The duration of the illness, to August 1947, was seven years

Case 2 (R.I 58457/46) *A housewife of 27 years with persistent mild leucopenia and recurrent agranulocytic infections over a period of seven years*

The age at onset was 27 years

1939 She developed cystitis and was treated with a long course of sulphonamides There had been no relevant past illnesses or exposure to other bone marrow toxins No family history was available

1940 Following a dental extraction after which she had been given phenacetin, swelling of the face, pyrexia, and agranulocytosis appeared The white cells were 2,400 (254 granulocytes) per c mm She was given pentnucleotide, which was discontinued after six injections on account of the severity of the reactions The white cells rose to 5,600 (3,696 granulocytes) per c mm , and the red-cell count was 1,200,000 per c mm one month later, the haemoglobin was 12 4 gm per 100 c c

1942 She was released from the Army with a diagnosis of agranulocytosis

1943 A blood count showed red cells 5,010,000 per c mm , white cells 4,000 (1,640 granulocytes) per c mm , and haemoglobin 13 0 gm per 100 c c The patient kept well.

June 1946 She was admitted to the Radcliffe Infirmary with tiredness of 10 days' duration and influenzal symptoms for three days There was fever There had been slight bleeding from the gums for 10 days and a history of gingival bleeding sporadically since the birth of a child two years previously On examination she appeared healthy There was slight bruising of the shins, desquamation of the palate, herpes labialis, and enlarged lymphnodes in the right carotid triangle, but no other abnormalities The haemoglobin was 15·2 gm per 100 c c , red cells 5,150,000 per c mm , white cells 3,000 (330 granulocytes) per c mm , platelets 255,000 per c mm , and colour index 1 0 The plasma-bilirubin was 0 3 mg per 100 c c The bone-marrow was very cellular, with an unusual degree of early leucopoiesis, erythropoiesis was normoblastic A low-grade urinary infection (*Staphylococcus aureus*) was treated with potassium citrate

October 1946 She was tired, but otherwise well A few small freely movable lymphnodes were present in the axillae and groins The white cells were 3,000 (570 granulocytes) per c mm

1947 She was keeping well Inoculations before going abroad were followed by deterioration in the white-cell count, but there were no symptoms The duration of the illness to June 1947 was seven years At the time of writing she was still alive and well

Case 3 (R I 27155/44) *Chronic agranulocytosis in a soldier of 22 years, ending fatally after two years*

The age at the (known) onset was 22 years The past history revealed that this patient had suffered from boils since the age of eight years, and had had an axillary abscess at 14 years At 17 years, in 1938, he was a lead-worker for one year, apparently adequately protected, and developed no symptoms of lead-poisoning In May 1943 he had acute tonsillitis and gingivitis Furunculosis was common in his family, otherwise there was nothing relevant in the family history

June 1943 He had suppurative cervical lymphadenitis, scabies, and furunculosis, for which he was admitted to a Military Hospital, and an abscess incised.

mean corpuscular volume was 78 3 μ^3 The Price-Jones curve showed no macrocytosis or microcytosis, with a mean corpuscular diameter 6 95 μ, and standard deviation 0 48 μ The bone-marrow was very cellular with no qualitative abnormality, there were relatively few segmented neutrophils She was discharged on liver therapy, but small buccal ulcers recurred repeatedly and granulocytopenia persisted

August 1945 She was readmitted with a large ulcer on the upper lip and in the mouth, of one week's duration, after ulceration of the gums Vincent's spirochaetes were present There was cervical lymphadenopathy and fever There was no response to local treatment The haemoglobin was 13 2 gm per 100 c c , and white cells 8,200 (2,214 granulocytes) per c mm on two days *Streptococcus viridans* was predominant in the ulcer The bone-marrow was cellular, with maturation arrest of granulocytes There was no response to vitamin B, yellow bone-marrow (Armour), or to penicillin locally and parenterally There was slow improvement with scar formation but little change in the leucocyte level The buccal ulcers persisted She was given penicillin pastilles, and advised splenectomy but refused

February 1946 She attended as an out-patient before leaving for the United States of America There had been recent coryza with lymphadenopathy The haemoglobin was 12 4 gm per 100 c c , red cells 4,590,000 per c mm , white cells 4,400 (1,188 granulocytes, 88 lymphoblasts, 2,508 lymphocytes) per c mm , platelets 197,000 per c mm , and mean corpuscular volume 82 8 μ^3.

April 1946 to February 1947 She attended a clinic in Wharton, Texas There was recurrent ulceration of the mouth, apparently not responsive to treatment During this period the blood count varied as follows red cells 3,790,000 to 4,650,000 per c mm , white cells 2,050 to 6,300 (205 to 2,016 granulocytes) per c mm , and platelets 225,000 per c mm were reported The duration of the illness, to Fcbuary 1947, was four years since the original diagnosis

Comment

Four out of the five patients were women, and four out of the five were in the twenties when they came under treatment The woman who was 46 years at the time the leucopenia was recognized may well have begun the disease a number of years earlier All had been exposed to factors which might possibly have damaged the bone-marrow before the diagnosis of agranulocytosis was made, such as hair-dye, sulphonamides, lead, benzyl benzoate, and mumps There is no proof that these factors actually damaged the marrow, and it is just as probable that the illnesses for which sulphonamides were given were manifestations of an already existent agranulocytosis

The course of the disease was characterized by attacks of severe infection from relatively trivial causes They included inflammation of the lips, gums, mouth, and throat, severe reactions to dental extraction, otitis media, septic fingers and cutaneous sepsis, suppurative lymphadenitis, urinary infection, septicaemia, and unexplained fever One patient had slowly progressive pulmonary tuberculosis Intervals between attacks ranged from a few days or weeks to six years Between attacks the patients were fairly well, though they suffered from lack of vitality The average duration of the illness in the four survivors is now more than five years, and there is no evidence of progressive deterioration.

September 1946 She was admitted to the Radcliffe Infirmary with a septic finger The white cells were 2,000 (740 granulocytes) per c mm, red cells 3,400,000 per c mm, haemoglobin 12 4 gm per 100 c c, platelets 118,000 per c mm, colour index 1 3, and mean corpuscular volume 118 μ^3 The bone-marrow showed reduced cellularity with maturation arrest of granulocytes at the myelocyte stage, erythropoiesis was normoblastic She was given folic acid (5 mg. thrice daily for 14 days) and marmite, with no response

October 1946 She was readmitted for investigation There was no history of exposure to possible toxins, except treatment with barbiturates and aspirin two years previously for a septic finger She was emaciated, weight 82 lb The haemoglobin was 12 7 gm per 100 c c, red cells 3,870,000 per c mm, white cells 2,600 (881 granulocytes) per c mm, platelets 177,000 per c mm, colour index 1 1, and reticulocytes 3 per cent The mean corpuscular volume was 106 μ^3 The plasma-bilirubin was 0 3 mg per 100 c c The Price-Jones curve showed a marked shift to the right, with 63 6 per cent macrocytosis, mean corpuscular diameter 8 85 μ, and standard deviation 0 81 μ X-rays of the chest showed a quiescent tuberculous lesion at the left apex, the opacity being minimal There was a low androgen excretion (4 0 mg in 24 hours' urine specimen) There was no response to pyridoxine or to suprarenal cortical extract (100 c c intravenously in two days) She was discharged taking liver extract orally

April 1947 There had been no change She was able to get about satisfactorily without undue disability The tuberculosis was quiescent The haemoglobin was 9 8 gm per 100 c c, red cells 3,120,000 per c mm, white cells 2,300 (943 granulocytes) per c mm, and platelets 176,000 per c mm Transfusions were not necessary

May 1948 She was admitted as an emergency with swollen and painful gums, and considerable irregular fever The haemoglobin was 7 6 gm per 100 c c, white cells 2,100 (462 granulocytes) per c.mm, and erythrocyte sedimentation rate 68/100 mm in one hour A sternal puncture showed thin films that were relatively acellular, and though thick films contained plenty of cells and showed considerable erythropoietic activity, areas showing the structure of the marrow suggested some degree of aplasia The X-ray film of the chest showed no change, but tubercle bacilli were cultured from the fasting gastric contents She was transfused and referred for sanatorium treatment The duration of the known blood dyscrasia was four years

Case 5 (R I 9010/43) *A woman of 24 years with recurrent agranulocytic angina, little change over four years*

The age at onset was 24 years, and her occupation hairdresser

1939 She had an attack of tonsillitis She had been subject to ulcers in the mouth since childhood

July and September 1942 She had two attacks of sore throat with cervical lymphadenitis, and in the second attack an excavated ulcer on the right tonsil Sulphonamides were administered for four days

February 1943 There was a recurrence of sore throat, with low-grade pyrexia The haemoglobin was 11 4 gm per 100 c c, red cells 4,150,000 per c mm, and white cells 2,500 (725 granulocytes) per c mm She was treated with sodium salicylate and a gargle There was no relevant family history, and no history of exposure to known bone-marrow toxins

May 1943 She was admitted to the Radcliffe Infirmary for investigation The haemoglobin was 14 9 gm per 100 c c, red cells 5,490,000 per c mm, white cells 5,000 (750 granulocytes) per c mm, platelets 202,000 per c.mm, and reticulocytes 1 0 per cent The plasma-bilirubin was 0 3 mg per 100 c c The

Table III

Sternal Punctures in Chronic Agranulocytosis

Date	Myeloblast (%)	Promyelocyte (%)	Neutrophil: Myelocyte (%)	Neutrophil: Young form (%)	Neutrophil: Band form (%)	Neutrophil: Segmented (%)	Eosinophil: Myelocyte (%)	Eosinophil: Segmented (%)	Basophil (%)	Lymphocyte (%)	Monocyte (%)	Plasma cell (%)	Megakaryocyte (%)	Proerythroblast (%)	Basophil erythroblast (%)	Polychromatic erythroblast (%)	Orthochromatic erythroblast (%)
Case 1																	
*26 5 44	1 0	0 5	16	15	18	7	2 5	1 5		11 5		3 5		1	10	13	
†31 5 46	1 5	3 0	30	27	9		1 5	1 5		12 5		1			5	5 5	1
Case 2																	
‡12 6 46	1 5	4 5	31	28	14 5	2	2 5	0 5	0 5	5		0 5			1 5	1 5	1
Case 3																	
§14 4 44			14	16		3		3		61	2	1		(Erythrocytes not included in count, but leuco erythrocyte ratio 7 1)			
‖17 5 44		2 0	9	3	7	0 5	1 5	1		39				2	4 5	26 5	3 5
Case 4																	
¶16 9 46	0 8	6 0	22 8	14		4 4	0 4	1 2		16		2 4	0 4	0 4	1 2	36 0	
**28 5 48	1 0	1 0	12 5	15 0	9 0	1 5			0 5	12 5		2 5	0 5	0 5	11 0	25 5	6 0
Case 5																	
††7 5 43	1 5	1 0	15 5	18	16	5 5	4	2 5		14 5	3 5	0 5			1	14 5	2
‡‡20 8 45	2 0	6 5	16 5	13	18	5	5	3 5	0 5	6 5		0 5		0 5	2 5	10 5	9

REMARKS

* Smear very cellular Considerable leucopoietic and erythropoietic activity, apparently normal in type Rather high percentage of plasmatoid erythroblasts and basophil erythroblasts

† Moderately cellular Considerable leucopoietic tissue, though no mitoses were seen Ferrata cells 1 5 per cent

‡ The marrow was extremely cellular with an unusual amount of early leucopoiesis

§ Marrow difficult to obtain (two failed punctures) and rather scanty Granulopoiesis appeared normal, but no myeloblasts were seen

‖ Marrow only moderately cellular Leucopoietic activity diminished Many smudge cells Ferrata cells 0 5 per cent

¶ Cellularity reduced Maturation arrest of granulocyte series at myelocyte stage marked

** Relatively acellular but considerable erythropoietic activity Mitoses 1 0 per cent

†† Marrow extremely cellular No qualitative abnormality

‡‡ Very cellular Typical maturation arrest of acute agranulocytosis

Representative haematological data are summarized in Table II Cases 1 and 4 had a moderate degree of anaemia and macrocytosis at times, usually associated with the attacks on infection, the anaemia was capable of spon-

TABLE II

Representative Blood Counts in Five Cases of Chronic Agranulocytosis

Admission date	Haemoglobin (gm per 100 c c)	Red cells (millions per c mm)	Colour index	White cells (per c mm)	Granulocytes (per c mm)	Platelets (thousands per c mm)	Mean corpuscular volume (μ^3)	Mean corpuscular diameter (μ)
Case 1								
24 11 40	10 2	3 9	0 9	3,700	2,516			
12 1 44	10 8	3 5	1 1	2,800	644			
26 5 44	10 5	3 56	1 0	2,200	572	546	95	7 03
25 10 44	12 4	4 09	1 1	1,400	280		103	
20 1 45	13 0	4 49	1 0	2,600	806	315	85	
25 5 45	10 2	3 6	1 0	4,600	2,024	.	83	
10 12 45	13 5	4 77	1 0	3,400	578	263	86	7 28
31 5 46	10 8	3 95	1 0	2,800	308	128		7 28
24 7 46	11 6	4 01	1 0	4,100	697	527		
Case 2								
12 9 40	.			2,400	254			
4 10 40	12 4	4·2	1 1	5,600	3,696			
26 3 43	13 0	5 01	0 9	4,000	1,640			
9 12 43				3,800	1,976			
12 6 46	15 2	5 15	1 0	3,000	330	255		
3 10 46				3,000	570			
12 5 48	14 4	5 29	1 0	3,100	340	238	87	
Case 3								
8 6 43	13 5	5 04	1 0	3,600	832			
5 8 43	15 0	5 39	1 0	2,600	416			
14 4 44	13 5	5 2	0 9	1,800	504	250		
17 5 44	14 6	5 82	0 9	1,800	144	185		
Case 4								
13 12 44	8 3	2 7	1 1	2,000	1,260			
16 9 46	12 4	3 4	1 3	2,000	740	118	118	
25 10 46	12 7	3 87	1 1	2,600	884	177	106	8 85
28 4 47	9 8	3 12	1 1	2,300	943	176		
14 6 48	8 2	2 33	1 3	1,400	630	103	112	
Case 5								
13 2 43	11 4	4 15	1 0	2,500	725			
7 5 43	14 9	5 49	1 0	5,000	750	202	78	6 95
20 8 45	13 2			8,200	2,214	285		
22 8 45				3,400	476			
13 2 46	12 4	4 59	1 0	4,400	1,188	197	83	
4 2 47	13 8	4 47	1 1	4,600	552			

taneous improvement The white-cell count was usually, though not invariably, subnormal, and there were usually less than 1,000 neutrophils per c mm The platelet count was normal In four of the patients the plasma-proteins were normal except for a slight reduction of albumin, Case 4 showed a persistently high plasma-globulin The blood-urea, plasma-bilirubin, plasma-uric acid, and plasma-phosphatase were within normal limits Free hydrochloric acid was present in the test-meal in the three patients examined

Table III

Sternal Punctures in Chronic Agranulocytosis

Date	Myeloblast (%)	Promyelocyte (%)	Neutrophil: Myelocyte (%)	Neutrophil: Young form (%)	Neutrophil: Band form (%)	Neutrophil: Segmented (%)	Eosinophil: Myelocyte (%)	Eosinophil: Segmented (%)	Basophil (%)	Lymphocyte (%)	Monocyte (%)	Plasma cell (%)	Megakaryocyte (%)	Proerythroblast (%)	Basophil erythroblast (%)	Polychromatic erythroblast (%)	Orthochromatic erythroblast (%)
Case 1																	
*26 5 44	1 0	0 5	16	15	18	7	2 5	1 5		11 5		3 5		1	10	13	
†31 5 16	1 5	3 0	30	27	9		1 5	1 5		12 5		1			5	5 5	1
Case 2																	
‡12 6 16	1 5	4 5	31	28	14 5	2	2 5	0 5	0 5	5		0 5			1 5	1 5	1
Case 3																	
§14 4 11			11	16		3		3		61	2	1		(Erythrocytes not included in count, but leuco-erythrocyte ratio 7 1)			
‖17 5 11		2 0	9	3	7	0 5	1 5	1		39				2	4 5	26 5	3 5
Case 4																	
¶16 9 16	0 8	6 0	22 8	14		1 4	0 4	1 2		16		2 4	0 4	0 4	1 2	36 0	
**28 5 48	1 0	1 0	12 5	15 0	9 0	1 5			0 5	12 5		2 5	0 5	0 5	11 0	25 5	6 0
Case 5																	
††7 5 13	1 5	1 0	15 5	18	16	5 5	4	2 5		14 5	3 5	0 5			1	14 5	2
‡‡20 8 15	2 0	6 5	16 5	13	18	5	5	3 5	0 5	6 5		0 5		0 5	2 5	10 5	9

REMARKS

* Smear very cellular Considerable leucopoietic and erythropoietic activity, apparently normal in type Rather high percentage of plasmatoid erythroblasts and basophil erythroblasts

† Moderately cellular Considerable leucopoietic tissue, though no mitoses were seen Ferrata cells 1 5 per cent

‡ The marrow was extremely cellular with an unusual amount of early leucopoiesis

§ Marrow difficult to obtain (two failed punctures) and rather scanty Granulopoiesis appeared normal, but no myeloblasts were seen

‖ Marrow only moderately cellular Leucopoietic activity diminished Many smudge cells Ferrata cells 0 5 per cent

¶ Cellularity reduced Maturation arrest of granulocyte series at myelocyte stage marked

** Relatively acellular but considerable erythropoietic activity Mitoses 1 0 per cent

†† Marrow extremely cellular No qualitative abnormality

‡‡ Very cellular Typical maturation arrest of acute agranulocytosis

The details of the marrow smears obtained by sternal puncture are given in Table III Not more than 0 2 c c of marrow was aspirated It is difficult to estimate the cellularity of the marrow by sternal puncture, and in cases where the diagnosis has subsequently been confirmed by post-mortem examination we have obtained acellular smears from patients with leukaemia and cellular smears from patients with aplastic anaemia With this proviso it may be noted that the smears were described as cellular in two of the patients and acellular in three The main qualitative change was an increase in the proportion of myelocytes and a great decrease in the proportion of segmented neutrophils There was a relative lymphocytosis in the acellular marrows The erythropoietic tissue and the platelets were normal

The only remedy of proved efficacy was penicillin for the control of the acute attacks It was usually given intramuscularly in a dosage of 60,000 units three hourly. When attacks of infection were occurring frequently a prophylactic

TABLE IV

Changes in the White Cells after Splenectomy in Case 1

Date	*White cells (per c mm)*	*Neutrophils (per c mm)*
5 6 46	2,300	69
6 6 46		
9 a m	Splenectomy	
10 30 a.m	3,300	
4 30 p m	4,100	1,752
7 6 46	5,000	1,400
14 6 46	5,100	765
1 7 46	3,700	185

TABLE V

Sternal Punctures before and after Splenectomy in Case 1

	5 6 46	*6 6 46* Splenectomy	*7 6 46*
Cellularity	Moderate		Low
Myeloblast	1 5		1 0
Promyelocyte	3 0		1 0
Neutrophils			
Myelocytes	30 0		7 0
Young form	27 0		15 0
Band form	9 0		5 5
Segmented			
Eosinophils			
Myelocytes	1 5		2 0
Segmented	1 5		2 0
Lymphocytes	12 5		46 5
Monocytes			5 0
Ferrata cells	1 5		
Plasma cells	1 0		
Endothelial cells			4 5
Normoblasts			
Basophil	5 0		1 0
Polychromatic	5 5		8 5
Orthochromatic	1 0		1 0

dose of 100,000 units was given twice daily No improvement in the white-cell count was noted from transfusion, liver extract, yellow bone-marrow extract, adrenal cortical extract, folic acid, or pyridoxine Pentnucleotide caused a transient rise in the white count, but not enough to compensate for the discomfort

Splenectomy was advised in Case 1 as the patient was having very frequent attacks of infection and the bone-marrow appeared cellular on sternal puncture The operation was carried out without difficulty, but there was little leucocytosis and the marrow picture became more aplastic She had a furuncle on the buttock before operation and it was very troublesome during convalescence A year later there was little change from the pre-operative state other than a slight lymphocytosis This is very different from the normal response to splenectomy, which is a conspicuous outpouring of segmented neutrophils and band forms, with total leucocyte counts of the order of 20,000 per c mm There is not much change in the cellularity of the normal marrow after splenectomy, but there is usually an increase in the myeloid-erythroid ratio (Limarzi, Jones, Paul, and Poncher, 1943) The loss of reactivity in Case 1 is similar to our findings in aplastic anaemia and in a few cases of leukaemia

Discussion

Lawrence (1946) has proposed the classification of agranulocytosis into acute, chronic, and recurrent forms Recurrence implies that the blood is normal between the attacks, in contrast to chronic cases with persistent leucopenia The recurrent group may be further subdivided into the regularly recurrent or cyclical form, and the irregularly recurrent or relapsing form Cyclic neutropenia has been reviewed by Reimann (1948) in an article on periodic diseases Additional cases have been reported in this country by Embleton (1936) and Fullerton (1947) Peculiarities of this syndrome are the extraordinarily regular rhythm in the rise and fall of the leucocyte count, the protracted duration, the resistance to all forms of treatment, including splenectomy, and the relative good health The rhythm appears to be independent of any known natural cycle and the cause is unknown The irregularly recurrent or relapsing cases form an entirely different group The attacks, of which there may be only two or three, occur at unpredictable intervals They are presumably successive attacks of acute agranulocytosis, and they have become less frequent since the recognition of the part played by drug sensitivity In relapsing agranulocytosis, as pointed out by Roberts and Kracke (1930), the blood and bone-marrow are normal in the free interval and the attack is characterized by three successive phases, a bone-marrow onset, a blood-stream onset, and a clinical onset

In recent years interest has been renewed in an uncommon form of leucopenia which was described by Frank (1925) under the name splenopathic leucopenia, but which has been renamed primary splenic neutropenia (Wiseman and Doan, 1939) The features of this syndrome are leucopenia, splenomegaly, and myeloid hyperplasia of the bone-marrow There is usually an associated depression of

red cells and platelets, though it is not agreed whether this is the result of increased blood destruction or inhibition by the spleen of the emission of cells from the marrow (Semple, 1948) Splenectomy usually brings about a cure Just as haemolytic anaemia can occur without a palpable spleen, so presumably can splenopathic leucopenia, but evidence of increased blood destruction would be desirable to support the diagnosis in this event The value of bone-marrow biopsy will be discussed later

The cases presented by us form another distinct group in that they were chronic and persistent, and there was no evidence of overactivity of the spleen They are considered by us to be a variant of aplastic anaemia in which the main impact is on the white cells (Dameshek, 1944) Two of the patients appeared to be borderline cases with aspects of both diseases The response to splenectomy in one of these patients was characteristic of a hypoplastic marrow They nevertheless differ from aplastic anaemia in a number of aspects Four out of the five patients were female, this suggests that chronic agranulocytosis, like acute agranulocytosis, may be more common in women, whereas aplastic anaemia has no sex bias Only one of the five patients has died over a period of observation which now averages five years, in aplastic anaemia 60 per cent of our patients are dead in two years and 75 per cent in five years The sternal marrow is not so frequently hypoplastic as in chronic aplastic anaemia, it may be cellular with an arrest of maturation at the myelocyte level

In their paper on refractory anaemia Bomford and Rhoads (1941) described one of their groups of cases as 'refractory anaemia with immature acellular marrow, chronic granulocytopenia, probably including medullary pseudo-leukaemia' These patients all suffered from anaemia, and on this criterion alone we should not have diagnosed them as suffering from chronic agranulocytosis Other differences were the rapid downhill progress, the hypercellularity of the marrow, and the predominance of mononuclear cells in the marrow The nosological position of these cases is obscure Many authors believe them to be atypical forms of leukaemia, and for the present it would be better to classify them as 'unregenerator anaemia with leucopenia'

Chronic agranulocytosis of the type we have described appears to be rare There are few case reports in the literature (Doxiades, 1932) Bousser and Neydé (1947) have described cases of chronic agranulocytosis with a familial incidence, which form a link with familial hypoplastic anaemia (Estren and Dameshek, 1947) Our own five cases occurred over a period during which 27 cases of chronic aplastic anaemia were under treatment The cause is unknown The bone-marrow is an extensive and labile tissue, and though it is easy to see how a poison can induce an acute attack of agranulocytosis, it is difficult to understand why the leucopenia should persist when the poison is removed The idea that the haemopoietic cells can be frozen into immobility like the victims of a fairy-tale is a picturesque one, and has made the concept of maturation arrest popular It does not explain how growth and maturation are arrested or why the bone-marrow does not regenerate in chronic agranulocytosis and chronic aplastic anaemia It will be difficult to devise rational

treatment until we discover whether the cause is the persistence of a toxic agent or the lack of an essential enzyme or nutrient

The diagnosis of chronic agranulocytosis is easy in view of the isolated and persistent leucopenia and the liability to agranulocytic infection The haematologist may nevertheless feel some anxiety when the bone-marrow is cellular, lest he is overlooking a case of splenopathic neutropenia This is unlikely in the absence of splenomegaly and increased blood destruction Nevertheless it may be argued that the patient should not miss the possible benefits of splenectomy For similar reasons we have operated in four cases of aplastic anaemia where the bone-marrow findings were equivocal, without fatality but without success The argument against splenectomy in chronic agranulocytosis is stronger than in aplastic anaemia, in that the patients get on surprisingly well in spite of their leucopenia We should be doubtful about advising splenectomy in future unless the attacks of agranulocytic infection were frequent and the marrow was shown to be cellular in several situations, for example, the vertebral spines and the iliac crest as well as the sternum

Summary

1 Five cases of chronic agranulocytosis are presented They are differentiated from recurrent agranulocytosis and from splenopathic leucopenia

2 It is suggested that these cases are variants of chronic aplastic anaemia in which the main impact of the disease is on the white cells

3 The prognosis appears to be relatively good, particularly with control of attacks of infection by penicillin

REFERENCES

Bomford, R R , and Rhoads, C P (1941) *Quart J Med* N S **10**, 175
Bousser, J , and Noydé, R (1947) *Sang* **18**, 521
Dameshek, W (1944) *Leukopenia and Agranulocytosis*, New York
Doan, C A , and Wright, C S (1946) *Blood*, **1**, 10
Doxiades, T (1932) *Klin Woch* **11**, 419
Embleton, D (1936) *Brit Med J* **2**, 1258
Estren, S , and Dameshek, W (1947) *Amer J Dis Child* **73**, 671
Fisher, J A (1947) *Quart J Med* N S **16**, 245
Frank, E (1925) *Handbuch der Krankheiten des Blutes und der blutbildenden Organe*, ed A Schittenhelm, Berl , vol 2, p 432
Fullerton, H W (1947) *Quart J Med* N S **16**, 308
Lawrence, J S (1946) *Trans Coll Phys Philadelphia*, **14**, 1
Limarzi, L R , Jones, R M , Paul, J T , and Poncher, H G (1943) *Amer J Clin Path*, **13**, 231
Osgood, E E , Brownlee, I E , Osgood, M W , Ellis, D M , and Cohen, W (1939) *Arch Int Med* **64**, 105
Reimann, H A (1948) *J Amer Med Ass* **136**, 239
Roberts, S R , and Kracke, R R (1930) *Ibid* **95**, 780
Schultz, W (1922) *Deutsch med Wchnschr* **48**, 1495
Semple, R (1948) *Brit Med J* **2**, 72
Wiseman, B K , and Doan, C A (1939) *J Clin Invest* **18**, 473
Witts, L J (1948) *Acta med Scand* Supp **213**, 352

616 721–002 77

ANKYLOSING SPONDYLITIS[1]

Radiological, Clinical, and Biochemical Investigations in a Series of Cases

By ROBERT MOWBRAY, ALBERT L LATNER, and J HOWARD MIDDLEMISS

(From the Departments of Medicine and Chemical Pathology, The Medical School, King's College, University of Durham, and the Department of Radiology, Royal Victoria Infirmary, Newcastle-upon-Tyne)

With Plates 23 to 26

Introduction

Although the natural history of ankylosing spondylitis is well known, there are still fundamental problems connected with the disease which are unsolved Little or nothing is known regarding its aetiology or relationship to other forms of arthritis, especially rheumatoid arthritis The marked preponderance of ankylosing spondylitis in the male sex has raised the suspicion of a possible endocrine factor Davison, Koets, and Kuzell (1947) therefore measured the 17-ketosteroid excretion in a series of cases of spondylitis in men and of rheumatoid arthritis in women They found a tendency to greater excretion of 17-ketosteroids in the spondylitis cases than in normal men, but no such tendency was demonstrated in the rheumatoid arthritis group One of our purposes was to confirm or refute these observations Other workers (Carter and Maclagan, 1946, Rennie and Rae, 1947) have stated that certain serum flocculation reactions are abnormal in a proportion of cases of rheumatoid arthritis, but as far as we are aware no such observations have been made in patients with ankylosing spondylitis It was, therefore, decided to carry out a comparable series of these reactions in the two diseases Our third object was to examine as fully as possible the radiological changes found in ankylosing spondylitis, to assess the significance of these changes in relation to the pathogenesis of the disease, and to aid early diagnosis and treatment In the pursuit of these three objects a certain number of data of a purely clinical character have been collected which are considered worthy of record

Material

The radiological observations are based on 137 cases, consisting of 118 male and 19 female patients The ages of the men varied from 17 to 73 years and of the women from 25 to 69 years The clinical and biochemical investigations were made on 27 of these patients, of whom 16 had received deep X-ray therapy

[1] Received November 29, 1948.

and 11 had not Serum flocculation reactions were also carried out in 26 patients with rheumatoid arthritis, of whom 19 were female and seven male, varying in age from 16 to 66 years Fourteen of these patients had been treated with gold. In Table I an analysis is given in five-year periods of the ages when symptoms were first noticed in all the cases It shows that in most cases in either sex

TABLE I

Age of onset	Under 16	16 to 20	21 to 25	26 to 30	31 to 35	36 to 40	41 to 45	46 to 50	51 to 55	56 to 60	61 to 65	Years
Men	1	11	49	20	15	7	1	4	2	0	2	
Women	0	1	4	6	2	4	1	0	0	1	0	

symptoms begin between the ages of 21 and 30 years, but as cases occurred at any age from 15 to 65 years, the disease is not one which is entirely confined to any particular age-group

It has also been possible to analyse the length of time between the onset of symptoms and the radiological diagnosis of the condition (Table II) This table

TABLE II

	Under 1 yr	1 to 2 yrs	2 to 5 yrs	5 to 10 yrs	10 yrs and over
Number of cases	9	32	57	21	18

shows that too often there is great delay in diagnosis and, therefore, in instituting proper treatment, so far as we know it at present

Radiological Findings

Though Freund (1942) described the histology of the joint changes in an advanced case of spondylitis, no published references to the histological examination of the early changes have been found McWhirter (1945) described changes in the sterno-manubrial joint and suggested the possibility of biopsy in this situation, but no records have been published of any such examination A knowledge of the pathological process in its early stages and during its course, therefore, depends to a large extent on the interpretation of the radiological appearances The primary lesion is in the joint and the pathological process is one which brings about destruction of articular cartilage This process is the same in any joint involved, but the earliest changes are more easily demonstrated in some joints than others The earliest detectable sign is a marginal decalcification of the joint surface, which is shown by areas of erosion causing absorption of the sub-articular cortex, an osteoclastic process This progresses, producing an apparent widening of the joint space, and there is often an associated sclerosis of bone on the side of the erosion away from the joint space (Plate 23, Fig 2). The latter is presumably an osteoblastic reaction Destruction of the articular cartilage then takes place, leading to actual narrowing of the joint space, at this stage amorphous calcium deposits can sometimes be detected in the joint cavity (Plate 23, Fig 3) Reconstruction of the bony cancellous architecture follows, leading to complete bony ankylosis, an osteoblastic

activity (Plate 24, Fig 4) The whole process is most easily observed in the sacro-iliac joints, and is usually first detected radiologically there It can also be well demonstrated in the costo-transverse joints (Plate 24, Fig 5) and the symphysis pubis, involvement of the latter being usually a late development The same process occurs, but is not so easily demonstrable in its early stages, in the posterior spinal articulations, the sterno-clavicular and other sternal joints, and some of the peripheral joints, such as the hip and shoulder In the spinal and peripheral joints it is often possible to demonstrate only a local osteoporosis and destruction of articular cartilage causing narrowing of the joint space In the sacro-iliac joints and spine the condition is always bilateral, in the peripheral joints it may sometimes be unilateral

Osteoblastic activity may also be seen in other sites, the commonest of which are the spinal ligaments The anterior longitudinal ligament is usually the first to become involved, its attachments to the margins of the vertebral bodies often being the first site of calcific deposition, causing what has been described as a 'marginal squaring' of the bodies (Rolleston, 1947) If the disease is not arrested, the posterior longitudinal ligament and ligamenta flava also ossify, and in some cases the lateral margins of the annulus fibrosus, this final very advanced state producing the classical picture of the 'bamboo spine' Ligamentous ossification is an inconstant and often late accompaniment of the other pathological processes, its presence indicates that the disease is considerably advanced, but on the other hand it may be entirely absent even in very advanced cases Also in advanced cases an osteoblastic invasion of muscle attachments, especially those on the outer surfaces of the pelvis, may occur (Scott, 1942) The ischial tuberosities when involved provide an interesting example of this type of osteoblastic activity Usually it is preceded by the development of cyst-like areas of decalcification or erosion at the margins of the tuberosities at the site of origin of the adductor magnus This may progress no farther or may in time show evidence of osteoblastic invasion of the muscle origin (Plate 25, Fig 6) It seems possible, therefore, that in other regions where such osteoblastic invasion occurs it also is preceded by similar erosions, but that owing to their site these are not detected Radiologically these areas of erosion differ in no way from those which occur in sub-articular bone in the early joint manifestations of the disease, and as both occur in the course of the same disease it seems reasonable to regard them as part of the same pathological process Two further points are worthy of note

1 It has been stated that no diminution in intervertebral spaces occurs (Williams, 1939), but it is the experience of the present writers that there is often narrowing of these spaces, particularly in the dorsal region An attempt is sometimes made to classify ankylosing spondylitis into two types, spondylitis ossificans ligamentosa (the Marie-Strumpell type) and spondylitis muscularis (the Bechterew type), it is stated that no narrowing of intervertebral spaces occurs in the former while in the latter there may be narrowing anteriorly with fusion of the anterior margins of the bodies Our experience shows that the processes which lead to the appearances classified as the Bechterew type are

the same as those which lead to the Marie-Strumpell type It appears that if ossification of the ligaments occurs in early life the bridges thus formed buttress the intervertebral spaces and prevent narrowing If ossification of the ligaments fails to occur or is a late feature of the disease, degenerative changes in the disks may cause narrowing of the intervertebral spaces (Plate 26, Fig 7) If osteoblastic activity occurs after atrophy of the disk has caused approximation of the anterior parts of the bodies, it may be expected to bring about bony fusion, and this in fact does occur

2 Generalized osteoporosis is an infrequent accompaniment of the disease, but does sometimes occur Usually, apart from the marginal decalcification of the early stage, the bony texture and the apparent degree of bony calcification remain normal In our experience all cases showing a generalized osteoporosis have been clinically acute and active examples of the disease, but not all acute cases show osteoporosis, and none of the quiescent or insidiously progressive cases in our series have shown it

Thus, the pathological process appears to be one causing osteoclastic erosion of sub-articular bone and sometimes of bone beneath muscle attachments, this is followed by destruction of articular cartilage, and in turn leads to osteoblastic activity producing bony ankylosis of the joints, bony invasion of muscle attachments, and ossification of the spinal ligaments If radiological signs are present in the spine, there are always changes in the sacro-iliac joints, and it seems likely that the latter are the earliest indication of the disease All stages may be present in the same patient The spinal changes do not necessarily develop in a caudo-cephalic direction, as has sometimes been stated, and there may be advanced changes in two widely separated regions of the spine with no detectable abnormality between the two sites

It is possible to classify the radiological changes into three grades

Grade I Early cases, that is, those showing radiological evidence of sub-articular erosions, with no evidence of destruction or narrowing of joint spaces

Grade II Intermediate cases, that is, those showing narrowing of joint spaces indicating destruction of articular cartilage

Grade III Advanced cases, that is, those showing bony ankylosis of any joint involved

The radiological appearances in the 137 cases investigated have been analysed and are shown in Table III All cases had involvement of the sacro-iliac joints, and 15 were encountered in which no other radiological changes could be detected. It is interesting to note that in Grade I no case occurred in which evidence of ossification in spinal ligaments could be detected, in earlier investigations great importance was attached to identification of this sign It is now clear that by the time such ossification appears, the disease is advancing beyond the early stage, and indeed, in the total series, there were 11 cases classified as 'advanced' in which no evidence of ligamentous ossification could be found It is also interesting to note that in the early cases characteristic changes were detected in the posterior spinal articulations in 36 per cent and in the costo-transverse joints in 58 per cent In the intermediate cases the figures for these

TABLE III

Analysis of Bones, Joints, and Ligaments involved

	Total cases	*Sacro-iliac joints*	*Posterior spinal articulations*	*Costo-transverse joints*	*Ischial tuberosities*	*Symphysis pubis*	*Ossification in muscle attachments*	*Peripheral joints*	*Ligamentous ossification (spinal)*	*Generalized osteoporosis*	*Narrowing of intervertebral spaces*
Grade I	31	31	12	19	1	.		2			
Grade II	49	49	42	39	23	16	1	17	28	7	25
Grade III	57	57	55	50	47	37	8	28	46	3	38
Total	137	137	109	108	71	53	9	47	74	10	63

two sites were 84 and 78 per cent respectively, and in the advanced cases 96 and 88 per cent respectively. Forty-seven cases showed involvement of one or more peripheral joints The joint most commonly affected was the hip, and in fact one or both hips were involved in all 47 cases, but in addition some of them showed changes in the knee and shoulders Sixty-three cases showed narrowing of intervertebral spaces, all these patients were over 35 years of age

Clinical Analysis of 27 Cases of Spondylitis (Tables IV and V)

Sixteen cases had been treated with deep X-rays and 11 had not There was one female patient in the treated group and three in the untreated group At the time of interview the average age for the treated group was 31 years and for the untreated group 38 years, and the average age of onset of symptoms for the two groups respectively was 23 and 28 years Thus, the untreated patients were slightly older and had suffered from the disease for a slightly longer period

The occupational and social histories revealed nothing significant, two patients had suffered from peptic ulceration, one from pulmonary tuberculosis, one from pneumonia and myocarditis, and two from scarlet fever, of whom one had also had gonorrhoea Nephrectomy had been performed on one other patient for renal calculi The relationship of trauma to spondylitis is thought by some to be of importance (Parr and Slipton, 1946), but in the present series only one patient had suffered severe trauma to his back before the onset of symptoms, and eight others gave a history of slight trauma to the back or thighs before the onset of the disease The severe trauma was a crush injury to the spine sustained while the patient was working as a coal-miner, while the minor injuries were strains or falls which were not thought to be severe at the time when they occurred, but were recalled as possible causes for the symptoms which developed later Evidence in support of trauma as a major aetiological agent in spondylitis is, therefore, lacking

In two of the four female patients symptoms were first noted shortly after parturition In all patients the onset was gradual and the initial symptom was pain, usually intermittent, but sometimes constant and nearly always preceding stiffness It began as a rule in the lumbo-sacral region, sometimes elsewhere in the back or in one hip or thigh, as it increased it frequently involved the neck and in due course was followed by spinal rigidity and deformity. Infrequently pain and stiffness were noticed first in the knees or shoulders, and a few patients complained of epigastric or chest pain only Generally the pain, which was aching in character, was worse after a period of immobility and tended to diminish with movement It was remarkable how few patients experienced real difficulty in getting about, some preferred cycling to walking in spite of the difficulty in turning the head Some experienced great difficulty in finding a comfortable position in bed, and with increasing spinal stiffness dressing became a problem, but on the whole these patients adapted themselves well to their disabilities Only one patient was bedridden when first examined and this was due mainly to extensive bilateral hip-joint involvement

Most patients were rather thin and a few overweight, but as a rule the general

Table IV

Treated Cases

Case	Sex	Age (years)	Age at onset (years)	Occupation	Past illness	Previous trauma	Iritis	Blood sedimentation rate (mm in 1 hr)	Gonococcal complement fixation test	Wassermann reaction	Endocrine development	Chest expansion (in inches)	Radiological Grade	Last deep X ray therapy
1	M	18	16	Miner	None	Slight	None	62	Negative		Normal	1 5	II	1948
2	M	44	35	Insurance agent	Pneumonia and myocarditis	,,	,,	50	,,		,,	1	III	1947
3	M	33	22	Grocer	Scarlet fever, gonorrhoea	None	,,	22	Positive	Negative	,,	2 5	I	1948
4	M	43	25	Baker	None	,,	,,	4	Negative		,,	1 25	III	1945
5	M	24	20	Metal worker	,,	,,	,,	35	,,		,,	1 5	II	1948
6	M	27	22	Coach painter	,,	,,	,,	55	,,	Positive	,,		I	1948
7	M	39	33	Bus-driver	,,	Slight	,,	9	Slight fixation		,,	1	II	1946
8	F	29	27	Housewife	,,	None	,,	23	Negative		Obese and sterile	1	II	1948
9	M	37	23	Engineer	,,	Severe	1942	12	,,		Normal	1 75	II	1947
10	M	24	16	Miner	,,	None	None	30	,,		,,	1 5	II	1944
11	M	23	19	Labourer	,,	,,	,,	3	,,		,,	2 25	I	1948
12	M	30	21	Clerk	,,	,,	,,	13	,,		,,	1	II	1947
13	M	31	21	Tobacconist	,,	,,	,,	14	,,		,,	1	I	1947
14	M	41	21	Engineer	,,	Slight	1948	58	,,		,,	1	III	1947
15	M	30	20	Student	,,	None	None	15	,,		,,	2	III	1946
16	M	24	22	Porter	,,	Slight	,,	92	Anti-complementary		,,	2	III	1948

Table V

Untreated Cases

Case	Sex	Age (years)	Age at onset (years)	Occupation	Past illness	Previous trauma	Iritis	Blood sedimentation rate (mm in 1 hr)	Gonococcal complement fixation test	Wassermann reaction	Endocrine development	Chest expansion (in inches)	Radiological Grade	Remarks
1	F	27	20	Shop assistant	None	None	None	24	Negative		Normal	0 75	III	
2	M	43	37	Miner	,,	Slight	1942	15	,,		,,	1 5	III	Rheumatoid arthritis
3	M	44	32	Gardener	Peptic ulcer	None	None	35	Doubtful		,,		III	
4	M	57	47	Turner	None	,,	,,	35	Negative		,,	1 75	II	
5	F	35	35	Housewife	,,	,,	,,	19	,,	Negative	,,		I	
6	M	34	34	Clerk	Pulmonary tuberculosis	,,	,,	25	,,		,,	0 75	II	
7	M	16	16	Miner	None	,,	,,	8	,,	Negative	,,	0 75	III	
8	M	36	21	Engineer	Peptic ulcer	Slight	,,	3	,,		,,	3 0	I	
9	M	28	28	Stone worker	None	None	,,	3	Doubtful		,,	2 5	I	
10	F	48	27	Housewife	Renal calculi	,,	,,	10	Negative		,,	1 0	III	
11	M	23	15	Shop assistant	Scarlet fever	Slight	,,	100	,,		,,	1 25	I	

health had suffered remarkably little The majority showed rigidity of some part of the spinal column, often accompanied by kyphotic deformity and loss of the lumbar curve Limitation of hip movement was frequent, but shoulder involvement was much less common. In a few cases the neck was completely rigid Clinical scoliosis and marked lordosis were each seen only in one case Chest expansion was measured in 24 cases and ranged from 0 75 to 3 0 in, averaging 1 5 in for the whole group Limitation of expansion was most marked in untreated patients with advanced radiological changes, but even in these severe cases it was less marked in the patients who had received deep X-ray therapy The abdominal wall usually sagged forward and breathing was mainly diaphragmatic and abdominal

Pulmonary disease was found in two cases, one patient having a mild chronic bronchitis and the other long-standing non-active pulmonary tuberculosis Clinical cardiovascular, abdominal, or neurological disease was not discovered in any case Splenomegaly and lymphnode enlargement were absent Clinical examination for focal sepsis was entirely negative and clinical signs of anaemia absent A few patients had full blood examinations which showed no significant abnormality. A short period of low-grade pyrexia was seen in one early case, otherwise the patients were all afebrile One patient gave a history of gonorrhoea 12 years previously, a year before symptoms of spondylitis commenced, and the gonococcal complement fixation test in this case was positive No other patient gave a history of gonorrhoea, but the complement fixation text was doubtful in two cases, and gave slight fixation in one other One serum was anticomplementary Particular attention was paid in clinical examination to signs of possible endocrine disease, but these were entirely absent, all patients had developed normally and their sex development and outlook were normal One female patient had become moderately obese and sterile after deep X-ray therapy Dermatological examination revealed no abnormalities, and no patient gave a history of psoriasis Eye complications of 'rheumatic' types are said to occur with ankylosing spondylitis, in the present series three patients had suffered from iritis at some stage in the disease One had received X-ray therapy and two had not All cleared up on routine ophthalmological treatment and none suffered relapse

Blood sedimentation rates in ankylosing spondylitis appear to bear little relationship to the radiological state In the group of treated cases the average blood sedimentation rate (Westergren) was 28 mm in 1 hour, but varied from 3 to 92 mm in individual cases In untreated cases the average was 25 mm in 1 hour and varied from 3 to 100 mm Correlation of the blood sedimentation rate with radiological grading shows that the average for treated and untreated cases respectively was 24 mm and 38 mm in Grade I, 26 mm and 30 mm in Grade II, and 34 mm and 18 mm in Grade III It is, therefore, difficult to assess the significance of blood sedimentation rate readings, but it is correct to state that the blood sedimentation rate is raised in the majority of cases We hope to investigate this problem further, attempting to correlate the blood sedimentation rate readings with the clinical state and stage of therapy

Practically all patients in both groups had received some form of treatment, such as various forms of physiotherapy or gold injections, but they had not in any way received benefit The one form of treatment which did subjective good was deep X-ray therapy All but two patients so treated improved greatly after one or more courses, pain was much diminished, stiffness improved to a lesser extent, and when the course was completed the patients' general condition was always improved

Two cases require further clinical comment The first was a miner aged 46 years who had been kyphotic for 30 years and whose only symptom was slight abdominal discomfort His chest expansion was 0 75 in and there was complete rigidity of the thoracic and lumbar spine, but excessive mobility of the hips suggesting the possibility of latent tabes dorsalis, this, however, was excluded by further investigation He had never had any treatment and was carrying on with his work as a hewer at the coal face The second case was also a miner aged 43 years who had developed ankylosing spondylitis six years previously, and had suffered and recovered from an attack of iritis during the first two years of his illness A few months after the iritis he developed typical rheumatoid arthritis involving hands, feet, knees, and elbows, leaving him with considerable residual deformities in the hands and feet During the whole of this period the spondylitis appears to have progressed independently and to have been unaffected by the other condition The clinical, radiological, and biochemical findings suggest that this patient was the subject of two separate pathological processes, each developing independently and according to its own pattern His present state is that of a man with non-active rheumatoid deformities and slowly progressive ankylosing spondylitis

Biochemical Findings

Biochemical investigations were carried out on the same group of 27 patients, namely, 23 male and four female subjects In each patient, appropriate blood specimens were collected for the following determinations, the plasma alkaline phosphatase, by the method of Jenner and Kay (1932), the plasma inorganic phosphorus, the serum-calcium, the serum thymol turbidity and thymol flocculation reactions at pH 7 55 (Latner, 1948), and the serum colloidal gold precipitation test at pH 7 55 (Latner, 1948) In addition the 24-hour urinary excretion of 17-ketosteroids was determined The technique adopted in this laboratory involves a much longer extraction period than the modified Robbie and Gibson technique described by Davison, Koets, and Kuzell (1947) Parallel determinations by the latter method and our own have been carried out on a series of urines and have been found to give results in remarkably close agreement

The findings obtained in the biochemical investigations are given in Tables VI and VII and show that the results seem to bear no relationship to the presence or absence of previous deep X-ray therapy The serum flocculation reactions were performed in order to compare the findings with those in the group of 26 patients suffering from rheumatoid arthritis (Table VIII) It is already

Table VI

Biochemical Findings in 16 Cases of Ankylosing Spondylitis which had received Deep X-ray Therapy

Sex	Age (years)	Duration of disease (years)	X ray grade	Urinary 17 ketosteroids (mg per 24 hrs)	Serum-calcium (mg per 100 c c)	Plasma inorganic phosphorus (mg per 100 c c)	Plasma alkaline phosphatase (units per 100 c c)	Combined thymol reactions	Colloidal gold test
M	18	2	II	11	10 3	2 7	6 8	Negative	Negative
M	44	9	III	7	10 2	2 9	9 0	"	"
M	33	11	II	10	10 4	2 8	6 4	"	"
M	43	18	III	13	9 9	2 3	4 7	"	"
M	24	4	II	10	10 7	3 4	8 8	"	"
M	27	5	I	16	10 9	3 6	6 5	"	"
M	39	6	II	11	10 2	2 5	11 5	"	"
F	29	2	II	8	10 7	3 7	6 8	"	"
M	37	14	II	10	10 7	2 9	6 7	"	"
M	24	8	II	13	10 1	2 0	6 9	"	"
M	23	4	I		10 4	3 4	4 5	"	"
M	30	9	II	6	10 2	2 6	8 8	"	"
M	31	10	I	11	10 7	3 1	3 1	"	"
M	41	20	III	11	9 6	2 5	6 5	"	"
M	30	10	III	11	10 7	2 3	9 3	"	"
M	24	2	III	3	10 1	3 4	7 2	"	"

Table VII

Biochemical Findings in 11 Untreated Cases of Ankylosing Spondylitis

Sex	Age (years)	Duration of disease (years)	X ray grade	Urinary 17 ketosteroids (mg per 24 hrs)	Serum-calcium (mg per 100 c c)	Plasma inorganic phosphorus (mg per 100 c c)	Plasma alkaline phosphatase (units per 100 c c)	Combined thymol reactions	Colloidal gold test
F	27	7	III	9	9 9	3 5	6 3	Negative	Negative
M	43	6	III	2	9 7	1 8	11 4	"	"
M	44	12	III	9	10 3	3 5	8 3	"	"
M	57	10	II	4 1	8 9	2 3	6 6	"	"
F	35	6/52	I	10 0	8 7	3 5	7 7	"	"
M	34	8/12	II	6 0	10 3	2 5	6 6	"	"
M	46	30	III	7 5	9 6	2 4	9 9	"	"
M	36	15	I	10 3	10 5	2 4	5 3	"	"
M	28	6/12	I	8 6	10 9	3 2	4 2	"	"
F	48	21	III	3	10 5	3 7	4 8	"	"
M	23	8	I	10	10 0	2 4	8 6	"	"

known that in the latter condition there is a marked tendency for abnormal flocculations to occur (Carter and Maclagan, 1946, Rennie and Rae, 1947) The thymol turbidity and thymol flocculation reactions are essentially part of the same test They are, therefore, included in the Tables under the heading of the combined thymol test, which is said to be positive if the turbidity exceeds

TABLE VIII

The Serum Flocculation Reactions in 26 Cases of Rheumatoid Arthritis

Sex	*Age (years)*	*Combined thymol reactions*	*Colloidal gold test*
F	40	Positive	Positive
M	45	,,	,,
F	61	Negative	Negative
F	63	,,	Positive
M	51	,,	,,
M	50	,,	Negative
F	64	,,	,,
F	66	Positive	Positive
F	50	,,	,,
M	46	,,	,,
F	43	,,	,,
F	16	,,	Negative
F	59	Negative	Positive
F	51	Positive	,,
F	49	Negative	,,
F	56	Positive	,,
M	45	Negative	Negative
F	43	,,	,,
F	35	,,	,,
M	48	Positive	,,
F	60	Negative	,,
F	55	Positive	Positive
F	56	Negative	Negative
F	42	,,	,,
F	52	,	,,
F	63	Positive	Positive

four Maclagan units (Maclagan, 1944*b*) or if the flocculation exceeds one plus Similarly, the colloidal gold precipitation test is said to be positive if it exceeds one unit (Maclagan, 1944*a*) In no case of ankylosing spondylitis was either of the flocculation tests positive, in marked contrast to the group of 26 cases of rheumatoid arthritis which showed a positive combined thymol reaction in 46 per cent of cases and a positive colloidal gold precipitation in 54 per cent A positive flocculation reaction of one kind or another was shown in 62 per cent

It will also be seen from Tables VI and VII that the plasma inorganic phosphorus and serum-calcium levels were all within the normal range In the majority of cases of ankylosing spondylitis investigated, the same may be said of the plasma alkaline phosphatase, which in this laboratory has been found to have a normal range of 3 to 8 Jenner and Kay units per 100 c c of plasma A few cases of X-ray Grades II and III were slightly raised above the normal range This can be seen in Fig 1, in which the alkaline phosphatase levels have been diagrammatically represented in terms of X-ray grading Raised values were found in three out of 10 of Grade II and in five out of 10 of Grade III

patients The normal range of urinary 17-ketosteroid excretion found in this laboratory is 2 to 18 mg per 24 hours for female and 6 to 23 mg per 24 hours for male subjects The 17-ketosteroid excretion in the group of cases of ankylosing spondylitis was, therefore, essentially normal Four patients, including one woman, had urinary excretions in the somewhat low range of 2 to 4 mg. per 24 hours No significance can be attached to this finding

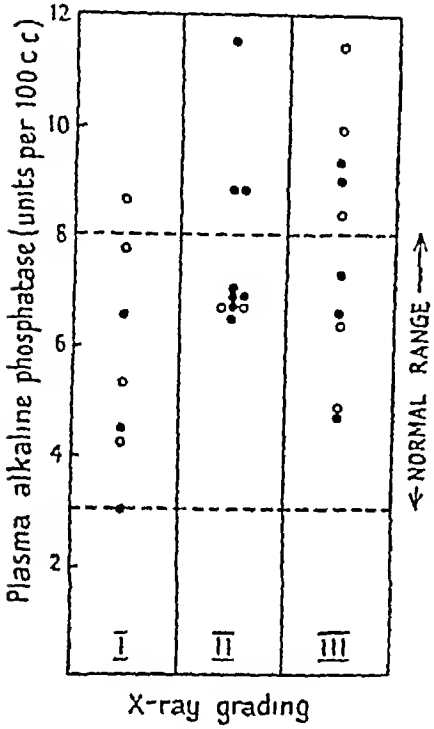

FIG 1 Correlation between X ray grading and plasma alkaline phosphatase in 27 cases of ankylosing spondylitis

(• = Treated o = Untreated)

Discussion

The aetiology of this fairly common and disabling disease is unknown There is no evidence in the present series of cases that tuberculosis, gonorrhoea, focal infection, trauma, or endocrine disease play any part, nor is there any evidence of a familial incidence The series gives no support for the supposed predilection of the disease for young athletes Parr and Shipton (1946) have described a pre-spondylitic phase of generalized pains, which gradually passes into the first stage of the disease proper, in which pain and stiffness become localized generally to the back In all but nine of the 137 cases in our series, over a year elapsed between the onset of symptoms and the radiological diagnosis, and in some cases this period extended to over 10 years Our evidence does not show how soon radiological changes may be demonstrated, but it suggests that in some cases at least they are present within a few months of the onset of symptoms Earlier diagnosis should, therefore, be possible if this condition is kept clearly in mind It has been stated (Lennon and Chalmers, 1948) that ankylosing spondylitis and rheumatoid arthritis are the same disease We find it impossible to agree with this statement on clinical, radiological, biochemical, or therapeutic grounds Ankylosing spondylitis appears to be a disease *sui generis*, with its primary pathological lesion in the sub-articular bone and only secondary pathological changes in ligaments and joints

In considering the radiological features of the disease certain factors stand out Publications in the past have stressed that phase of the disease in which ossification occurs in joints, ligaments, and muscle attachments Scott (1942) and subsequent writers have drawn attention to the sub-articular erosions which can be seen in the sacro-iliac joints in early cases However, there has been too

little detailed attention paid to the disease process as a whole, and too little attempt to correlate all the changes that may occur. From the present analysis it is possible to present these changes in terms of one pathological process One phase of the process may best be observed in one site, another phase in another site, the appearances in one site may leave the diagnosis in doubt, but examination of another confirm it This conception of the pathological process as primarily an osteoclastic one makes an understanding of the subsequent osteoblastic activity easier The osteoblastic process appears to be a reaction to the initial destruction, at first presenting a barrier to this process, later bringing about reconstruction of the bony architecture, this occurs first within the normal confines of bony structure, then extends into the adjacent articular cartilage, peri-articular ligaments, and muscle attachments This conception of the changing nature of the pathological process is important primarily from a diagnostic point of view, but also in directing any future research into the aetiology of the disease Diagnosis depends essentially on radiological investigation Advanced cases will be diagnosed clinically, but if treatment is to be instituted in useful time the condition must be diagnosed early

The radiological picture of the advanced case is unmistakable In early and intermediate cases the important points to bear in mind are that the sacro-iliac joints are always involved, that in these joints and the spinal joints the condition is always bilateral, and that usually in addition changes can be detected in other sites, such as the costo-transverse joints or ischial tuberosities Tuberculosis of a sacro-iliac joint also causes a marginal erosion of the articular surfaces, but is almost invariably unilateral, is often localized to one part of a joint, and produces none of the other changes associated with spondylitis The only other condition which may cause appearances bearing some resemblance on first inspection to spondylitis is the little-understood disorder known as osteitis condensans ili which causes sclerosis of the iliac portion of the sacro-iliac joints and is often associated with low backache, but produces no marginal erosion, no narrowing of joint spaces, and none of the other associated changes

As recently as 1947 Angevine, in discussing the pathology of rheumatic diseases, referred to ankylosing spondylitis as a 'rheumatoid arthritis of the spine' The changes demonstrated radiologically in the joints in rheumatoid arthritis do not appear to be the same as those we have described in ankylosing spondylitis, and there certainly does not appear to be any radiological evidence to support that view, though it is a view widely held in the United States of America and to a lesser extent in this country

In the group of cases of ankylosing spondylitis investigated biochemically, the urinary 17-ketosteroid excretion was never above normal We cannot, therefore, agree with the findings of Davison, Koets, and Kuzell (1947) that there is a trend towards a greater excretion than normal in patients suffering from this disease We are also at a loss to explain this divergence in the findings The explanation cannot lie in the previous application of X-ray therapy, as 11 of our patients were untreated, which equals the number of untreated cases included in the report of Davison, Koets, and Kuzell It is interesting to note

patients The normal range of urinary 17-ketosteroid excretion found in this laboratory is 2 to 18 mg per 24 hours for female and 6 to 23 mg per 24 hours for male subjects The 17-ketosteroid excretion in the group of cases of ankylosing spondylitis was, therefore, essentially normal Four patients, including one woman, had urinary excretions in the somewhat low range of 2 to 4 mg. per 24 hours No significance can be attached to this finding

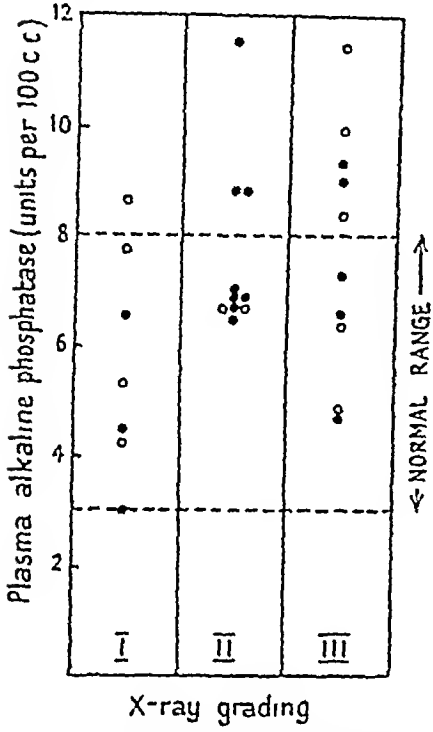

FIG 1 Correlation between X ray grading and plasma alkaline phosphatase in 27 cases of ankylosing spondylitis

(• = Treated o = Untreated)

Discussion

The aetiology of this fairly common and disabling disease is unknown There is no evidence in the present series of cases that tuberculosis, gonorrhoea, focal infection, trauma, or endocrine disease play any part, nor is there any evidence of a familial incidence The series gives no support for the supposed predilection of the disease for young athletes Parr and Shipton (1946) have described a pre-spondylitic phase of generalized pains, which gradually passes into the first stage of the disease proper, in which pain and stiffness become localized generally to the back In all but nine of the 137 cases in our series, over a year elapsed between the onset of symptoms and the radiological diagnosis, and in some cases this period extended to over 10 years Our evidence does not show how soon radiological changes may be demonstrated, but it suggests that in some cases at least they are present within a few months of the onset of symptoms Earlier diagnosis should, therefore, be possible if this condition is kept clearly in mind It has been stated (Lennon and Chalmers, 1948) that ankylosing spondylitis and rheumatoid arthritis are the same disease We find it impossible to agree with this statement on clinical, radiological, biochemical, or therapeutic grounds Ankylosing spondylitis appears to be a disease *sui generis*, with its primary pathological lesion in the sub-articular bone and only secondary pathological changes in ligaments and joints

In considering the radiological features of the disease certain factors stand out Publications in the past have stressed that phase of the disease in which ossification occurs in joints, ligaments, and muscle attachments Scott (1942) and subsequent writers have drawn attention to the sub-articular erosions which can be seen in the sacro-iliac joints in early cases However, there has been too

2 Radiological analysis has led to the grading of cases and suggested a probable pathogenesis

3 Twenty-seven cases have been subjected to clinical and biochemical investigation The results obtained have been correlated with the suggested pathogenesis

4 Urinary 17-ketosteroid excretion was within normal limits

5 The serum flocculation reactions have been contrasted with those in a group of 26 cases of rheumatoid arthritis

We wish to thank Professor F J Nattrass for much helpful criticism and advice in the preparation of this paper, and Mr C J Duncan, Director of the Photographic Department, King's College, for the illustrations

REFERENCES

Angevine, D M (1947) *Radiol* 49, 1
Carter, A B, and Maclagan, N F (1946) *Brit Med Journ* 2, 80
Davison, R A, Koets, P, and Kuzell, W C (1947) *Journ Clin Endocrinol* 7, 201
Ellman, P (1948) in *Progress in Clinical Medicine*, by various authors, 336
Freund, E (1942) *Edin Med Journ* 49, 91
Jenner, H D, and Kay, H D (1932) *Brit Journ Exper Path* 13, 22
Latner, A L (1948) M.D Thesis, University of Liverpool
Lennon, W, and Chalmers, I S (1948) *Lancet*, 1, 12
Maclagan, N F (1944*a*) *Brit Journ Exper Path* 25, 15
—— (1944*b*) *Ibid* 25, 234
McWhirter, R (1945) *Brit Journ Rad* 18, 302
Marie, P (1898) *Revue de Medicine*, 18, 285
Parr, L J A, and Shipton, E (1946) *Med Journ of Austral* 1, 277
Rennie, J B, and Rae, S L (1947) *Brit Med Journ* 2, 1030
Rolleston, G L (1947) *Brit Journ Rad* 20, 288
Scott, S G (1942) *A Monograph on Adolescent Spondylitis or Ankylosing Spondylitis*, Lond
von Bechterew, W (1893) *Neurolog Centralbl* 12, 426
Williams, E R (1939) *Text-book of X-ray Diagnosis*, by British authors Ed by S C Shanks, P Kerley, and E W Twining

that in accordance with what is already known of the blood chemistry of this condition, the serum-calcium and plasma inorganic phosphorus were within the normal range in untreated and treated cases The plasma alkaline phosphatase levels were of interest In no case was the alkaline phosphatase greatly raised. All cases in X-ray Grade I were within the normal range, apart from one which was a fraction of a unit above the upper limit of normal, but there were slight increases above normal in 30 per cent of Grade II and 50 per cent of Grade III These findings are in accordance with the radiological description of the pathogenesis of the condition already given It is well known that much of the plasma alkaline phosphatase is derived from osteoblastic activity, and its level is often a reflection of this process It may be deduced, therefore, that in Grade I there was no increase in osteoblastic activity, whereas, in Grades II and III, there was a slight increase above normal Correlating these findings with the demonstrated pathological changes, it may be suggested that

1. All cases in Grade I are in the early phase of erosion of the subarticular bone It will be remembered that no single case gave radiological evidence of ossification of the spinal ligaments
2. In Grade II osteoblastic activity has commenced This grade consists of cases showing sclerosis of bone on the side of the erosion away from the joint space, as well as some abnormal calcification in joint spaces or ligaments
3. In Grade III osteoblastic activity has gone a stage farther and abnormal ossification is more manifest In this grade, the four cases showing raised phosphatase values and, therefore, increased osteoblastic activity, occurred in the first 10-year period On the other hand, the three cases of longest duration showed normal phosphatase values, indicating that osteoblastic activity was probably normal So far as increased osteoblastic activity is probably a reaction to activity of the disease process, it follows that the disease is progressive for a decade or more and eventually burns itself out

Many still believe that ankylosing spondylitis and rheumatoid arthritis are variants of the same disease (Ellman, 1948, Lennon and Chalmers, 1948) Strong evidence against the identity of the two diseases is afforded clinically by the great difference in the sex distribution and the response to gold therapy Biochemically, the lack of identity is indicated by the negative serum flocculation reactions in all the cases of ankylosing spondylitis which we have investigated, in contrast with the positive reactions in a large percentage of our cases of rheumatoid arthritis The evidence is further strengthened by the fact that such findings were demonstrated in male as well as female patients, while the negative flocculations in ankylosing spondylitis were given in patients of both sexes It was, therefore, the patient's disease, and not the patient's sex, which determined the flocculation reaction

Summary

1 A group of 137 cases of ankylosing spondylitis has been investigated radiologically and correlated with age of onset and duration of the disease

2 Radiological analysis has led to the grading of cases and suggested a probable pathogenesis

3 Twenty-seven cases have been subjected to clinical and biochemical investigation The results obtained have been correlated with the suggested pathogenesis

4 Urinary 17-ketosteroid excretion was within normal limits

5 The serum flocculation reactions have been contrasted with those in a group of 26 cases of rheumatoid arthritis

We wish to thank Professor F J Nattrass for much helpful criticism and advice in the preparation of this paper, and Mr C J Duncan, Director of the Photographic Department, King's College, for the illustrations

REFERENCES

Angevine, D M (1947) *Radiol* 49, 1
Carter, A. B , and Maclagan, N F (1946) *Brit Med Journ* 2, 80
Davison, R A , Koets, P , and Kuzell, W C (1947) *Journ Clin Endocrinol* 7, 201
Ellman, P (1948) in *Progress in Clinical Medicine*, by various authors, 336
Freund, E (1942) *Edin Med Journ.* 49, 91
Jenner, H D , and Kay, H D (1932) *Brit Journ Exper Path* 13, 22
Latner, A L (1948) M D Thesis, University of Liverpool
Lennon, W , and Chalmers, I S (1948) *Lancet*, 1, 12
Maclagan, N F (1944*a*) *Brit Journ Exper Path* 25, 15
—— (1944*b*) *Ibid* 25, 234
McWhirter, R (1945) *Brit Journ Rad* 18, 302
Marie, P (1898) *Revue de Medicine*, 18, 285
Parr, L J A., and Shipton, E (1946) *Med Journ of Austral* 1, 277
Rennie, J B , and Rae, S L (1947) *Brit Med Journ* 2, 1030
Rolleston, G L (1947) *Brit Journ Rad* 20, 288
Scott, S G (1942) *A Monograph on Adolescent Spondylitis or Ankylosing Spondylitis*, Lond
von Bechterew, W (1893) *Neurolog Centralbl* 12, 426
Williams, E R (1939) *Text-book of X-ray Diagnosis*, by British authors Ed. by S C Shanks, P Kerley, and E W Twining

FIG 2 An early case Note the sub articular erosions, apparent widening of the sacro iliac joint spaces, and the sclerosis in both iliac bones

FIG 3 An intermediate case This shows some narrowing of the sacro iliac joint spaces, though some erosions are still visible

a

b

c

FIG 6 Changes in ischial tuberosities (a) early erosions, (b) early osteoblastic activity, (c) advanced ossification in the muscle attachment

FIG 4 An advanced case Note the ankylosis of the sacro iliac joints and the symphysis pubis Both ischial tuberosities show changes the right showing ossification in the origin of the adductor magnus

FIG 5 An intermediate case, showing sub articular erosion in the right and commencing bony ankylosis in the left first costo transverse joints

Irregularity of the arteriolar lumen (Plate 27, Fig 5) We are rightly reminded by Gowers in his book on Medical Ophthalmoscopy in 1890 that 'the red lines spoken of as the retinal arteries or veins are not the vessels themselves, but the columns of blood within them The walls of the vessels are, as a rule, invisible ' The two sides of the blood column are normally parallel, although a little deviation may occur at points of branching Irregularity of the lumen of the arteriole usually appears as a gradual narrowing of the blood column with sudden or gradual return to its previous diameter This may be repeated on many occasions as the artery is traced towards the periphery Sometimes the changes are more localized and are seen to be ring-like in character Every branch must be searched for this sign as it may be confined to some of the smaller ones In a few cases an apparent irregularity of lumen was optical in origin, due to lack of uniformity in the refractive media of the eye Such irregularities caused little difficulty because they disappeared when the same point was examined from a slightly different angle The degree (+ to +++) of irregularity of lumen was recorded for each of the eight main arterioles in the two eyes (Table I) Changes in the lumen have been variously ascribed to local atheroma (Raehlmann, 1902, Coats, 1906, 1913) and to localized spasm (Haselhorst and Mylius, 1928) Probably both these changes are involved Manlove (1946) has shown in histological studies of subjects with malignant hypertension that intimal proliferation is rare in the retinal arterioles

Generalized arteriolar narrowing (Plate 27, Fig 5) In 1876 Gowers pointed out the relation between narrow retinal arteries and high blood-pressure as determined [illegible] Scarre (1916) found it difficult to say whether the [illegible] direct comparison [illegible] was inconstant, [illegible] 'arterioscle[illegible] 1937, Bjorl[illegible] or not, as t[illegible] been made i[illegible] the width o[illegible] panion vein [illegible] himself hac[illegible] cannot be l[illegible]

'The rela[illegible] ness than t[illegible] tion of the [illegible] Sometimes [illegible] veins accon[illegible] vessels whi[illegible] and are av[illegible] as a rule, [illegible] the vein [illegible] of the ves[illegible] large mere[illegible]

careful estimate of the blood-pressure was then made and always repeated in patients with hypertension The size of the left ventricle was judged by cardioscopy, and an electrocardiogram was often taken The condition of the right brachial artery was noted Care was taken to exclude aortic valvular disease, chronic nephritis, and coarctation of the aorta.

Methods

Ophthalmoscopy was invariably performed first The patients were examined in a well-shaded room and only accepted if the fundus was well seen A mydriatic was seldom employed In some cases the arrangement of the retinal vessels follows a characteristic pattern (Plate 27, Fig 4) The central retinal artery divides into two main branches, which again divide into two, usually on or near the disk, so that four main arterioles radiate from the region of the disk, these comprise superior and inferior temporal branches, and superior and inferior nasal branches Each branch is usually accompanied by a corresponding vein Variations of this arrangement are often seen A routine was followed in the ophthalmoscopic examination because abnormalities may be confined to two or three branches and they must be looked for For this reason, each of the eight main arterioles in the two eyes was examined for irregularity of lumen, generalized narrowing, pallor, nipping and opacity of the arterial wall at arterio-venous crossings, and changes in the light reflex The results were compiled in a special table, an example of which is shown in Table I Each individual

TABLE I

The Findings on Ophthalmoscopy in a Typical Patient with Hypertension, whose Right Fundus is illustrated in Plate 27, Fig 5

	Right fundus				*Left fundus*			
	Superior temporal arteriole	*Superior nasal arteriole*	*Inferior temporal arteriole*	*Inferior nasal arteriole*	*Superior temporal arteriole*	*Superior nasal arteriole*	*Inferior temporal arteriole*	*Inferior nasal arteriole*
Irregularity of the lumen	+++	++	+++	++	0	0	0	0
Arterio venous ratio	3/6	3 5/6	3/6	3/6	3 5/6	—	3 5/6	—
Pallor of the blood column	++	++	++	++	++	++	++	++
Nipping of a vein at an arterio venous crossing	0	0	++	0	0	0	0	0
Opacity of the arteriolar wall at an arterio venous crossing	++	0	0	0	0	0	0	0
Light reflex	++	0	0	0	++	0	++	0

0 Normal appearance ++ Moderate changes +++ Great changes
— No arterio venous ratio possible

observation was tabulated in this way The wide range of normal variations in the appearance and arrangement of the retinal vessels is a well-known source of difficulty in detecting abnormalities With this in view, hundreds of fundi were examined before the investigation was started Further, patients with hypertension were interspersed with the healthy subjects who comprised nearly half the cases

Irregularity of the arteriolar lumen (Plate 27, Fig 5) We are rightly reminded by Gowers in his book on Medical Ophthalmoscopy in 1890 that 'the red lines spoken of as the retinal arteries or veins are not the vessels themselves, but the columns of blood within them The walls of the vessels are, as a rule, invisible' The two sides of the blood column are normally parallel, although a little deviation may occur at points of branching Irregularity of the lumen of the arteriole usually appears as a gradual narrowing of the blood column with sudden or gradual return to its previous diameter This may be repeated on many occasions as the artery is traced towards the periphery Sometimes the changes are more localized and are seen to be ring-like in character Every branch must be searched for this sign as it may be confined to some of the smaller ones In a few cases an apparent irregularity of lumen was optical in origin, due to lack of uniformity in the refractive media of the eye Such irregularities caused little difficulty because they disappeared when the same point was examined from a slightly different angle The degree (+ to +++) of irregularity of lumen was recorded for each of the eight main arterioles in the two eyes (Table I) Changes in the lumen have been variously ascribed to local atheroma (Raehlmann, 1902, Coats, 1906, 1913) and to localized spasm (Haselhorst and Mylius, 1928) Probably both these changes are involved Manlove (1946) has shown in histological studies of subjects with malignant hypertension that intimal proliferation is rare in the retinal arterioles

Generalized arteriolar narrowing (Plate 27, Fig 5). In 1876 Gowers pointed out the relation between narrow retinal arteries and high blood-pressure as determined by the hardness of the pulse Moore (1916) found it difficult to say whether the arteries in an individual case were reduced in size when direct comparison with the normal was not possible and when the normal itself was inconstant, but he believed that this should be considered as one of the signs of 'arteriosclerosis' Recent studies are in accordance with this view (Wagener, 1937, Bjork, 1946) The difficulty is to decide whether the arteriole is narrow or not, as the actual width cannot ordinarily be measured An attempt has been made in the present investigation to assess arterial narrowing by comparing the width of each of the four main arterioles in both eyes with that of its companion vein, the arterio-venous ratio It was subsequently found that Gowers himself had described this method in his text-book of 1890 and his description cannot be bettered

> 'The relative size of the arteries and veins can be observed with more exactness than their absolute size A difficulty arises from the fact that the distribution of the arteries and veins corresponds approximately but not exactly Sometimes two arterial branches accompany one venous trunk, sometimes two veins accompany one artery But in each eye there is usually at least one set of vessels which have a nearly identical course and distribution, run side by side, and are available for comparison When this is the case it will be found that, as a rule, the width of the artery is about two-thirds or three-quarters that of the vein Special attention must be given to the number of primary branches of the vessel It often happens that veins are thought to be pathologically large merely because they are few'

It was found in the present investigation that if the branching of the veins followed the usual pattern, provided that papilloedema, high venous pressure, or local thrombosis was absent, little variation in the absolute size of the veins occurred in a large number of cases with emmetropia This measurement was carried out with a graticule mounted in the ophthalmoscope so as to project a scale on the retina Apparent variation in the size of the vein due to magnification from refractive errors may occur, but is clearly of no importance when considering the arterio-venous ratio, because the artery also would be affected The most important obstacle to comparison of the width of the arteriole with that of its companion vein lies in unpaired, or asymmetrical branching of the artery and vein It is very common to see three or four small arterioles accompanied by only one vein, and no arterio-venous ratio is then possible The ratio of artery to vein was recorded in sixths in as many of the eight main branches as possible (Table I)

Pallor of the arterioles (Plate 27, Fig 5) Pallor of the arteriolar blood column (Wagener, 1935) is a more difficult sign to recognize because these vessels are normally paler than the veins The edges of the blood columns should be compared, thus excluding changes due to the light reflex

The arterio-venous crossings (Plate 27, Fig 5) Much has been written about the changes at arterio-venous crossings Normal variations are frequent and introduce difficulty, for example, slight bending or displacement of the vein from its course and slight increase in the opacity of the arterial blood column obscuring the vein (Pines, 1929) These changes have not been considered Rare phenomena such as banking or evidence of venous obstruction at the crossings and pipe-stem sheathing have also been excluded Nipping implies apparent constriction of the vein when it is crossed by an artery (Plate 27, Fig 5) Opacity of the arterial wall may be deduced from the presence of a clear area on either side of the arterial blood column as it crosses the vein (Plate 27, Fig 5) *Normally the venous blood column can be seen right up to the edge of the arterial column and, indeed, often right through it*

Accentuation of the light reflex (Plate 27, Fig 5) Normally the light reflex consists of a narrow, clear, bright streak bounded on either side by two distinct dark red lines Accentuation of the light streak is usually described in terms of copper or silver wire, and these expressions are a source of bewilderment to the ordinary observer It is better to describe the light reflex as being brighter, or wider than usual, whichever is the case This is a difficult physical sign to interpret because it is an accentuation of a normal feature No reliance can be placed on changes in the light reflex at or near the disk Irregularity of the reflex is found mainly in severe cases (Moore, 1916)

Tortuosity of the retinal arterioles This was not considered to be a sign of hypertension because it was found as frequently in old people with a normal blood-pressure as in those with a high blood-pressure This is in agreement with Moore (1916) A search was not made for tortuosity of the small arterioles in the macular region because it is of infrequent occurrence (Moore, 1916) and can be observed only through a dilated pupil (de Schweinitz, 1906)

The blood-pressure This was taken with a mercurial manometer in the manner recommended by the Cardiac Society and the American Heart Association in 1939 The readings were taken to the nearest multiple of five with the patient recumbent A blood-pressure of 155/90 was taken as the highest normal figure

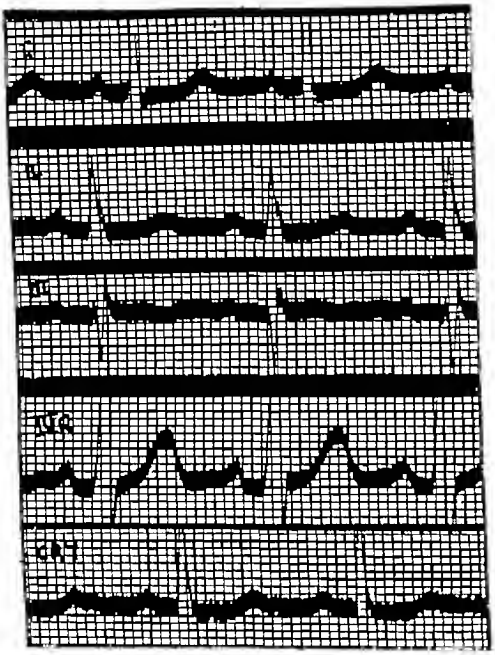

FIG 1 Slight left ventricular preponderance (+)

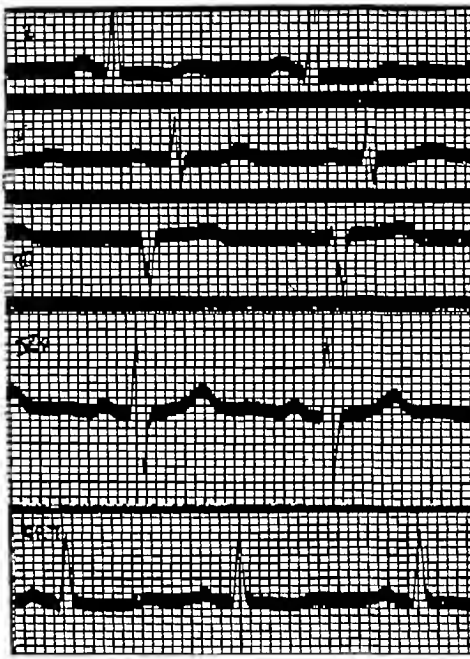

FIG 2 Moderate left ventricular preponderance (++)

Since it was difficult to classify patients with variable readings, the lowest reading obtained on or near the date of ophthalmoscopy was taken

The size of the left ventricle This was assessed by anterior and left oblique fluoroscopic views Admittedly this method depends upon personal experience, but it is generally considered to be more reliable than the cardio-thoracic ratio (Parkinson, 1936, White, 1944, Schwedel, 1948) Enlargement was graded as slight (+), moderate (++), and great (+++) (Plate 28, Figs 6, 7, and 8) Care was taken to distinguish the left ventricle of the transversely lying heart from that abnormally enlarged and to exclude patients with cardiac enlargement from infarction or any cause other than hypertension

The electrocardiogram The electrocardiogram was analysed for ventricular preponderance as shown by changes in the S-T segments and T waves Depression of the S-T segments with low T waves in leads I, II, and CR_7 was described as slight left ventricular preponderance (+) (Fig 1) If the T waves were flat, it was described as moderate left ventricular preponderance (++) (Fig. 2) If the T wave in lead I or CR_7 was inverted, it was termed great left ventricular preponderance (+++) (Fig 3) Care was taken to exclude all cases of cardiac infarction If there was any suspicion of this condition from the history and

physical signs, or if the electrocardiogram was not characteristic of left ventricular preponderance, the record was discarded Electrical axis deviation was always recorded, but it was not considered in the final analysis because it is not a specific sign of left ventricular enlargement

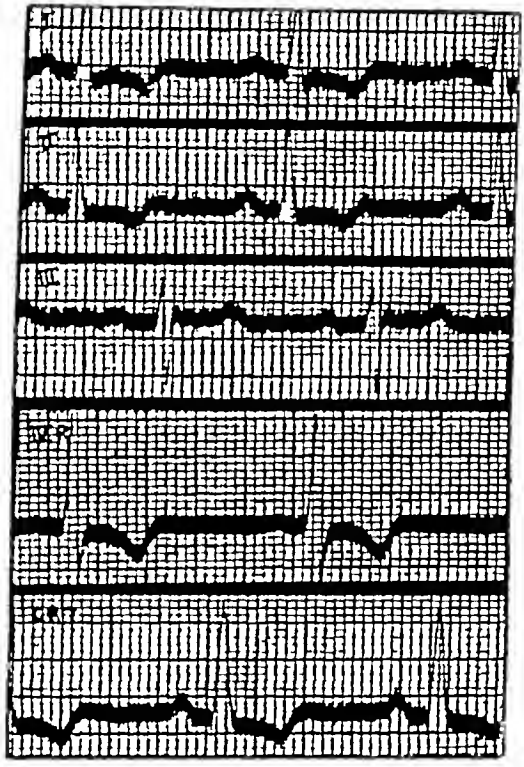

FIG 3 Great left ventricular preponderance (+++)

Results

The retinal arterioles in hypertension The fundi of 45 patients with hypertension where the diastolic pressure was 110 mm Hg or more were compared with those of 103 healthy subjects, including 14 old people with a systolic pressure of 155 or less and a diastolic pressure of 90 or less (Table II) From analysis of the tables prepared, it was found that irregularity of lumen in two or more arterioles never occurred in subjects without hypertension Irregularity of lumen in two arterioles out of the possible eight in both fundi was regarded as slight (+), in three as moderate (++), and in four or more as great (+++) Irregularity of lumen was found in 76 per cent of the subjects with a high diastolic pressure An arterio-venous ratio of 3/6 in one pair of comparable vessels, with most of the others showing a ratio less than the normal 4/6, was not found in subjects without hypertension and was regarded as evidence of slight (+) narrowing A 3/6 arterio-venous ratio in two pairs was regarded as

moderate (++) narrowing, and in three or more as great (+++) narrowing In this way generalized narrowing was found in 61 per cent of subjects with a high diastolic pressure Other abnormalities occurred quite often in hypertension, but were also found in health There was pallor of the arterial blood column in 94 per cent of those with hypertension, but also in 5 per cent of

TABLE II

The Retinal Arterioles in Hypertension

	Irregularity of the lumen	*Narrowing*	*Pallor of the blood column*	*Nipping at arterio-venous crossings*	*Opacity of the arteriolar wall at arterio-venous crossings*	*Light reflex broader or more prominent than normal*	*Hypertensive retinal arterioles*
HYPERTENSION							
Diastolic pressure 110 or more (45 cases)	76	61	94	36	38	61	89
CONTROL SERIES							
Systolic pressure 155 or less and diastolic pressure 90 or less (103 cases)	0	0	5 4	2	5	12	0

The figures are in percentages

the healthy subjects There were changes at the arterio-venous crossings in 37 per cent of those with hypertension, but also in 2 to 5 per cent of the control series The light reflex was prominent or broad in 61 per cent of those with hypertension, but also in 12 per cent of the control series However, combinations of at least two of these three lesser signs, pallor, arterio-venous crossing changes, and abnormality of the light streak, were found only in hypertension Of all the cases with hypertension, 89 per cent were found to have changes peculiar to hypertension in the retinal arterioles, and these may be described as hypertensive retinal arterioles

The relation of changes in the retinal arterioles to the systolic and diastolic blood-pressure, hardening of the brachial artery, enlargement of the left ventricle, and left ventricular preponderance in the electrocardiograms The diastolic pressure is more significant than the systolic in cardiovascular disease, since it represents the resistance which the ventricular contraction must overcome to open the aortic valves, and approximates more closely to the mean blood-pressure Furthermore, it has been shown (Fineberg, 1927, White, 1944) that the prognosis in hypertension depends mainly on the diastolic pressure For these reasons, the cases have been arranged according to the value of the diastolic and systolic blood-pressure (Table III)

Hypertension with high diastolic pressure (Table III) Forty-five subjects had a high diastolic pressure (110 mm Hg or over) Hypertensive retinal arterioles were present in 89 per cent of this group If the changes were graded from + to +++ in severity, an average of +++ was recorded for this group Nevertheless 11 per cent showed no changes which were diagnostic of hypertension The left ventricle was enlarged in 89 per cent and the right brachial artery was hardened in 92 per cent In 32 subjects the diastolic pressure was slightly raised (95 to 105 mm Hg), 62 per cent of this group had hypertensive retinal

physical signs, or if the electrocardiogram was not characteristic of left ventricular preponderance, the record was discarded Electrical axis deviation was always recorded, but it was not considered in the final analysis because it is not a specific sign of left ventricular enlargement

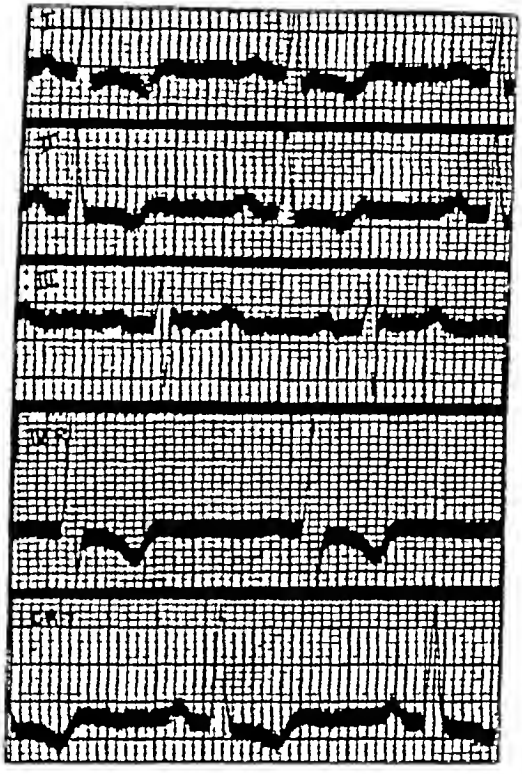

Fig 3 Great left ventricular preponderance (+++)

Results

The retinal arterioles in hypertension The fundi of 45 patients with hypertension where the diastolic pressure was 110 mm Hg or more were compared with those of 103 healthy subjects, including 14 old people with a systolic pressure of 155 or less and a diastolic pressure of 90 or less (Table II) From analysis of the tables prepared, it was found that irregularity of lumen in two or more arterioles never occurred in subjects without hypertension Irregularity of lumen in two arterioles out of the possible eight in both fundi was regarded as slight (+), in three as moderate (++), and in four or more as great (+++) Irregularity of lumen was found in 76 per cent of the subjects with a high diastolic pressure An arterio-venous ratio of 3/6 in one pair of comparable vessels, with most of the others showing a ratio less than the normal 4/6, was not found in subjects without hypertension and was regarded as evidence of slight (+) narrowing A 3/6 arterio-venous ratio in two pairs was regarded as

arterioles, and the average severity of the changes was graded as ++, 56 per cent had an enlarged left ventricle The value of ophthalmoscopy was particularly clear in the borderline group of seven patients with a diastolic pressure of 95 Three had hypertensive retinal arterioles and all were later found to have enlargement of the left ventricle Of the other four with normal retinal arterioles, only one had enlargement of the left ventricle and this was slight

Hypertension with high systolic pressure but normal diastolic pressure In 34 patients the systolic pressure was moderately raised (160 to 220 mm. Hg) though the diastolic pressure was normal (90 mm Hg or under) They showed a lower incidence of changes in the retinal arterioles (50 per cent) than the group with slight diastolic hypertension (62 per cent), and occurred in older people The average age of the 34 patients in this group was 63 years, compared with 56 years in 45 with a diastolic pressure between 110 and 160 mm Hg A rise in systolic pressure is to be expected in old people with a loss of elastic recoil in the aorta and great vessels Nevertheless, in many of these patients the hypertension was probably significant, since the left ventricle was enlarged in 44 per cent and there was left ventricular preponderance in the electrocardiogram in 25 per cent Thus in the older age-groups it is probable that hypertension with high systolic and normal diastolic pressure can cause signs of cardiovascular hypertrophy The retinal arterioles may be helpful here, they were characteristic of hypertension in 80 per cent of patients with an enlarged left ventricle, but in 21 per cent with a normal left ventricle

Control series There were 14 healthy subjects aged over 65 years with a normal blood-pressure who were examined specially for retinal vascular changes Many had hardening of the brachial artery Not one of the 14 cases showed the alterations in the retinal arterioles here described as being typical of hypertension, but there was a slightly greater incidence of the signs, such as pallor of the arterioles and increase in the light reflex, which occurred naturally in some healthy subjects Tortuosity of the retinal arterioles, considered by some to be a sign of hypertension, was observed as frequently in old people with normal blood-pressure as in those with high blood-pressure In addition to the group of elderly subjects, an examination was made of 89 healthy younger persons. Hypertensive retinal arterioles were never seen These patients were interspersed with the hypertensive subjects, and ophthalmoscopy was invariably performed while in ignorance of the blood-pressure From consideration of the blood-pressure groups it was found, firstly, that alterations in the retinal arterioles were associated with the diastolic pressure more often than the systolic, and a diastolic pressure of from 95 to 105 was more likely to be accompanied by changes in these vessels than a systolic of 180 or more with a normal diastolic pressure Secondly, in old age, when arteriosclerosis is likely to be present, there were none of the changes in the retinal arterioles which are here considered to be diagnostic of hypertension There was a slight increase over the incidence of changes found in the younger controls, but all were within normal limits Thirdly, the brachial artery was hard in 92 per cent of 45 patients with a diastolic pressure of 110 or over, but also in a quarter of the

Table III

	Blood-pressure: Systolic	Blood-pressure: Diastolic	Cases	Retinal arterioles: Irregularity of the fundus	Retinal arterioles: Narrowing	Retinal arterioles: Pallor of the blood column	Retinal arterioles: Nipping at arterio-venous crossings	Retinal arterioles: Opacity of the arterio-venous wall at arterio-venous crossings	Retinal arterioles: Light reflex broader or more prominent than normal	Retinal arterioles: Hypertension of retinal arterioles	Retinal arterioles: Average severity of all signs	Hardening of the brachial artery	Enlargement of the left ventricle on fluoroscopy	Left ventricular preponderance in the electro-cardiogram
Hypertension with high diastolic pressure	Variable	110 to 160	45 (average 50 yr.)	76	61	94	36	38	61	89	+++	92	89	69
Hypertension with high diastolic pressure	Variable	95 to 105	32 (average 55 yr.)	37	38	85	12	16	28	62	++	82	56	16
Hypertension with high systolic pressure only	160–220	90 or under	34 (average 63 yr.)	32	23	83	15	15	32	50	++	86	44	25
Control series: Old people	155 or under	90 or under	14 (average 71 yr.)	0	0	10	0	0	21	0	—	33	0	0
Control series: Others	155 or under	90 or under	80 (average 43 yr.)	0	0	4	2	5	11	0	—	24	0	0

The figures are in percentages

results of the present investigation are in agreement with Friedenwald on this point Arterio-venous crossing abnormalities occurred in 37 per cent of cases with hypertension, but also in from 2 to 5 per cent of the control series Obvious changes at the arterio-venous crossings were seen only in hypertension Irregularity of the lumen of the retinal arterioles was found to be the best sign of hypertension, and was seen in 76 per cent It was never seen in over 100 healthy people, providing that astigmatism was excluded by examining the same length of vessel at slightly different angles It did not occur in old people with normal blood-pressure This sign therefore is of great value, and reliance may be placed upon it if a careful examination has been made Each arteriole, and particularly the smaller branches, must be searched for it, and the finding of equivocal signs such as pallor of the blood column or slight alterations in the arterio-venous ratio should indicate the need for a more careful search for irregularity of the lumen There was generalized narrowing in 61 per cent of those with hypertension, but not in any controls, including the group of old people This confirms the findings of Gowers (1876), Moore (1916), Friedenwald (1931), and Bjork (1946), but is contrary to the views of Wagener (1935), who considered that there was an attenuation of arterioles in old age without hypertension. Generalized narrowing was determined by the arterio-venous ratio, but the greatest care must be taken to see that there is comparable branching before such a ratio is accepted Unfortunately, there is often no comparable branching and no arterio-venous ratio can be determined Great care is needed to exclude the presence of a small arterial twig branching off at an early stage in the region of the optic disk with no comparable branch from the vein The other changes must be found in combination to be diagnostic of hypertension Hypertension may therefore be diagnosed with reasonable certainty on ophthalmoscopic findings alone on one of the following three criteria

1 Irregularity of lumen in at least two arterioles

2 Generalized arteriolar narrowing as shown by alteration in the ratio between the width of arterioles and their companion veins, provided that comparable branching is found For the diagnosis of hypertension at least one retinal arteriole should be half the width of its companion vein with less than the normal two to three ratio between most of the others

3 Pallor of the arteriolar blood column, arterio-venous crossing changes, and a broad or bright light streak Of these three changes, at least two must be seen for the diagnosis of hypertension

It is clear that the features described indicate hypertension and not merely arteriosclerosis This is in agreement with Gunn (1898), who did not believe that they could be due to old age alone It is suggested that such arterioles be called hypertensive retinal arterioles rather than arteriosclerotic or arteriolosclerotic, as these terms merely imply purely degenerative changes which can occur in otherwise healthy subjects

Careful studies correlating retinal vascular changes, electrocardiographic alterations, and radiological heart size have been carried out by Roesler,

healthy subjects, a finding in agreement with Wagener (1923), who stated that there was no correlation between alterations in the retinal arterioles and peripheral arteriosclerosis It follows that a patient with a soft brachial artery is very unlikely to have hypertension of serious degree, but the converse is not true

The relation of hypertensive retinal arterioles to enlargement of the left ventricle (Plate 28, Figs 6, 7, and 8) and to left ventricular preponderance in the

TABLE IV

The Relation of Hypertensive Retinal Arterioles to Enlargement of the Left Ventricle

Enlargement of left ventricle	*Number of patients*	*Hypertensive retinal arterioles*	*Severity of changes in the retinal arterioles*
Great	14	13 (93%)	Great
Moderate	41	37 (90%)	Great
Slight	18	12 (66%)	Moderate
No enlargement of left ventricle	38	14 (37%)	Slight

TABLE V

The Relation of Hypertensive Retinal Arterioles to the Electrocardiogram of Left Ventricular Preponderance

Electrocardiogram of left ventricular preponderance	*Number of patients*	*Hypertensive retinal arterioles*	*Severity of changes in the retinal arterioles*
Great	21	20 (95%)	Great
Moderate	9	8 (89%)	Great
Slight	8	7 (87%)	Great
Absent	38	25 (66%)	Moderate

electrocardiogram (Figs 1, 2, and 3) All the patients with great enlargement of the left ventricle on fluoroscopy (Plate 28, Fig 8) had great changes in the retinal vessels, while 64 per cent of those with slight enlargement (Plate 28, Fig 6) had changes which were moderate in degree With a left ventricle of normal appearance 38 per cent had hypertensive retinal arterioles

With great changes in the electrocardiogram, namely, inversion of the T waves in leads I, II, and CR_7 (Fig 3), there were hypertensive retinal arterioles in 95 per cent With slight changes in the electrocardiogram, namely, S-T depression and low T waves in lead I or CR_7 (Fig 1), there were hypertensive retinal arterioles in 87 per cent With a normal electrocardiogram there were hypertensive retinal arterioles in 66 per cent

Discussion

There have been many accounts of the retinal vessels in hypertension since Gunn's classical paper in 1898 The growth of knowledge of these changes has been well reviewed by Wagener (1930, 1937) and Friedenwald (1931) Nevertheless the criteria for the diagnosis of so-called retinal arteriosclerosis have varied It is customary to place great reliance on arterio-venous crossing phenomena (Moore, 1916) Friedenwald (1931) and Friedenwald and Friedenwald (1929) thought that these were not diagnostic signs of hypertension unless the changes were extreme, slight changes occurred in normal people The

I wish to thank the Physicians to the National Heart Hospital who have given me facilities for examining patients under their care, and also Dr William Evans, Sir John Parkinson, and Mr Foster Moore for much helpful advice I am grateful to Dr T V L Critchlow for radiological facilities at Aylesbury, and to the Aylesbury Town Council for permission to see patients in the Infirmary

REFERENCES

Bjork, S (1946) *Acta med Scand* **124**, 175, Suppl
Coats, G (1906) *Ophthalmoscope*, **4**, 605
—— (1913) *Trans Ophthal Soc U.K* **33**, 30 and 48
Cohen, M. (1943) *Arch Ophthal* **29**, 85
de Schweinitz, G E (1906) *Ophthal Rec* **15**, 383
Fineberg, M H (1927) *Amer J Med Sc* **173**, 835
Friedenwald, H (1931) *Trans Ophthal Soc U.K* **50**, 452
—— and Friedenwald, J S (1929) *Bull Johns Hopkins Hosp* **45**, 232
Gowers, W R (1876) *Brit Med J* **2**, 743
—— (1890) *A Manual and Atlas of Medical Ophthalmoscopy*, edited with the assistance of Marcus Gunn, 3rd ed , London.
Gunn, Marcus (1898) *Trans Ophthal Soc U.K* **18**, 356
Haselhorst, G , and Mylius, K (1928) *Zlb f Gynäk* **52**, 1180
Keith, N M , Wagener, H P , and Barker, N W (1939) *Amer J Med Sc* **197**, 332
Manlove, F R (1946) *Arch intern Med* **78**, 419
Moore, R (1916–17) *Quart J Med* **10**, 29
O'Hare, J P , and Walker, W G (1924) *Arch intern Med* **33**, 343
——, Calhoun, A. W , and Altnow, H O (1928) *J Amer Med Ass* **90**, 1436
Parkinson, J (1936) *Lancet*, **1**, 1337 and 1391
Pines, N (1929) *Brit J Ophthal* **13**, 97, 161, 225
Raehlmann, E (1902) *Z Augenheilk* **7**, 425
Roesler, H , Gibson, G G , and Hussey, R (1940) *Ann intern Med* **13**, 1814
Schwedel, B (1948) *Clinical Roentgenology of the Heart*, New York.
Wagener, H. P (1923) *Med Clin N Am* **7**, 275
—— (1930) *Arch Ophthal* **3**, 335
—— (1935) in *The Kidney in Health and Disease*, by Berglund, H , and Medes, G , Philad
—— (1937) *Penn Med J* **40**, 705
White, P D (1944) *Heart Disease*, 3rd ed., New York

Gibson, and Hussey (1940) In their investigations, as in many other recent papers on the subject, Keith, Wagener, and Barker's (1939) four groups were used to indicate the severity of the retinal changes This system has been avoided here in order to make an analysis of the changes which are characteristic of hypertension, in addition an attempt has been made to carry the correlation farther by studying the severity of the changes and by relating the changes in the retinal arterioles to both the diastolic and systolic blood-pressure. In 45 patients with a high diastolic pressure, hypertensive retinal arterioles were found in 89 per cent, enlargement of the left ventricle in 89 per cent, and left ventricular preponderance in 69 per cent In 34 patients with a high systolic pressure and normal diastolic pressure, hypertensive retinal arterioles were found in 50 per cent, enlargement of the left ventricle in 44 per cent, and left ventricular preponderance in 25 per cent Of the 111 patients in the series with hypertension, systolic or diastolic, 70 per cent had changes in the retinal arterioles which were never found in health or old age, 66 per cent had enlargement of the left ventricle, and 50 per cent left ventricular preponderance in the electrocardiogram Roesler, Gibson, and Hussey (1940), with a similar definition of hypertension, found changes in the retinal arterioles in all of their 80 patients, enlargement of the left ventricle in 78 per cent, and left ventricular preponderance in 69 per cent

Summary and Conclusions

1. The condition of the retinal arterioles has been studied in 214 patients, of whom 111 had hypertension of varying degree and 103 were normal controls, the last including 14 persons over 65 years of age

2 The changes in the retinal arterioles most characteristic of hypertension were irregularity of the lumen and generalized narrowing The lesser changes, including pallor of the arteriolar blood column, arterio-venous crossing changes, and a broadened or exaggerated light reflex, were seen in health, but when combined they indicated hypertension It is suggested that such retinal arterioles should be called hypertensive retinal arterioles and not arteriosclerotic or arteriolosclerotic, for this implies purely degenerative changes which can occur in health In about 10 per cent of patients with a diastolic pressure of 110 mm Hg or over, the retinal vessels were within normal limits

3 Changes in the retinal arterioles were found more often in patients with a high diastolic blood-pressure than in those with a high systolic and normal diastolic pressure

4 Changes in the retinal arterioles were found more often in hypertensive patients with radiological enlargement of the left ventricle and left ventricular preponderance in the electrocardiogram than in patients without these signs of cardiovascular hypertrophy

5 In patients with cardiac enlargement of unknown aetiology and a normal or equivocal blood-pressure, examination of the retinal vessels should help to decide whether hypertension is the cause or not

I wish to thank the Physicians to the National Heart Hospital who have given me facilities for examining patients under their care, and also Dr William Evans, Sir John Parkinson, and Mr Foster Moore for much helpful advice I am grateful to Dr T V. L Critchlow for radiological facilities at Aylesbury, and to the Aylesbury Town Council for permission to see patients in the Infirmary

REFERENCES

Bjork, S (1946) *Acta med Scand* **124**, 175, Suppl
Coats, G (1906) *Ophthalmoscope*, **4**, 605
—— (1913) *Trans Ophthal Soc U.K* **33**, 30 and 48
Cohen, M (1943) *Arch Ophthal* **29**, 85
de Schweinitz, G E (1906) *Ophthal Rec* **15**, 383
Fineberg, M H (1927) *Amer J Med Sc* **173**, 835
Friedenwald, H. (1931) *Trans Ophthal Soc U.K* **50**, 452.
—— and Friedenwald, J S (1929) *Bull Johns Hopkins Hosp* **45**, 232
Gowers, W R (1876) *Brit Med J* **2**, 743
—— (1890) *A Manual and Atlas of Medical Ophthalmoscopy*, edited with the assistance of Marcus Gunn, 3rd ed , London
Gunn, Marcus (1898) *Trans Ophthal Soc U.K* **18**, 356
Haselhorst, G , and Mylius, K. (1928) *Zlb f Gynäk* **52**, 1180
Keith, N M , Wagener, H P , and Barker, N W (1939) *Amer J Med Sc* **197**, 332.
Manlove, F R (1946) *Arch intern. Med* **78**, 419
Moore, R (1916–17) *Quart J Med* **10**, 29
O'Hare, J P , and Walker, W G (1924) *Arch intern Med* **33**, 343
——, Calhoun, A. W , and Altnow, H O (1928) *J Amer Med Ass* **90**, 1436
Parkinson, J (1936) *Lancet*, **1**, 1337 and 1391
Pines, N (1929) *Brit J Ophthal* **13**, 97, 161, 225
Raehlmann, E (1902) *Z Augenheilk* **7**, 425
Roesler, H , Gibson, G G , and Hussey, R (1940) *Ann intern Med* **13**, 1814
Schwedel, B (1948) *Clinical Roentgenology of the Heart*, New York.
Wagener, H P (1923) *Med Clin N Am* **7**, 275
—— (1930) *Arch Ophthal* **3**, 335
—— (1935) in *The Kidney in Health and Disease*, by Berglund, H , and Medes, G , Philad
—— (1937) *Penn Med J* **40**, 705
White, P D (1944) *Heart Disease*, 3rd ed., New York



FIG 3 Normal retinal vessels

FIG 4 Hypertensive retinal arterioles (as described in Table I)
Irr lum Irregularity of the lumen of the arterioles
A/V ratio 3/6 The ratio of the width of the arteriole to that of its companion vein is 3/6
Pallor Pallor of the arteriolar blood column
Nip Nipping at arterio venous crossings
Op Opacity of the arterial wall at arterio venous crossings
L R + Light reflex broader or more prominent than is normal

FIG 6 Slight enlargement of the left ventricle (+)

FIG 7 Moderate enlargement of the left ventricle (++)

FIG 8 Great enlargement of the left ventricle (+++)

616 721–002 77

ANKYLOSING SPONDYLITIS[1]

By F DUDLEY HART, K C ROBINSON, F M ALLCHIN, AND N F MACLAGAN

(From the Westminster Hospital, London)

With Plates 29 to 32

Introduction

ANKYLOSING spondylitis, as it principally affects the male sex in the second, third, and fourth decades, tends to come to the fore in times of war, as it is that sex and age-group which make up the mass of the armed forces Since 1939 numerous cases have come to our notice The present paper brings out some of the points of interest which we have noted during the study of 43 cases seen and treated one to six years previously, and the study of 30 additional cases recently investigated at this hospital

We have retained the use of the descriptive title ankylosing spondylitis for a variety of reasons Although the condition appears to be essentially an infective spondylitis, the natural history in the majority of cases is different from that of rheumatoid arthritis, and the title rheumatoid spondylitis therefore may tend to mislead The aetiology of both conditions remains unknown, there is little to be gained by classifying them under the same heading when clinically, radiologically, and therapeutically the two conditions remain distinct Sex and age-incidence, affected joint distribution, mode of spread, secondary calcification, and response to treatment are all entirely different

Symptomatology

The commonest complaints in the history of our patients were as follows

Backache In most the first complaint was of lumbo-sacral backache Many patients complained primarily of pain in the buttock or buttocks Mid-lumbar aches were the first complaint in some cases, while in others the pain was in the mid-thoracic and cervical regions At the onset such aches and pains were usually trivial and often ignored by the patient's medical officer, or resulted in the patient being treated as a case of 'fibrositis', 'rheumatism', or occasionally 'psychoneurosis' The disappearance of symptoms, which occurred at times after treatment for these conditions, seemed sometimes to confirm such diagnoses Some months later the pain would return accompanied by stiffness Relapse and remission continued remorselessly thereafter, and stiffness gradually progressed to complete fixity of the whole or part of the spine A frequent feature of the pain and stiffness was the aggravation caused by immobility. Waking in the morning stiff and in pain, the patient gradually became more supple

[1] Received November 17, 1948

during the day, feeling at his best from the afternoon until bedtime One patient noted that by frequent exercise his condition was kept in check, but confinomont to bed for any cause made him worse Another woke himself up two-hourly through the night to exercise his spine as otherwise he suffered unduly in the morning He had over a period of years reduced his sleeping hours to six or less, and he never allowed periods of sleep to exceed two hours A few patients were exceptional in that rest appeared to ease the pain A diffuse ache, present as part of the febrile process in an acute exacerbation, also was eased by rest, but even in these cases most of the patients preferred to remain mobile. On the other hand, heavy exertion or strain acted not infrequently as an aggravating factor It is of interest that in our cases the time between the onset of symptoms and the correct diagnosis varied from three months to 30 years, but was usually two to four years

Respiratory symptoms As noted below, some chest symptoms were found in 25 of 40 cases The symptom was largely masked by the more striking spinal pains which dominated the clinical picture and rendered exertion difficult and exertional dyspnoea impossible in most cases Nevertheless, stiffness and tightness in the chest were not infrequently major symptoms The following case is one of the only two, in a series of 30 recently observed in detail, where the sacro-iliac joints were radiologically normal If these joints were normal we did not make the diagnosis of ankylosing spondylitis unless other evidence was strong In the case noted below the diagnosis was made independently by two of us (F M A , F. D H) and Mr E P Brockman

Case 1, a man aged 37 years

He had been previously well Five months before coming to hospital he had noted aches, pains, and stiffness in the lower thoracic spine and across the shoulders Some two months later lumbar pains and stiffness appeared, together with a constricted feeling in the chest He was admitted to Westminster Hospital in great pain, unable to bend his back at all or lie comfortably in bed, and unable to take a deep breath because of the painful constricted feeling in the chest. X-rays showed no signs of spondylitis in the sacro-iliac joints or spine The blood sedimentation rate was 50 mm in 1 hour (Westergren) The temperature and pulse were slightly elevated for the first four days (temperature 99 to 99 5° F and pulse 80 to 100) The chest expansion was only half an inch at the nipple and upper axillary levels The vital capacity was 58 per cent of normal After a course of deep X-ray therapy his chest expansion rose to two inches and vital capacity to 80 per cent of normal Since then he has improved and he is now living a normal life and able to play tennis His present vital capacity is 114 per cent of normal

Fever. Diffuse aches and pains, sweating, fever, and a raised pulse-rate were present in some cases Where these symptoms predominated the patient was sent to hospital as a case of pyrexia of obscure origin, usually for a skiagram of the chest to be taken to exclude pulmonary tuberculosis This type of patient frequently remains undiagnosed for weeks or months, although symptoms and signs are usually striking enough to warrant the correct diagnosis being made at the first attendance.

Sciatic pain This is referred to later.

Mental changes In recent years much has been made of the mental side of rheumatic disease, and the chronic anxious expression and other signs of an anxiety state have been described as essential components of rheumatoid arthritis In our patients with ankylosing spondylitis it has seemed to us that in no way did they differ from the average young man of their age-group What anxiety there was seemed a normal reaction to chronic undiagnosed pain unrelieved by treatment, physical or psychiatric, for months or years, usually the latter A remarkable improvement occurred when the correct diagnosis was made and the condition explained to the patient Many had been seen by Service psychiatrists before the correct diagnosis was reached and in some cases therapy had been given, even convulsion therapy Many had been given physiotherapy for 'fibrositis', and many had been suspected of malingering It is little wonder that in some cases an anxiety element had appeared, but in no case was psychiatric therapy needed once the correct diagnosis was made and treatment started.

Discomfort and tenderness in the ischial tuberosities is commonly a major complaint In such cases X-rays may show changes in bones, such as rarefaction and periosteal reaction (Plate 31, Figs 6 and 7) The patient experiences considerable discomfort on sitting, and shifts on to the less painful buttock to find a comfortable position In several patients tenderness over the crest of the ilium was also found

Physical Signs

Impaired flexion of the spine Commonly early in the disease the lumbar spine was completely fixed by muscle spasm, and was moved in one piece so that with the body erect or flexed it showed no alteration in curvature (Plate 29, Figs 3 and 4) If the cervical spine was affected a characteristic stance and gait were seen, the patient walking stiffly and moving the body as a whole on looking to the right or left. This 'martial bearing' with shoulders held well back and the spine stiff and straight once seen is never forgotten

Diminished thoracic expansion with reduced vital capacity In all but four cases this feature was present on the first examination, it is a very common and early sign in most cases Nevertheless, three patients (with histories of three months, three years, and four years) showed no reduction in chest measurement or vital capacity

The hips were affected slightly in five cases and severely affected in five cases of the 30 studied This, however, can hardly be called an early sign, as the disease had usually been present for months or years before these joints were affected A patient was usually incapacitated by fixed hips to a greater extent than by a completely fixed spine, even though marked kyphosis were also present

Tenderness and slight swelling over the manubriosternal angle was present in three cases, though not as the initial complaint Parasternal tenderness also occurred, discomfort being elicited by palpation over the costal cartilages and intercostal spaces anteriorly close to the sternum

Pains in the shoulders were frequent, but gross shoulder-joint changes were present only in two of 25 cases, and to leading questions only eight of 43 gave positive answers (see below)

It is well to note the absence of physical signs which might be expected to be found in this disease Well-localized and constant tenderness over an affected structure such as the sacro-iliac joints is not a feature In other diseases of the sacro-iliac joint, such as tuberculosis, the part is held extremely carefully, the patient walking with a hand supporting the affected area, and he carefully avoids pressure on that buttock when sitting These points are not seen in ankylosing spondylitis Compression of the pelvis posteriorly and anteriorly does not cause pain in the affected joints in ankylosing spondylitis as it does in other conditions Subcutaneous nodules are not found in this condition as they sometimes are in rheumatoid arthritis The absence of such signs supports Borak's (1946) contention that the condition in the sacro-iliac joints is not a true arthritis early in the disease, but a para-articular osteosclerosis

Later in the disease in some cases there is a tendency to develop an upper thoracic kyphosis, the bent head giving the 'hang-dog' dejected appearance, particularly if cervical disease has restricted rotatory movements This kyphosis comes on variably, sometimes not until the disease has been present for years In one case now under treatment, back pain and stiffness had been present for 14 years before bending forward of the head and shoulders was noted by the patient, the latter sign coinciding with his leaving the Royal Air Force and taking up office work Many patients do not develop kyphosis

Follow-up of patients treated with deep X-ray therapy

A questionnaire was sent to 50 male patients who had received X-ray therapy in Westminster Hospital since the outbreak of war in 1939, 43 forms were returned completed The duration of the disease varied from nine months to 16 years The number of treatments varied from one to six, the last treatment in most cases having been given one to three years previously Symptoms complained of were diffuse pains and stiffness in different parts of the spine, painful and aching ribs especially after exertion, tightness in the chest, inability to regain weight, increased forward curvature of the spine, sciatica, and general weakness The commonest symptoms were stiffness and aching in the lumbo-sacral region and tightness in the chest, less common were aching and stiffness in the neck and across the shoulders The following answers were returned to these specific questions

Question	Answer: Yes	Answer: No
1 Did the X ray treatment relieve your back pain ?	40	3
2 Did the X ray treatment relieve your stiffness in the back ?	33	5
3 Did X-ray treatment relieve any stiffness in the chest ?	15	10

Question	Answer: Yes	Answer: No
4 Have you at any time had sciatica? (Pain radiating down into the leg from the buttock) If so, which side?	31 { Right 11; Left 11; Right and left together 2; Right and left alternating 7 }	12
5 Was shortness of breath on exertion or tightness in the chest present at any time in your case since the onset of the spinal condition?	25	15
6 Have you had any pains and stiffness in the hips?	24	0
7 Have you had any pains and stiffness in the arms and shoulders?	8	0
8 Have you had any rheumatism in the hands	2	
wrists	2	
elbows	1	
ankles	0	38
knees	3	
jaws	1	
	5 cases	

To the question 'is your condition better, unchanged, or worse now than before X-ray treatment started?' the answers were better 32, worse 5, unchanged 3 When asked what effect X-ray treatment had on the hips when affected, the answers were improved 17, no effect 2 To the question 'has any form of treatment other than X-ray therapy helped?' the answer 'no' was returned in 24 cases, in 11 cases benefit had been obtained from some other form of treatment, but any one form of treatment was not mentioned more than twice Such treatments included heat, exercises with and without heat, supports, plaster jackets, and massage There did not appear to be any therapeutic weapon other than deep X-ray therapy which impressed the patients To the question 'did you get most ease during or after treatment?' the answer was 'after' in all cases, though five stated that improvement began during treatment and continued afterwards To the question 'if most ease was noted after treatment had ceased, how long after?' the answers ranged from one to 24 weeks, four weeks being the commonest time interval

It may be said that such follow-up reports are of limited value, because leading questions have to be put and for a variety of reasons the patient may give what answer appears to be expected of him, but certain points do emerge clearly The first is that 43 replies to 50 forms sent out is a high return, particularly as many addresses were Royal Air Force Stations which have long since ceased to exist The majority of forms were returned within a month and the patients were only too glad to co-operate and give all the help that they could Some replies came from as far afield as Siam The general air was one of optimism The reports in the majority of cases were cheerful and the patients in almost all cases were at work Two had developed pulmonary tuberculosis and were in sanatoria Many were able to play games normally. The second point is that to the specific question relating to rheumatic symptoms and signs in the hands, wrists, and elbows, only three complained of anything at all, two had symptoms of pain in the hands and wrists, and one in the elbows From the descriptions it is unlikely that these were due to rheumatoid arthritis

Were ankylosing spondylitis a part of rheumatoid arthritis one would have expected a much higher figure The third point is the satisfactory response to X-ray therapy. The failure to relieve pain in only three of 43 cases and a continued improvement in 32 is better than had been anticipated

The frequency of so-called sciatic pains in ankylosing spondylitis is well brought out in the literature The answers in this respect merely underline the frequency of this symptom The lesson to be learnt is that one should suspect ankylosing spondylitis in a young man with sciatica if the condition is relatively mild, if it is unaccompanied by signs in the central nervous system, and particularly if it is bilateral or alternating In such cases of 'sciatica' the sacro iliac joints should be X-rayed as the first investigation

Investigations

In the past 16 months we have had under investigation and treatment 30 patients with ankylosing spondylitis All but one were male and almost all were Service or ex-Service men The ages varied from 19 to 53 years The duration of symptoms was from three months to 31 years, the average, excluding one exceptionally long 31-year history, was 3 4 years The age at onset varied from 16 to 47, averaging 24 years, and in the large majority the onset was in the 20's

Chest expansion and vital capacity Diminution in vital capacity was found in 18 of 21 patients, the average figure being 79 per cent of normal Fifteen patients had readings taken before and after a course of deep X-ray therapy, the second reading being taken four to 10 days after the last treatment The average figure before treatment was 71 per cent and after treatment 86 per cent, an increase of 15 per cent The increase in chest expansion was also reflected in readings of expansion of the chest at the nipple level, the average expansion before treatment was 1 1 in , after treatment 1 6 in , an increase of 0 5 in As might be expected, the most striking increases occurred as a rule in the patients with shorter histories, but this was not invariably so It was interesting to find that the vital capacity was often markedly reduced without any complaint of dyspnoea on exertion, but as the spinal lesion commonly limited exercise this is hardly surprising

It has been reported (Swaim and Kuhns, 1932) that degenerative changes in the diaphragm lead to poor respiratory excursions by this muscle This was not found in our cases, indeed often with marked fixation of ribs the diaphragmatic excursions were of a high normal order. In some cases the patient seemed to be entirely dependent on the activity of this muscle for any respiratory movement at all In early cases the reduction in vital capacity appeared to be due to pain and stiffness In advanced stationary cases reduction in vital capacity seemed to be due to permanent fixation of the ribs Although after X-ray therapy the most marked increase in vital capacity readings occurred in patients with minimal radiological bony change, some of the more chronic patients with extensive bony change also experienced improvement in this respect

Blood sedimentation rate In common with other writers we have found this investigation of little use in controlling therapy Some patients showed normal rates, others high figures throughout the period of observation, and others fluctuations from normal to high values The great majority of estimations taken were raised In some patients who started treatment with normal figures

TABLE I

Serum-proteins and Serum Colloidal Gold Test

Case	Diagnosis	Serum-proteins (gm per 100 c c) Albumin	Globulin	Total	Serum colloidal gold reaction
	Normal range	4 0 to 5 5	1 5 to 3 0	6 to 8	0
1	Ankylosing spondylitis	3 40	4 90	8 30	0
2	,, ,,	3 80	3 50	7 30	0
3	,, ,,	4 79	3 17	7 96	0
4	,, ,,	4 58	2 72	7 30	0
5	,, ,,	3 90	2 50	6 40	0
6	,, ,,	4 65	2 84	7 49	0
7	,, ,,	4 53	2 01	6 54	0
8	,, ,,	4 72	1 69	6 41	+
9	,, ,,	4 53	1 75	6 28	+
10	,, ,,	5 46	1 07	6 53	0
11	,, ,,	4 33	1 97	6 30	0
12	,, ,,	4 64	2 13	6 77	0
13	,, ,,	5 23	2 51	7 74	++
14	Rheumatoid arthritis	4 20	3 30	7 50	++++
15	,, ,,	2 70	3 00	5 70	++++
16	,, ,,	3 30	2 30	5 60	+
17	,, ,,	3 80	2 70	6 50	+
18	,, ,,	4 64	2 13	6 77	0
19	,, ,,	4 20	2 20	6 40	0
20	,, ,,	4 12	2 68	6 80	+++

the rate rose, in others who started with high figures, it fell As a measure of clinical improvement and response to treatment the sedimentation rate was useless On the other hand, as one of the cardinal diagnostic signs of the disease it is a most useful investigation, though an isolated normal rate does not negative the diagnosis Six of the 30 cases had a normal sedimentation rate when first seen, though none followed for any length of time maintained a normal figure

Haematology A moderate reduction in haemoglobin was the rule in patients who had had prolonged fever and systemic upset Figures varied from 60 to 110 per cent (Haldane) In most cases the haemoglobin was either normal or showed a slight reduction (to 80 or 90 per cent) Where anaemia was present it was of the normochromic or hypochromic type, usually the former White blood-cells were normal in total and differential counts in all cases Eosinophilia noted by Böni (1947) was not seen

Urine examination revealed no abnormality

The Wassermann reaction, Kahn test, and gonococcal complement fixation tests were done as a routine In only one case was the Wassermann and Kahn test positive, in a youth who had syphilis in addition to spondylitis The gonococcal complement fixation tests were all negative

Cardiological investigations. Screening and X-rays did not reveal cardiac abnormalities in our cases and the few electrocardiograms taken were normal.

Neurological investigations We did not attempt routine lumbar puncture and performed this investigation only where the diagnosis was in doubt Boland, Headley, and Hench (1946), in a study of the cerebrospinal fluid of 50 cases

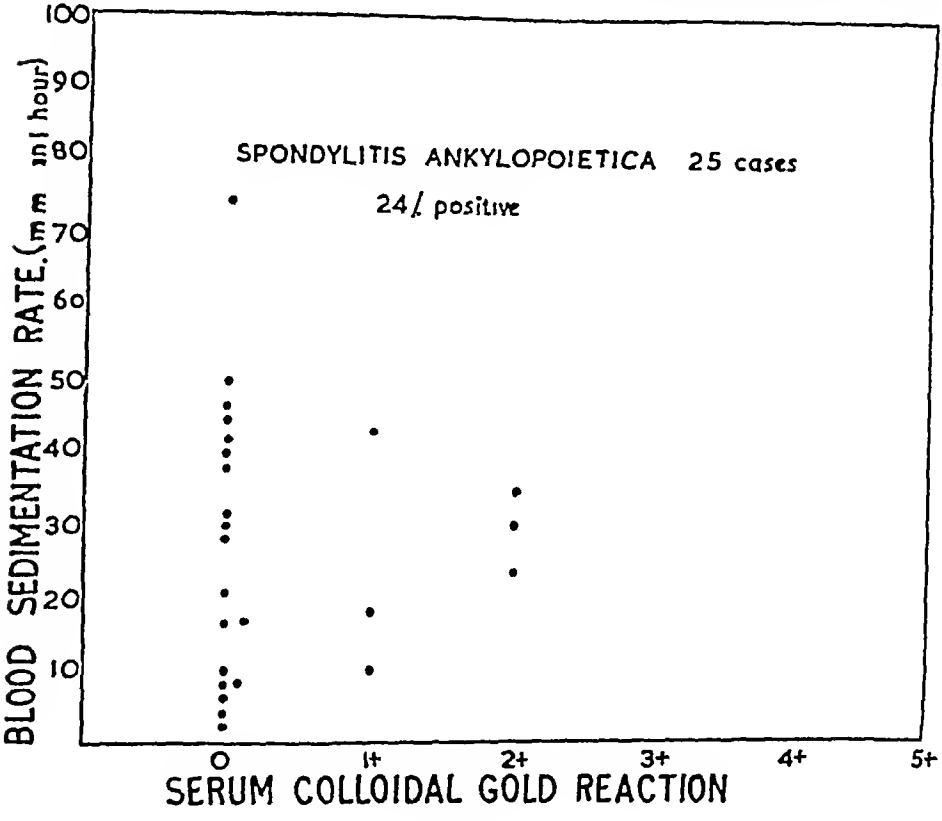

FIG 1

of ankylosing spondylitis, found cell counts, initial manometric pressures, and concentrations of sugar normal in all specimens, but an increase of total protein in 21 cases, the figures ranging from 47 to 98 per 100 c c The increase in protein seemed related to the severity of the disease, and in 17 of the 50 cases peripheral joint changes were present The rise in protein in the cerebrospinal fluid bore no consistent relationship to the duration of the disease or to the degree of spinal involvement, and was not greater in cases with sciatica than in cases without this feature

Biochemical investigations The serum-proteins were estimated in 13 typical cases of spondylitis with the results shown in Table I Seven cases of rheumatoid arthritis are shown for comparison It will be seen from Table I that in rheumatoid arthritis four cases show either some reduction in albumin or some increase in globulin or both, although the results are often within normal limits Similar changes were seen in four of the 13 cases of spondylitis The

combination of high serum-globulin with a negative colloidal gold test was seen only in the spondylitis group, and suggests that the protein changes are not identical with those in rheumatoid arthritis

A further study of the serum colloidal gold reaction was therefore made The test was performed in 25 typical cases of spondylitis by the method of

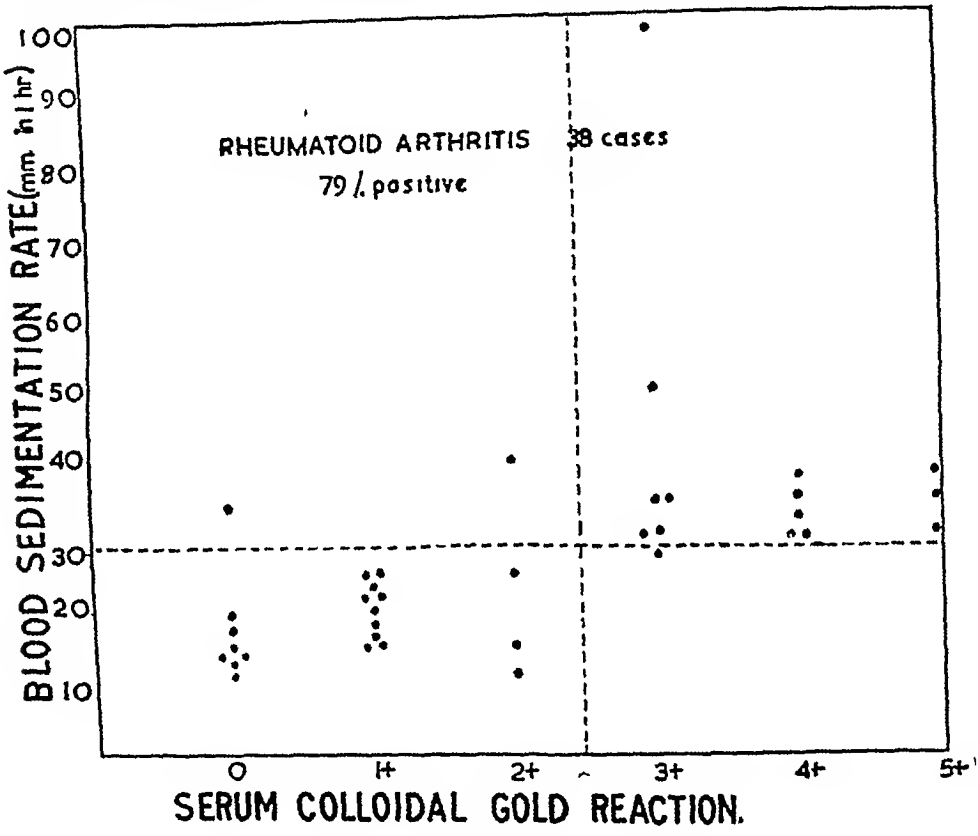

Fig 2

Maclagan (1946), with the results shown in Fig 1 Fig 2 shows a parallel series of cases of rheumatoid arthritis similarly tested, part of the data being taken from Carter and Maclagan (1946) In these figures the gold test is plotted against erythrocyte sedimentation rate as a correlation diagram It is evident that the gold test gives entirely different results in the two conditions, being positive in 79 per cent of cases of rheumatoid arthritis as opposed to only 24 per cent in spondylitis The data on sedimentation rates are included in order to show that the difference in the two groups is not merely one of severity, since the range of sedimentation rates is approximately equal in the two conditions In rheumatoid arthritis there is an obvious correlation between the two tests which is entirely absent in ankylosing spondylitis

Following a report by Davison, Koets, and Kuzell (1947) on the raised 17-ketosteroid excretion in spondylitis the estimation was performed in 10 typical cases with the results shown in Table II

It will be seen from Table II that all the values were within normal limits, so that we are unable to confirm the reported increase

Clinical photography With the co-operation of Dr Peter Hansell, Medical Officer in Charge of the Medical Photographic Department of Westminster Hospital, the range of spinal movements was photographed on squared paper

TABLE II

Urinary Excretion of 17-ketosteroids in Ankylosing Spondylitis

Case	*17-ketosteroids (mg per 24 hours)*
1	20 2
2	18 6
3	17 1
4	14·4
5	12 8
6	12 5
7	12 5
8	6 5
9	5 0
10	4 1

before and after treatment and at variable times in the follow-up period Although this method has its drawbacks it is the best that we have yet evolved in assessing improvement or deterioration in the patient's condition Double exposure on one plate with spine erect and flexed has proved a useful method to estimate improvement in spinal flexion (Plate 30, Fig 5)

Complications Two of the cases in our complete series developed pulmonary tuberculosis and a further one is under observation with minor infiltration in the lung fields Other complications, except iritis in one case, were not found Cough, bronchitis, pneumonia, and other chest complications have not been noted Bronchial spasm and the complaint of tightness in the chest-wall with inability to take a deep breath are easily distinguished by a careful history

Biopsy findings We have not yet seen nodule formation in ankylosing spondylitis nor was splenic or lymphnode enlargement noted in our cases Swelling and tenderness over the manubriosternal junction has already been mentioned In one such case biopsy was performed, the overlying periosteum was found to be oedematous and thickened but histological cellular change was not found in sections of bone and cartilage In four cases muscle biopsy was performed Significant changes were not found in the tissue removed, which consisted of a wedge of skin, subcutaneous tissue, and deltoid muscle Desmarais, Gibson, and Korsley (1948) also reported negative muscle biopsy findings in 17 cases of ankylosing spondylitis, as compared with positive findings in 34 of 56 (61 per cent) cases of rheumatoid arthritis

Pathological findings As none of our cases have come to autopsy we have nothing to add to the descriptions by Guntz (1933), Krebs and Vontz (1934), Eltze (1940), and Freund (1942)

Radiological appearances The X-ray appearances in ankylosing spondylitis vary from the minimum of sacro-iliac irregularity to the gross changes known as 'bamboo spine' The incidence of sacro-iliac change is so great, and it is so

early a sign, that it has almost come to be a criterion of diagnosis The early changes in the sacro-iliac joints consist of lack of definition, blurring of outline in joint spaces, and, later, evidence of actual bony erosion of articular surfaces Thus, in spite of great variation of normal sacro-iliac appearances, the early signs of this disease are always apparent to the experienced eye In a few cases the sole radiographic changes present are confined to the posterior vertebral articulations, and consist of loss of joint space with early ankylosis Following at intervals are the many departures from normal in the radiological appearances of the vertebral bodies, which show change of contour with partial or complete obliteration of the usual concave outline Together with this is a sharpening of the superior and inferior margins of the bodies giving an appearance rather like that of a child's brick Accompanying these bony changes is evidence of sclerosis in the intervertebral ligaments visible only in the best radiographs, and quite invisible in many over-exposed and over-penetrated negatives so often seen to-day This increase in density becomes more and more obvious and at times shows evidence of calcification and later ossification, eventually leading to a complete bridging of the intervertebral spaces, which as a general rule remain clearly defined and the disks of normal thickness When this process has extended for any length of time the appearances described as 'bamboo spine' cannot be mistaken It is important to insist on oblique views of the sacro-iliac joints and the intervertebral articular surfaces before pronouncing any particular area of the vertebral column normal or abnormal, for the changes typical of ankylosing spondylitis occur early in the small intervertebral joints and postero-anterior views are useless in assessing changes in many of them As the direction of the inter-articular surfaces changes between thoracic and lumbar vertebrae the only satisfactory technique is to take several coned oblique views of the intervertebral articulations at different levels down the spine If this is done the involvement is usually seen to be at first haphazard, more joints being affected as time goes on, until, in advanced cases, few or no articular spaces can be visualized, the whole spine being fused There does not seem to be a progressive spread up the vertebral column from the sacro-iliac joints, though commonly the lumbar intervertebral joints are early affected Borak (1946), in a stimulating article on the radiological changes in ankylosing spondylitis, argues that the sacro-iliac joints are normal at the onset of the disease, the apparent involvement of the joints in postero-anterior views being due to para-arthrodial osteosclerosis of the ilium, the ragged, irregular, 'rat-bitten' appearances of the joints in this view being due to iliac sclerosis alone Borak claimed that at this early stage true articular changes are present in the intervertebral joints, but that at this time an oblique 45° view of the sacro-iliac joint shows this joint to be normal The changes that occur later in the sacro-iliac joint are, he stated, due to a degenerative process similar to that seen in old age, and are not part of the same pathological process as that affecting the smaller spinal joints While for many reasons this seems to us to be unlikely, there is no doubt that many of the changes in the postero-anterior views of the sacro-iliac joints are in fact due to para-arthrodial osteosclerosis of the ilium

rather than changes in the joint. This para-arthrodial osteosclerosis of the ilium occurs when the surrounding bone may be considerably rarefied, it fades gradually as the sacro-iliac joint becomes progressively destroyed and gradually ankylosed. Nevertheless, we have found evidence in our cases of true early involvement of the sacro-iliac joint and consider the process here to be the same as that occurring higher in the spine

The costo-vertebral articulations in advanced cases show double fusion, the rib being locked to the transverse process as well as to the body of the thoracic vertebra This is perhaps best seen in the first rib, the normal clear line of articulation becoming first irregular and eroded, and later disappearing as complete fusion occurs (Plate 32, Figs 8 and 9)

Finally, periosteal reactions occur, usually but not invariably late in the disease The bones of the pelvis may show this to a marked degree, the symphysis pubis being in extreme cases fused 'Squaring' of the vertebral bodies, referred to above, is a manifestation of this reaction Change in the ischial tuberosities are referred to elsewhere in the present paper

Treatment

In the absence of established aetiology, treatment must of necessity be empirical Apart from attention to the general health the main methods have been physical On what might be called anti-rheumatic lines, the use of vaccines and gold have been tried with doubtful effect It is the custom to advise postural treatment by orthopaedic measures to prevent deformity, but as the disease progresses for so long a time with such variations in remission and relapse, it is doubtful to what extent such measures really help in the end Wyatt (1945), as a result of his experience in the Ministry of Pensions, advocated mobilization and exercises, and advised against the use of physiotherapy and supports Physiotherapeutic measures, including all forms of heat, in our experience have proved disappointing, and in fact the use of heat in the form of short-wave diathermy appears to aggravate the condition in a number of cases In the periods of quiescence of the disease, gentle massage may be employed with advantage

The therapeutic method which has met with most success has been the employment of X-ray therapy Different opinions have led to the use of diverse methods, but all claim successes Whatever method is employed it should be emphasized that its direction should be in the hands only of experts The use of X-radiation in the treatment of chronic, inflammatory, and infective conditions is well established and has been in use for 30 years Its use in acute inflammation has also found favour, although of course the field here is much more limited The action of X-rays when used in this way must be sharply contrasted with that used in the treatment of neoplastic processes In the latter a lethal effect on neoplastic cells is the primary object, and for this purpose intensive dosage is required, whereas in the former temporary effects, such as depression of cell activity, increased blood and lymph flow, diapedesis, and

proliferation of fibroblasts are desirable For this reason and because the condition concerned is not neoplastic, X-radiation should be given intermittently and in small doses On no account must the dosage be such that permanent tissue changes are produced It is assumed that all the effects produced are local and take place only in the area submitted to irradiation Little evidence exists to support the employment of so-called 'wide field' therapy (Scott, 1939) in which large areas of the body are subjected to 'homoeopathic' doses of X-rays Claims of considerable success have, however, been made for this method In general, X-ray therapy should in our opinion be confined to the affected areas and the appropriate dosage should be given to such areas Some workers make it their practice in all cases to irradiate the whole spine regardless of symptoms (Windeyer, 1948, McWhirter, 1945) In our experience each case is best treated according to its signs and symptoms Where pain and limitation of movement are confined to one region of the spine this region is the site chosen for treatment, where signs and symptoms point to the whole spinal column being involved, treatment is directed to the whole column, including the sacro-iliac regions In some cases where the hip-joints are involved these areas are also treated The method we have adopted is very similar to that advocated by McWhirter, though dosage was small and intermittent Thus, treatment was given only on alternate days, and the total skin dosage administered to any one area did not exceed 1,500 roentgens The routine procedure adopted was to use X-rays of kilovoltage 180 to 200, filtration 1 5 mm of copper, half value layer 1 7 mm of copper, and skin dosage daily to each field treated was not greater than 150 roentgens Treatment was given to not more than two fields daily, and the total treatment time was spread over three weeks In acute cases the daily dosage was even less than that mentioned above and the administration of analgesics was sometimes necessary It is possible to repeat courses of the above treatment in three months and this was often desirable where relief was only partial Such repeated courses were limited by tolerance of the skin and underlying tissue It must be understood that in this condition the dosage delivered should not in any circumstances reach the level of tolerance of the skin, and this implies that the underlying tissues do not at any time receive a dosage which will involve permanent tissue changes

In a very chronic and variably progressive disease an advantage of repeated X-ray therapy is that the patient is kept under observation Except in the extremely advanced cases and those where the hips are affected, treatment may often conveniently be given to out-patients who can continue at light work While undergoing deep X-ray treatment the patient should in our opinion live an easy life, maintaining full spinal mobility yet avoiding heavy exercise and strain to the back Periods of inactivity lead to aggravation of symptoms and increase fixity of the spine, and we do not therefore advise the strict rest which was considered the correct therapy in the past nor do we advocate prolonged immobilization in a plaster jacket or bed We encourage the patient after courses of treatment to maintain full range of movements and to live an active,

healthy life, including cycling, swimming, walking, and later working, if his occupation does not involve repeated back strain or, which is worse, assumption of a cramped, bent position for long periods Rehabilitation early in treatment with exercises under an optimistic therapist is essential, care being taken not to overdo the 'regimental' side of things and so lessen the enthusiasm of the patient Breathing exercises are also important, but like all other exercises, should give place to full natural function as soon as possible Normal respiration is better than artificial over-breathing for short given periods, the over-breathing caused in simple exercises such as walking, swimming, or playing games is the best way of maintaining as full thoracic movements as possible

Surgery Generally speaking the surgeon can offer little help in this disease Osteotomy (Smith-Petersen, Larson, and Aufranc, 1945, La Chapelle, 1946) of hip or spine has been performed and various types of reconstructive procedure for the hips also, such as Whitman's reconstruction, Colonna's operation, Girdlestone's hip incision, Jones's subtrochanteric pseudo-arthrosis (Capener, 1948). There is a risk of increased ossification in these cases and end results are often unsatisfactory Surgical measures on the whole offer little relief Manipulation in the few cases where it had been tried before patients were referred to us had appeared to aggravate the condition and in one case to precipitate a relapse

Penicillin In 12 cases we gave penicillin in doses of 500,000 units intramuscularly daily at three-hourly intervals for 12 to 14 days In no instance did we note any immediate improvement in signs or symptoms and in most cases sedimentation rates rose under treatment and subsequently In no case did the sedimentation rate return to normal after penicillin therapy

Oestrogens We have not attempted oestrogen therapy as reports from elsewhere are discouraging (Freyberg, 1947)

Transfusions of fresh blood Transfusions of fresh blood have been of great assistance in one or two resistant cases Certain cases of ankylosing spondylitis do not derive benefit from deep X-ray therapy Although such cases are not common they are a real problem and extremely difficult to treat It is in these cases that fresh blood transfusions are of occasional assistance We have not yet tried the effect of blood from pregnant women nor have we tried protein shock therapy

Progress and Prognosis

Our follow-up of cases is a relatively short one, all were patients first seen after 1939 and none have been known to us more than six or seven years We are not, therefore, in a position to make pronouncements of the end result in this disease From the literature it appears that relapse and intermission alternate for up to 10 or even 20 years before the disease 'burns out', leaving the patient without active disease but crippled to a variable degree by immobility of the back and neck, and sometimes hips and shoulders, in some cases with a straight spine, in others with forward curvature, the patient facing a point on the ground a short space ahead of his own feet These end results we

have seen, but what proportion of slight cases 'burn out' sooner (the *formes frustes* of Ködderman, 1939) without residual disability, and what proportion merge into osteo-arthritis and are classed as such is not forthcoming from any article to which we have had access From our own series we know that at present the disease is very often not diagnosed until it is relatively far advanced with gross sacro-iliac joint changes We know that complete crippling can occur within a few years or, rarely, months We know the prolonged remissions that deep X-ray therapy can cause, and we know also that duration of symptoms and extent of radiological changes do not run parallel X-ray therapy, particularly applied early in the disease, has not yet been used long enough to assess prognosis in adequately treated early cases Until more is known of the aetiology, early diagnosis and deep X-ray therapy with repeated courses, together with appropriate supervision over many years, appear to offer the best hope

Discussion

The aetiology of ankylosing spondylitis remains entirely unknown There seems to be little to be gained, therefore, by grouping the condition under the general heading of rheumatoid arthritis until more certain evidence than that now available is forthcoming In some respects, however, the diseases are similar in that elevated blood sedimentation rate, low-grade pyrexia, and constitutional upset occur in both ankylosing spondylitis and rheumatoid arthritis In most respects ankylosing spondylitis resembles an infective process rather than a simple metabolic or endocrine one, though the high incidence in male patients suggests that the last factor may play some part in the disease It is possible that some articular infective disease processes may eventually prove to be of virus origin, but as yet evidence in this respect is lacking as regards ankylosing spondylitis Parathyroid disease, prostatic infection, tuberculosis, fluorosis, and a host of other possible aetiological agents have been suggested and found wanting In our series no factor became apparent, and the family histories were likewise unhelpful We agree with Steinbrocker (1942) that ankylosing spondylitis is 'a rheumatoid-like disease with its own characteristic features', and with Buckley (1938) that 'ankylosing spondylitis is often described as rheumatoid arthritis of the spine, but it has many distinctive characteristics and should be regarded as a separate disease'

Our biochemical results are of some interest in relation to previous work and in their possible bearing on the aetiology of the condition A number of observers have reported changes in the serum-proteins in rheumatoid arthritis (Rawls, Weiss, and Collins, 1937, Robinson, 1942, Dole and Rothbard, 1947) and we have been able to confirm these in the seven cases investigated, four of whom showed a slightly raised serum-globulin, lowered serum-albumin, or both Four of the 13 cases of spondylitis showed similar changes The results with the serum colloidal gold test, however, show a striking difference in the two conditions This test, which depends mainly on the serum gamma globulin fraction (Maclagan and Bunn, 1947) was in our experience mainly negative in

spondylitis (76 per cent). This finding is to be contrasted with the positive results obtained in rheumatoid arthritis (79 per cent) which confirmed those previously reported (Carter and Maclagan, 1946) Correlation with the sedimentation rate in both conditions did not suggest that this observed difference could have been due to a different grade of severity in the two groups It appears, therefore, that the serum-protein disturbance is different in the two diseases, rheumatoid arthritis having a tendency to gamma serum-globulin increase, while spondylitis may sometimes show a rise of globulin which is probably not gamma globulin A raised serum-globulin is usually regarded as indicative of the presence of some type of chronic infection The results would, therefore, support an infective theory of ankylosing spondylitis There appear to be two possible explanations of the different serological results in spondylitis and rheumatoid arthritis Firstly, the same hypothetical infective agent might produce different results according to the number and/or nature of the joints involved There appears to be little to support this hypothesis, which would not account for the age and sex distribution Furthermore, the joint fluid from two cases of rheumatoid arthritis has been tested by one of us (N F M) with the gold test with negative results, so that direct absorption of gamma globulin from the joints appears unlikely. Secondly, the two conditions may be due to different aetiological agents This hypothesis appears to be in accordance with the facts at present known, and is the explanation which we regard as most probable

Ankylosing spondylitis can be diagnosed with greater ease than most conditions in medicine The gait, bearing, and the patient's restricted movements can be seen from a distance and their significance should be appreciated It is the more surprising, therefore, that such a long period of time should so often elapse between the onset of symptoms and correct diagnosis, for probably our finding of an average of 2 years and 11 months between the onset of symptoms and correct diagnosis is in no way exceptional A patient with chronic backache is too frequently diagnosed as 'fibrositis' or 'psychogenic backache' and referred to the physiotherapeutic department without full investigation Of the four major diagnostic features, stiff back, restricted thoracic excursion, raised sedimentation rate, and sacro-iliac radiological change, the first two should be noted at once and should lead to the second two investigations being performed

In any chronic relapsing disorder of unknown aetiology logical therapy includes a follow-up system, allows the patient to earn his own living, and yet permits medical supervision so that proper treatment may be administered as frequently and thoroughly as is needed Few chronic articular diseases affect the wage-earning capacity so little, the patients are usually a young, normal, intelligent group of prime importance to the community Only early diagnosis, and earlier and more thorough treatment will show whether this disease may with the available methods be arrested at a non-crippling stage

Summary

1 A follow-up of 43 cases of ankylosing spondylitis treated one to six years previously and a study of 30 fresh cases are discussed

2 The aetiology of the condition remains obscure There seems, in our opinion, little advantage to be gained by using the title rheumatoid spondylitis, as the diagnosis remains a clinical and radiological one, the disease running a different course from, and responding to different therapeutic measures from, rheumatoid arthritis

3 Ankylosing spondylitis is a relapsing, remittent disease lasting many years. This fact has to be taken into consideration in treatment, which should be also spread over a period of years and accompanied by a complete follow-up system The use of clinical photography in such a system is discussed

4 The four cardinal diagnostic features, spinal stiffness, diminished thoracic expansion, raised sedimentation rate, and radiological changes in the sacro-iliac joints, are emphasized Attention is drawn to the long period which has been found to have elapsed between the onset of symptoms and the correct diagnosis being made, the average time being 2 years and 11 months in our series

5 Involvement of the articulations of the thoracic cage, with reduction of vital capacity, is shown to have been present in 18 of 21 cases on their first examination by us Although not invariably present this appears to be a common and early physical sign, characteristic of the disease The average increase in vital capacity readings on completion of a course of deep X-ray therapy was 15 per cent

6 In some cases of ankylosing spondylitis the serum-proteins showed changes similar to those seen in rheumatoid arthritis The urinary excretion of 17-ketosteroids in spondylitis was within normal limits The serum colloidal gold reaction showed a striking difference between rheumatoid arthritis (mainly positive) and spondylitis (mainly negative) Blood sedimentation rate estimations, useful in diagnosis, were found to be unreliable as a test of progress or response to therapy

7 Reasons are given for the view that of the present forms of treatment deep X-ray therapy is the most effective Reasons are also given for favouring maintenance of bodily activity, short of spinal strain, at all stages of treatment in the large majority of cases

8 Attention is drawn to the delayed action of deep X-ray therapy, maximal improvement occurring several weeks or months after cessation of treatment

9 Attention is drawn to the deterioration in prognosis as regards leading a wage-earning existence when the hips are seriously involved This joint is considered the most vital as regards prognosis in this respect Involvement of the hip causes more crippling than does involvement of any of the other joints

We are indebted to Drs C W Buckley and W S C Copeman and Mr E P. Brockman for help in compiling this paper, to Dr Alan Morgan for his reports

on the histology of biopsy material, and to Miss B Lunnon and Miss M. Burchell for technical assistance

REFERENCES

Boland, E W , Headley, N E , and Hench, P S (1946) Amer Rheum Ass Meeting reported in *Ann Rheum Dis* , London 1947, 6, 90
Böni, A (1947) *Schweiz med Wschr* 77, 647
Borak, J (1946) *Radiology*, 47, 128
Buckley, C. W (1938) *Arthritis, Fibrositis, and Gout*, London
Capener, N (1948) Heberden Socy Meeting reported in *Ann Rheum Dis* 7, 19
Carter, A B., and Maclagan, N F (1946) *Brit Med J* 2, 80
Davison, R A , Koets, P , and Kuzell, W. C (1947) *J Clin Endocrin* 7, 201
Desmarais, M H L , Gibson, H J , and Kersley, G D (1948) *Ann Rheum Dis* 7, 132
Dole, V P , and Rothbard, S (1947) *J Clin Invest* 26, 87
Eltze, M (1940) *Med Klin* 36, 1125
Freund, E (1942) *Edin Med J* 49, 91
Freyberg, R H (1947) Discussion Amer Rheum Ass , quoted in *Ann Rheum Dis* , London, 6, 95
Gantz, E (1933) *Fortschr a d Geb d Röntgenstrahlen*, 47, 683
Köddermann, O (1939) *Munch med Wochenschr* 86, 731
Krebs, W , and Vontz, O (1934) *Deutsch med Wochenschr* 60, 100
La Chapelle, E H (1946) *J Bone Joint Surg* 28, 851
Maclagan, N F (1946) *Brit J Exp Path* 27, 369
Maclagan, N F , and Bunn, D (1947) *Biochem J* 41, 580
McWhirter, R (1946) *Brit J Radiol* 18, 302
Rawls, W B , Weiss, S , and Collins, V L (1937) *Ann Int Med* 10, 1021
Robinson, G L (1942–3) *Ann Rheum Dis* 3, 207
Scott, G (1939) *Wide Field X-ray Treatment*, London
Smith Petersen, M N , Larson, C B , and Aufranc, D E (1945) *J Bone and Joint Surg* 27, 1
Steinbrocker, O (1942) *Arthritis in Modern Practice*, Philadelphia
Swann, L T , and Kuhns, J G (1932) *Arch Phys Therap* 13, 517
Windeyer, B W (1948) Personal communication
Wyatt, H (1945) *Brit J Radiol* 18, 301

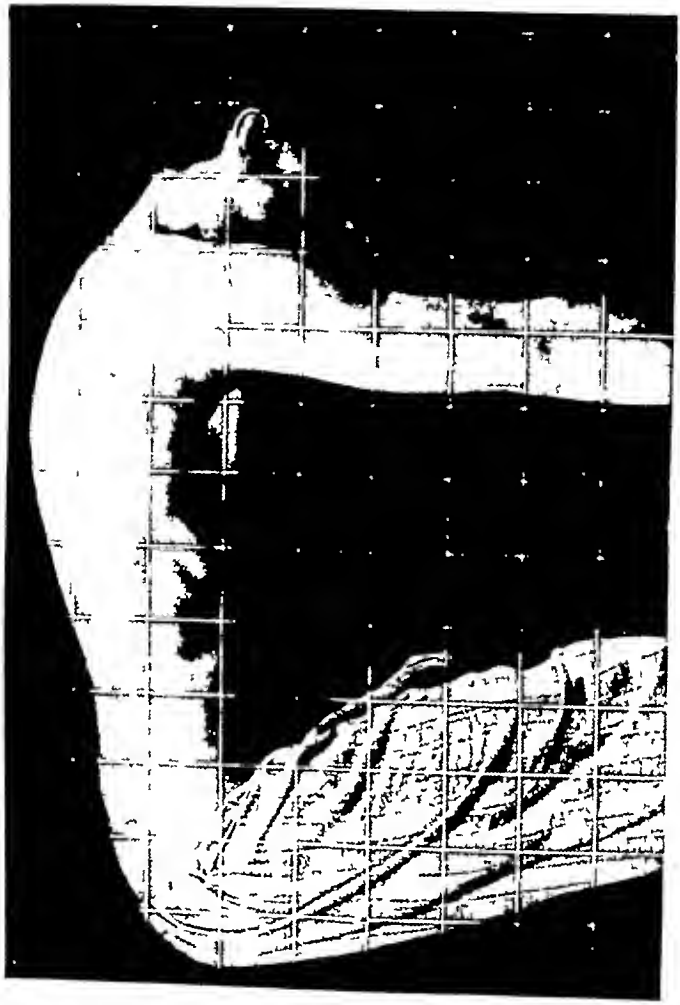

FIG 4

Spondylitis ankylopoietica after irradiation treatment Although the patient can touch his toes, spinal movement is seen to be almost absent



FIG 3

on the histology of biopsy material, and to Miss B Lunnon and Miss M Burchell for technical assistance

REFERENCES

Boland, E W, Headley, N E, and Hench, P S (1946) Amer Rheum Ass Meeting reported in *Ann Rheum Dis*, London 1947, 6, 99
Böni, A (1947) *Schweiz med Wschr* 77, 647
Borak, J (1946) *Radiology*, 47, 128
Buckley, C W (1938) *Arthritis, Fibrositis, and Gout*, London
Capener, N (1948) Hoberden Soey Meeting reported in *Ann Rheum Dis* 7, 19
Carter, A B, and Maclagan, N F (1946) *Brit Med J* 2, 80
Davison, R A, Koets, P, and Kuzell, W C (1947) *J Clin Endocrin* 7, 201
Desmarais, M H L, Gibson, H J, and Kersley, G D (1948) *Ann Rheum Dis* 7, 132
Dole, V P, and Rothbard, S (1947) *J Clin Invest* 26, 87
Eltzo, M (1940) *Med Klin* 36, 1125
Freund, E (1942) *Edin Med J* 49, 91
Freyberg, R H (1947) Discussion Amer Rheum Ass, quoted in *Ann Rheum Dis*, London, 6, 95
Güntz, E (1933) *Fortschr a d Geb d Röntgenstrahlen*, 47, 683
Ködderman, O (1939) *Munch med Wochenschr* 86, 731
Krebs, W., and Vontz, O (1934) *Deutsch med Wochenschr* 60, 100
La Chapelle, E H (1946) *J Bone Joint Surg* 28, 851
Maclagan, N F (1946) *Brit J Exp Path* 27, 360
Maclagan, N F, and Bunn, D (1947) *Biochem J* 41, 580
McWhirter, R (1945) *Brit J Radiol* 18, 302
Rawls, W. B, Weiss, S, and Collins, V L (1937) *Ann Int Med* 10, 1021
Robinson, G L (1942–3) *Ann Rheum Dis* 3, 207
Scott, G (1939) *Wide Field X-ray Treatment*, London
Smith Petersen, M N, Larson, C B, and Aufrane, D E (1945) *J Bone and Joint Surg* 27, 1
Steinbrocker, O (1942) *Arthritis in Modern Practice*, Philadelphia
Swain, L T, and Kuhns, J G (1932) *Arch Phys Therap* 13, 517
Windeyer, B W (1948) Personal communication
Wyatt, H (1945) *Brit J Radiol* 18, 301

Fig 4

Spondylitis ankylopoietica after irradiation treatment Although the patient can touch his toes, spinal movement is seen to be almost absent



Fig 3

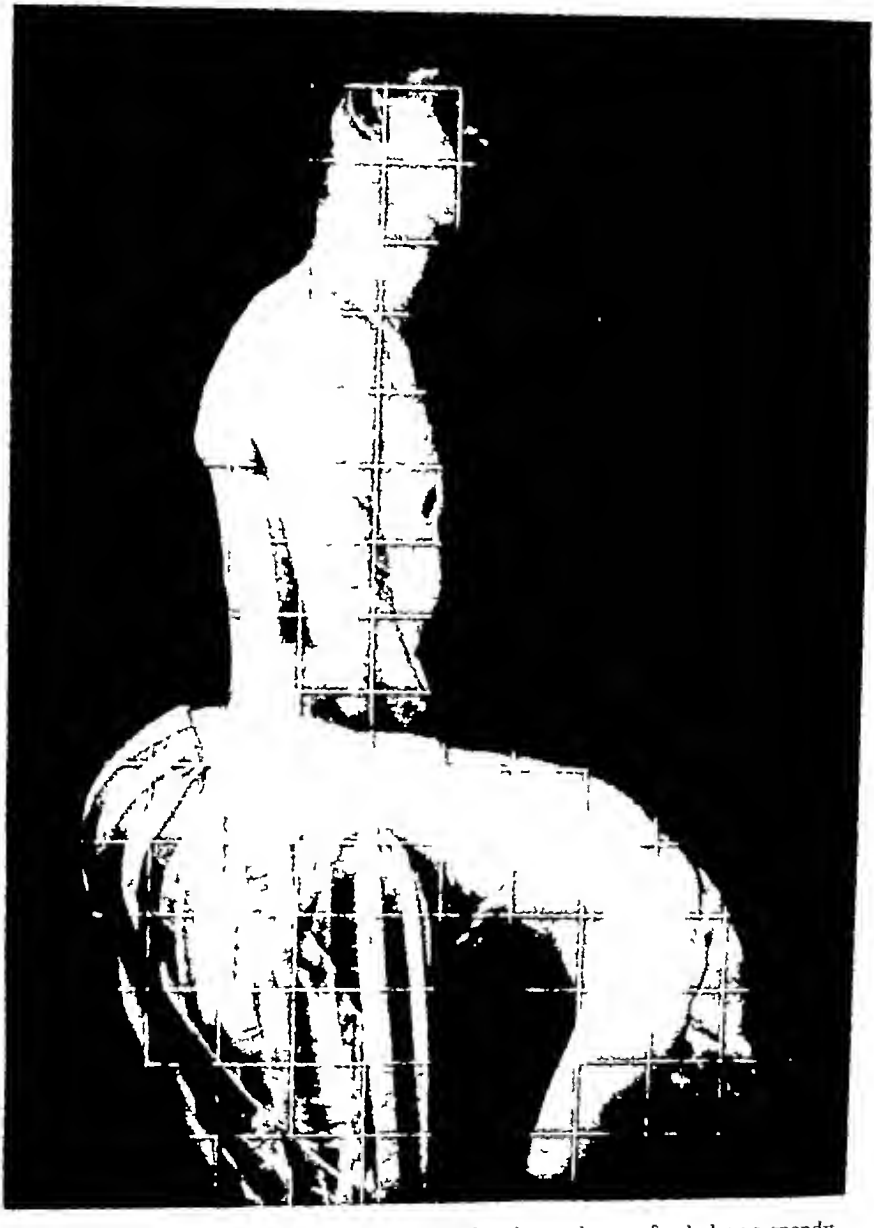

FIG 5 Full flexion demonstrated in a moderately advanced case of ankylosing spondylitis Although the toes can be touched, spinal movement is very slight

FIG 6 Normal ischial tuberosities The sacro iliac joints show typical erosive changes of ankylosing spondylitis with para arthrodial iliac sclerosis

FIG 7 Showing changes in the ischial tuberosity on the right side This is the same case as Fig 6, one year later

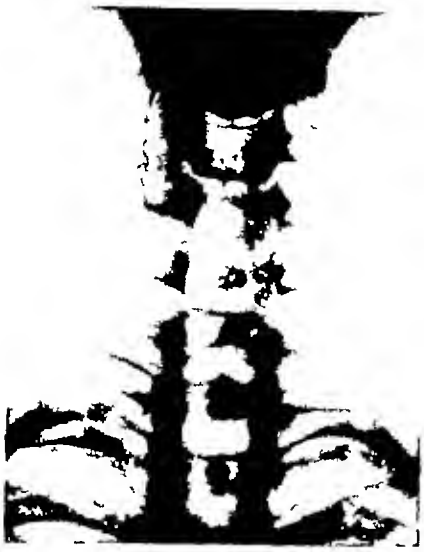

FIG 8 Normal articulations of the first rib

FIG 9 An advanced case of ankylosing spondylitis, showing double fusion of the first rib with the transverse process of D 1 and body of the vertebra

FIG 10 Ankylosing spondylitis in the final stage There is complete fusion of the sacro iliac joints, with advanced changes in the hips and symphysis pubis Iliac osteosclerosis has disappeared

612 015 346 612 323

CARBOHYDRATE METABOLISM AND GASTRIC SECRETORY ACTIVITY[1]

By ANDREW MUIR

(From the Western Infirmary, Glasgow, and Gardiner Institute of Medicine, University of Glasgow)

It has been known for many years that a close relationship exists between the metabolism of carbohydrate and the secretory activity of the stomach In 1900 Leconte showed that in dogs the introduction of 25 per cent glucose solution intraduodenally greatly inhibited gastric secretion, and in 1920 this work was confirmed in man (Miller, Bergeim, Rehfuss, and Hawk) Since then further work has brought to light other interesting associations between the metabolism of sugar and the secretory activity of the stomach This work has been done almost exclusively in America, France, and Germany, and seems to have attracted little attention in Britain The observations fall into three groups

1 *The effect of insulin on gastric activity*

Since the original observations of La Barre (1931 *a*, *b*, *c*, *d*), Kalk and Meyer (1932), and Okada, Kuramochi, Tsukahara, and Oomaue (1929, 1930), we know that insulin is a powerful stimulant to both gastric secretion and motility Approximately three-quarters of an hour after the intravenous injection of 12 to 20 units of soluble insulin in man an augmented secretion of gastric juice occurs, and the motility of the stomach is greatly increased This secretion has a total volume of 100 to 200 c c , a high free acidity, total acidity, and total chloride, and in every way resembles the gastric secretion induced by vagal stimulation (Welin and Frisk, 1936) There is now little doubt that the principal action of insulin in this mechanism is one of vagal stimulation In 1929 Quigley, Johnson, and Solomon demonstrated that insulin had its maximal effect on the pyloric portion of the human stomach Since electrical stimulation of the vagus nerves has a similar action, it was suggested that insulin exerted its principal gastric effect through these nerves Quigley and Templeton (1930 *a*, *b*) showed that the gastric response to the injection of insulin in dogs was completely inhibited by previous division of the vagi in the neck, and was augmented by removal of the splanchnic nerves They concluded that the action of insulin on the stomach was by way of central stimulation of the dorsal nucleus of the vagus, electrical stimulation of which is known to produce strong gastric activity (Laughton, 1929) This was confirmed in 1931 by La Barre and Cespédès A dog was prepared with a gastric fistula, and all structures between its head and

[1] Received October 4, 1948

body except the vagus nerves were removed It was kept alive from a second dog by the cross-circulation method of Heymans and Heymans (1925) When insulin was administered to the latter dog a copious highly acid secretion occurred in the stomach of the former From these observations and from the fact that atropine antagonizes the insulin gastric reaction while pilocarpine and histamine augment it, the original suggestion of Quigley, Johnson, and Solomon (1929) is now generally accepted There is, however, still not complete agreement whether insulin acts as a vagal stimulant directly, or indirectly as a result of the production of hypoglycaemia Recent work tends to confirm the latter hypothesis (Roholm, 1930) In 1930, Meyer showed that insulin is effective in enhancing gastric secretion in diabetics with high blood-sugar levels only when these have been reduced to normal levels by previous therapeutic doses of insulin Furthermore, it has been shown that administration of glucose simultaneously with the insulin prevents its gastric effect, particularly when the glucose is given orally or intraduodenally On the other hand, some observers have claimed that the insulin gastric reaction is not dependent on the blood sugar level Lapp and Dibold (1931), for example, showed that insulin could augment gastric secretion in some patients without lowering the blood-sugar level, and Beldyreff and Stewart (1932) were unable to confirm the increased gastric secretion in hypoglycaemia These differences led to the suggestion by Debreff (1931) and others that the action of insulin was biphasic, an early transient inhibitory phase and a later and more powerful stimulant one In spite of these differences, the general opinion seems to be that the action of insulin on the stomach is determined by the hypoglycaemia In support of this is the significant fact that insulin has no gastric action until the blood-sugar falls below normal levels Quantitatively the enhanced secretion roughly parallels the degree of hypoglycaemia and the increase becomes apparent only with the onset of hypoglycaemic symptoms

2 *The action of glucose on gastric acidity*

In the same year as Leconte's original observations, Aldor (1900) reported diminished acidity in standard test meals in man on the addition of 60 gm of glucose to the test feeds In 1901 Clemm found diminished secretion in the Pavlov pouch of dogs when 20 per cent glucose was added to the milk on which they were fed All further work has shown conclusively that glucose is a powerful inhibitor of gastric secretion and motility Its maximal action is obtained when it is given intraduodenally in strong solution It has a much weaker effect when given orally or intravenously In 1932 Matsuyama, working on dogs with gastric and duodenal fistulae, showed that the introduction of strong glucose solutions into the duodenum inhibited the expected gastric secretion in response to milk feeds He also showed that it was only the first or vagal phase of gastric secretion which was reduced, and concluded that glucose inhibited gastric secretion by way of the vagus nerves In 1939 Day and Komarov studied in dogs the effects of glucose on the gastric acidity induced by central and peripheral stimulation of the vagi Central stimulation was accomplished by sham-feeding the

animals and it was found that the secretion induced by this procedure was powerfully inhibited by glucose. Peripheral stimulation was produced by electrical stimulation of the nerves in the neck, and the gastric secretion obtained was shown to be inhibited to a much lesser extent by the administration of glucose It was therefore concluded that the inhibitory action of glucose on gastric secretion was produced by central inhibition of the vagi, a view now generally accepted They also confirmed the observation that glucose had its maximal gastric action when given orally or intraduodenally in strong solution (30 to 40 per cent), and pointed out that glucose did reduce, but only slightly, gastric secretion induced by peripheral stimulation of the vagi and also by the injection of histamine, and therefore did not act exclusively by central vagal inhibition They explained this anomaly by referring to the observations of Gilman and Cowgill (1931), who had shown that administration of crystalloids in sufficient quantity to raise the osmotic tension of the blood reduced the secretion of gastric juice, and Day and Komarov suggested that this crystalloid property of glucose explained the slight inhibitory action on gastric secretion induced by purely peripheral mechanisms Further support for this view was given by the work of Noble and Robertson (1938) who showed that intravenous sodium chloride solution was just as effective as similar quantities of osmotically equivalent glucose solution in reducing the gastric secretion in cats

Shay, Gershon-Cohen, and Fels (1939) and Shay, Gershon-Cohen, Fels, and Siplet (1942) did much to clear up disputed points on this problem They were mainly interested in the reason for the profound inhibition of gastric secretion in man produced by the administration of strong intraduodenal glucose solutions, and showed that this effect was not a unique property of glucose Intraduodenal soap solutions, fats, hydrochloric acid, and other materials had a similar action Experiments with various strengths of glucose solution demonstrated that they reduced gastric secretion only when hypertonic and therefore irritant to the duodenal mucosa By using insulin to control the height of the blood-sugar levels during the experiment they showed that these had little relationship to the degree of inhibition of gastric secretion obtained, and concluded that strong intraduodenal glucose solution owed its main depressant action on gastric secretion to its irritant effect on the duodenal mucosa When they repeated their experiments, using intravenous in place of intraduodenal glucose, they found that gastric secretion was slightly inhibited when hyperglycaemic blood-sugar levels were obtained, in spite of using only 10 per cent solution given at a relatively slow rate to minimize alteration of the osmotic tension of the blood Before the blood reached hyperglycaemic levels, gastric secretion appeared to be slightly stimulated, a fact previously noted by Friedman (1939) From this work it is apparent that sugar has three actions on gastric secretion

(1) When given intraduodenally in hypertonic solution it is a profound depressant, in common with other irritant materials, including hydrochloric acid This action is reflex in nature, acting by central inhibition of the vagus nerves

(ii) When given in strong solutions intravenously it acts as an inhibitor, as the result of alteration of the osmotic tension of the blood

(iii) When given by any route in sufficient quantity to raise the blood-sugar it has a slight inhibitory action, the nature of which is still undetermined.

3 *The hypoglycaemic effect of the administration of intraduodenal hydrochloric acid*

In 1926 Freud and Nazim found a rapid fall in blood-sugar levels in dogs after intraduodenal administration of 100 c c of 5 per cent hydrochloric acid This observation has since been confirmed (Zunz and La Barre, 1930) and was demonstrated in human subjects by Coelho and Olivero (1928) La Barre and Haussa (1932) showed that it occurred in depancreatized animals and therefore was not due to the simple liberation of insulin The accepted explanation is that hydrochloric acid liberates ferments from the duodenal and jejunal walls which have a similar action to insulin These ferments are known to exist and can be isolated from extracts of bowel wall It is doubtful if this observation has any practical application, but it is suggested that the high fasting gastric acidity in patients with duodenal ulcer is in part due to the hypoglycaemia produced by the passage of hydrochloric acid into the duodenum

This general survey of past work leads to some important practical suggestions In the first place, if it is true that the presence of hyperglycaemia depresses gastric activity, we might expect to find a high incidence of hypochlorhydria in diabetics As far back as 1926, Bowen and Aaron drew attention to this fact, and in 69 diabetics they found complete achlorhydria in 20 and hypochlorhydria in others These observations have been confirmed by McPherson (1927), and as a natural corollary the very low incidence of peptic ulcer in diabetics has been noted Thus Dibold (1933) was able to find only seven peptic ulcers in 800 diabetics, Landé (1931) 10 peptic ulcers in 2,000 diabetics, and Rothenberg and Teicher (1938) found an incidence of ulcer of 1 49 per cent in 130,500 general admissions, while in 3,525 diabetic admissions only 0 25 per cent suffered from ulcer Finally, Portis and Jaffé (1938), in discussing the post-mortem findings in 339 peptic ulcers, mentioned that only one of the patients had diabetes There is therefore ample evidence that diabetic patients have less tendency to peptic ulceration than normal subjects McPherson (1927) suggested that this is the result of long-standing severe hyperglycaemia, as the longer and more severe the diabetes the greater is the incidence of hypochlorhydria Again, since hypoglycaemia is now accepted as a powerful stimulant to gastric secretion and motility we may expect to find corresponding changes in the stomach of a person liable to spontaneous hypoglycaemia Lyon and Kleinhaus (1945) described three cases of posthepatitic hypoglycaemia with dyspeptic symptoms In each, gastric hypersecretion, hypermotility, and increase in the size of the mucosal folds developed, and gradually subsided with the disappearance of the hypoglycaemic state None of these patients developed peptic ulcer, although gastric secretion and motility were excessive at night Since sugar is a powerful depressant of gastric acidity and since the control of the latter may be the most impor-

tant single factor in the treatment of peptic ulcer, it has been suggested that intractible cases of ulcer might benefit from the administration of glucose, particularly intraduodenal hypertonic glucose (Glaessner, 1943) Recht (1931), Strauss (1932), and others have treated patients with peptic ulcer with sugar and have claimed good results Finally, it has been claimed (Glaessner, 1943) that the pain in some cases of duodenal ulcer may be induced by hypoglycaemia It has been pointed out that the pain of duodenal ulcer is rapidly relieved by small meals, that it comes on at times when hypoglycaemia is most likely, that it is sometimes associated with weakness, dizziness, sweating, hunger, and other hypoglycaemic manifestations, and that the duodenal ulcer patient is more liable to hypoglycaemia than normal subjects

Personal Observations

The present paper records the results of personal observations on the following questions

1 The action of glucose on the gastric acidity of patients with duodenal ulcer
2 The action of insulin on the gastric acidity of patients with duodenal ulcer.
3 The importance of hypoglycaemia as a factor in the production of pain in duodenal ulcer
4 The effect of glucose on the pain of duodenal ulcer.

1 *The action of glucose on the gastric acidity of patients with duodenal ulcer*

Six patients with typical symptoms and signs of duodenal ulcer and six healthy control subjects were selected A standard fractional test meal was performed in each of three consecutive weeks to eliminate any case showing big fluctuations in free acidity The effect of oral glucose on the free acidity was noted by adding 60 gm of glucose to the gruel and repeating the test The effect of intravenous glucose was observed by starting an intravenous drip of 10 per cent glucose solution quarter of an hour before repeating the standard test meal The glucose was given at the rate of 60 drops per minute and continued throughout the test until the stomach was empty Finally, the effect of intraduodenal glucose was assessed by repeating the test while 30 per cent glucose solution was introduced at the rate of 40 drops per minute into the duodenum To do this a duodenal tube was passed in the fasting subject by the usual method A stomach tube was then passed, the fasting juice withdrawn, the gruel administered, and specimens of gastric juice taken at quarter-hour intervals until the stomach was empty The intraduodenal glucose drip was started at the time of the gruel administration In all cases where glucose was given, blood was taken for blood-sugar estimation each time a specimen of gastric contents was removed. Fig 1 shows the typical average response in a patient with duodenal ulcer and Fig 2 the response in a normal subject The complete results are shown in Tables I and II respectively

The important points which emerge are as follows The administration of oral glucose prolonged gastric emptying time and depressed gastric acidity in both series of patients The former was the more constant and occurred in every

Table I

The Effects of the Administration of Glucose by Various Routes on the Free Gastric Acidity of Six Duodenal Ulcer Patients

A, B, C = Standard fractional test meals at weekly intervals (c c of N/10 NaOH)
D = Repeat of test meal with 60 gm of glucose added to the gruel
E = Repeat of test meal with 10 per cent Intravenous glucose at 60 drops per min started a quarter of an hour before the test
F = Repeat of test meal with 30 per cent glucose intraduodenally at 40 drops per min.
B S (D) = Blood sugar levels (mg per 100 c c) taken at the time of withdrawal of each gastric specimen
B.S (E)
B.S (F) during test meals D, E, and F respectively

No		Fasting	¼	½	¾	1	1¼	1½	1¾	2	2¼	2½	2¾	3	3¼	3½ hrs	Gastric residue (c.c.)
1	A	54	18	26	51	68	74	82	88								
	B	32	26	36	58	98	78	80	74								
	C	90	14	44	04	70	74	80	71	86							
	D	50	26	30	38	42	56	42	36	40	48	20					
	B.S (D)	01	117	131	152	167	108	184	191	113	08	94					
	E	42	38	48	56	42	42	28	20	36	28						
	B.S (E)	106	126	104	181	214	203	221	184	179	131						
	F	42	2	9	24	7	0	0	3	0	12	8	6	0	1	14	68
	B.S (F)	01	133	133	198	168	192	174	168	153	141	126	114	08	112	119	
2	A	51	17	43	64	82	68	55	40								
	B	47	12	36	73	81	72	68	52								
	C	45	8	44	61	80	74	53	44	41							
	D	47	14	38	58	71	61	34	32	21	26						
	B.S (D)	94	114	137	152	168	141	137	125	111	103						
	E	52	24	84	78	61	36	27	16	25	8						
	B.S (F)	121	138	171	224	210	191	184	168	167	147						
	F	44	11	33	36	14	10	0	0	0	0	0	6	4	7	0	21
	B.S (F)	08	124	161	214	186	171	174	178	141	126	117	123	131	109	132	
3	A	81	9	42	58	88	90	51									
	B	76	14	48	51	72	86	42	41								
	C	75	26	55	03	84	06	32									
	D	52	12	33	41	50	30	28	42	16	23	11					
	B.S (D)	104	147	155	172	176	174	141	128	117	123	110					
	E	70	23	46	81	46	43	28	28								
	B.S (E)	124	137	149	104	241	232	195	216								
	F	01	12	0	7	3	0	9	11	0	9	0	14	21	2	4	47
	B.S (F)	98	123	141	101	182	234	185	181	171	152	147	131	126	134	139	
4	A	55	13	28	38	45	68	84	89								
	B	48	21	35	42	51	99	78									
	C	50	14	25	26	38	81	04	85								
	D	45	9	23	31	38	44	52	29	11	17	23					
	B.S (D)	74	112	125	143	169	157	152	131	194	94	104					
	E	06	12	24	41	97	97	32	14	23	11						
	B.S (E)	05	123	145	101	214	219	103	178	187	173						
	F	58	9	0	0	0	7	4	12	6	0	17	11	19	0	9	17
	B.S (F)	78	05	138	102	237	228	201	199	188	128	146	121	131	114	134	
5	A	25	14	36	42	96	51	08	42								
	B	29	11	41	52	03	42	51	71								
	C	47	28	34	34	49	59	74	31	49							
	D	34	11	34	41	59	01	56	43	43	37	35	21	12			
	B S (D)	103	131	246	191	171	143	136	135	121	129	114	118	122			
	E	36	28	42	50	78	53	58	39	42							
	B.S (E)	114	138	141	156	178	165	167	174	191							
	F	29	4	19	12	6	2	8	14	3	9	12	14	9			
	B.S (F)	06	134	142	183	175	186	192	184	175	182	164	158	158			
6	A	74	16	26	42	59	78	86									
	B	63	13	35	61	78	64										
	C	71	10	42	59	71	85	88									
	D	59	23	31	44	39	45	52	48	44							
	B.S (D)	81	149	234	185	172	169	152	141	105							
	E	79	15	38	59	75	78	79	74								
	B.S (E)	117	129	144	198	224	187	183	186								
	F	58	7	14	3	9	9	9	16	4	9	12	21	14	3	2	14
	B.S (F)	86	98	137	152	103	228	223	185	178	188	200	164	147	159	116	

Table II

The Effects of the Administration of Glucose by Various Routes on the Free Gastric Acidity of Six Normal Subjects

A, B, C = Standard fractional test meals at weekly intervals (c c. of N/10 NaOH)
D = Repeat of test meal with 60 gm of glucose added to the gruel.
E = Repeat of test meal with 10 per cent intravenous glucose at 60 drops per min. started a quarter of an hour before test
F = Repeat of test meal with 30 per cent glucose intraduodenally at 40 drops per min.
B S (D) = Blood sugar levels (mg per 100 c c) taken at the time of withdrawal of each gastric specimen
B S (E) during test meals D, E, and F respectively
B S (F)

No		Fasting	¼	½	¾	1	1¼	1½	1¾	2	2¼	2½	2¾	3	3¼	3½ hrs	Gastric residue (c c)
1	A	21	4	16	36	50	43	40	36	26	18						.
	B	39	8	23	32	44	46	37	46	14							
	C	11	14	18	22	54	48	44	30	26	10						.
	D	32	7	16	25	40	18	12	26	13	4	13	6				..
	B.S (D)	74	112	131	145	159	167	153	144	109	96	103	85				
	E	34	6	26	47	59	55	22	10	6	4	6					
	B S (E)	109	127	145	167	198	183	204	161	199	161	148					
	F	41	0	0	0	0	6	18	14	3	0	0	0	0	0	0	4
	B S (F)	61	96	142	175	203	228	195	214	168	174	162	159	145	104	126	
2	A	12	2	12	24	32	20	16	10	6	6	4					
	B	17	6	12	28	36	18	18	14	10	8						
	C	45	2	18	23	34	28	32	16	8	8						
	D	24	0	11	16	28	10	14	12	6	6	7					
	B.S (D)	85	111	128	136	141	134	128	119	114	97	91					
	E	21	0	28	28	37	23	21	17	10	8	6					
	B.S (E)	98	104	143	168	191	183	174	201	172	161	118					
	F	8	0	14	16	8	0	12	0	0	0	14	8	6	7	0	36
	B S (F)	76	91	123	145	187	226	265	194	207	191	176	163	141	117	103	
3	A	26	3	16	32	48	40	32	30	26	20	10					.
	B	29	8	24	36	54	51	46	40	24	24	17				.	
	C	18	10	18	41	47	48	56	44	41	26						
	D	10	12	17	33	46	59	59	51	48	31	8	12	14			
	B.S (D)	80	95	113	152	185	164	151	137	126	111	102	99	106			
	E	33	16	26	40	58	43	31	36	32	20	14	12	6			
	B S (E)	121	146	168	166	171	152	147	155	132	138	129	142	131			
	F	20	4	0	0	0	0	0	0	0	0	0	0	0	0	0	74
	B S (F)	86	124	147	171	144	152	176	165	151	143	139	121	108	99	104	
4	A	16	2	26	36	46	48	26	24	18	16						
	B	18	6	32	46	42	42	23	12	17	21						
	C	26	8	26	36	42	46	23	18	18	12	14					
	D	4	12	16	19	23	26	11	6	0	7	6	6	2	11	10	14
	B S (D)	101	126	136	147	161	147	138	122	109	93	104	97	104	96	107	
	E	20	15	46	60	22	11	13	17	8	6	11					
	B S (E)	131	149	161	175	237	221	101	165	144	152	137					
	F	33	0	0	0	0	0	6	12	0	0	0	0	0	0	0	48
	B.S (F)	97	125	135	176	196	142	165	191	161	155	142	117	101	94	111	
5	A	26	11	16	23	31	46	60	46	26	26	14	22				
	B	29	3	26	23	36	51	56	42	20	16	16					
	C	18	10	23	41	46	56	42	41	26	21	20					
	D	31	6	17	17	22	34	21	16	8	4	3	0	12			
	B S (D)	75	104	123	145	166	154	131	122	61	78	61	86	90			
	E	24	16	38	42	46	46	51	39	36	27	20	26				
	B.S (E)	117	136	161	176	162	156	174	162	170	145	141	137				
	F	14	17	12	0	0	6	6	14	16	12	7	7	4	0	3	26
	B S (F)	63	134	161	172	185	174	166	171	161	151	143	117	91	86	104	
6	A	7	0	11	14	16	26	26	14	10	8						
	B	10	0	13	16	28	26	16	10	6	4	4					
	C	17	0	16	26	32	31	16	12	6	10						
	D	15	0	6	16	19	16	5	5	3	17	6	0	4			
	B S (D)	03	114	140	152	161	161	132	103	111	101	95	78	106			
	E	14	0	26	34	23	23	21	16	14	12	17	4				
	B S (E)	123	137	146	156	174	174	163	171	163	142	125	116				
	F	14	0	0	0	0	0	0	0	0	0	0	0	0	0	0	15
	B.S (F)	104	146	169	183	174	167	159	176	185	143	132	117	121	119	131	

patient The average time of emptying was extended by half an hour, and in one normal subject (Case 4) the stomach still contained gruel one hour after its normal time of emptying The depression of gastric acidity was moderate in five patients of each group In the remaining ulcer patient (Case 5) the acidity

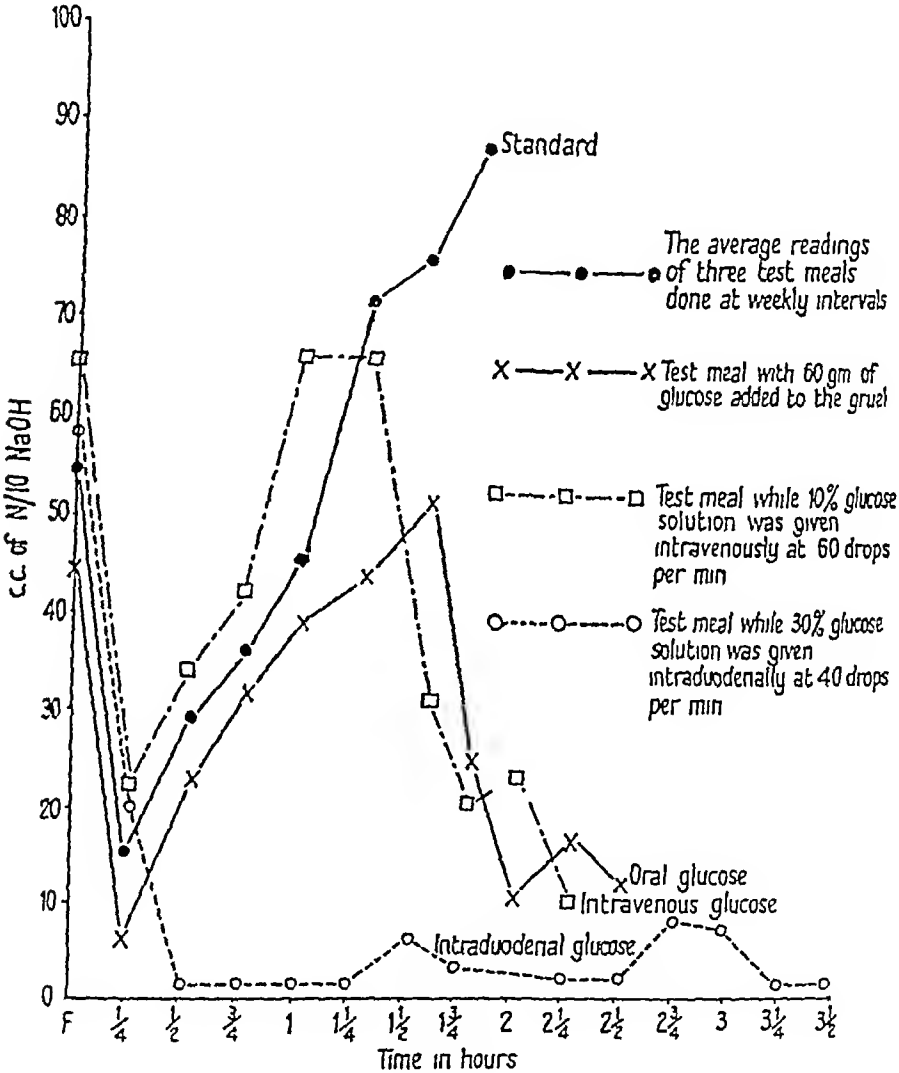

FIG 1

was not reduced and in the other normal control (Case 3) it was actually stimulated It is also clear from the figures that the acid depression was maximal during the second half of the test meal and did not depend to any extent on the height of the blood-sugar This suggests that the action of oral glucose given in this manner is dependant on its passage into the duodenum in hypertonic solution The concentration of glucose in the above experiments was approximately 15 per cent, sufficiently hypertonic to irritate the duodenal mucosa

Intravenous 10 per cent glucose had a variable effect Its most constant action was stimulation of the gastric acidity while the blood-sugar was rising. This occurred constantly and agrees with the observation of Friedman (1939). The subsequent behaviour of the free acid depended on the height to which the

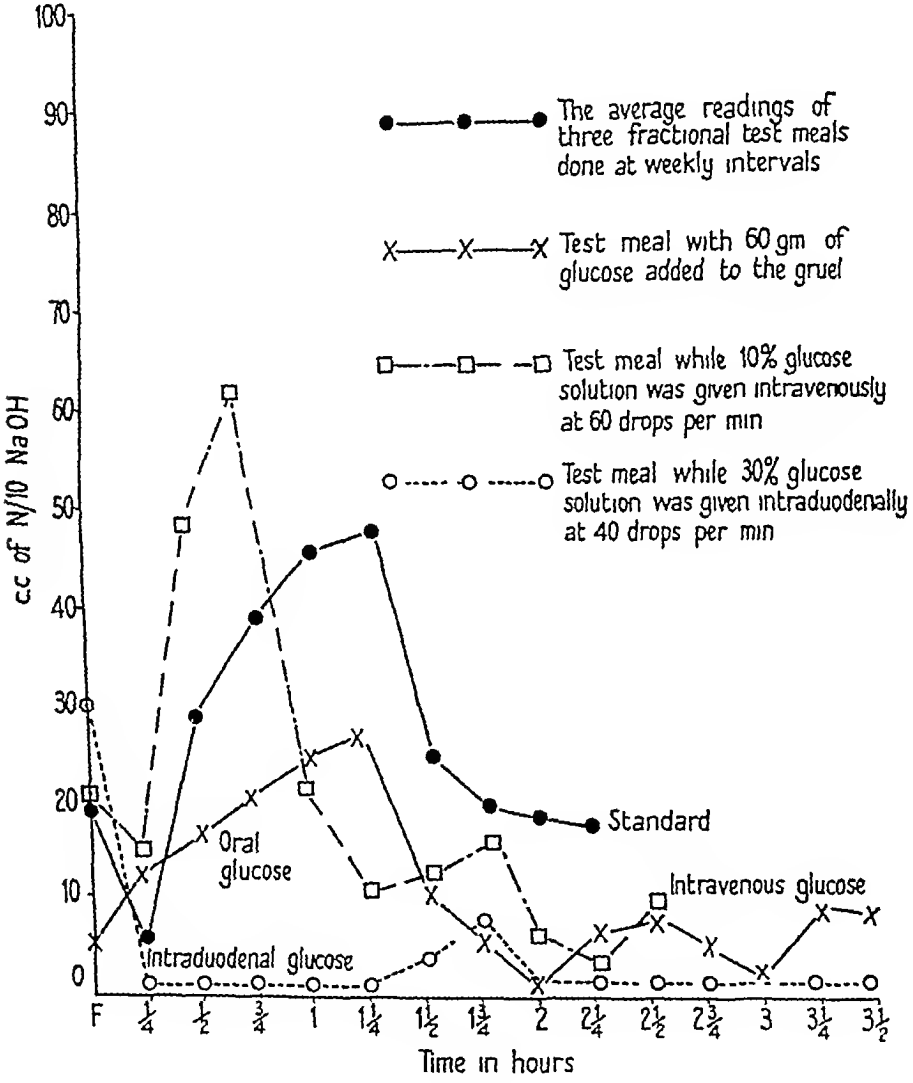

Fig 2

blood-sugar rose When this remained at reasonable limits of 200 mg per 100 c c and below, there was no inhibitory action When, however, it reached levels in the region of 220 to 240 mg per 100 c c a rapid fall in gastric acidity was noted It is probable therefore that hyperglycaemia *per se* can cause inhibition of gastric acidity Whether this is purely a question of alteration in the osmotic tension of the blood is difficult to assess

Intraduodenal hypertonic glucose had a constant and powerful inhibitory effect in both groups In two normal subjects (Cases 3 and 6) complete anacidity was produced after the first half hour In the remaining four, small quantities of free acid were intermittently produced throughout the test In the ulcer group complete anacidity was not seen, but very marked hypochlorhydria was produced In all cases the emptying time of the stomach was greatly prolonged and in all but one (Case 5, in the ulcer series) gruel was withdrawn from the stomach after three and a half hours

2 *The action of insulin on the gastric acidity of patients with duodenal ulcer*

Preliminary experiments, not included here, on the effect of insulin on the gastric acidity showed that a single hypoglycaemic attack induced during a test meal had a variable effect It was therefore decided to induce a prolonged attack by using larger doses of insulin during the test meal and repeating them when necessary Four normal subjects and four patients with duodenal ulcer were therefore selected and a standard fractional test meal performed on each On a subsequent occasion insulin was given intravenously by means of a tuberculin syringe 15 minutes before repeating the test and again one hour after its start In this way it was found possible to maintain a prolonged hypoglycaemic state throughout the greater part of the test When symptoms became severe they were relieved by 40 per cent glucose given intravenously, and an attempt was made to give just sufficient glucose to relieve the more distressing symptoms without abolishing the hypoglycaemic state entirely This was difficult and in many cases impossible, and the attempt usually simplified itself into the giving of small repeated doses of glucose rather than a single large dose The total dosage of insulin employed averaged 20 to 30 units, given in two parts at the times stated In two patients, 54 and 48 units were given before hypoglycaemic symptoms became evident The hypoglycaemic symptoms which developed were those commonly associated with this condition Sweating, lassitude, and pallor were usually the earliest, and subsequently tachycardia, headache, progressive drowsiness, dilated pupils, tremor, and in some cases dysarthria and apprehension, gradually developed The patient was encouraged to withstand the milder symptoms as long as possible and in three patients in whom drowsiness was a prominent symptom it was found possible to complete the entire test without giving glucose The symptoms always developed within half an hour of the start of the meal and in two patients, not included in this series, the test had to be abandoned, because both required large doses of glucose intravenously and subsequently orally to control the symptoms No patient over the age of 40 years was included, owing to the known risks associated with hypoglycaemia in coronary artery disease

Figs 3 and 4 show the average response to this experimental procedure in a patient with duodenal ulcer and a normal subject respectively Tables III and IV summarize the complete results It is evident that insulin has a powerful stimulant effect on the free gastric acidity of both groups, and greatly shortens the time of emptying of the stomach In the four patients with duodenal ulcer

the effect was dramatic Commencing within 20 minutes, at the period of earliest hypoglycaemia, intense secretion of free acid was observed The average increment in acidity in the half-hour specimen was twice its original level, as judged by the previous standard test meal Subsequent differences were not so

The Effect of Insulin on the Gastric Acidity of Four Duodenal Ulcer and Four Normal Patients

A = Standard fractional test meal (c c of N/10 NaOH)
B = Repeat of fractional test meal with insulin given intravenously 15 min. before its start and again one and a quarter hours later
B.S (B) = Blood sugar levels (mg per 100 c.c) during test meal B at times of withdrawal of each gastric specimen

TABLE III *Duodenal Ulcer Patients*

No		−¼	Fasting	¼	½	¾	1	1¼	1½	1¾	2	2¼	2½ hrs	Amount of insulin and amount of 40 per cent glucose intravenously
1	A		76	12	43	56	67	71	48	32				10 units
	B		39	21	79	86	91	98						10 units
	B S (B)	126	94	60	50	45	39	35						No glucose given
2	A		41	17	28	45	63	74	82	63				16 units
	B		62	21	86	79	98	96						14 units
	B S (B)	78	68	55	34	84	62	34						10 c.c at 36 min. 10 c c at 47 min.
3	A		72	12	36	60	78	61						22 units
	B		60	33	71	94	88							No second dose
	B.S (B)	81	57	38	101	51	46							10 c.c at 17 min 5 c c at 25 min.
4	A		48	6	14	28	52	66	73	41	16			18 units
	B		55	0	68	91	100	112						14 units
	B S (B)	118	70	59	52	34	94	62						20 c c at 46 min

TABLE IV *Normal Cases*

No		−¼	Fasting	¼	½	¾	1	1¼	1½	1¾	2	2¼	2½ hrs	Amount of insulin and amount of 40 per cent glucose intravenously
1	A		12	0	14	22	31	46	34	28	14	8	22	28 units
	B		27	8	18	34	61	68	51	52				26 units
	B S (B)	92	61	55	96	58	37	74	46	54				10 c c at 24 min. 10 c.c at 61 min. 5 c.c at 94 min.
2	A		18	10	16	24	36	28	13	8	21	24	7	24 units
	B		31	17	38	48	61	48	66					24 units
	B.S (B)	110	75	53	128	67	37	44	38					10 c c at 19 min 10 c c at 24 min. 5 c c at 61 min.
3	A		31	16	24	36	48	53	30	16	21	8		22 units
	B		10	18	39	51	49	67	61					15 units
	B S (B)	114	66	54	48	36	32	37	36					No glucose given
4	A		14	6	22	31	28	16	8	12	14	14		16 units
	B		28	11	36	58	61	64	41					10 units
	B.S (B)	95	82	66	48	40	38	38	32					No glucose given

great, but were nevertheless striking The emptying time did not exceed one and a quarter hours in any case and in two the stomach was empty in one hour In the control series the stimulant effect was again present, but not so marked as in the former group The main effect was seen to be the maintenance of peak acidity until the stomach was empty The emptying time of the stomach was again shortened by an average period of half an hour The number of cases

investigated is small, but the constancy of this exaggerated response to insulin in the patients with duodenal ulcer as compared with normal controls seems noteworthy

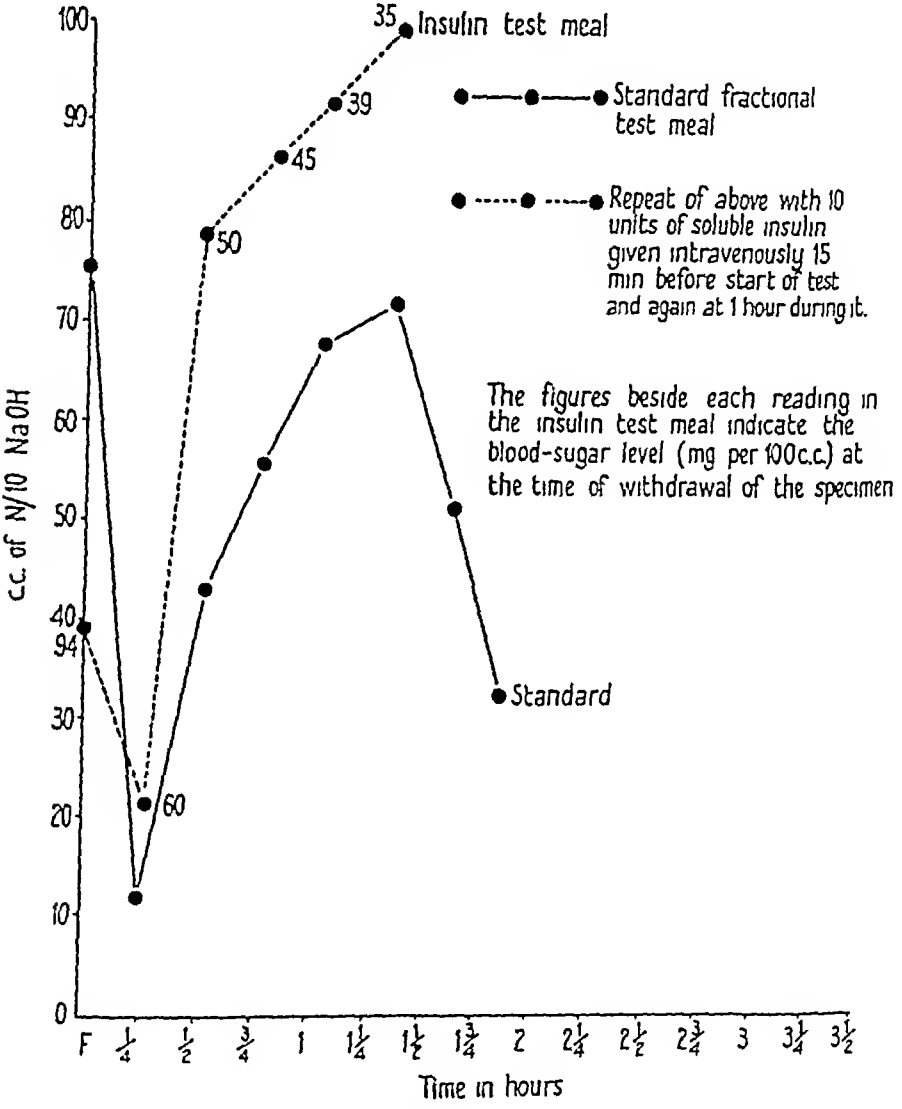

FIG 3

3 *The importance of hypoglycaemia as a factor in the production of pain in duodenal ulcer*

The term 'lag curve' was applied by Maclean (1926) to a peculiar response in the blood-sugar curve in man after the ingestion of 50 gm of glucose The blood-sugar rises rapidly to hyperglycaemic levels and transient glycosuria is often found This curve is differentiated from that of true diabetes by the equally rapid fall in the blood-sugar to normal or subnormal levels within a very

short time The original explanation of the 'lag curve' was that insulin production was delayed for some unknown reason, permitting an exaggerated rise in the blood-sugar Thereafter insulin was rapidly released, reducing the blood-

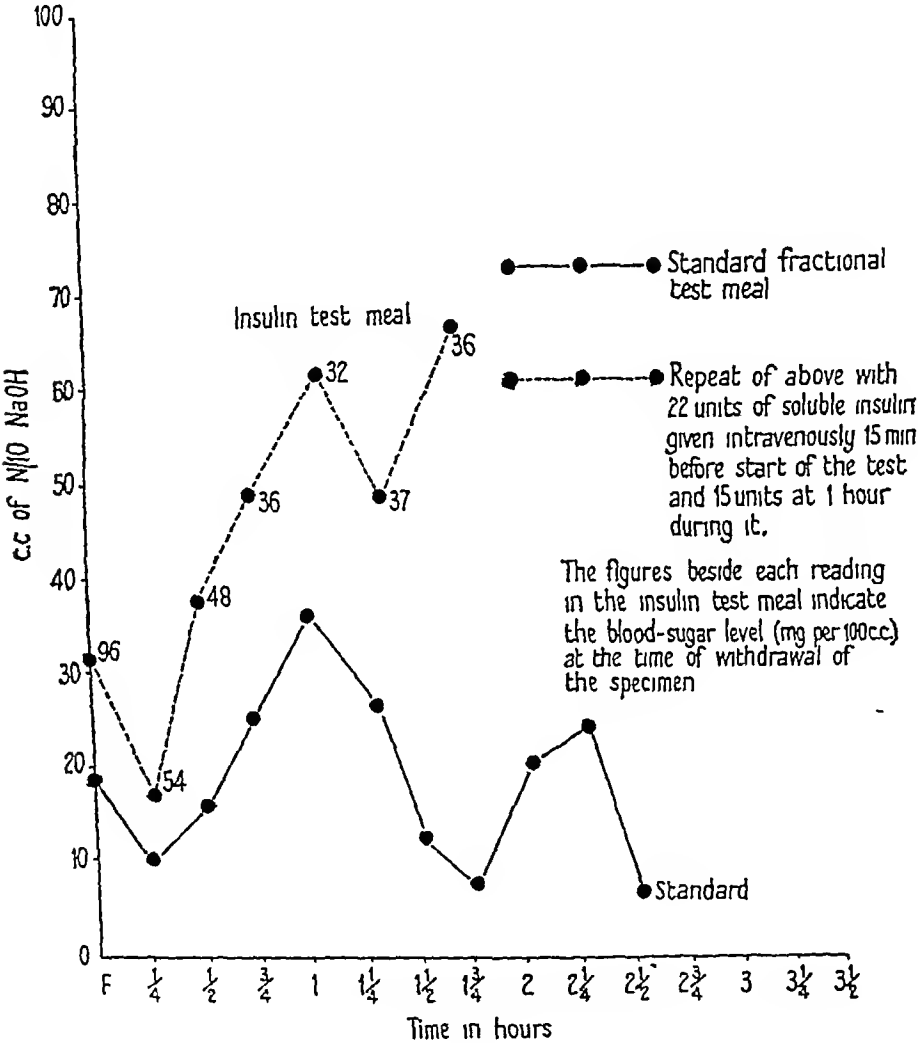

FIG 4

sugar quickly to normal or hypoglycaemic levels Within recent years this type of curve has been found in increasing frequency in patients with duodenal ulcer, after gastrojejunostomy, and particularly after subtotal gastrectomy (Evensen, 1942) Rapid emptying of the stomach is the common factor in these conditions, and it is now clear that this plays an important part The initial conception of a lag in the production of insulin in patients showing these curves has given place to the more likely hypothesis that early hyperglycaemia is due to very rapid absorption of glucose from the bowel In the present experiments it is not so much the hyperglycaemia which is of interest as the hypoglycaemia which

frequently follows The latter generally occurs within two hours of ingestion of glucose and is thought to be the result of the action of an excessive quantity of insulin secreted by the pancreas in response to the early hyperglycaemia produced during the test. It is often of sufficient degree to produce symptoms It was therefore decided to study the response of patients with duodenal ulcers to the ingestion of 50 gm of glucose Particular attention was directed towards the frequency of 'lag curves' in cases of uncomplicated duodenal ulcer and to the symptoms produced during any hypoglycaemic phase The test was performed on 80 male subjects between the ages of 16 and 67 years Each had a typical story of duodenal ulcer and the diagnosis was confirmed radiologically No case showing evidence of pyloric stenosis was included in the series The test was also performed on 80 male subjects of similar age with no history of duodenal ulcer Each patient had an unrestricted carbohydrate diet for several weeks previous to the test The blood-sugars were estimated by the method of Hagedorn and Jensen and capillary blood was used throughout In all patients showing glycosuria the test was repeated a few days later with blood-sugars estimated at quarter-hour instead of half-hour intervals

In the control series 76 subjects showed a normal response In subsequent discussion a normal response will be taken as one in which the fasting blood-sugar lies between 70 and 120 mg per 100 c c, the maximal level does not exceed 180 mg per 100 c c, and a subsequent fall to approximately fasting levels occurs within two hours, no glycosuria appearing throughout the test Of the remaining four patients, one proved to be a mild diabetic with a fasting blood-sugar of 126 mg per 100 c c and a maximal reading of 261 mg per 100 c c, falling to 153 mg per 100 c c at the end of two hours One man in whom anomalous results appeared was subsequently found to be suffering from thyrotoxicosis A third was a typical example of renal glycosuria with a renal threshold of 125 to 135 mg per 100 c c The remaining patient had a 'lag curve' response The fasting blood-sugar was 92 mg per 100 c c, the one-hour reading 226 mg per 100 c c, and the two-hour reading 86 mg per 100 c c Glycosuria was present during the first hour A subsequent test meal performed on this subject revealed a normal acidity with an emptying time of one and a half hours, and a barium meal confirmed the presence of a small hyperactive stomach In the 80 patients with duodenal ulcer, 66 showed relatively normal curves The fasting and minimal blood-sugars were on the average not lower than in the normal subjects The maximal rise was distinctly greater, however, as may be seen from Table V, in which curves not fully within our previous definition of normal are excluded Of the remaining 14 curves which were not classified as normal, one was a curve of a mild diabetic and the remaining 13 were typical 'lag curves' The actual readings are given in Table VI Confirmed hypoglycaemic symptoms developed in six patients (Cases 2, 4, 7, 10, 11, and 13) and were of mild degree All complained of a feeling of hunger and a sense of weakness, and Cases 7 and 13 developed excessive sweating

From these results it is seen that 'lag curve' is a relatively frequent finding in patients with duodenal ulcer, occurring in about 15 per cent of the present

series Distinct hypoglycaemic symptoms occurred in six of these patients, and in one other patient (Table VI, Case 8) the blood-sugar fell to 61 mg per 100 c c at one and a half hours without producing symptoms Patients with duodenal ulcer therefore appear to have a greater tendency to hypoglycaemia than normal subjects as judged by the above test This is directly due to rapid emptying of

TABLE V

Number of cases showing maximal blood-sugar rise between—	*Ulcer patients*	*Normal subjects*
130 to 140 mg per 100 c c	21	47
140 to 150 " "	27	24
150 to 160 " "	9	3
160 to 170 " "	4	1
170 to 180 " "	5	1

TABLE VI

Blood-sugar Readings (mg per 100 c c)

Time (in hours)	*Fasting*	¼	½	¾	1	1¼	1½	1¾	2	2¼	2½
1	96	137	188	233	194	142	124	98	101	104	94
2	102	148	226	173	121	68	117	114	100	92	94
3	91	151	176	241	214	191	136	112	87	98	90
4	72	136	181	214	173	140	64	91	85	78	80
5	84	134	161	196	175	161	142	104	91	97	91
6	103	131	250	286	204	161	140	126	118	114	108
7	78	184	274	193	146	63	94	76	78	84	73
8	84	134	174	216	216	163	61	97	89	96	83
9	96	142	181	243	191	170	136	114	116	112	104
10	100	196	193	124	109	71	66	99	104	106	98
11	77	104	162	189	203	134	86	72	78	74	81
12	102	128	161	211	198	131	117	96	114	113	107
13	91	139	174	217	224	152	123	63	104	98	102

the stomach causing an early hyperglycaemia and a subsequent reactive hypoglycaemia, in spite of the continued presence of food in the stomach and small bowel (Malmros, 1928) Staub (1927) has shown that physical work has a pronounced effect on the character of glucose tolerance curves in man The hypoglycaemic phase is exaggerated, since available glucose is utilized by the muscles, so that the tendency to hypoglycaemia in patients with duodenal ulcer would be more marked under ordinary working conditions With the above conclusions in mind it was decided to investigate the blood-sugar levels of patients with duodenal ulcer during an attack of ulcer pain Specimens of blood were taken at random from 87 patients with confirmed duodenal ulcer during an attack of pain Altogether 254 such observations were made and a record was kept of the severity, type, and duration of the pain in each, particular attention being directed to any accompanying hypoglycaemic symptoms and to the length of time which had elapsed since a meal had been eaten Not more than four investigations were made on any one patient The blood-sugar levels obtained are recorded in Table VII

It was found that the 87 patients could be divided according to the results of these investigations into three groups

Group A A group of 75 patients who had ulcer pain constantly associated with a blood-sugar level above 70 mg per 100 c c A total of 214 tests was made on these patients In this group symptoms of hypoglycaemic type, faintness, lassitude, sweating, tremor, and inability to concentrate, accompanied the ulcer pain in eight instances These symptoms were regarded clinically as hypo-

TABLE VII

Blood sugar (mg per 100 c c)	*Number of times encountered*
Over 200	3
180 to 199	1
170 ,, 179	2
160 ,, 169	11
150 ,, 159	7
140 ,, 149	14
130 ,, 139	20
120 ,, 129	27
110 ,, 119	21
100 ,, 109	21
90 ,, 99	43
80 ,, 89	26
70 ,, 79	22
65 ,, 69	6
60 ,, 64	24
55 ,, 59	4
50 ,, 54	2
Total	254

glycaemic in origin before the blood-sugar level was known In six of them the blood-sugar was subsequently found to be between 70 and 80 mg per 100 c c , and the remaining two readings were 81 and 85 mg per 100 c c It is well known that hypoglycaemic symptoms can occur with much higher blood-sugar levels, particularly if a previous rapid fall in that level has occurred It is possible therefore that the symptoms which accompanied the ulcer pain in these eight instances were hypoglycaemic, in spite of the relatively high blood-sugar levels

Group B A group of four patients who had ulcer pain constantly associated with blood-sugar levels below 70 mg per 100 c c In the 16 tests made on these patients, the highest blood-sugar reading obtained was 68 mg , and the lowest 53 mg per 100 c c In this group, symptoms regarded clinically as hypoglycaemic and subsequently confirmed accompanied the ulcer pain in every instance in which it was studied The very low blood-sugar reading of 53 mg per 100 c c mentioned above was seen twice in the same patient and on each occasion ulcer pain was accompanied by severe hypoglycaemic symptoms, dysarthria, tremor of the hands, profuse sweating, and inability to repeat the context of a short newspaper paragraph read to him during this period

Group C A group of eight patients who had ulcer pain associated with variable blood-sugar levels, occasionally below 70 mg per 100 c c , but more often above this level A total of 24 tests was made on these patients In this group hypoglycaemic symptoms accompanied the ulcer pain in eight instances Subsequent blood-sugar readings confirmed the presence of hypoglycaemia in seven, and in the other the reading was 74 mg per 100 c c

Further similar investigations made only on the 12 patients of Groups B and C, not included in the above, confirmed these findings, as may be seen from Table VIII One striking clinical fact emerged from the study of the type of ulcer pain experienced by these 87 patients with duodenal ulcer In the 75 patients of Group A who had pain constantly associated with blood-sugar levels

TABLE VIII

	Case No	Number of observations made	Blood-sugar levels (mg per 100 c c) during the ulcer pain
GROUP B	1	10	64, 66, 56, 58, 56, 58, 60, 60, 66, 64
	2	9	63, 68, 65, 59, 61, 68, 58, 67, 57
	3	8	52, 56, 56, 64, 63, 56, 59, 58
	4	8	58, 54, 61, 61, 60, 68, 50, 64
GROUP C	5	11	63, 142, 114, 136, 81, 75, 151, 52, 116, 141, 174
	6	10	61, 127, 114, 118, 139, 63, 112, 98, 141, 107
	7	8	128, 155, 71, 64, 58, 119, 92, 96
	8	8	61, 142, 79, 98, 112, 68, 134, 121
	9	10	117, 126, 143, 61, 58, 114, 122, 138, 96, 100
	10	10	114, 162, 148, 140, 112, 81, 64, 56, 82, 94
	11	9	65, 56, 123, 121, 59, 66, 132, 94, 100
	12	10	124, 117, 86, 87, 92, 104, 108, 82, 61

above 70 mg per 100 c c , the pain was identical with that classically described as occurring in patients with duodenal ulcer It came on at a time which varied from 40 minutes to three and a quarter hours after meals, the average interval being 70 minutes Untreated, its duration varied from 15 minutes to five hours, with an average of one and three-quarter hours It was often severe and was usually described as burning or boring in character Its site was diffuse, but most commonly in the epigastrium and in patients with duodenal ulcer of the posterior wall, radiation of the pain to the interscapular area frequently occurred Three patients had typical ulcer pain constantly situated below the umbilicus in the midline, and in four others it was felt maximally in the right hypochondrium It was accompanied by acid regurgitation, heartburn, or waterbrash in 60 per cent of cases, and vomiting of a few mouthfuls of acid material occurred at the height of the pain in 15 per cent In 85 per cent of cases it was relieved within an average period of 15 minutes by the taking of food In the remaining 15 per cent , all of them examples of very severe ulcer pain, relief by food was not experienced Relief by alkalis was rapid in the few cases in which they were used Hypoglycaemic symptoms accompanied the pain only on rare occasions In no case was the pain accompanied by true hunger On the contrary, when severe it was invariably associated with anorexia and even when mild was often accompanied by this symptom This finding is contrary to the belief of many clinicians who regard a feeling of hunger as an integral part of the pain of duodenal ulcer In the present investigation ulcer pain was found to be accompanied frequently by a desire to eat, which is understandable considering the relief obtained It occurred with the onset of hunger, but when pain started, hunger disappeared and, particularly if severe, was often replaced by an actual distaste for food Moderate pain was often found to be associated with what

the patient called hunger, but on closer questioning this was always found to be a combination of two things, a knowledge that food would give relief, and the absence of an actual distaste for it In no instance was ulcer pain found to be accompanied by a strong desire for food for the simple pleasure of eating it, that is, true hunger

In the four patients of Group B, who had ulcer pain invariably associated with blood-sugar levels below 70 mg per 100 c c , the pain was found to be completely different from that described above It came on later, at a time which varied from two and three-quarters to four hours after a meal, the average interval being three and a quarter hours Its duration was much shorter, varying from 10 to 55 minutes with an average of 30 minutes It was never severe, and was described as an empty or tight feeling in the epigastrium, which in itself was not distressing It was invariably associated with a feeling of intense hunger and by symptoms which were unquestionably of hypoglycaemic origin, sweating, lassitude, apprehension, pallor, diplopia, emotional instability, palpitation, inability to concentrate, and tremor of the hands It was constantly and rapidly abolished by food and oral glucose, occasionally relieved by adrenalin injection, and unaffected by alkalis It was not accompanied by symptoms of acid regurgitation or vomiting The hypoglycaemic symptoms experienced by these patients were much more distressing than the mild epigastric discomfort which occurred, as may be appreciated from the following case record of one which is typical of the other three

Case 1 Age 39 years, grocer The patient was first seen in February 1946 He was admitted to hospital with severe melaena of two days' duration He was treated on standard lines and made an uneventful recovery in six weeks During the latter part of this period a test meal was performed and showed the following figures

Fasting	¼	½	¾	1	1¼ *hrs*	
38	6	41	63	74	62	c c of N/10 NaOH.

A barium meal revealed a tender deformed duodenal cap with no actual ulcer crater visible Shortly after admission he was questioned about his previous digestive history and the following facts were elicited Five years previously he had developed an abnormal appetite He found that if he did not have something to eat between meals his efficiency and alertness were greatly impaired and he had formed the habit of carrying with him to work chocolate, sweets, or biscuits If he neglected to do this, by noon or late afternoon he was ravenously hungry, exhausted, and irritable If he allowed the intense hunger to persist, other symptoms developed, including an empty feeling in the epigastrium which he refused to call a pain His wife supported him in this contention, stating that she had not heard him complain of pain during this period, although she had been aware of his abnormal desire for food Of these other symptoms the most pronounced were sweating, palpitation, a feeling of apprehension, and occasionally diplopia On one occasion when he had gone fishing and lost his sandwiches, a doctor had found him sitting by the loch side unable to tell him his name or address until he had been given fortuitously a cup of sweet tea Two years previously he had consulted the Medical Officer of his Army unit about his complaints and after being medically examined was informed that he suffered from diabetes A week later he had a sugar tolerance test and was told that this

diagnosis was incorrect, that the sugar found in his urine was of no importance, and that he should avoid sugary foods as far as possible for the remainder of his life He had not consulted any other doctor since then, although his symptoms had been constantly present until his admission to hospital with melaena He was discharged from hospital at the end of six weeks and for seven months remained well, although his hypoglycaemic symptoms occasionally recurred if he did not have frequent meals He then developed severe tonsillitis and during his convalescence when he was walking about but had not yet returned to work, his abnormal desire to eat returned As instructed, he reported immediately to hospital and further investigations were carried out Physical examination was negative except for some deep tenderness in the epigastrium A test meal showed no appreciable difference from the previous one, and his faecal occult blood test (benzidine) was positive on three occasions on a meat-free and chlorophyll-free diet The report of a barium meal done at this time was as follows 'The barium passes normally down the oesophagus into the stomach, which is small and hyperactive but otherwise normal The barium passed quickly into the duodenum, the cap of which is very deformed and tender on deep pressure A small ulcer crater is present in the anterior wall of the duodenum 1½" from the pylorus' A sugar tolerance test was performed in August 1946 and the following results were obtained (Table VI, Case 2)

Time	*Fasting*	¼	½	¾	1	1¼	1½	1¾	2	2¼	2½ *hrs*
Blood-sugar (mg per 100 c c)	102	148	226	173	121	68	117	114	100	92	94

Glycosuria was present during the first half of the test, and excessive hunger, weakness, sweating, and pallor persisting for 20 minutes developed at 73 minutes Blood-sugar readings taken during subsequent periods of hunger associated with upper abdominal discomfort are recorded in Table VIII (Case 2), and were all at hypoglycaemic levels Intravenous and oral glucose relieved the symptoms completely within a few minutes Both intravenous saline and water sweetened with saccharine taken orally had no effect He was put on a standard ulcer regime and three weeks later his symptoms disappeared He has since remained well, apart from occasional mild hypoglycaemic attacks, except for a period of three weeks in May 1947 when his symptoms suddenly reverted to their former severity, necessitating strict dieting and a short period in bed

There can be no doubt that the mild type of epigastric discomfort experienced by this patient and by the other three of Group B is a clinical entity separate from the common type of ulcer pain previously described This fact was clearly established in the investigations carried out in the eight patients of Group C who had duodenal ulcer pain associated with variable blood-sugar levels Two of these patients complained spontaneously of two distinct varieties of ulcer pain corresponding closely to the types described above It is significant that each applied the same terminology to the pains, describing the more common severe type as 'early' and the other as 'late' The following case record is taken from one of them and illustrates this point

Case 2 Age 40 years, garage mechanic The patient first developed dyspepsia in 1933, and in 1935 he was diagnosed radiologically as having a chronic duodenal ulcer He had had two severe haematemeses in 1935 and an operation for a perforated duodenal ulcer in 1939 Thereafter he remained symptom free until November 1944, when his dyspepsia recurred and persisted until he came under

observation in July 1946 At this time he complained of the following symptoms At an interval which varied from 40 minutes to one and a half hours after a meal he developed severe burning pain in the epigastrium radiating to the interscapular area This pain was relieved but not abolished by food, rest, and alkalis, and at its height heartburn and vomiting occasionally occurred. It came on at some period every day and often woke him up at night It was not accompanied by hunger, but some food was usually eaten to alleviate it When the pain was very severe, food failed to give relief, his appetite disappeared, and considerable loss of weight occurred as a result In addition to this severe pain which he described as his 'early' pain he also complained of a second type which he described as his 'late' pain The latter always occurred just before meals and lasted no longer than half an hour It was again described as an intense empty feeling in the stomach and was not distressing in itself It was immediately relieved by food, but not by alkalis He regarded this type of pain as a warning of the imminence of more unpleasant symptoms of hypoglycaemic type The most prominent of these were dysarthria, inability to think clearly, sweating, pallor, and palpitation He attributed the loss of two good jobs to these symptoms, as his work deteriorated badly in quality during their presence and he was liable to commit the most elementary technical errors His severe type of pain did not affect his work to an appreciable extent Inevitably he had discovered that a piece of chocolate or a few sweets relieved these 'late' symptoms within a few minutes, but he emphasized the importance of taking these early in an attack, as failure to do so was quickly followed by a mental state in which their therapeutic value was forgotten The hypoglycaemic symptoms did not occur more than twice or thrice a week and on one recent occasion they had disappeared for a continuous period of five weeks, in spite of the presence of severe 'early' pain during this time He stated that both types of pain sometimes occurred after the same meal, and even in these circumstances hypoglycaemic symptoms developed with the onset of 'late' pain Radiological investigation of this patient confirmed the presence of a penetrating posterior wall duodenal ulcer A sugar-tolerance test gave the following values (Table VI, Case 13)

Time	*Fasting*	¼	½	¾	1	1¼	1½	1¾	2	2¼	2½ *hrs*
Blood sugar (mg per 100 c c)	91	139	174	217	224	152	123	63	104	98	102

Glycosuria was present during the test and hypoglycaemic symptoms similar to those of which he complained developed in 95 minutes A fractional test meal revealed a typical climbing-curve type of hyperchlorhydria and faecal occult blood tests were constantly positive He was put on a standard ulcer regime and has remained fairly well since that time, although he still has periods of severe symptoms

Four of the remaining six patients in Group C did not spontaneously give a history of having suffered from two distinct types of ulcer pain, but their descriptions of symptoms gave this impression, and when the possibility was brought to their attention they readily agreed and were able to differentiate clearly between the two varieties and, what is of greater significance, were able to describe hypoglycaemic symptoms present with the 'late' type which were never present with the other The remaining two patients of this group had no experience of 'late' pain, in spite of having occasional low blood-sugar levels during attacks of ulcer pain Each time 'late' pain was encountered in the patients of this group the blood-sugar level was below 70 mg per 100 c c , and

it was accompanied by classical symptoms of hypoglycaemia It is noteworthy that the converse was found to be untrue, typical severe ulcer pain being found not infrequently with blood-sugar levels as low as 60 mg per 100 c c It is of interest to record some other investigations (Table IX) in the four patients of Group B who complained solely of 'late' or hypoglycaemic pain Each patient

TABLE IX

(a) *Test meals*

	Fasting	¼	½	¾	1	1¼	1½ *hrs*	
Case 1	73	12	34	58	72	80		c c of N/10 NaOH
,, 2	38	6	41	63	74	62		
,, 3	44	14	22	48	71	86	84	
,, 4	31	7	29	41	63	72		

(b) *Glucose tolerance test*

	Fasting	¼	½	¾	1	1¼	1½	1¾	2	2¼	2½ *hrs*	
Case 1	72	136	181	214	173	140	64	91	85	78	80	mg per 100 c c
,, 2	102	148	226	173	121	68	117	114	100	92	94	
,, 3	84	134	174	216	216	163	61	97	89	96	83	
,, 4	91	139	174	217	224	152	123	63	104	98	102	

showed hyperchlorhydria with a rapidly emptying stomach The glucose tolerance curves were of the 'lag' type and glycosuria occurred in each Hypoglycaemic symptoms occurred in Cases 1, 2, and 4 about the time of minimum blood-sugar levels

4 *The effect of glucose on the pain of duodenal ulcer*

In 83 patients with duodenal ulcer confirmed radiologically, all included in the series previously investigated for hypoglycaemia during an attack of pain, a simultaneous investigation into the effects of intravenous glucose on such pain was undertaken In all, 122 intravenous injections of 30 c c of 40 per cent. glucose were given at random and the results controlled by giving equivalent injections of normal saline Each injection was made during an attack of ulcer pain, the character and severity of which were carefully recorded before the injection was given, and its effect noted No attempt was made to investigate the blood-sugar levels during these experiments Not more than three investigations of each type were made on any one patient In eight patients, intravenous glucose invariably relieved the pain within a few minutes The composition of this group was as follows

(i) Three men who also experienced prompt relief from intravenous normal saline It was considered in these cases that the psychological effect of the injection was more important than its composition

(ii) One man who suffered from typical severe ulcer pain constantly relieved by intravenous glucose and not by intravenous saline No explanation could be offered for this finding, as blood-sugar readings taken during his attacks of pain did not fall below 91 mg per 100 c c and did not rise above 178 mg per 100 c c after an injection It is unlikely that inhibition of gastric motility and secretion occurred at the latter level

(iii) The four men of Group B above, who invariably complained of 'late' or hypoglycaemic pain Each injection was made during a typical attack of this type of pain, and relief was rapid and complete Intravenous normal saline solutions and glucose solutions of strength insufficient (1 to 5 per cent) to raise the blood-sugar above hypoglycaemic levels were uniformly unsuccessful in alleviating the ulcer pain

In six patients, intravenous glucose relieved ulcer pain only on some occasions, and saline had no effect These were the same six patients of Group C who occasionally suffered from 'late' pain, and on each occasion when the injection successfully relieved the pain it was of this type When it was of the common 'early' type it was not alleviated In the remaining 69 patients, intravenous glucose had no effect on ulcer pain, which was invariably of the 'early' type When it was realized that pain associated with a low blood-sugar level and of a characteristic type was a clinical entity in patients with duodenal ulcer, glucose injections were given each time it was encountered The pain was uniformly abolished by this procedure and also by giving 15 gm of glucose in a glass of water by mouth When saline was substituted for the intravenous glucose, no relief was experienced When a glass of water with saccharine added to sweeten it and a pinch of flour to give it a cloudy appearance was substituted for the glucose drink, relief was experienced but it was delayed and never complete

Discussion

The results obtained in these experiments confirm the closeness of the relationship between carbohydrate metabolism and gastric secretory activity Patients with duodenal ulcer were shown to react to glucose and insulin in a manner similar to normal subjects The only differences observed were differences of degree Thus insulin appeared to stimulate free gastric acidity more powerfully in the ulcer cases, and intraduodenal glucose inhibited it more markedly in the normal subjects The former observation is probably a manifestation of the vagotonia of patients with duodenal ulcer while the latter may be explained by the work of Shay, Gershon-Cohen, and Fels (1942) in which they showed that the duodenal mucosa of a patient with duodenal ulcer was less sensitive to stimulation by hypertonic solutions than that of a healthy person

It was found that approximately 15 per cent of a series of 80 cases of duodenal ulcer had a glucose tolerance curve of the 'lag type' and more readily showed symptoms of hypoglycaemia during the test This agrees with the majority of published observations, Evensen (1942), for example, finding a similar incidence in 50 cases, after excluding all other possible causes of glycosuria It is thus apparent that patients with duodenal ulcer have a greater tendency to hypoglycaemia than normal persons, and it is clear that under more natural conditions where physical work is performed this tendency would be even more marked Evensen (1942) has indeed proved this point by performing glucose tolerance tests during the performance of a standard amount of work According to some workers the importance of this type of hypoglycaemia in patients with

duodenal ulcer is that it may initiate ulcer pain, since hypoglycaemia is the important factor causing the increase in gastric secretion and motility after insulin administration The results obtained do not support this view in the great majority of cases The common type of ulcer pain was not relieved by glucose given in sufficient quantity to overcome any hypoglycaemia present. Blood-sugar readings taken at different times throughout the attacks of pain were in most cases above hypoglycaemic levels Occasionally typical severe ulcer pain was associated with blood-sugar levels below 70 mg per 100 c c , but in each case intravenous glucose failed to give relief and no other hypoglycaemic symptoms were present On the other hand, it is stressed that hypoglycaemic pain can occur as a symptom of duodenal ulcer The frequency of this type of pain is difficult to assess In the present series of 87 patients, four were found who suffered from it exclusively and it was present occasionally in six others, but this incidence may, however, be unusually high Since its recognition it has been searched for in several hundred other patients with duodenal ulcer, but only one man was discovered with this special type of pain as his main complaint, although it was encountered not infrequently as an occasional symptom It is readily differentiated from typical ulcer pain by its constant association with true hunger and with other symptoms of hypoglycaemia Other distinctive features may be summarized as follows

'Late' pain	*'Early' pain*
1 Never severe Usually described as a marked 'empty' or 'sinking' feeling in the stomach	1 Often severe Described as 'burning', 'boring'
2 Does not radiate	2 Often radiates into the back and chest
3 Constantly associated with a feeling of intense hunger	3 Seldom associated with a feeling of hunger, particularly if severe
4 Occurs several hours after a meal when the stomach feels empty	4 May occur as early as half an hour after a meal when the stomach feels full
5 Relief by food immediate and complete	5 Usually, but not constantly, relieved by food
6 Alkalis do not relieve	6 Alkalis often relieve
7 Frequently associated with dryness of the mouth	7 Not usually associated with dryness of the mouth
8 Often accompanied by other symptoms more distressing than the pain itself, such as lassitude, apprehension, sweating, faintness, pallor, clumsiness, inability to concentrate, emotional instability, &c	8 Seldom accompanied by other symptoms, apart from those often associated with severe pain, such as restlessness and irritability

The cause of 'late' or hypoglycaemic ulcer pain is difficult to determine It may be due to the increase in gastric motility and secretion known to occur

during hypoglycaemia, the former causing rapid stomach emptying, leaving the augmented gastric acid unbuffered to induce ulcer pain If this is the cause, however, it is difficult to explain why it should differ so much clinically from typical ulcer pain, which, according to modern opinion, is induced by the same mechanism, and particularly why it should not be relieved by alkalis A more likely hypothesis is that it is a component of the ordinary hypoglycaemic syndrome and not related to the presence of a duodenal ulcer *per se* The clinical features of 'late' ulcer pain suggest that this explanation is the more likely To investigate this point the four patients of Group B who complained exclusively of hypoglycaemic ulcer pain and the six of Group C who complained of it occasionally were given intravenous insulin in sufficient doses to produce hypoglycaemia This was done on a fasting stomach immediately after a large dose of soluble alkali had been taken to ensure that any epigastric discomfort subsequently experienced was not due to unbuffered acid secretion In each case hypoglycaemic symptoms developed identical to those experienced spontaneously, and these included epigastric discomfort similar in every respect to hypoglycaemic ulcer pain, suggesting that this type of pain is directly due to the hypoglycaemia and not to any secondary effects which this may have on gastric secretion and motility One fact, however, still requires explanation if this hypothesis is correct In healthy persons hypoglycaemia often produces intense hunger by increasing gastric tone and motility, but it seldom produces epigastric discomfort, even of the mild character of hypoglycaemic ulcer pain Furthermore, in 10 fasting patients with duodenal ulcer, none of whom had ever suffered from hypoglycaemic ulcer pain, hypoglycaemia induced by insulin failed to produce epigastric discomfort of any kind It is obvious, therefore, that in those patients with duodenal ulcer who experience hypoglycaemic pain, some unknown factor exists which promotes epigastric discomfort to an unusually prominent position in the symptomatology of hypoglycaemia The fact that hypoglycaemic pain occurs as an occasional symptom of duodenal ulcer is not unexpected From what has been said above, it is probably no more than an exaggeration of a condition which has been known for some time to occur in healthy people, many of whom, with the onset of hunger, experience a feeling of emptiness of the stomach associated with lassitude, inability to concentrate, faintness, and other mild hypoglycaemic symptoms Jones (1935) discussed this problem in healthy American workers and attributed mid-morning hypoglycaemic symptoms to the high-carbohydrate, low-fat content of the average American breakfast To this condition the name alimentary hypoglycaemia has been applied and its mode of production is identical with that of hypoglycaemic symptoms in patients with duodenal ulcer, namely, initial rapid absorption of carbohydrate as a result of a rapidly emptying stomach followed by reactive hypoglycaemia due to an excessive insulin response by the pancreas In the present investigation one healthy man was found who suffered from alimentary hypoglycaemic attacks and the similarity of his symptoms to those of the four patients of Group B was striking, as will be seen from his case record

A medical student aged 22 years In August 1946 a control sugar-tolerance test was performed on this healthy man and a 'lag curve' response obtained. A test meal showed normal gastric acidity with a stomach emptying time of one and a half hours A barium meal revealed no gastric or duodenal abnormality, apart from the presence of a small hyperactive stomach, and repeated faecal occult blood tests were negative The actual blood-sugar levels after the ingestion of 50 gm of glucose have been recorded on p 248 Subsequent questioning of this student elicited the following history Since the age of 15 years he had suffered from attacks of lethargy and mental confusion before meals These attacks lasted for about half an hour, occurred only after a three- or four-hour fast, and were immediately relieved by food He estimated that they occurred perhaps twice a week and he had recently come to the conclusion after reading an article on this syndrome that they were hypoglycaemic in origin The symptoms which developed during an attack were very constant Hunger and sweating developed first, rapidly followed by palpitation and a feeling of intense apprehension If nothing was eaten apprehension gradually became replaced by a state of euphoric mental confusion very similar to mild alcoholic intoxication He was naturally questioned closely about his gastric symptoms during these attacks, and admitted that he experienced a feeling of tightness across the stomach, but the impression was gained that this was not so marked as that of hypoglycaemic ulcer pain He had formed the habit of carrying about with him biscuits or a few lumps of sugar to terminate the attacks He had been forced to give up playing rugby football, as violent exercise frequently precipitated an attack The palpitation and faintness he experienced had even led him to suspect erroneously a cardiac weakness The possibility of an islet-cell tumour of the pancreas was considered in this case, but rejected on clinical grounds

This man's symptoms differ from those of the four patients with duodenal ulcer of Group B only in their relative infrequency and in the fact that epigastric discomfort was a little less marked It is suggested, therefore, that patients with alimentary hypoglycaemia should have a complete gastric investigation, even in the absence of a history of dyspepsia, to exclude the presence of duodenal ulceration Each of the four patients in Group B gave a history of what were virtually attacks of alimentary hypoglycaemia None suffered from ulcer dyspepsia even in its mildest form, and were recognized as suffering from chronic duodenal ulcer only after serious haemorrhage had occurred

Finally, an attempt was made in these investigations to assess the possible merits of glucose as an antacid in the therapeutics of duodenal ulcer The addition of 60 gm of glucose to the test meal gruel led to a depression in gastric acidity From the results obtained, the degree of depression in acidity by this relatively large dose of glucose does not warrant its employment as an antacid Smaller doses of the common alkalis are much more effective and considered purely in this light oral glucose has little place in the treatment of duodenal ulcer The same conclusion applies to intravenous glucose for similar reasons, but cannot be applied to intraduodenal glucose which is a profound depressant to gastric acidity when given in hypertonic solution A modern diet and alkali regime thoroughly controls diurnal acidity in patients with duodenal ulcer Intragastric drips of milk and alkali have been used to control nocturnal acidity in intractable cases and it is suggested that an intraduodenal drip of 30 per cent

glucose might act more efficiently in this respect, as its action is to inhibit the production of gastric secretion and not to neutralize it after its formation, and so allow it even a transitory action

Summary

1 Glucose inhibited acid secretion of the stomach in patients with duodenal ulcer, and prolonged gastric emptying time The maximal effect was produced by intraduodenal hypertonic glucose, oral and intravenous glucose having a similar but weaker action

2 The inhibition of gastric acidity produced by intraduodenal hypertonic glucose in patients with duodenal ulcer was not so complete as that produced in normal persons

3. Insulin stimulated acid secretion of the stomach in patients with duodenal ulcer and shortened gastric emptying time This action was more powerful in patients with duodenal ulcer than in normal persons

4 Thirteen patients with duodenal ulcer out of 80 investigated had a 'lag curve' type of response to the ingestion of 50 gm glucose Six of them developed confirmed hypoglycaemic symptoms during the test

5 In 87 patients with duodenal ulcer, blood-sugar estimations made during attacks of ulcer pain showed constant hypoglycaemic levels in four patients, variable levels in eight, and levels invariably above 70 mg per 100 c c in 75

6 It is suggested that hypoglycaemic pain is a clinical entity in duodenal ulcer Four patients were found who suffered exclusively from it, and six who had it as an occasional symptom

7 Hypoglycaemic pain is contrasted with the common type of ulcer pain and found to differ from it, mainly in its association with intense hunger and other hypoglycaemic symptoms

8 Four patients with chronic duodenal ulcer are described, each of whom gave a history of repeated attacks of alimentary hypoglycaemia as their major complaint

9 Glucose was found to be ineffective in relieving the common type of ulcer pain. It relieved hypoglycaemic pain immediately

10 It is suggested that intraduodenal hypertonic glucose has a place in the treatment of intractable cases of peptic ulcer

My thanks are due to Dr D K Adams and Professor C F Illingworth in whose departments of the Western Infirmary, Glasgow, the work was carried out, and principally to Professor J W McNee for his help and encouragement in the preparation of this paper, and for laboratory facilities in the Gardiner Institute of Medicine

The work was carried out during the tenure of a British Medical Association Research Scholarship

REFERENCES

Aldor, L (1900) *Z klin Med* **40**, 248
Boldyreff, E B, and Stewart, J F (1932) *J Pharmacol* **46**, 407
Bowen, B D, and Aaron, A H (1926) *Arch int Med* **37**, 674
Clemm, W N (1901) *Zucker Therap Monatshefte*, **15**, 403
Coelho, E, and Oliviero, J C (1928) *C.R Soc Biol* **98**, 477
Day, J J, and Komarov, S A (1939) *Amer J Dig Dis* **6**, 169
Dibold, H (1933) *Med Klin* **29**, 1606
Dobreff, M (1931) *Arch Verdauungskr* **50**, 157
Evensen, O K (1942) *Acta med scand*, Suppl 126
Freud, J, and Nazim, S (1926) *C.R Soc Biol* **95**, 571
Friedman, M H F (1939) *Amer J Physiol* **126**, 495
Gilman, A, and Cowgill, G R (1931) *Ibid* **99**, 172
Glaessner, C L (1943) *Amer J Dig Dis* **10**, 307
Heymans, J F, and Heymans, C (1925) *C.R Soc Biol* **93**, 1032
Jones, C R (1935) *Amer J Dig Dis* **1**, 135
Kalk, H, and Meyer, P F (1932) *Z klin Med* **120**, 692
La Barre, J (1930) *C R Soc Biol* **105**, 209
—— (1931*a*) *Ibid* **106**, 1244
—— (1931*b*) *Ibid* **107**, 906
—— (1931*c*) *Ibid* **107**, 258
—— (1931*d*) *Ibid* **108**, 231
—— and Cespédès, C de (1931) *Ibid* **106**, 480
—— and Haussa, P (1932) *Ibid* **110**, 598
Landé, K (1931) *Klin Wchnschr* **10**, 359
Lapp, F W, and Dibold, H (1931) *Ibid* **10**, 1221
Laughton, N B (1929) *Amer J Physiol* **89**, 18
Leconte, P (1900) *La Cellule*, **17**, 285
Lyon, E, and Kleinhaus, E M (1945) *Acta med orient* **4**, 144
Maclean, H (1926) *Lancet*, **1**, 1129
McPherson, E (1927) *Glasgow Medical Journal*, **107**, 340
Malmros, H (1928) *Acta med scand*, Suppl 27
Matsuyama, M (1932) *Jap J Gastroenterol* **4**, 262
—— (1933) *Ibid* **5**, 37
Meyer, P F (1930) *Klin Wchnschr* **9**, 1578
Miller, R J, Bergeim, O, Rehfuss, M E, and Hawk, P B (1920) *Amer J Physiol* **53**, 28
Noble, R L, and Robertson, J D (1938) *J Physiol* **93**, 430
Okada, S, Kuramochi, K, Tsukahara, T, and Oomaue, T (1929) *Arch int Med* **43**, 446
—— —— —— —— (1930) *Ibid* **45**, 783
Portis, S A, and Jaffé, R H (1938) *J Amer Med Ass* **110**, 6
Quigley, J P, Johnson, V, and Solomon, E I (1929) *Amer J Physiol* **90**, 89
—— and Templeton, R D (1930*a*) *Ibid* **91**, 475
—— —— (1930*b*) *Ibid* **91**, 482
Recht, G (1931) *Med Rev of Rev* **37**, 1
Roholm, K (1930) *Acta med scand* **73**, 472
Rothenberg, R E, and Teicher, I (1938–9) *Amer J Dig Dis* **5**, 603
Shay, H, Gershon Cohen, J, and Fels, S S (1938–9) *Ibid* **5**, 4
—— —— —— (1939–40) *Ann int Med* **13**, 294
—— —— —— (1942) *Amer J Dig Dis* **9**, 124
—— —— —— and Siplet, H (1942) *Ibid* **9**, 363
Staub, H (1927) *Klin Wchnschr* **6**, 401
Strauss, H (1932) *Arch Verdauungskr* **51**, 168
Wein, G, and Frisk, A R (1936) *Acta med scand* **90**, 543
Zunz, E, and La Barre, J (1930) *Arch intern physiol* **33**, 142

616.24–007 63

CIRCULATORY DYNAMICS IN EMPHYSEMA[1]

By A D GILLANDERS

(From the Royal Infirmary, Edinburgh)

Introduction

Blumgart and Weiss (1927) made the significant observation that pulmonary blood-flow is not retarded in the presence of emphysema At the same time they found cause to believe that peripheral venous pressure is unaffected by this disease They argued therefore that in the emphysematous patient a prolonged circulation time *or* a raised venous pressure is diagnostic of heart-failure 'even in the absence of oedema or other clinical evidence of congestive failure' (Blumgart, 1931) This was not in accord with their findings in decompensated heart-failure of other aetiology that circulation time is prolonged *and* venous pressure raised Nor did it conform to their valid argument that in the evolution of congestive heart-failure circulation time is prolonged before venous pressure rises That circulation times are not appreciably changed in uncomplicated emphysema has been confirmed by many workers (Tarr, Oppenheimer, and Sager, 1933, Fishberg, Hitzig, and King, 1932, Kaltreider, 1938), but it has subsequently been shown (Kountz, Pearson, and Koenig, 1932) that peripheral venous pressure is commonly raised in the absence of heart-failure The opposite view that venous pressure is reduced has also been expressed (Master, Jaffe, and Dack, 1935, Durant, 1946) The present paper presents evidence that *in pulmonary emphysema blood-flow is significantly faster and peripheral venous pressure higher than in health*

Emphysema and congestive heart-failure have so many symptoms and signs in common, including effort dyspnoea and cyanosis, that the diagnosis may at times be difficult (Fishberg, 1944) It is usually stated that enlargement of the liver from venous engorgement or the appearance of oedema establishes the diagnosis of heart-failure (Durant, 1946) Neither cardiographic nor X-ray examination can be relied upon to do so (Parkinson and Hoyle, 1937) Enlargement of the liver is ordinarily presumed from descent of its lower border In the emphysematous patient downward displacement of this organ is a natural sequel to the changes within the chest and in these circumstances it may be impossible to determine whether it is engorged or not Moreover oedema may possibly be caused by emphysema alone (Kountz and Alexander, 1934) From a consideration of circulation times and venous pressures an attempt will be made to establish diagnostic criteria by which emphysema can be differentiated from the heart-failure it may cause and this, in turn, from heart-failure occurring

[1] Received December 28, 1948

as an incidental but serious complication of the pulmonary disease Rational treatment demands this distinction

Clinical Material

The investigation embraces representative groups of patients (1) with emphysema, (2) with emphysema with congestive heart-failure, and (3) healthy adults The word emphysema as used in the present paper refers to *chronic hypertrophic vesicular emphysema* The subjects included in the third group, 40 in number, were normal in the sense that they had no recognizable disease, they serve as controls The group with emphysema comprises only 25 patients because in an attempt to incorporate only those with uncomplicated emphysema the rejection rate was high Although this principle of selection was retained, it became apparent that its strict application was impracticable, otherwise all, or nearly all, those of middle age and beyond would be excluded As age advances, emphysema, as it is encountered in the wards and out-patient department of a large general hospital, is increasingly accompanied by degenerative changes elsewhere, notably in the systemic and coronary arterial systems To an even greater extent did this set a limit to the number in the second group The intention was to restrict it to patients with congestive heart-failure caused, so far as could be made out, by emphysema alone This meant the exclusion of all with any additional lesion that might be considered to have contributed to the development of heart-failure It became clear in time, as others had previously observed (White and Brenner, 1933, Parkinson and Hoyle, 1937), that the pure syndrome of emphysema heart-failure is rare The group as now considered, therefore, consists of patients in whom emphysema appeared to be the direct cause of heart-failure, and in whom it was unlikely that coexisting hypertension or atherosclerosis would by itself have caused heart-failure Twelve such patients were available for investigation over a period of two years All the 37 cases of emphysema in the whole series conformed to the diagnostic criteria of Christie (1934, 1944), the ultimate diagnosis in each case being based on the spirometric pattern of breathing By the same standards, emphysema was excluded in the controls There was every indication in all those with heart-failure that emphysema preceded failure by a long period of time A fourth group of 40 patients with rheumatic heart disease with congestive failure, investigated at the same time, will be referred to briefly by way of comparison

Methods

The respiratory pattern (including vital capacity, complemental air, and reserve air) of each subject was registered with a McKendrick recording spirometer (Christie, 1934, Cournand, Richards, and Darling, 1939) During this and all other technical procedures to be mentioned the patient was supported in the position of 45 degrees recumbency Venous pressure was recorded directly (Moritz and von Tabora, 1909) from an antecubital vein with the arm abducted to 45 degrees The zero reference level used was the horizontal plane passing

through the sternal angle (Lewis, 1930) After the vein had been punctured, not less than 15 minutes were allowed to pass before the pressure was recorded Subsequently, the abdomen was pressed firmly with the palm of the hand and any change in brachial venous pressure noted (Winsor and Burch, 1946) Without removing the needle from the vein, arm to tongue time was recorded with decholin (Winternitz, Deutsch, and Brull, 1931), and arm to lung time with ether (Hitzig, 1933) The quantity and dilution of each drug conformed to the optimum demanded by Ruskin and Rockwell (1945) Care was taken in explaining to the patient his or her role in the performance of these tests Circulation times were measured from the moment when half the injection had been given The first reading of both decholin and ether times was discarded, irrespective of what was thought of its accuracy, and a second determination made 24 hours later All observations of venous pressure and circulation times were made between 10 a m and noon, never less than two hours after a meal, and at a time sufficiently remote from the patient's exercise with the spirometer to prevent any interference from that experience Each patient was investigated in this way on one or more occasions during a single period in which he or she was under hospital care Many were known of old and had previously been investigated in the same way, but observations made outside the period of planned investigation are excluded from the statistical analysis In the emphysema group 35 observations were made in each test category, in the emphysema heart-failure group there were 27, and in the control group 40 The age and sex distribution in each group was sufficiently similar to preclude any variations from this cause in circulation time (Blumgart, 1931, Tarr, Oppenheimer, and Sager, 1933) or venous pressure (Winsor and Burch, 1946, Wiggers, 1947)

Results

Relevant statistics calculated from the frequency distribution of segmental circulation times and brachial venous pressures in each of the three groups (controls, emphysema, and emphysema heart-failure) are given in Table I Comparison of the emphysema group with the controls (Table II) revealed significant differences as follows In those with emphysema, arm to tongue time was less, lung to tongue time was less, and brachial venous pressure was greater than in the controls By the conventional standard of significance (which is a value of $P = 0\ 05$, or a difference between means which is twice the standard error) arm to lung time did not differ significantly in the two In no individual of either group did manual compression of the abdomen cause brachial venous pressure to alter appreciably Within the trivial range observed (−3 to +2 mm of blood) the direction of change was erratic in both groups Among those patients classified as having uncomplicated emphysema, in seven subcutaneous oedema of mild or moderate degree was present The occurrence of oedema was not apparently correlated with the level of brachial venous pressure nor with the duration of either of the circulation times

In those with emphysema and congestive heart-failure (Table II) arm to tongue and arm to lung times were, as would be expected, greater than in those

with uncomplicated emphysema, and greater than in the normal controls Venous pressure was likewise higher, whereas lung to tongue time (by the same minimal standard as before) was not significantly different from that in the controls, but was greater than in those with uncomplicated emphysema. In every patient classified as having emphysema heart-failure, abdominal com-

TABLE I

Circulation Times and Brachial Venous Pressure in Controls, Uncomplicated Emphysema, and Emphysema with Congestive Heart-Failure

	Arm to tongue time (seconds)	*Arm to lung time (seconds)*	*Lung to tongue time (seconds)*	*Brachial venous pressure, mm blood above sternal angle*	*Change in brachial venous pressure caused by compression of abdomen, mm blood*
			Controls		
Mean	12 01	4 72	7 30	17 45	
Range	8 2 to 14 6	3 6 to 9 0	3 0 to 9 9	3 to 46	−3 to +2
Standard deviation .	1 56	1 19	1 78	9 41	
Standard error of mean . .	0 25	0 19	0 28	1 49	
			Uncomplicated emphysema		
Mean	10 44	5 09	5 35	56 76	.
Range	7 3 to 14 0	3 7 to 7 5	2 6 to 8 1	22 to 135	−3 to +2
Standard deviation	1 38	0 97	1 35	27 51	
Standard error of mean . .	0 23	0 17	0 23	4 72	
			Emphysema heart failure		
Mean	19 42	12 43	6 83	123 13	+70 66
Range	11 6 to 35 2	4 0 to 20 3	4 0 to 16 5	15 to 300	+10 to +160
Standard deviation	5 62	4 65	2 79	89 18	45 98
Standard error of mean	1 15	0 95	0 54	18 20	9 40

pression caused an increase in brachial venous pressure (Table I) This increase was so pronounced as never to be equivocal It became less as the patient recovered, but the smallest increase recorded during the period of observation exceeded the maximum obtained in either of the other two groups

When admitted to hospital all patients with emphysema heart-failure had cyanosis and oedema of varying degree All were dyspnoeic at rest, but only one was orthopnoeic He was a patient known to us previously whose disability had appeared to be determined by emphysema although he was also hypertensive Two other patients became orthopnoeic subsequently, with the development of left ventricular failure from which they died. These will again be referred to presently Seven of the 12 patients died during the stay in hospital, four within 24 hours of admission One patient, after improving for a time, developed acute left ventricular failure after coronary thrombosis and died two

hours later The right heart-failure of another developed into a progressive failure of the whole heart associated with an insidiously advancing pneumonia Records of circulation times and venous pressures in the phase of superadded left ventricular failure are included in the records (Tables I and II) Both these instances will tend to vitiate the characteristic features of cor pulmonale, as will

TABLE II

Difference between Mean Values in

(*a*) *Controls and Emphysema*

	Controls	*Emphysema*	*Difference*	*Standard error of difference*	*t*	*P*
Arm to tongue time (seconds)	12 01	10 44	1 57	0 338	4 645	< 0 001
Arm to lung time (seconds)	4 72	5 09	0 37	0 250	1 480	> 0 1
Lung to tongue time (seconds)	7 30	5 35	1 95	0 362	5 387	< 0 001
Brachial venous pressure (mm. blood)	17 45	56 76	39 31	4 870	8 031	< 0 001

(*b*) *Controls and Emphysema Heart-Failure*

	Controls	*Emphysema heart-failure*	*Difference*	*Standard error of difference*	*t*	*P*
Arm to tongue time (seconds)	12 01	19 42	7 41	1 173	6 319	< 0 001
Arm to lung time (seconds)	4 72	12 43	7 71	0 968	7 955	< 0 001
Lung to tongue time (seconds)	7 30	6 83	0 47	0 589	0 798	> 0 4
Brachial venous pressure (mm blood)	17 45	123 13	105 68	18 300	5 775	< 0 001

(*c*) *Uncomplicated Emphysema and Emphysema Heart-Failure*

	Emphysema	*Emphysema heart-failure*	*Difference*	*Standard error of difference*	*t*	*P*
Arm to tongue time (seconds)	10 44	19 42	8 98	1 170	7 675	< 0 001
Arm to lung time (seconds)	5 09	12 43	7 34	0 964	7 614	< 0 001
Lung to tongue time (seconds)	5 35	6 83	1 48	0 565	2 619	< 0 02
Brachial venous pressure (mm blood)	56 76	123 13	66 39	18 810	3 519	< 0 001

be shown Five patients died from progression of their initial heart-failure, which preserved its right ventricular pattern to the end

When the distribution of lung to tongue times in each of the three groups is represented by a frequency diagram it is obvious that uncomplicated emphysema and emphysema with heart-failure have a common mode which is less than that of the controls, and that three values of the variate (11 0, 13 1, and 11 5 seconds)

lie outside the otherwise symmetrical curves Two of these aberrant values derive from the patients already referred to as having superadded failure of the left heart at the time when the observations were made, the third is from the patient who was orthopnoeic when admitted and was previously known to be hypertensive If the three values in question are excluded from the statistical

TABLE III

Circulation Times and Brachial Venous Pressure in Rheumatic Heart-Failure

	Arm to tongue time (seconds)	*Arm to lung time (seconds)*	*Lung to tongue time (seconds)*	*Brachial venous pressure (mm blood above sternal angle)*
Mean	30 27	20 19	19 10	99 03
Standard deviation	22 63	13 38	14 08	52 33
Standard error of mean	1 06	2 40	2 53	9 40

calculation, the lung to tongue time of emphysema heart-failure no longer differs significantly from that of uncomplicated emphysema, at the same time it becomes significantly less than in the controls The implications of this may well be that when heart-failure develops purely in consequence of emphysema there is no change in the original lung to tongue time, and that in the presence of emphysema, even after it has caused heart-failure, the pulmonary circulation is faster than it is in health In contrast (Table III), arm to tongue time is often twice as long in heart-failure due to rheumatic heart disease as it is in the heart-failure of emphysema, notwithstanding that peripheral venous pressure is equally raised in both In rheumatic heart-failure also prolongation of circulation time is gross in both arm to lung and lung to tongue fractions, the greater prolongation occurring over one or other parts of the circulation respectively as the failure is dominantly of the right or left side of the heart (Fishberg, Hitzig, and King, 1932) In emphysema heart-failure only arm to lung time is prolonged beyond normal values, and even so it is scarcely more than half the corresponding time in rheumatic heart-failure

Discussion

When intrapleural pressure is raised artificially, as in the Valsalva experiment or in positive pressure breathing, auricular pressure is increased by a greater amount than is the pressure in the peripheral veins (Holt, 1942, Richards, 1945, Carr and Essex, 1946), cardiac output falls as the venous pressure gradient becomes less (Cournand, 1947) At the same time the rate of blood-flow in the peripheral venous pathway must be retarded (Starling, 1920, Blumgart, 1931) and the corresponding circulation time prolonged In emphysema, although the intrapleural pressure is uniformly raised (Kountz, Pearson, and Koenig, 1932), the arm to tongue time is faster than in health at the same time as the peripheral venous pressure is increased Cardiac output also is high (McMichael, 1946) The raised intrapleural pressure of emphysema cannot therefore be the sole

cause of the venous hypertension that occurs in this disease Notwithstanding the complexity of the vascular system, the circulation of blood conforms to physical laws (Wiggers, 1940, Fishberg, 1944), from which it can be argued that in emphysema the combination of raised pressure and unretarded blood-flow in the peripheral veins necessarily implies a diminished (systemic) arteriolo-capillary resistance and a reduced capacity of the venous channels concerned Corresponding changes in the dynamics of blood-flow can be produced by experimental anoxia (Lennox and Gibb, 1932, Kountz and Alexander, 1934) It is probable that in emphysema these changes are also conditioned by oxygen lack and not directly by structural changes in the lungs The changes in circulatory dynamics in heart-failure due to emphysema are superimposed on a high venous pressure and a fast rate of blood-flow Slowing of the circulation is inevitable in congestive heart-failure from any cause (Fishberg, Hitzig, and King, 1932), but slowing is relative to its velocity before the heart failed. If therefore in the course of emphysema the arm to lung (and, consequently, arm to tongue) time becomes recognizably prolonged, then in the absence of other obvious cause, the heart is failing although the circulation times may still be within normal limits In this event the existence of relatively prolonged circulation times can be appreciated only by comparison of serial records

A significant prolongation of arm to lung and arm to tongue times was demonstrated in every patient in the group with emphysema heart-failure (Table I) In all but three this was apparent at the first examination because the circulation times exceeded the corresponding maximum recorded in the controls The three exceptions occurred in patients whose circulation times had been recorded from time to time during the previous 18 months In these patients, with the advent of failure the increase in both arm to lung and arm to tongue times was obvious relative to previously recorded values In all, moreover, who recovered from heart-failure or improved for a time, the same circulation times decreased in proportion Among those with emphysema were seven patients having peripheral oedema at the time of admission to hospital. In none of these nor in any of the 18 without oedema did the various segmental circulation times exceed the corresponding values recorded in the controls By ordinary clinical standards those having oedema might have been diagnosed as having cor pulmonale. Serial observations in all, however, failed to reveal an increase in either arm to lung or arm to tongue circulation times coincident with aggravation of symptoms, or the occurrence or progression of oedema One or more previous records of circulation times for each patient was available for comparison As the clinical condition improved and the oedema disappeared the circulation times did not diminish as would be expected if the patients had had congestive heart-failure On the contrary, of seven patients who improved, in four circulation times increased, while in three the variation was not significant The usual cause of the deterioration in health which brings the emphysematous patient to hospital is an exacerbation of bronchitis This applies whether heart-failure is present or not The tentative interpretation of the lengthening circulation times during recovery is that the addition of an acute respiratory illness impairs still further

the respiratory capacity of the emphysematous lungs and so necessitates a faster circulation of blood in the attempt to preserve the previous oxygen availability to the tissues Statistically, peripheral venous pressure in emphysema heart-failure is greater than in uncomplicated emphysema, but in the individual it may not be so Hence, although a rising venous pressure is an invariable accompaniment of congestive heart-failure (Lewis, 1930, Fishberg, 1944) a pressure in excess of normal lacks any significance in the emphysematous patient unless it also exceeds the range of raised pressure due to emphysema alone In the advanced stages of emphysema heart-failure it probably always does, in the early stage it commonly does not

It has long been known that manual compression of the engorged liver in the patient with congestive heart-failure causes visible distension of the neck veins (Pasteur, 1885, Randot, 1898) More recently it has been shown that in the presence of right ventricular failure, compression of the liver (Hitzig, 1942), the right upper quadrant of the abdomen or, in fact, any part of the abdomen (Winsor and Burch, 1946) produces an increase in brachial venous pressure In normal subjects the same compression causes the pressure to fall slightly or produces no change (Winsor and Burch, 1946) This test was applied to every subject included in the present investigation In the controls and in all patients otherwise diagnosed as having uncomplicated emphysema, abdominal compression did not cause appreciable change in brachial venous pressure (Table I) This included the seven patients who were considered not to have heart-failure because their circulation times were not prolonged, notwithstanding that they had obvious oedema In all classified as having emphysema heart-failure by other standards, brachial venous pressure rose abruptly when the abdomen was compressed The implication is that a positive venous pressure response of this kind is a valuable sign of right heart-failure, when the mere recording of peripheral venous pressure or the inspection of neck veins may be misleading Conversely, the absence of this response, so long as there is no unrelated obstructive lesion in the venous pathway concerned, excludes the presence of right heart-failure The qualitative difference between the permanently raised venous pressure of emphysema and that of right heart-failure means that they depend on different mechanisms From the previous consideration of these pressures it follows that whereas in emphysema the increase in venous pressure is actively determined (as by venoconstriction), in right heart-failure part at least of the increase in pressure is a passive sequel to a raised auricular pressure The passive pressure phenomenon has its equivalent in a retarded blood-flow, the active in an accelerated flow Mindful of the declining popularity of the theory of backward pressure (McMichael, 1938, 1946, Starr, Jeffers, and Meade, 1943, Warren and Stead, 1944) it is realized that active compensatory changes do occur to alter the dynamic quality of the circulation in heart-failure and that one effect of these will be to submerge the increment of pressure that has been produced as indicated The presumption is that the amount by which brachial venous pressure increases when the abdomen is compressed reflects the increment of pressure that is passively determined

The vital capacity in severe emphysema is reduced to a degree comparable to that in congestive failure caused by rheumatic or hypertensive heart disease and the symptom of effort dyspnoea is equally prominent The emphysematous patient, however, is not orthopnoeic and rarely becomes so in heart-failure, which, occurring as a direct consequence of emphysema, is selectively or dominantly failure of the right ventricle (Kountz, Alexander, and Prinzmetal, 1936) and the further reduction in vital capacity that accompanies it is small Crepitations or moist sounds can be heard over the lungs of many emphysematous patients with heart-failure, including some who recover These signs are usually attributed to failure of the left heart The lung to tongue time of these patients is not prolonged, more commonly it is less than in the controls In left ventricular failure from recognized causes, lung to tongue time is invariably prolonged (Fishberg, Hitzig, and King, 1932, Plotz, 1939) and vital capacity reduced (Blumgart, 1931), both greatly Left ventricular failure did supervene on the typical heart-failure of emphysema in two of the patients included in the present investigation They both died soon afterwards, but in the interval they became orthopnoeic and their lung to tongue times increased from 5 4 and 5 5 to 16 5 and 11 0 seconds respectively No attempt was made to record vital capacity in this ultimate phase, but in neither case did it appreciably exceed tidal air The further failure of the heart in one patient followed massive myocardial infarction The other had a terminal pneumonia, and post-mortem examination revealed that he had coronary arterial disease as well A third probably had failure of the whole heart from the beginning, he also was hypertensive This was the only one of these patients who was orthopnoeic when admitted to hospital, and the only one who had auricular fibrillation His lung to tongue time was 13 1 seconds (the mean for all patients with emphysema heart-failure was 6 8 seconds) and his vital capacity 20 per cent of its calculated normal value All three had crepitations, presumably caused by left ventricular failure, but other emphysematous patients with selective right heart-failure had equally pronounced crepitations certainly not caused in the same way Ordinarily orthopnoea which correlates with a prolonged lung to tongue time is an index of left heart-failure It probably has the same significance when it occurs with emphysema, irrespective of whether or not right heart-failure exists at the same time In either case the heart-failure is unlikely to be caused by emphysema alone

Summary

1 Thirty-seven patients with pulmonary emphysema, including 12 with congestive heart-failure, have been investigated with special reference to circulation time and peripheral venous pressure, corresponding records were made in 40 healthy controls of comparable age

2 In the presence of uncomplicated emphysema, lung to tongue and arm to tongue times were significantly less than in the controls and venous pressure was higher Arm to lung time did not differ significantly in the two groups

3 Irrespective of cause, congestive heart-failure implies a retardation of

blood-flow, and the heart-failure of emphysema is no exception Arm to lung and arm to tongue times were invariably prolonged relative to what these were in the emphysematous patient before the heart failed Statistically, the corresponding circulation times exceeded those of the healthy controls, but in the individual patient this was not necessarily so Prolonged circulation times could then be recognized only by a comparison of serial records

4 Peripheral venous pressure was, statistically, higher in emphysema heart-failure than in emphysema not so complicated, but an isolated brachial venous pressure, though obviously raised, could not be presumed necessarily to differentiate between the two The increased brachial venous pressure of heart-failure may, however, be distinguished by the further increase that can be caused by pressure on the abdomen with the hand

5 These observations are discussed in their relevance to the diagnosis of heart-failure supervening on emphysema

6 A prolonged lung to tongue circulation time is ordinarily an index of left heart-failure We have found nothing to suggest that its significance is different in the heart-failure of emphysema It may, additionally, imply that the heart-failure is not caused by emphysema alone

It is a pleasure to express my appreciation of Dr A Rae Gilchrist's encouragement to study the patients under his care and to acknowledge my indebtedness to his stimulating teaching I wish to thank Professor W Melville Arnott for his helpful criticism and Dr P E Brown for his part in checking the accuracy of the statistical tables

REFERENCES

Blumgart, H. L (1931) *Medicine*, **10**, 1
—— and Weiss, S (1927) *J Clin Invest* **4**, 555
Carr, D T., and Essex, H E (1946) *Amer Heart J* **31**, 53
Christie, R V (1934) *J Clin Invest* **13**, 295
—— (1944) *Brit Med J* **1**, 105 and 143
Cournand, A (1947) *Bull N Y Acad Med* **23**, 27
—— Richards, D W, and Darling, R C (1939) *Amer Rev Tuberc.* **40**, 487
Durant, T M (1946) *Clinics*, **5**, 167
Fishberg, A M (1944) *Heart Failure*, 4th ed, Philadelphia
—— Hitzig, W M, and King, F H (1932–3) *Proc. Soc Exp Biol N Y* **30**, 651
Hitzig, W M (1933–4) *Ibid* **31**, 935
—— (1942) *J Mt Sinai Hosp* **8**, 625
Holt, J P (1942–3) *Amer J Physiol* **139**, 208
Kaltreider, N L (1938) *International Clinics*, **4**, 221
Kountz, W B, and Alexander, H L (1934) *Medicine*, **13**, 251
—— —— and Prinzmetal, M (1936) *Amer Heart J* **11**, 163
—— Pearson, E F, and Koenig, K F (1932) *J Clin Invest* **11**, 1281
Lennox, W G, and Gibb, E L (1932) *Ibid* **11**, 1155
Lewis, Sir T (1930) *Brit Med J* **1**, 849
McMichael, J (1938) *Trans Med Chir Soc. Edin*, 1937–8, p 161 in *Edin Med J* **45**
—— (1946) *Schweiz med Wschr* **76**, 851 Abstract in *Brit Heart J* (1947), **9**, 70
Master, A M, Jaffe, H L, and Dack, S (1935) *Amer Heart J* **10**, 833
Moritz, F, and von Tabora, D (1909–10) *Dtsch Arch f klin Med* **98**, 475

Parkinson, J , and Hoyle, C (1937) *Quart J Med* N S **6**, 59
Pasteur, W (1885) *Lancet*, **2**, 524
Plotz, M. (1939–40) *Ann intern Med* **13**, 151
Randot, E (1898) *Gaz hebd d soc méd de Bordeaux*, **19**, 567, 579, and 590
Richards, D W (1945) *Fed Proc* **4**, 215
Ruskin, A , and Rockwell, P (1945) *Proc Soc Exp Biol N Y* **60**, 40
Starling, E H (1920) *Principles of Human Physiology*, 3rd ed , London
Starr, J , Jeffers, W A., and Meade, R H (1943) *Amer Heart J* **26**, 291
Tarr, L , Oppenheimer, B S , and Sager, R V (1933) *Ibid* **8**, 766
Warren, J V , and Stead, E A (1944) *Arch intern Med* **73**, 138
White, P D , and Brenner, O (1933) *New Eng J Med* **209**, 1261
Wiggers, C J (1940) *Physiology in Health and Disease*, 3rd ed Philadelphia
—— (1947) *Ann Rev Physiol* **9**, 273
Winsor, T , and Burch, G E (1946) *Amer Heart J* **31**, 387
Winternitz, M , Deutsch, J , and Brull, Z (1931) *Med Klin* **27**, 986

WILLIAM OSLER

By ROBERT HUTCHISON

In this the centenary year of Osler's birth, the Editors thought it proper that some appreciation of him should appear in the journal of which he was the principal founder They were kind enough to ask me to write it, and I readily agreed, all the more as I am now the sole survivor of the group who, under Osler's leadership, brought both the Association of Physicians and the *Quarterly Journal* into being I am acutely conscious, however, that it is difficult to say anything new about Osler in view of Harvey Cushing's monumental biography and the many tributes that appeared on the occasion of his seventieth birthday, at his death in 1919, and again quite recently on the occurrence of the centenary of his birth All I can hope to do is to give some personal impressions which may at least be of interest to a generation to whom he has become an almost legendary figure and who know him so to speak at second-hand, by what he did and wrote and not by what he was

I first saw him in 1897 on the occasion of the British Medical Association meeting at Montreal. It was the year of Queen Victoria's Diamond Jubilee when imperialism of the Kipling sort was at its height, and it was the first time the Association had met in one of the Dominions In Montreal, of course, Osler was on his native heath and undoubtedly, though not the President, he was the most prominent figure of the gathering He gave the Address in Medicine, and, suitably to the occasion, took 'British Medicine in Greater Britain' as his subject In the course of it, I remember, he described himself with great truth as 'a man whose affiliations are wide and his sympathies deep' After the meeting I travelled with John Thomson through some of the eastern states and in due course we came to Baltimore We took rooms at an hotel and at once proceeded to call upon Osler We found him lying on a sofa dictating to a stenographer, but he immediately put his work aside and with characteristic hospitality insisted on our giving up our rooms and coming to stay at his house This we did for two or three days and it was then that I first got to know him and was able to see something of his teaching and practice in ward rounds at the Johns Hopkins For the next four years I saw him fairly often on his almost annual visits to this country and was struck, as was everyone who had once met him, by his wonderful memory for faces and names and by the real interest he took in whatever one might be doing After 1904, when he came to Oxford as Regius, our association became closer It happened about this time that the idea was mooted—I think it originated with Archibald Garrod—of starting a new journal to be devoted solely to medicine in the strict sense and designed especially for physicians There were some who were rather critical, holding that there were already too many journals in existence and that

a new one might rob them of material Osler, however, was enthusiastically in favour of the project and a committee was formed to carry it into effect The members were Herringham, Hale White, Garrod, Rose Bradford, Rolleston, and myself, with Osler as Chairman Douglas Powell, then P R C P, attended sometimes in an official capacity, but was not a regular member It was difficult at first to find a name for the journal as so many suitable ones had already been pre-empted, but eventually someone, I forget now who, put forward the present title, which was at once adopted It was at one of our meetings that Osler suggested that it would be a good thing to start an Association of Physicians in this country as he had been impressed by the benefits of such a body in America Characteristically, he urged it more as a means of physicians getting to know one another than as an aid to the pooling of knowledge and experience, though he by no means belittled that function either The suggestion was agreed to unanimously, and it was decided that the journal should be the organ of the Association, and the committee then devoted itself to drawing up a constitution and rules for the new body, and both it and the *Journal* came into existence in 1907, Osler being undoubtedly the chief midwife of the twin birth He was also one of the Editors of the *Journal* from the start till his death, his colleagues being Bradford, Garrod, Rolleston, Hale White, and myself, and he contributed to the earlier numbers papers on such subjects as ochronosis, multiple hereditary telangiectases, and infective endocarditis

The above account by an eyewitness of Osler's activity in starting the Association of Physicians and the *Quarterly Journal* may be of interest to the younger generation, but it is difficult to convey any idea of his personal fascination to those who never met him Wide humanity, sympathy, and a total absence of what is called 'side' have often been mentioned as the chief elements in his charm and about these and his habitual good humour there can be no doubt I was interested to read, however, in a recent appreciation by Charles Singer,[1] that he considered that Osler was fundamentally melancholy, and I often had the same impression myself, in spite of his habitual gaiety Singer speculates as to the possibility of an early and unknown sorrow to account for this, but in a life so well documented as Osler's this is unlikely, indeed, until the tragedy of his son's death, he seems, like Mead, to have lived always 'in the full sunshine of life' It is more probable that a nature so sensitive as his could not escape from the sense of tears in mortal things and that his ears were always open to the 'sad, still music of humanity' His drooping moustache and down-turned corners of the mouth also imported a look of sadness to his face when in repose which may have been deceptive

During all his time at Oxford Osler had Clifford Allbutt as his 'opposite number' at Cambridge—his 'brother Reggie' as Osler used to like to call him, sometimes rather to Allbutt's annoyance I have often thought that it would have been interesting to have had parallel lives of the two in the manner of Plutarch They had much in common, but in some ways were strikingly different Both were consummate clinicians and, in addition, men of wide

[1] *Brit Med Journ* (1949), 2, 46

learning and classical culture, though there were some who thought Allbutt the better scholar Allbutt was essentially aristocratic with the air and aspect, it has been said, of an ambassador, Osler, as became his Canadian origin, was a true democrat Allbutt was dignified and rather reserved, Osler free and easy, forthcoming and effusive But why pursue the comparison? Both were very great men and this country was peculiarly fortunate in having them to represent medicine at the two older universities in the early years of this century

It has often been said that Osler had no enemy, and that is true, nobody could feel hostile to one so essentially friendly None the less there were a few who, oddly enough, did not feel altogether at ease with him I know that two of the little band who helped him in founding the *Journal* confessed, with regret, to such a feeling It is impossible to account for this There were certainly some who thought Osler almost 'too good to be true', and that such universal friendliness could not always be sincere, but in this I am sure they were unjust There were others, again, who did not always appreciate his particular brand of humour—impish, whimsical, even Rabelaisian at times, and with a tendency to show itself in practical jokes I have even heard it said that his disposition was almost *too* sweet and that a dash of cynicism would have improved it On the other hand, it may well have been that the few who found Osler antipathetic were simply, as the young people say now, 'not of the same wave-length' with him, certainly, to use another cliché of the moment, he could not have been 'allergic' to anyone Be all this as it may, to the great multitude of his friends and admirers on both sides of the Atlantic he was, indeed, the beloved physician, and as members of our calling tend to become more and more merely expert technicians it is improbable that we shall look upon his like again in another century

616 155 2–003 214

IDIOPATHIC THROMBOCYTOPENIC PURPURA[1]

By H N ROBSON

(From the Department of Medicine, University of Edinburgh)

The precise nature of the defect underlying the bleeding tendency in idiopathic thrombocytopenic purpura is still imperfectly understood It is now well established that the circulating platelets are reduced in number, an observation first made by Krauss (1883) and later by Denys (1887) Splenectomy, originally advocated by Kaznelson in 1916, results in amelioration, suggesting that the spleen may either destroy platelets or inhibit their production The theory of excessive destruction of platelets by the spleen and reticulo-endothelial system has many adherents (Wiseman, Doan, and Wilson, 1940) On the other hand, the idea that platelet formation is inhibited by an abnormal product of the spleen released into the blood is also favoured Following the description of the origin of platelets from megakaryocytes (Wright, 1906, 1910), Frank suggested in 1915 that there was reduced platelet production from the megakaryocytes and later (1925) attributed this to the influence of the spleen Apparent support to this view has been provided by reports that extracts of spleen from cases of idiopathic thrombocytopenic purpura caused reduction in platelet counts in the experimental animal (Troland and Lee, 1938) The production by the spleen of an inhibitor substance producing maturation arrest of megakaryocytes has been postulated again recently (Limarzi and Schleicher, 1940, Dameshek and Miller, 1946, Valentine, 1947, Diggs and Hewlett, 1948) There is, however, divergence of opinion on the evidence of such a maturation arrest, as adduced from cytological studies of megakaryocytes in the bone-marrow (Lawrence and Knutti, 1934, Wiseman, Doan, and Wilson, 1940) The basis of a further theory of the aetiology of idiopathic thrombocytopenic purpura is that the capillary endothelium is defective It has been suggested that excessive numbers of platelets are used up in plugging breaches in capillary walls (Tidy, 1926, Mackay, 1930) Macfarlane (1941) supported the concept of a defective capillary endothelium He observed by microscopy that the capillaries in this condition were distorted and failed to contract properly when ruptured In the hope of obtaining more precise evidence on the mechanism of bleeding in idiopathic thrombocytopenic purpura, it was decided to study the effects of splenectomy on the bleeding time, platelet count, and capillary resistance, and on the morphological characters of the megakaryocytes in the bone-marrow

Material

The subjects of the present study were patients undergoing treatment for idiopathic thrombocytopenic purpura in the Royal Infirmary and Western

[1] Received April 30, 1949

General Hospital, Edinburgh In addition, a number of patients suffering from other conditions were studied in order to control various aspects of the investigation The patients were classified in four groups, as follows

Group 1 *Cases of idiopathic thrombocytopenic purpura treated by splenectomy* This group comprised 10 cases, all presenting the clinical and haematological features which are considered diagnostic One patient had a normal bleeding time and capillary resistance before operation, but all other features conformed, and the response to splenectomy was typical

Group 2. *Cases of splenectomy for conditions other than idiopathic thrombocytopenic purpura* Fourteen cases in this group were further classified into three sub-groups as explained later

Group 3 *Cases undergoing operations other than splenectomy* Seven patients were studied, none of whom were anaemic or suffering from disease likely to cause haematological abnormalities One patient underwent two operations during the period of study

Group 4 *Cases of secondary purpura, not undergoing splenectomy* The bone-marrow was examined in three cases, where the thrombocytopenia was due to known toxic agents

The age and sex of the patients and details of diagnosis are given in Table I Platelet counts and measurements of bleeding time and capillary resistance were carried out before, during, and after operation In the cases of idiopathic thrombocytopenic purpura, long-term follow-up studies were made The megakaryocytes in bone-marrow obtained by sternal puncture were studied before and after operation Table I indicates which of these studies were carried out in each case, and thus the origin of the data presented

Methods

Peripheral platelet counts were done by the direct method in a counting chamber, the blood from a finger-prick being drawn into a red-cell pipette and diluted with 3 8 per cent sodium citrate solution The normal platelet count by this method ranges in our hands from 200,000 to 400,000 per c mm

Capillary resistance was estimated by the negative pressure method, using Searborough's (1941) modification of Dalldorf's method with the da Silva Mello instrument The suction cup was applied to three standard areas on the forearm, and the negative pressure maintained for 30 sec in each area Normally no haemorrhages occur with negative pressures below 250 mm of mercury To simplify the recording of results in tables, the capillary resistance has been indicated by a single number, which represents that negative pressure in mm of mercury which produced one or two petechiae in any of the standard areas

Bleeding time was estimated by the method of Duke (1915), the normal time being from two to five minutes When the bleeding time was very prolonged, and serial readings in fairly close succession were required, a fresh puncture was made, and two or three observations carried out simultaneously

Sternal puncture was performed according to the technique described by

Davidson (1941) The films were air-dried and stained with the May-Grunwald-Giemsa stain

Examination of smears of bone-marrow In each marrow smear 50 megakaryocytes were studied and described in detail as regards certain morphological

TABLE I

Cases studied in the Present Investigation showing Data used

Case number	Sex and age	Diagnosis	Peripheral blood studies: Before, during, and after operation	Peripheral blood studies: Follow-up	Megakaryocyte studies: Before operation	Megakaryocyte studies: After operation
			Group 1			
1	F 21	Idiopathic thrombocytopenic purpura		+		+
2	F 25	,,		+		+
3	F 23	,,	+	+		
4	F 50	,,		+	+	+
5	M 7	,,	+	+	+	+
6	F 5	,,		+		
7	F 14	,,		+	+	+
8	F 29	,,	+	+	+	+
9	F 5	,,		+		
10	F 47	,,	+	+	+	
11	M 30	,,	+	+	+	+
12	F 24	,,	+	+		
13	F 10	,,	+	+	+	
14	F 54	,,	+		+	
15	F 19	,,	+	+	+	+
16	F 23	,,		+	+	
17	F 14	,,	+	+	+	+
18	M 6	,,	+		+	+
19	F 32	,,	+			
			Group 2			
Sub-group (a)						
20	F 43	Gaucher's disease	+			
21	F 9	Splenic vein thrombosis	+		+	
22	F 16	,, ,,	+		+	+
23	M 32	Cirrhosis of liver	+			
24	F 12	,, ,,			+	+
Sub-group (b)						
25	M 33	Cirrhosis of liver	+		+	+
26	F 48	? Splenic leucopenia	+			
27	F 53	Cirrhosis of liver	+			
28	F 21	Haemolytic anaemia	+		+	
29	F 22	Aplastic anaemia	+		+	+
30	M 19	Cirrhosis of liver	+		+	+
Sub-group (c)						
31	F 14	Aplastic anaemia	+		+	
32	F 28	Aleukaemic leukaemia	+		+	+
33	M 23	Cirrhosis of liver	+		+	+
			Group 3			
34	F 57	Hypernephroma	+			
35	M 50	Peptic ulcer	+			
36	M 24	Tuberculous kidney	+		+	+
37	M 36	Peptic ulcer	+		+	+
38	M 54	Carcinoma of colon	+		+	+
39	F 27	Tuberculous kidney	+		+	+
40	F 37	,, ,,	+		+	+
			Group 4			
41	M 12	Sulphonamide toxicity			+	
42	F 45	Phenolphthalein toxicity			+	
43	F 61	Gold toxicity			+	

+ Indicates that the appropriate study was undertaken and the data used

features which are tabulated later Platelet formation was accepted as being present only when it was reasonably certain that the appearance was not being produced by superimposition or juxtaposition of platelets on the megakaryocyte Each specimen of marrow was examined by two observers working independently and using whenever possible different smears from the same sternal puncture Each used the same microscope throughout, with standard illumination In addition, counts of 50 cells were made, and classified on a simple morphological basis, following the definitions and descriptions used by Dameshek and Miller (1946)

Results

Studies of peripheral blood in idiopathic thrombocytopenic purpura Table II summarizes the results of the peripheral blood studies in the patients with idiopathic thrombocytopenic purpura The results are best described in three phases

1 *Before operation* the results were typical of idiopathic thrombocytopenic purpura The bleeding time was prolonged, the platelet count low, and the capillary resistance diminished

2 *From skin incision to ligation of the splenic pedicle* Observations were begun at the moment the skin incision was made The results are in agreement with those obtained before operation and show no gross changes The observations were repeated as near as possible to the moment when the splenic pedicle was ligated At this time no evident change had taken place in the capillary resistance or platelet counts, but in all but two cases a reduction in the bleeding time was already apparent, and in three patients (Cases 5, 13, and 19) it had actually fallen to normal levels

3 *After ligation of the splenic pedicle* Repeated observations were made at short intervals throughout the remainder of the operation, at longer intervals during the following two days, and thereafter daily until discharge from hospital

The following results were obtained The bleeding time continued to fall, reaching normal levels in 12 to 100 min (average 48 min) from the time of the initial skin incision Thereafter it continued to fall in every case, reaching a very low level (about 1 min in all but two cases) The lowest level was recorded in from a half to 36 hr after the skin incision (average 9½ hr) The capillary resistance began to improve, reaching normal levels in 12 to 360 min (average 270 min), and thereafter continued to increase, so that after 1 to 192 hr (average 61 hr) a negative pressure of at least 500 mm of mercury was usually necessary to produce one or more petechiae It is appreciated that capillary resistance estimations are subject to many factors of error (Munro, Lazarus, and Bell, 1947), but changes of the order here recorded are thought to have significance The apparatus employed provided a maximum negative pressure of 500 mm of mercury, and in many cases this was insufficient to produce petechiae The platelet counts altered much more slowly, usually reaching normal levels within a half to four days Eventually, in all but three cases

TABLE II

Peripheral Blood Observations before, during, and after Splenectomy in cases of Idiopathic Thrombocytopenic Purpura

	Before operation (Observations were made in the 7 days before operation)				During operation							After operation								
		Range of results			At time of skin incision				At time of ligation of pedicle			Bleeding time			Capillary resistance			Platelets		
Case number	Number of observations	Bleeding time (min)	Capillary resistance (mm Hg negative)	Platelets (thousands)	Bleeding time (min)	Capillary resistance (mm Hg negative)	Platelets (thousands)	Time from skin incision to ligation of pedicle (min)	Bleeding time (min)	Capillary resistance (mm Hg negative)	Platelets (thousands)	Time to reach normal (min)	Lowest level (min)	Time to reach lowest level (hr)	Time to reach normal (min)	Highest level (mm Hg negative)	Time to reach highest level (hr)	Time to reach normal (hr)	Highest level (thousands)	Time to reach highest level (days)
3	3	17 to 22		35 to 60	20		80	12	15		50	100	2	21				16	1,440	8
5	7	12 to 19	150 to 175	35 to 45	12	150	30	30	4	200	45	25	1	11	90	500	72	14	880	2
8	3	17 to 20		15 to 25	15		20	16	12		30	60	1	30				14	1,000	6
10	5	7 to 20	200 to 220	10 to 20	12	200	10	11	12	200	10	90	1	36	30	500	10	24	840	14
11	1	12	150	25	11	150	20	14	8	200		35	1	11	45	500	6	84	600	8
12	4	3 to 5	300	30 to 50	4	250	30	15	11	250	12		1	7		500	15	72	610	12
13	4	10 to 18	150 to 200	10 to 35	10	150		16	3	200	15	12	1	0 5	22	500	20	120	380	19
14	2	19 to 35	150	5	30	150	10	33	6	150	15	40	5	1	60	400	192	480	210	22
15	4	14 to 18	200 to 250	10 to 40	12	200	15	12	10	250	10		1	0 5	12	500	1		80	13
17	3	12 to 20	150 to 175	17 to 40	13	150	20	29	12	150	50	60	1	11	360	300	11	16	1,380	9
18	1	10	150	10	10	150	10	20	8	150	15	35	1	9	144	500	120	8	1,970	7
19	4	20 to 25	100 to 150	10 to 50	23	150	21	20	4	150	45	20	1	8	360	425	168	24	1,000	8

(Cases 13, 14, and 15), the platelet counts rose far above the normal level, reaching a maximum (average 866,000 per c mm) in two to 22 days (average 11 days).

Studies of peripheral blood in patients undergoing splenectomy for conditions other than idiopathic thrombocytopenic purpura It is obvious that some of the observations recorded above might have resulted from splenectomy under any conditions, and do not necessarily indicate behaviour specific to idiopathic thrombocytopenic purpura Thirteen patients undergoing splenectomy for other conditions were therefore studied in a similar manner The results are summarized in Table III

The results of platelet counts make it possible to divide the 13 patients into the following sub-groups—four cases in which there was a frank thrombocytopenia before splenectomy, six cases in which pre-operative counts shewed a moderate or transient thrombocytopenia, or were within normal limits, and three cases of thrombocytopenia which continued after splenectomy In the first two sub-groups splenectomy was followed by striking increases in platelet counts closely resembling those found in the cases of idiopathic thrombocytopenic purpura, and in the first sub-group the time that elapsed before normal platelet counts were obtained was of the same order (average two days) as in idiopathic thrombocytopenic purpura In the third sub-group splenectomy resulted in very small increases in platelet counts and normal levels were not reached at any time

At operation reduction in bleeding time had occurred by the time that the splenic pedicle was ligated, except in three cases (Cases 23, 26, and 29) In eight cases unusually short bleeding times were subsequently observed The striking feature, however, was that the reduction in bleeding time to its shortest took place more quickly on the whole than in idiopathic thrombocytopenic purpura, except in the cases in which there was pronounced pre-operative thrombocytopenia (the first sub-group) This point is dealt with in the discussion

In three of the 12 patients in whom capillary resistance estimations were made it was diminished before splenectomy, and in these operation resulted in improvement In the remaining nine cases in which the pre-operative readings were within normal limits, the resistance increased in all, and to very high levels in five The times taken to develop maximum resistance appeared to be less than those generally observed in the cases of idiopathic thrombocytopenic purpura except for the cases in the first sub-group where there was marked pre-operative thrombocytopenia

Studies of peripheral blood in patients undergoing other operations The observations recorded above might be non-specific results of any abdominal operation, unrelated to thrombocytopenic purpura or to splenectomy In order to test this possibility, comparable studies were carried out on seven patients undergoing other operations The results are summarized in Table IV, and show consistent reductions in bleeding time, though these are slight in extent because the initial values were normal The capillary resistance became increased to high or very high levels as the result of operation in *all cases* Post-operative

TABLE III

Peripheral Blood Observations before, during, and after Splenectomy for Conditions other than Idiopathic Thrombocytopenic Purpura

Case number	Number of observations	Before operation (Observations were made in the 7 days before operation) — Range of results: Bleeding time (min)	Capillary resistance (mm Hg negative)	Platelets (thousands)	During operation — At time of skin incision: Bleeding time (min)	Capillary resistance (mm Hg negative)	Platelets (thousands)	Time of skin incision to ligation of pedicle (min)	At time of ligation of pedicle: Bleeding time (min)	Capillary resistance (mm Hg negative)	Platelets (thousands)	After operation — Bleeding time: Time to reach normal (min)	Lowest level (min)	Time to reach lowest level (hr)	Capillary resistance: Time to reach normal (min)	Highest level (mm Hg negative)	Time to reach highest level (hr)	Platelets: Time to reach normal (hr)	Highest level (thousands)	Time to reach highest level (days)
Sub group (a) Thrombocytopenia—platelet response to splenectomy																				
20	3	8 to 20	200 to 300	50 to 75	14		50	32	4			30	1	72		350	240	60	450	14
21	2	8 to 10	300 to 350	25 to 50	0	250	60	22	6	250	02	60	2	11		500	24	48	1,040	11
22	2	3 to 6	300 to 350	60 to 150	6	350	40	26	3	370	102	20	1	24		450	72	36	575	10
23	3	2 to 4		80 to 170	2	300	60	37	2	300	170		1	24				48	730	15
Sub group (b) Moderate or transient thrombocytopenia—platelet response to splenectomy																				
25	1	5	300	205	5	250	85	38	3	350	110		2	10		400	10		525	14
26	3	2	250 to 350	120 to 197	2	300	130	8	2	300	202		1	0 5		500	24		525	10
27	1	3	350	227	4	350	160	34	1	400	440		1	0 5		400	1		1,340	13
28	2	2 to 5	300 to 350	215 to 275	4	200	225	30	2	350	200		1	1 5	30	350	0 5		1,150	15
29	2	2 to 4	300 to 350	270 to 320	2	350	220	10	2	400	284		1	1		500	2		1,030	29
30	2	2 to 3	300	220 to 240	2	300	200	25	1	350	275		1	0 5		500	2		485	6
Sub group (c) Thrombocytopenia—no effective platelet response to splenectomy																				
31	4	20 to 25	150 to 200	10 to 20	20	200	10	15	8	200	102		8	0 25	20	500	6		55	4
32	2	6 to 10	150 to 200	55 to 100	10	150	40	20	4	200	35	20	2	1	60	250	1		130	14
33	3	13 to 15	250 to 350	30 to 55	12	350	30	21	5	350	40	20	3	1		500	1		110	16

TABLE IV

Peripheral Blood Observations in Operations other than Splenectomy

Case number	Operation	Before operation: Day before: Bleeding time (min.)	Day before: Capillary resistance (mm. Hg negative)	Day before: Platelets (thousands)	At time of skin incision: Bleeding time (min.)	At time of skin incision: Capillary resistance (mm. Hg negative)	At time of skin incision: Platelets (thousands)	During and after operation: Bleeding time: Lowest level (min.)	Bleeding time: Time to reach lowest level (min.)	Capillary resistance: Highest level (mm. Hg negative)	Capillary resistance: Time to reach highest level (hr.)	Platelets: Highest level (thousands)	Platelets: Time to reach highest level (days)
34	Nephrectomy	2	250	294	1	300	320	No change		400	3	450	11
35	Gastrectomy	2	300	100	3	350	350	1.5	40	500	1.25	580	1
36	Nephrectomy	3	350	214	2	350	180	1	24	500	0.75	230	7
37	Gastro enterostomy	2	350	310	2	300	340	1	15	500	1	385	6
38 *a*	Colostomy	5	350	201	4	350	210	2	15	450	0.5	350	9
b	Colectomy	3	250	200	4	250	200	1	56	475	1.5	260	3
39	Nephrectomy	2	350	206	2	350	216	1	30	500	0.75	264	8
40	Nephrectomy	3	300	210	3	275	220	1	45	500	0.5	390	9

rises in platelet counts occurred, but were much smaller than those which followed the operation of splenectomy The reductions in bleeding time and the rises in capillary resistance took place rapidly as compared with most of the cases of idiopathic thrombocytopenic purpura

'Follow-up' studies of peripheral blood in idiopathic thrombocytopenic purpura after splenectomy In 16 of the 19 cases recorded, observations were made after discharge from hospital, at three months after splenectomy, in the majority of cases, and again at varying periods from half to 14 years The results are summarized in Table V Fourteen of the 16 patients had remained clinically well

TABLE V

Follow-up Results in Cases of Idiopathic Thrombocytopenic Purpura

	Three months after operation					Follow up: Haematological				Follow up: Clinical
Case number	Bleeding time (min)	Capillary resistance (mm Hg negative)	Platelets (thousands)	Comment	Years after splenectomy	Bleeding time (min)	Capillary resistance (mm Hg negative)	Platelets (thousands)	Comment	
1				?	14	8	200	40	Abnormal	Bleeding Purpura Was well for 7 yrs.
2	2		480	?	10	3	400	340	Normal	Well.
3	2		340	?	9	6	150	301	Abnormal	Well.
4	27	200	35	Abnormal	6	3	200	125	Abnormal	Well
5	2	450	65	Abnormal	4	8	350	140	Abnormal	Well.
6				?	3	3	300	240	Normal	Well
7	12		55	Abnormal	3	9	150	45	Abnormal	Well.
8	3		100	Abnormal	3	2	150	30	Abnormal	Well
9	3		110	Abnormal	2	3		22	Abnormal	Well.
10	4	500	305	Normal	1	2	350	410	Normal	Well.
11	6	300	100	Abnormal	2	4	250	190	Abnormal	Well
12	1	400	420	Normal	2	3	300	290	Normal	Well
13	3	300	400	Normal	2	5	250	305	Normal	Well
15	15	150	35	Abnormal	1	18	150	20	Abnormal	Bleeding Purpura
16	2		117	Abnormal	1	3	200	55	Abnormal	Well
17	2	250	400	Normal	½	2	350	200	Normal	Well

without haemorrhagic manifestations, this despite the fact that only six were able to show entirely normal results in all three tests—bleeding time, capillary resistance, and platelet count It is evident that there had been a considerable reversion to haematological abnormality after the dramatic improvement immediately after splenectomy Yet a recurrence of bleeding was noted in only two of the 16 cases Of the 12 cases tested three months after splenectomy, eight already showed one or more abnormal results by the tests, and no evident subsequent improvement On the other hand, the normal results achieved by the remaining four cases at the end of three months were thereafter sustained These results show that in idiopathic thrombocytopenic purpura an assessment of the final effects of splenectomy cannot accurately be made until at least three months after operation

These results confirm a previous observation (Bedson, 1922) that there is no apparent direct relation between the level of circulating platelets and the bleeding time Tables II and III show that striking reduction in bleeding time

took place during splenectomy before there was any rise in platelet counts Again in four of the cases recorded in Table V (Cases 5, 8, 9, and 16), low platelet counts were recorded three months after splenectomy, yet the bleeding times were within normal limits This suggests that some other factor besides reduced circulating platelets has an influence on bleeding in idiopathic thrombocytopenic purpura, this question is considered in the discussion The results also indicate that there is no constant relation between platelet counts and capillary resistance Marked increase in capillary resistance was observed during operation before any rise in platelet levels, and also occurred even when the post-operative platelet increase was slight (for example, the third sub-group of Table III and the cases in Table IV) This dissociation has also been reported by Elliot (1938), and Aggeler, Howard, and Lucia (1946)

Studies of megakaryocytes in idiopathic thrombocytopenic purpura The results of the study of megakaryocyte characteristics before and after splenectomy in idiopathic thrombocytopenic purpura are shown in Table VI. The figures show the average percentage incidence of each characteristic in megakaryocytes derived from 14 pre-operative and 18 post-operative bone-marrow examinations in cases of idiopathic thrombocytopenic purpura The results of the two observers are recorded separately Changes after splenectomy which were noted by both observers to a statistically significant extent ($P<0\ 01$) were a marked increase in the percentage of cells showing platelet formation, an increase in the percentage of cells with 'intermediate' staining of the cytoplasm, with reduction in both basophilic and eosinophilic forms, and an increase in cells having coarse granularity of the cytoplasm In addition, both observers recorded two further changes, but only one observer's results were statistically significant, namely, an increase in cells with three-lobed nuclei, with correspondingly fewer showing more elaborate lobulation, and an increase of cells having nuclei which were small in relation to the size of the cell There were no consistent or significant alterations in nuclear shape or in the shape and size of the cells The results of the two observers, both experienced in examining bone-marrow smears, differ in several respects This illustrates the danger of drawing conclusions from the observations of only one person On the other hand, when both record a statistically significant change, the result may be accepted with a high degree of confidence

Studies of megakaryocytes in other conditions Exactly similar studies were made of the megakaryocytes in the bone-marrow of 10 patients before and seven after splenectomy for conditions other than idiopathic thrombocytopenic purpura (Group 2, Table I) These cases fell into three sub-groups as described on p 284 The salient results only in the first and third sub-groups are shown in Table VII In addition the main results are given of similar observations made on five patients undergoing abdominal operations other than splenectomy, and on three cases of thrombocytopenia due to known toxic agents The numbers in each of the categories in this Table are too small for statistical treatment, nevertheless there emerge several results, agreed on by both observers Splenectomy was followed by an increase in platelet formation in the cases of the first

TABLE VI

Megakaryocyte Characteristics in Idiopathic Thrombocytopenic Purpura before and after Splenectomy

Comparison of results of two observers

	Observer 1 (H N R)		*Observer 2 (R H.G)*	
	Before	*After*	*Before*	*After*
	Average percentages			
Nuclear shape				
round	2 9	5 6	4 6	5 1
lobular	83 8	83 9	90 0	87·4
irregular	13 3	10 5	5 4	7 5
	P = 0 01 (approx.)		P = >0 2	
Cell size *				
large	12 9	11 6	12 0	11 5
medium	71 8	73 4	72 1	74 1
small	15 3	15 0	15 9	14 4
	P = >0 95		P = >0 95	
Cell shape				
round	55 0	55 9	66 7	60 5
irregular	45 0	44 1	33 3	39 5
	P = >0 7		P = 0 01 (approx)	
Platelet formation	1 9	11 2	0 14	9 2
	P = <0 001		P = <0 001	
Nucleus cell ratio				
1 3	55 1	59 3	34 9	53 5
1 2	31 6	31 7	42 1	31 1
2 3	13 3	9 0	23 0	15 4
	P = 0 02 (approx)		P = <0 001	
Number of lobes				
1	8 6	8 6	10 3	11 7
2	20 3	20 3	26 3	23 1
3	21 4	25 6	23 9	31 4
4	19 6	18 3	17 7	18 3
5	15 0	12 4	11 7	8 6
6	7 6	7 4	4 8	3 7
7	3 1	4 1	2 3	0 6
8 or more	4 4	3 3	3 0	2 6
	P = >0 3		P = <0·05	
Mean number of lobes	3 73	3 63	3 35	3 07
	t = 1 14		t = 3 30	
	P = 0 25 (approx)		P = 0 001 (approx)	
Cytoplasm colour				
basophil	10 4	7 7	8 9	6·1
intermediate	73 9	84 5	74 4	85 4
eosinophil	15 7	7 8	16 7	8 5
	P = <0 001		P = <0 001	
Cytoplasm granularity				
nil	3 6	1 8	1 1	2 2
slight	22 6	17 7	17·0	14 7
medium	53 1	56 8	78·0	74 4
coarse	20 7	23 7	3 9	8 7
	P = 0 01 (approx.)		P = <0 001	

Before—14 smears = 700 megakaryocytes.
After —18 smears = 900 megakaryocytes

* large — greater than 56 μ
medium — between 28 μ and 56 μ
small — less than 28 μ
These diameters were judged by comparison with the diameter of a red cell

Table VII

Megakaryocyte Characteristics in Cases of Splenectomy for Conditions other than Idiopathic Thrombocytopenic Purpura, and in Other Abdominal Operations

Average percentages

	Observer 1 (H N R)							*Observer 2 (R H G)*						
	Splenectomy for other than idiopathic thrombocytopenic purpura				*Operations other than splenectomy*		*Toxic purpura*	*Splenectomy for other than idiopathic thrombocytopenic purpura*				*Operations other than splenectomy*		*Toxic purpura*
	Sub group (a)		*Sub-group (c)*					*Sub-group (a)*		*Sub group (c)*				
Number of cases	3	2	3	2	5	5	3	3	2	3	2	5	5	3
	Before	*After*	*Before*	*After*	*Before*	*After*		*Before*	*After*	*Before*	*After*	*Before*	*After*	
Cell size														
large	13	17	4	13	8	7	21	12	19	10	17	14	14	24
medium	74	71	73	70	86	84	77	82	77	75	77	75	73	68
small	13	12	23	17	6	9	2	6	4	15	6	11	13	8
Platelet formation	5	13	0	1	0	0	0	4	7	0	0	1	1	0
Cytoplasm colour														
basophil	10	10	12	5	6	5	28	24	16	43	8	10	20	24
intermediate	77	86	75	50	88	90	67	72	81	57	55	77	77	74
eosinophil	13	4	13	45	6	5	5	4	3	0	37	13	3	2
Cytoplasm granularity														
nil	2	1	1	0	0	0	0	10	7	23	17	2	5	14
slight	23	16	29	25	14	13	32	19	20	27	29	22	13	25
medium	62	64	68	72	65	62	63	52	49	46	47	69	65	55
coarse	13	19	2	3	21	25	5	19	24	4	7	7	17	6

sub-group where the operation resulted in an increase in circulating platelets In the cases in the third sub-group where there was no such increase in platelets, the megakaryocytes showed no evidence of platelet formation before operation and little or none after No platelet formation was observed in cases of toxic purpura Both observers agree, though at different levels, that platelet formation was more evident in the pre-operative marrows of haematologically normal cases undergoing other abdominal operations than it was in the cases of idiopathic thrombocytopenic purpura before splenectomy (Table VI) It is therefore shown that, by these standards at least, platelet production in untreated idiopathic thrombocytopenic purpura is diminished as compared with normal. As in the cases of true idiopathic thrombocytopenic purpura, splenectomy in the first sub-group was followed by an apparent increase in cells with coarse granular cytoplasm which showed an intermediate staining reaction Both observers are agreed that in cases of thrombocytopenia that did not respond to splenectomy, there was a striking post-operative increase in the number of megakaryocytes with eosinophil cytoplasm The possible significance of this is intriguing, but is beyond the scope of the present paper Splenectomy and other operations in these groups of cases produced no apparent change in nuclear shape or lobulation, or in the shape of the cells The figures relating to these characters have been omitted from Table VII in the interests of brevity

Morphology of megakaryocytes in idiopathic thrombocytopenic purpura The immature megakaryocyte, or megakaryoblast, is a relatively small cell with a single round nucleus and scanty basophil cytoplasm The mature cell is large, has a multi-lobed nucleus, and abundant granular intermediate-staining cytoplasm It has been postulated that in idiopathic thrombocytopenic purpura there is an arrest in the normal maturation of megakaryocytes, an arrest which might be released by removal of the spleen If such a hypothesis were correct, splenectomy would have been expected to result in many changes in the cell characteristics, such as an increase in cell size, increased lobulation of the nucleus, and reduction in the numbers of cells with non-granular basophil cytoplasm Few of the expected changes were in fact found In order to furnish additional evidence the megakaryocytes were examined and classified according to descriptions given by Dameshek and Miller (1946) The cases were grouped in the same way as previously described and the results are shown in Table VIII These figures showed no evidence of an increase in primitive forms (megakaryoblasts and promegakaryocytes) in idiopathic thrombocytopenic purpura before operation, as compared with the other conditions studied Nor was there any consistent evidence that removal of the spleen promoted development from immature forms

The outstanding feature of the present study is that platelet formation has been shown to be much reduced in idiopathic thrombocytopenic purpura as compared with normal, and that splenectomy causes a considerable increase Furthermore, this increased platelet formation takes place in a megakaryocyte population which is little altered morphologically by splenectomy It is con-

TABLE VIII

Morphological Classification of Megakaryocytes in the Groups Studied

(Average percentages—50 cells counted in each case)

Observer	Number of smears	Megakaryoblast and promegakaryocyte		Lymphoid forms		Mature megakaryocytes		Degenerated forms		Naked nuclei met with in count of 50 megakaryocytes	
		H.N R	R H G	H N R	R H G	H N R	R H G	H.N R	R H G	H.N.R	R.H G
Idiopathic thrombocytopenic purpura											
Pre operative	14	2	5	5	2	77	72	16	21	17	16
Post-operative	18	2	4	2	1	80	70	16	16	17	17
Splenectomy in other conditions											
sub group (*a*) pre operative	3	6	10	3	2	80	82	11	6	15	10
post-operative	2	8	9	4	2	76	81	12	8	13	7
sub group (*b*) pre operative	4	14	12	2	0	72	78	12	10	16	14
post operative	3	12	11	2	1	76	82	10	6	14	13
sub group (*c*) pre operative	3	5	8	1	0	68	63	26	29	17	14
post-operative	3	2	5	3	0	65	59	29	35	25	30
Other abdominal operations and normal controls											
Pre operative*	7	2	9	4	0	76	64	19	27	13	9
Post-operative	5	2	8	3	1	84	81	12	10	10	11
Toxic purpura	3	0	15	3	2	66	66	22	17	25	19

* Figures from two normal subjects, not undergoing operation, are included in these results

sidered that the changes in granularity and colour are natural accompaniments of platelet formation No evidence has been found in untreated idiopathic thrombocytopenic purpura of a maturation arrest of megakaryocytes at a primitive stage No attempt has been made in the present study to make precise numerical counts of the megakaryocytes, because the accuracy of such counts was considered doubtful The impression was that the numbers of megakaryocytes in untreated idiopathic thrombocytopenic purpura were either normal or increased, which is in agreement with the observations of other writers The conclusion from these morphological studies is that the appearances seen in untreated idiopathic thrombocytopenic purpura are consistent with a simple failure in platelet formation from an otherwise normal megakaryocyte population

Discussion

Effects of splenectomy on bleeding These studies show that splenectomy in idiopathic thrombocytopenic purpura results consistently in a rapid reduction in bleeding time and an increase in capillary resistance, but the changes do not indicate a cure of the essential disorder in idiopathic thrombocytopenic purpura, since they occur long before the circulating platelets show any important increase in numbers, and, moreover, are not a specific feature of the disease As the data in Table III show, a rapid reduction in bleeding time and increase in capillary resistance regularly follows splenectomy for other conditions, furthermore, these changes are not even a specific effect of splenectomy since they have been regularly observed after other abdominal operations (Table IV) Clearly, in idiopathic thrombocytopenic purpura, the *immediate* effects of splenectomy on bleeding time and capillary resistance are not a primary consequence of removing the influence of the spleen, since an improvement in the bleeding time is usually observed while the operation is actually in progress, at the time of ligation of the splenic pedicle (Tables II and III) It appears that any abdominal operation has a profound and almost immediate effect on the reactions of the capillaries and their liability to bleed, the anaesthetic, or the trauma of the operation (and the latter seems the more likely), causes an increase in capillary resistance and a reduction in bleeding time This has importance for the purpose of the present paper, namely, to contribute to an understanding of the essential disorder in idiopathic thrombocytopenic purpura, because there is a striking difference in speed of this general reaction of the capillaries to bodily injury in cases with thrombocytopenia, as compared with controls Laparotomy for other diseases (Table IV), and for splenectomy in cases without pronounced thrombocytopenia (Table III, the second sub-group) results in a fall in bleeding time that reaches its lowest level in a matter of an hour or less In idiopathic thrombocytopenic purpura, by contrast, the fall in bleeding time is gradual and does not usually reach its lowest level until some time later (average 9½ hours from the beginning of the operation) Moreover, a similar delay in the fall in bleeding time was also observed in other cases where an initial pronounced thrombocytopenia responded to splenectomy

(Table III, the first sub-group). At first sight this phenomenon might be thought to be due to the time taken for a sufficient number of circulating platelets to appear after removal of the spleen, their appearance having the effect of reinforcing the general reaction of the capillaries to bodily injury Such a simple explanation is not justified by the facts, for in 10 out of 15 cases (Tables II and III, the first sub-group), normal platelet counts were not achieved until after the bleeding time had reached its lowest level It might be argued that every available platelet was being used to maintain the capillaries, so that the numbers of circulating platelets continued to be low, despite an effective increase in 'platelet strength' immediately following splenectomy Such an explanation appears to be ruled out by the observation that the improvement in bleeding time was rapid and transient in cases with low platelet counts which did not ultimately respond to splenectomy (Table II, Case 15, and Table III, the third sub-group) In such cases the thrombocytopenia was presumably due to causes other than the influence of the spleen It therefore appears that the malevolent influence of the spleen in idiopathic thrombocytopenic purpura affects not only the numbers of circulating platelets, but also inhibits the rapid reaction of the capillaries to bodily injury

Effects of splenectomy on circulating platelets It is now accepted that splenectomy in idiopathic thrombocytopenic purpura results in ultimate improvement in the majority of cases The observations here presented are in agreement with this view, but they show at the same time certain characteristics of this improvement that may help to throw light on the fundamental mechanism involved A crucial point in the evidence is the effect, if any, of splenectomy on the production of platelets by the megakaryocytes in the bone-marrow The main conclusions from the cytological studies of bone-marrow here reported are that in untreated idiopathic thrombocytopenic purpura the numbers of megakaryocytes are normal or increased with low production of platelets, that their cytology shows little evidence of a 'maturation arrest' at an early stage, that such cytological changes as follow splenectomy in granularity and staining of the cytoplasm are best explained as an expression of impending platelet production, and that splenectomy is followed by a pronounced and clear-cut increase in platelet production In the light of this evidence, the various theories of the nature of the disorder in idiopathic thrombocytopenic purpura which were mentioned in the introduction can be considered It has been suggested that low platelet counts in idiopathic thrombocytopenic purpura are to be explained by excessive destruction of platelets by the spleen. One would then expect to find evidence of increased platelet formation in the bone-marrow, like the reaction of the bone-marrow in haemolytic anaemia, together with an immediate increase in circulating platelets after splenectomy The studies of bone-marrow here presented have shown, rather, a reduced production of platelets in untreated idiopathic thrombocytopenic purpura It has also been shown that after splenectomy the numbers of platelets in circulation do not reach normal levels for several days It is concluded that the evidence is against the theory of excessive platelet destruction It has been suggested that the

spleen produces a humoral factor which inhibits platelet production The thrombocytopenia characteristic of the disease and the slow return of circulating platelets to normal levels after splenectomy are entirely consistent with this theory The studies of bone-marrow here reported show that there is a 'hold-up' in the final stage of platelet formation from megakaryocytes It has been suggested that defective capillary endothelium is the underlying fault in idiopathic thrombocytopenic purpura The present evidence also lends support to this theory It was argued earlier in this discussion that in idiopathic thrombocytopenic purpura the capillaries do not respond normally to bodily injury It therefore appears that in untreated idiopathic thrombocytopenic purpura, in addition to reduced numbers of circulating platelets, there is an abnormal condition of the capillaries What then, in the light of this evidence, is the most probable explanation of the part played by the spleen in idiopathic thrombocytopenic purpura?

Influence of the spleen in idiopathic thrombocytopenic purpura The megakaryocyte is believed to develop extravascularly (Doan, Cunningham, and Sabin, 1925, Sabin, Miller, Smithburn, Thomas, and Hummel, 1936), and it seems likely that the whole or part of the cell has to penetrate the intersinusoidal capillary wall in order to deliver platelets into the blood-stream (Wright, 1910) It has even been suggested that the delivery of platelets from the cytoplasm of megakaryocytes depends on the action of plasma on the cytoplasm (Cesaris-Demel, 1929) Alterations in the state of the capillaries in the bone-marrow might therefore affect the delivery of platelets Evidence has here been adduced of a capillary defect in idiopathic thrombocytopenic purpura, and it is therefore suggested that the platelet deficiency is due to a failure in the delivery of platelets from otherwise normal megakaryocytes, because of some alteration in the capillary wall which prevents their entry into the blood-stream It is postulated that the essential disorder in idiopathic thrombocytopenic purpura is the production by the reticulo-endothelial system of some factor liberated into the blood which exerts its primary influence on the capillaries The factor might either be an abnormal product peculiar to idiopathic thrombocytopenic purpura, or more likely, an excessive production of some normal internal secretion of the spleen This latter idea is supported by the 'non-specific' rise in circulating platelets that follows splenectomy under any conditions (Table III, the second sub-group), in contrast to the absence of any important increase after other operations (Table IV) The same factor may be at work in other types of thrombocytopenia responding to splenectomy by an increase in circulating platelets (Table III, the first sub-group) The existence of such a factor is suggested by the results of work on splenic extracts (Troland and Lee, 1938, Ungar, 1946) The action of this capillary-influencing factor will explain the prolonged bleeding time, the reduced capillary resistance, and the impaired delivery of platelets from the bone-marrow Removal of the spleen, which constitutes a large part of the reticulo-endothelial system, reduces the output of this factor and alleviates these disorders This hypothesis will explain why it is that in idiopathic thrombocytopenic purpura after splenectomy platelet

counts, bleeding times, and capillary resistance may initially show dramatic changes to supra-normal levels, but some months later are frequently found to have reverted to abnormal levels These subsequent abnormalities are presumably due to the action of the factor liberated by other parts of the reticulo endothelial system, which may, after a period of months, achieve some compensatory increase in production The reported beneficial effects of the removal of spleniculi in cases where splenectomy has failed (Curtis and Moritz, 1946), lend support to this contention The theory is put forward that splenectomy can be a successful therapeutic measure because it removes the most potent source of this factor The success or failure of the operation depends on whether the concentration of this factor in the blood is thereby reduced below the threshold necessary to cause serious derangement of capillary function

Summary

1 Nineteen cases of idiopathic thrombocytopenic purpura have been investigated with regard to changes in bleeding time, capillary resistance, and platelet counts, before, during, and after splenectomy

Similar observations were made on a control series of 13 patients on whom splenectomy was carried out for other conditions, and seven patients undergoing other abdominal operations The megakaryocytes in the bone-marrow were studied before and after operation

2 It has been shown that the operation of splenectomy in cases of idiopathic thrombocytopenic purpura is associated with a sequence of changes in bleeding time, capillary resistance, and platelet counts, the results of observations on the control groups indicate that these changes are brought about initially by a non-specific effect of operative interference, followed by the effect of the removal of the spleen itself

3 In cases of idiopathic thrombocytopenic purpura, an assessment of the final effects of splenectomy cannot accurately be made until at least three months after operation

4 No evidence has been found of an increase in primitive forms of megakaryocytes in the bone-marrow in cases of idiopathic thrombocytopenia purpura There is, however, a diminished formation of platelets, and this is alleviated by removal of the spleen

5 It is suggested that the cause of idiopathic thrombocytopenic purpura lies in the production by the spleen and other reticulo-endothelial tissue, of some factor which alters the state of capillaries and also reduces platelet formation from megakaryocytes Removal of the spleen may bring about a complete or partial reversal of these changes with consequent variation in clinical results

Grateful acknowledgement is made to Dr R H Girdwood, of the Department of Medicine, University of Edinburgh, who suggested the method of describing megakaryocytes, and whose co-operation added greatly to the value of the results The author is indebted to Dr J R Clark and Miss S T Lindsay for much valuable assistance The statistical analysis was carried out by Dr B

Woolf, Lecturer in Medical Statistics, University of Edinburgh Sincere thanks are due to Professor Sir James Learmonth and other members of the staff of the Royal Infirmary and the Western General Hospital for their kindness in facilitating the investigations at operation The work has been carried out under the direction of Professor L S P Davidson, whose encouragement and criticism are most gratefully acknowledged.

REFERENCES

Aggeler, P M, Howard, J, and Lucia, S P (1946) *Blood*, **1**, 472
Bedson, S P (1922) *J Path and Bact* **25**, 94
Cesaris-Demel, A (1929) *Pathologica*, **21**, 602 (cited by Tocantins, 1938)
Curtis, G M, and Movitz, D (1946) *Ann Surg* **123**, 276
Dameshek, W, and Miller, E B (1946) *Blood*, **1**, 27
Davidson, L S P (1941) *Edin Med J* **48**, 678
Denys, J (1887) *La Cellule*, **3**, 445 (cited by Tocantins, 1938)
Diggs, L W, and Hewlett, J S (1948) *Blood*, **3**, 1090
Doan, C A, Cunningham, R S, and Sabin, F R (1925) *Contributions to Embryology*, **16**, 163 Carnegie Institute Publications
Duke, W W (1915) *J Amer Med Ass* **65**, 1600
Elliot, R H E (1938) *Ibid* **110**, 1177
Frank, E (1915) *Berl Klin Wochenschr* **52**, 454, and **52**, 490
—— (1925) *Handbuch der Krankheiten des Blutes und der blutbildenden Organe* **2**, 289 Berlin
Kaznelson, P (1916) *Wien Klin Wochenschr* **29**, 1451
Krauss, E (1883) *Inaug Dissertation*, Heidelberg (cited by Tocantins, 1938)
Lawrence, J S, and Knutti, R E (1934) *Amer J Med Sci* **188**, 37
Limarzi, L R, and Schleicher, E M (1940) *J Amer Med Ass* **114**, 12
Macfarlane, R G (1941) *Quart J Med* N S **10**, 1
Mackay, W (1930–1) *Ibid* **24**, 285
Munro, H N, Lazarus, S, and Bell, G H (1947) *Nutr Abs and Rev* **17**, 291
Sabin, F R, Miller, F R, Smithburn, K C, Thomas, R M, and Hummel, L E (1936) *J Exper Med* **64**, 97
Scarborough, H. (1941) *Edin Med J* **48**, 555
Tidy, H L (1926) *Lancet*, **2**, 305
Tocantins, L M (1938) *Medicine*, **17**, 155
Troland, C E, and Lee, F C (1938) *J Amer Med Ass* **111**, 221
Ungar, G (1946–7) *J de Physiologie*, **39**, 219
Valentine, E H (1947) *Amer J Med Sci* **214**, 260
Wiseman, B K, Doan, C A, and Wilson, S J (1940) *J Amer Med Ass* **115**, 8
Wright, J H (1906) *Boston Med and Surg J* **154**, 643.
—— (1910) *J Morphol* **21**, 263

counts, bleeding times, and capillary resistance may initially show dramatic changes to supra-normal levels, but some months later are frequently found to have reverted to abnormal levels These subsequent abnormalities are presumably due to the action of the factor liberated by other parts of the reticulo-endothelial system, which may, after a period of months, achieve some compensatory increase in production The reported beneficial effects of the removal of spleneuli in cases where splenectomy has failed (Curtis and Moritz, 1916), lend support to this contention The theory is put forward that splenectomy can be a successful therapeutic measure because it removes the most potent source of this factor The success or failure of the operation depends on whether the concentration of this factor in the blood is thereby reduced below the threshold necessary to cause serious derangement of capillary function

Summary

1 Nineteen cases of idiopathic thrombocytopenic purpura have been investigated with regard to changes in bleeding time, capillary resistance, and platelet counts, before, during, and after splenectomy

Similar observations were made on a control series of 13 patients on whom splenectomy was carried out for other conditions, and seven patients undergoing other abdominal operations The megakaryocytes in the bone-marrow were studied before and after operation

2 It has been shown that the operation of splenectomy in cases of idiopathic thrombocytopenic purpura is associated with a sequence of changes in bleeding time, capillary resistance, and platelet counts, the results of observations on the control groups indicate that these changes are brought about initially by a non-specific effect of operative interference, followed by the effect of the removal of the spleen itself

3 In cases of idiopathic thrombocytopenic purpura, an assessment of the final effects of splenectomy cannot accurately be made until at least three months after operation

4 No evidence has been found of an increase in primitive forms of megakaryocytes in the bone-marrow in cases of idiopathic thrombocytopenia purpura There is, however, a diminished formation of platelets, and this is alleviated by removal of the spleen

5 It is suggested that the cause of idiopathic thrombocytopenic purpura lies in the production by the spleen and other reticulo-endothelial tissue, of some factor which alters the state of capillaries and also reduces platelet formation from megakaryocytes Removal of the spleen may bring about a complete or partial reversal of these changes with consequent variation in clinical results

Grateful acknowledgement is made to Dr R H Girdwood, of the Department of Medicine, University of Edinburgh, who suggested the method of describing megakaryocytes, and whose co-operation added greatly to the value of the results The author is indebted to Dr J R Clark and Miss S T Lindsay for much valuable assistance The statistical analysis was carried out by Dr B

616 15–003 214 616 916 1

THREE CASES OF THROMBOCYTOPENIC PURPURA OCCURRING AFTER RUBELLA[1]

WITH A REVIEW OF PURPURA ASSOCIATED WITH INFECTIONS

By J F ACKROYD

With Plate 33

Three cases of thrombocytopenic purpura occurring after rubella were seen during the epidemic of rubella which swept through this country during the spring of 1940 Only seven other well-authenticated cases have been found in the literature, namely, those of Pitten (1929), Gunn (1933), Fox and Walton (1946), Magnusson (1946), and Warren, Roghand, and Potsubay (1946) In these seven cases recovery was complete with no residual haemorrhagic manifestations In none was the preceding attack of rubella of more than average severity Pitten did not see his patient until the primary rash had disappeared, but he brought forward good evidence in support of the diagnosis of rubella In this way his case resembles the second case described here Apart from these reports, Cheadle (1881) described a case of rubella in which petechiae and small purpuric patches appeared on the extremities, and Dunlop (1871) reported two cases which developed a few cutaneous petechiae during convalescence More recently, Rudisill (1936) in a paper on the treatment of thrombocytopenic purpura with X-rays, stated in a footnote that one of his cases occurred after rubella Welt and Kasnetz (1938) have reported a case of purpura with thrombocytopenia after an attack of rubella which was complicated by mastoiditis, lateral sinus thrombosis, pyaemia, and erysipelas As these authors pointed out, it is impossible to prove that the purpura was caused by any one of the conditions which preceded it In addition to the one case mentioned above, Fox and Walton (1946) described another patient in whom purpura followed rubella They gave no details of blood counts or other investigations The fatal case of purpura after rubella described by Stratford (1911) would seem, as Moore (1911) has pointed out, probably to have been one of purpura complicating scarlet fever In addition to the above, a few cases of rubella with a haemorrhagic rash have been reported Glaister (1881) reported one case of this type but gave no details, and Hottinger (1931) has reported cases in an epidemic in Dusseldorf (Reitschel, 1931) Two cases have recently been described in detail by Ström (1940) The platelet count was normal in each and the haemorrhages appeared to be due to extravasation of blood from the dilated capillaries in the macules which constituted the rash, for not only were the haemorrhages confined

[1] Received January 25, 1949

the next day the temperature was normal and the rash beginning to fade His doctor did not see him again until 16 3 40, when he was found to have a few purpuric spots on the body and legs and bruises round both knees There was also a small submucous haemorrhage inside the left cheek He had never had an attack like this before and did not usually bleed excessively, neither was there any family history of purpura or abnormal bleeding By the following day there was bleeding from the gums and a submucous haemorrhage had developed in the faucial region Also, the purpura had become more extensive That night the patient had an epistaxis and on the following morning (18 3 40) was admitted to the Bristol Royal Hospital for Sick Children and Women under the care of Professor C Bruce Perry On admission his temperature was100 2° F and there was bleeding from the lips, gums, and nose There were numerous petechial haemorrhages over the legs and trunk and ecchymoses near both elbows and knees The fauces showed extensive submucous haemorrhages The spleen was not palpable On the following day the capillary resistance test was found to be strongly positive and the platelets were too few to estimate On the next day he was noticed to be passing tarry stools, and treatment with ascorbic acid 0 5 gm daily was commenced The condition remained more or less unchanged until 24 3 40, when bleeding from the nose, lips, and gums ceased and the purpuric rash began to fade After this there were no further haemorrhages, although the capillary resistance test was still strongly positive Treatment with ascorbic acid was stopped 25 3 40 By 3 4 40 all the petechiae and ecchymoses had faded completely and the stools were normal On 10 4 40 the lower pole of the spleen could just be felt The platelets numbered 160,000 per c mm , but the capillary resistance test was still strongly positive The spleen was never more than just palpable and could not be felt after 17 4 40 The patient was discharged home on 24 4 40, 39 days after the onset of purpura The platelet count was then 112,000 per c mm , but the capillary resistance test was rather less strongly positive than before He was seen again on 11 5 40, when he appeared perfectly well The capillary resistance test was then normal and the platelets numbered 146,000 per c mm Shortly after this the patient moved to South Wales and, unfortunately, it was not possible to examine him again The haematological investigations are summarized in Table I and Fig 1

Case 2, a boy aged 6½ years This was the mildest of the three cases On 20 4 40 he developed a rash on the body, lasting only for 24 hours He did not feel ill and did not see a doctor The illness was so slight that his mother mentioned it only when asked specifically if he had had German measles During the next two days he appeared well, but on 23 4 40 started to bleed from the gums On 26 4 40 he was admitted to the Bristol General Hospital under the care of Dr Orr-Ewing He had had no previous illnesses There was no family history of purpura or excessive bleeding The temperature and pulse-rate were normal There were fairly numerous purpuric spots on the back, chest, and abdomen, and a few on the arms and legs Several ecchymoses were observed on the arms and legs and one on the abdomen Submucous haemorrhages on the lips and inside the mouth were also seen and there was bleeding from the gums The spleen was not palpable, but became so on the following day, when the platelets were found to be too few to estimate On 28 4 40 a vitamin C saturation test did not indicate any serious deficiency On the following day vitamin C therapy was begun, a daily dose of 0 5 gm being given On 29 4 40 the patient had an epistaxis and the purpura was more marked, but the spleen was no longer palpable By 2 5 40 the petechiae were fading, but a few fresh ecchymoses had appeared on the feet and one on the upper lip

to the rash, but when the capillary fragility was investigated by constricting the arm, the petechiae produced were confined almost entirely to the rash

As only seven well-authenticated and six doubtful cases of thrombocytopenic purpura after rubella have previously been reported, the occurrence in less than six weeks of the three cases described here represents a high incidence of the condition The epidemic in which these cases occurred was characterized by an abnormally large proportion of cases developing other complications (Suffern, 1940, Hodges, 1940*a*, *b*, Harrison, 1940, Simpson, 1940, Witney, 1940, Tidy, 1940, Bennett and Copeman, 1940, Sprott, 1940, Evans, 1942) This suggested that the epidemic might have been due to an unusually virulent virus, possibly one with an exceptional tendency to cause purpura A series of uncomplicated cases of rubella, occurring in the same epidemic, was therefore investigated to determine whether the platelet count was lowered or the capillary fragility increased in patients who did not develop purpura Changes in the erythrocytes, leucocytes, bleeding time, and coagulation time were also observed As a result it was concluded that these three cases of purpura were not due to any abnormalities of the virus responsible for the epidemic, but were probably due to an unusual susceptibility of the patients' tissues to the infection

Methods

Platelet counts were done by Fonio's (1912) method Each figure given is the mean of at least two estimations The normal is generally about 250,000 to 500,000 per c mm , but counts as low as 140,000 to 180,000 per c mm may sometimes be found in normal subjects Case 1 reported here appears to have been of this type

The differential leucocyte counts were based on counts of not less than 400 cells.

Capillary fragility was investigated by a modification of Hess's (1916) method in which the sphygmomanometer band was left on the arm at a pressure of 80 mm of mercury for five minutes The result was not considered abnormal unless more than 10 petechiae were produced The petechiae were counted in daylight without the use of a lens

Bleeding time was estimated by the method of Ivy, Shapiro, and Melnick (1935) The normal range by this method is up to four minutes

Coagulation time was estimated by the capillary tube method of Sabrazes The normal range is from two to four minutes (Stitt, 1927)

Case Reports

Case 1, a boy aged 9 years Previously he had suffered from scarlet fever, whooping-cough, and chickenpox He had been quite well until 5 3 40, when he developed a rash on the face On the following day he had a temperature of 100° F and a very profuse rash over the whole of the body The occipital glands were enlarged and slightly tender, and the condition was considered by his doctor to be a typical attack of rubella The patient did not feel ill, and by

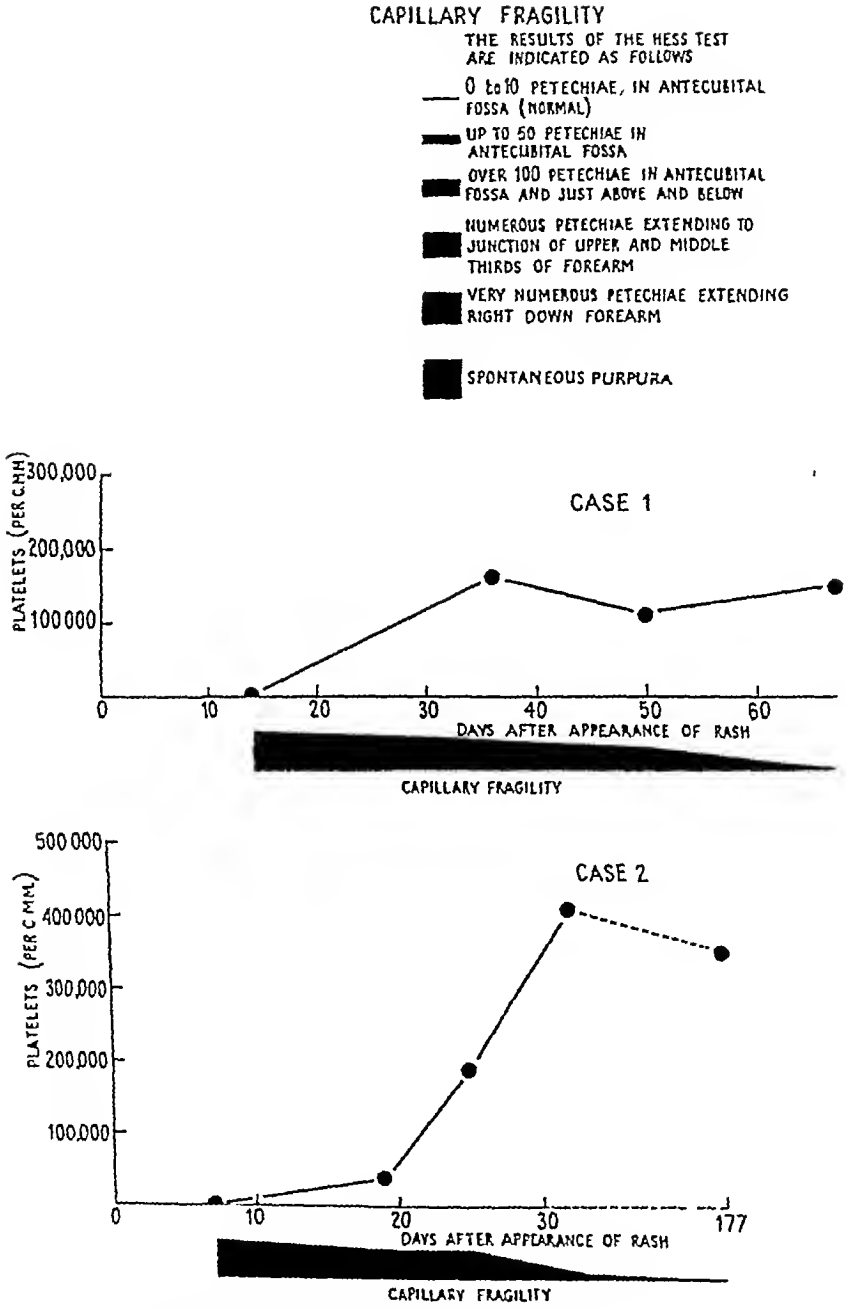

FIG 1 Platelet counts and capillary fragility in two patients (Cases 1 and 2) with thrombocytopenic purpura occurring after rubella

The dose of ascorbic acid was increased to 1·0 gm daily, and after this recovery was rapid Treatment with vitamin K, 8,000 Dam units daily, in addition to the ascorbic acid, was started on 7 5 40, and by 9 5 40 he appeared well, although the platelet count was only 40,000 per c mm and the capillary resistance test was still strongly positive The dose of vitamin K was doubled on 16 5 40 By 22 5 40, 26 days after admission, the capillary resistance test had become almost normal, the platelets were normal in number, and he was discharged.

TABLE I

Blood Examinations and Capillary Fragility in Three Cases of Purpura occurring after Rubella

Case	Date 1940	Red cells (per c.mm.)	Haemoglobin (Haldane) %	White cells (per c.mm.)	Neutrophil polymorphs (per c mm)	Eosinophil polymorphs (per c mm)	Basophil polymorphs (per c.mm)	Lymphocytes (per c.mm)	Monocytes (per c.mm)	Platelets (per c.mm)	Bleeding time (mins)	Coagulation time (mins)	Capillary fragility*
1	10.3	4 500 000	77	7,600	2,660	110	40	4,330	460	Too few to estimate	20+	2 5	++++
	10 4	4,000 000	70	8 000	1 760	120	40	5 600	480	160 000			+++
	24 4	4 000 000	70	8,300	2,130	250	80	5,330	410	112,000	5	2 5	++
	11 5	4,560 000	76	5,800	2,030	120	0	3,250	400	140,000	3	1 5	N
2	27 4	3,850,000	73	5,200	2,080	80	30	2,300	620	Too few to estimate	20+	1·0	++++
	9.5	3 000 000	73	7,800	3,120	270	40	3,740	620	40 000	1 5	1 75	+++
	15.5	4 100 000	76	7 000	3,570	210	140	2,450	630	190,000	2 75	1 5	+++
	22.5	4 480 000	76	8 400	5 210	250	80	2,270	590	410 000	2·0	1·0	Sl+
	12.11	4,200 000	77	7,300	3,800	150	40	2,920	400	350,000	1·5	3·0	N
3	11 4	3,500 000	70	7,000	3,900	70	0	2 660	350	Too few to estimate	20+	2 5	++++

* *Capillary fragility* The symbols used in this column indicate the number and distribution of the petechiae produced by the Hess test as follows

N 0 to 10 petechiae in antecubital fossa (normal)
Sl+ Up to 50 petechiae in antecubital fossa
\+ Over 100 petechiae in antecubital fossa and just above and below
++ Numerous petechiae extending to junction of upper and middle thirds of forearm.
+++ Very numerous petechiae extending right down forearm.
++++ Spontaneous purpura

Six months later (12 11 40) he was again examined He had been well during the interval and the platelet count and capillary resistance test were normal The results of the haematological investigations are summarized in Table I and Fig 1 This case is the least satisfactory of the three as the primary exanthem was not seen by a doctor However, in view of its mild and transient nature and the fact that it occurred at the height of an epidemic of rubella, it seems almost certain that the condition was, in fact, rubella

Case 3, a boy aged 9 years He had previously suffered from varicella and mumps Neither he nor any other member of the family had ever suffered from purpura or abnormal bleeding On 3 4 40 the patient was taken to his doctor, suffering from a typical attack of rubella There was an extensive rash and the occipital glands were enlarged Three days later he had an epistaxis and developed bleeding from the gums Purpuric spots were observed on the legs On 7 4 40 the patient developed haematuria He was admitted to the Bristol Royal Hospital for Sick Children and Women under the care of Professor C Bruce Perry on 10 4 40 There were purpuric spots on both legs, especially round the ankles, and some on the neck and shoulders The spleen was not palpable There was gross haematuria On the following day a blood count (see Table I) showed that the platelets were so greatly reduced in number that it was not possible to count them The capillary resistance test was strongly

Histology

Lung The sections showed numerous intra-alveolar haemorrhages which all appeared to be very recent No megakaryocytes were found

Kidney There were haemorrhages in the pyramid and also in the pelvis and pericapsular tissues

Spleen The only apparent alteration was the presence of many eosinophil leucocytes in the Malpighian bodies and in the pulp No megakaryocytes were seen

The liver appeared normal No megakaryocytes were seen

The pancreas, adrenals, and *pituitary* all appeared normal

No platelet thromboses of the type described by Baehr, Klemperer, and Schifrin (1936) were seen in any of the sections

Bone-marrow Paraffin sections were taken from the upper end of the femur and from the sternum They were fixed in Helly's solution and stained with the May–Grunwald–Giemsa stain The erythroblastic cells showed no abnormalities The only change noted in the leucoblastic cells and leucocytes was a slight increase in the proportion of eosinophils

Megakaryocytes A modification of Frey's (1928) method of counting was used Sections 7 microns thick were cut at five different levels through the thickness of the bone-marrow at the upper end of the femur, and the number of megakaryocytes per 100 fields at each level was estimated, using a Leitz 1/12 in objective (NA 1 2) and a ×8 ocular at a tube length of 170 mm Portions of megakaryocytes were also counted, except when these appeared obviously to be pseudopodia, which had become separated from adjacent cells The distribution of megakaryocytes at the different levels was found to be remarkably uniform The average figure obtained was 67 megakaryocytes per 100 fields It is difficult to estimate the number of cells in the bone-marrow because the proportion of haemopoietic cells to fat cells often varies from one part of a section to another To minimize this effect, any fields containing more than an occasional fat cell were passed over The figures obtained when this is done provide an indication of the number of megakaryocytes per unit volume of haemopoietic tissue and give results which it is believed are valuable for purposes of comparison in cases with cellular marrows It has proved difficult to obtain satisfactory control material with which to compare the figures obtained in this investigation, as the bone-marrow is notoriously liable to undergo changes in disease Also, the number of megakaryocytes in the marrow varies with age (Frey, 1928) It was therefore desirable to obtain specimens from cases of sudden death in previously healthy subjects of approximately the same age as the patient I am indebted to Professor W D Newcomb for two specimens of femoral bone-marrow from cases of sudden death in previously healthy children The first specimen was from a female child aged 6 years who was found drowned The megakaryocytes in this case numbered 65 per 100 fields The second specimen was from a male child aged 7 years who was injured in a street accident He was operated on immediately and was found to have a ruptured liver He died shortly after the operation Only very small pieces of bone-marrow had been kept, and it was possible to count only 350 fields The megakaryocytes numbered 66 per 100 fields The megakaryocytes were also counted in a woman aged 63 years, who died of extensive fat embolism 2½ hours after receiving multiple fractures in an air-raid The megakaryocytes in this case numbered 40 per 100 fields This is lower than the figure obtained for Case 3, but the bone-marrow, as would be expected in a patient of this age, was not as cellular Also, as Frey (1928) has shown, the number of megakaryocytes normally tends to be higher in children than in the aged The

positive. On 12 4 40 the general condition was about the same He went to sleep in the afternoon and awoke at 5 p m , complained of nausea, and vomited once Within 10 minutes he had become comatose, the limbs being flaccid and respirations stertorous Ten minutes later lumbar puncture was performed and uniformly blood-stained cerebrospinal fluid withdrawn under great pressure The pupils gradually became fully dilated and fixed, the respirations shallower, and the pulse weaker The heart stopped beating at 6 50 p m

Summary of findings at autopsy performed 16 hours after death

The body was that of a well-nourished muscular boy There were very numerous cutaneous petechiae and small subcutaneous haemorrhages all over the body

The serous cavities All the serous membranes showed petechiae There was an extensive retroperitoneal haemorrhage which extended around the ascending colon

The heart showed no change apart from epicardial haemorrhages

The mouth, soft palate, and *pharynx* showed small submucous haemorrhages

The larynx and *trachea* showed small submucous haemorrhages

The lungs showed numerous subpleural petechiae On section no gross changes could be detected

The spleen weighed 88 gm It appeared slightly enlarged, with rounded margins On section it was soft in consistency

The bone-marrow of the right femur, vertebrae, sternum, and ribs appeared healthy

The lymph nodes were not enlarged

The liver weighed 1,040 gm There were a few subserous petechiae, but on section the appearances were normal

The gall-bladder, bile-ducts, and *pancreas* appeared normal

The oesophagus, stomach, and *intestines* showed numerous submucous and subserous haemorrhages

The kidneys each weighed 110 gm There was extensive haemorrhage in the perirenal tissues on each side On section there was blood in the pelvis of each kidney, but apart from this the appearances were normal The *ureters* appeared healthy There were a few subepithelial haemorrhages in the *bladder*

The genitalia appeared normal

The thymus, pituitary, thyroid, and *adrenals* showed no abnormalities

Muscles There were many haemorrhages in the muscles of the trunk and limbs

The cranial cavity appeared normal

The meninges The dura was healthy There was a small calcified plaque 8 mm in diameter in the arachnoid over the right frontal pole, which might have been the result of calcification of a birth injury There was a similar but smaller plaque over the left frontal pole There was fresh blood in the subarachnoid space at the base of the brain The pia-arachnoid showed numerous minute petechiae

The brain The convolutions were flattened, but there was no pressure cone on the cerebellum A coronal section after fixation revealed a very large haemorrhage in the right cerebral hemisphere (*Plate 33, Fig 3*), extending from the white matter of the right frontal pole, very nearly to the occipital pole It had caused almost complete destruction of the internal capsule, thalamus, and zona radiata, and had ruptured into the right lateral ventricle

The cerebral arteries appeared normal There was no indication of an aneurysm.

was true both for the patients with uncomplicated rubella and for those who developed purpura Similar investigations in other infections have also failed to show any correlation between the leucocyte and platelet counts (Tocantins, 1938)

Capillary fragility This was usually greatest at the onset of the disease and became normal during convalescence In two patients (Cases 4 and 7), a small

TABLE II

Haematological Findings and Capillary Fragility in Cases of Uncomplicated Rubella

Case	Date 1940	Red cells (per c.mm.)	Haemoglobin (Haldane) %	White cells (per c mm.)	Neutrophil polymorphs (per c.mm.)	Eosinophil polymorphs (per c.mm.)	Basophil polymorphs (per c mm.)	Lymphocytes (per c mm.)	Monocytes (per c.mm.)	Platelets (per c.mm.)	Bleeding time (mins.)	Coagulation time (mins.)	Capillary fragility†
4	16 4	3,750,000	80	5,000	2,500	80	20	2,000	400	140 000	4·0	1 5	+
	19 4	3,800 000	80							137,000	6 5	1 75	+
	23 4	3,850,000	80	5,200	2,240	80	30	2,440	420	170,000	5 5	2 5	+
	27 4	3,750,000	80	8,200	4 070	80	0	2,050	490	140 000	3·0	1 5	N
	2 5	3,700 000	80	0,700	5,630	0	0	3,400	680	130 000	3 0	3·0	Sl +
	0 5	3 800,000	80	6 600	3,230	70	70	2 840	400	140 000	6·0	1 5	N
	18.5	4,500 000	76	7 700	4 700	40	40	2,620	310	280,000	4·0	2 5	N
	28.5	4,400,000	80	5,000	2,000	80	30	2,400	500	204 000	6 5	1 75	N
5	17 4	4 400,000	00	8,500	5,780	90	0	2,210	430	210 000	4 5	1·0	N
	20 4	4 800,000	00							192,000	4 5	2·0	N
	26 4	4 600,000	90	9 600	5,180	240	50	3,650	480	190 000	2·0	3 5	N
	6 5	4 850,000	00	7,700	4,700	150	80	2,310	460	340 000	2 5	2 5	N
	16 5	4,800,000	00	10,000	7,000	150	50	2,400	400	300,000		1 5	N
6	21 4	4,200 000	80	6,000	2,160	180	0	3,360	300	180 000	3 5	1 75	Sl +
	25 4	4 200,000	80							170 000	3·0	1 5	Sl +
	29 4	4,150 000	76	11 700	4,330	230	0	6,670	460	390 000		1 25	N
	3 5	4 200 000	80	11,200	6,940	60	60	4,700	450	350 000	3·0	2·0	N
	7 5	4 000 000	80	11,200	6,940	450	0	4,700	560	320 000		1 5	N
	16.5	4 100,000	80	8 700	4,350	460	40	3,480	350	310,000		1·0	N
7	17 4	4,700 000	00	9,500	3,310	100	0	5,200	380	247 000	3 5	1 0	N
	20 4	4 400 000	00							228,000	3 5	1 5	Sl +
	24 4	4 600 000	90	6 000	2,460	180	60	2 940	360	327,000		2 25	N
	29 4	4 500 000	00	11 800	6,960	180	60	3,780	830	310 000	3 5		+
	4 5	4,800 000	94	13 600	8 570	200	70	4,080	680	250,000			N
	11 5	4,700 000	04	10,400	6,030	310	0	3,640	420	245,000	2·0	2·0	N
8	0 5	4 250 000	80	3,800	1 860	80	40	1 480	340	120 000	2·0	1 5	++
	13 5	4 600 000	80	8,200	3,850	160	0	3 610	570	180 000	4 5	1 25	++
	17 5	4,400,000	80	12,700	7,400	130	0	4,320	760	270 000	2·0	1 5	++
	21 5	4,400 000	76	12,600	7,310	190	60	4 280	760	350,000	2·0	1 5	++
	27 5	4 650 000	80	9 000	4 860	180	0	3,330	620	330 000	2 5	1·0	++
	5 6	4 600,000	80	9,600	4 220	380	0	4,610	380	282,000		3 5	Sl +*

* This patient s capillary fragility was normal when she was re-examined 12 months later
† For key to the symbols used in this column see Table I.

rise in capillary fragility was also observed about the twentieth day of the disease The changes in fragility varied greatly from one patient to another; in Case 5 there was no increase at any time, while in Case 8 the test was strongly positive for over a fortnight, although the disease appeared to be equally mild in each case

The platelet count and capillary fragility There appeared to be no correlation between the changes in the platelet counts and capillary fragility Normal fragility was observed with a platelet count as low as 140,000 per c mm in Case 4 and considerably increased fragility with a count as high as 350,000 per c mm in Case 8, and it may be noted here that in two of the patients who developed purpura (Cases 1 and 2), greatly increased capillary fragility was seen with platelet counts as high as 160,000 and 190,000 per c mm respectively

figures of 65 and 66 per 100 fields obtained for the two children are, however, extraordinarily close to the figure of 67 per 100 fields obtained for Case 3 This indicates a remarkable degree of uniformity in the numbers of megakaryocytes in the bone-marrow of these three children and demonstrates clearly that the disease had caused no significant alteration in the number of megakaryocytes in the bone-marrow of Case 3 No attempt was made to perform differential megakaryocyte counts as these cannot be carried out satisfactorily on post-mortem section material It may be stated that a large proportion of the cells appeared normal and contained their full complement of the characteristic azurophil granules and that, certainly, no gross changes such as those described by Baar and Gasul (1929) in a case of purpura secondary to diphtheria or by Leitner (1945) in a case occurring in the course of generalized septicaemia, were present in the bone-marrow in this case The normal appearance of these cells is well shown in the two photomicrographs of sections of the femoral marrow (Plate 33, Figs 4 and 5)

Investigation of Cases of Uncomplicated Rubella

The present investigation was undertaken at the end of the epidemic of rubella in which the patients just described were seen By that time cases were becoming infrequent, and unfortunately only five patients were seen who could be repeatedly examined over a sufficiently long period In each the attack was mild and the only patient who complained of feeling ill did not feel sufficiently unwell to go to bed These cases have been described as uncomplicated cases of rubella It will be seen from the clinical notes in the Appendix that two of the patients (Cases 4 and 7) suffered from joint pains This symptom was, however, very common in the epidemic One patient (Case 8) suffered from 'tinglings' in both hands, also a not uncommon symptom in the epidemic There were no detectable neurological changes, and the abnormal sensation rapidly disappeared The only definite complication occurred in Case 6 who developed an attack of urticaria one week after the onset of rubella This does not appear to have had any effect on the platelet count or on the response to the capillary resistance test, as the changes observed in this patient were identical in type with those seen in the remaining cases, and it has, therefore, been felt justifiable to include her in the series Complete haematological investigations were carried out on all these patients at frequent intervals The results are shown in Table 2 and Fig 2

Platelet count The changes in the platelet counts in all five patients were similar At the onset of the disease the count was usually low After a varying interval it rose to above the normal level for that patient and later fell to normal The curves differed from one another only in the intensity and duration of the thrombocytopenia Thus, in Case 7 the changes in the platelet count were only slight, while in Case 4 there was a very considerable reduction in the platelet count for over four weeks, although the preceding attack of rubella was, if anything, slightly milder in this patient

Leucocyte and platelet count The variations in the total and differential white-cell counts showed no uniform trends nor did there appear to be any parallelism between the changes in the leucocyte counts and numbers of platelets This

The bleeding time and coagulation time These showed no striking deviation from the normal The slightly prolonged bleeding times observed in Case 4 may have been due to the fact that she had acrocyanosis

Analysis of the platelet counts in many other acute infections, including even the common cold (Bannerman, 1924), has also shown a tendency to an initial thrombocytopenia, followed, after a variable period, by a rise which may temporarily reach a level above normal There appears to have been no other investigation of the platelet count in rubella, but the changes found in measles (Schiff and Matyas, 1918, Beck, 1924), varicella (Beck, 1924), and vaccinia (Beck, 1924) are very similar to those observed in the cases of rubella reported here, and show the same striking variations in individual susceptibility as demonstrated by the different degrees of thrombocytopenia that developed in different individuals in response to the same infection The capillary fragility in rubella has been investigated by Hecht (1907) and Kernau (1938) Using the suction technique described by Hecht (1907), Kernau found that the capillary fragility was increased in all but two of 35 cases The increase was greatest during the first three days and persisted for seven to eight days Hecht (1907) examined two patients by the same method In one, the capillary fragility showed no significant alteration while in the other, who was observed for only eight days, the fragility was still increased at the end of this period As Monro, Lazarus, and Bell (1947) have pointed out, it is difficult to compare the results obtained by this method with those obtained by the positive pressure method which was used in the present investigation, but it is clear that the general pattern of the changes in these different investigations is the same, the capillary fragility being high at the onset of the disease and falling during convalescence There is, as with the changes in the platelet count, considerable variation in individual susceptibility, some patients showing a considerable increase in capillary fragility and a few showing little or no change The authors of these investigations have not commented on this wide range of response of the platelet count and capillary fragility to apparently equally severe attacks of the same infection, but this finding suggests strongly that it is not so much the virulence of the organism as the susceptibility of the patient which determines the degree to which thrombocytopenia and capillary damage result

Discussion

The significance of thrombocytopenia in acute infections It is known that organisms when injected intravenously into animals become clumped together with platelets and rapidly disappear from the circulation Not all animals react in this way to all organisms If a mixture of staphylococci and pneumococci, for instance, is injected intravenously into rabbits, only the staphylococci are agglutinated (Govaerts, 1921) Pneumococci are, however, agglutinated in this way if injected into dogs (Govaerts, 1921) The agglutination, when it occurs, is accompanied by a peripheral thrombocytopenia (Govaerts, 1921, Dudgeon and Goadby, 1931) This phenomenon is known as 'platelet loading' Its

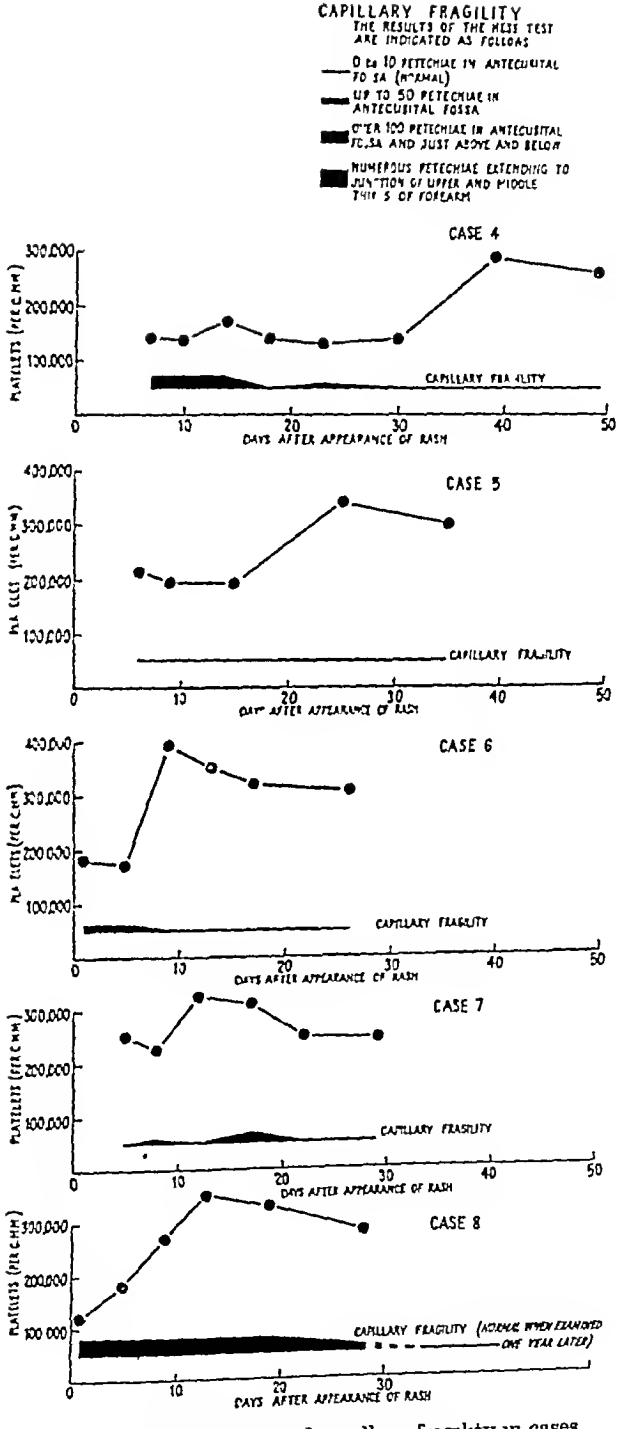

FIG 2 Platelet counts and capillary fragility in cases of uncomplicated rubella

The bleeding time and coagulation time These showed no striking deviation from the normal The slightly prolonged bleeding times observed in Case 4 may have been due to the fact that she had acrocyanosis

Analysis of the platelet counts in many other acute infections, including even the common cold (Bannerman, 1924), has also shown a tendency to an initial thrombocytopenia, followed, after a variable period, by a rise which may temporarily reach a level above normal There appears to have been no other investigation of the platelet count in rubella, but the changes found in measles (Schiff and Matyas, 1918, Beck, 1924), varicella (Beck, 1924), and vaccinia (Beck, 1924) are very similar to those observed in the cases of rubella reported here, and show the same striking variations in individual susceptibility as demonstrated by the different degrees of thrombocytopenia that developed in different individuals in response to the same infection The capillary fragility in rubella has been investigated by Hecht (1907) and Kernau (1938) Using the suction technique described by Hecht (1907), Kernau found that the capillary fragility was increased in all but two of 35 cases The increase was greatest during the first three days and persisted for seven to eight days Hecht (1907) examined two patients by the same method In one, the capillary fragility showed no significant alteration while in the other, who was observed for only eight days, the fragility was still increased at the end of this period As Monro, Lazarus, and Bell (1947) have pointed out, it is difficult to compare the results obtained by this method with those obtained by the positive pressure method which was used in the present investigation, but it is clear that the general pattern of the changes in these different investigations is the same, the capillary fragility being high at the onset of the disease and falling during convalescence There is, as with the changes in the platelet count, considerable variation in individual susceptibility, some patients showing a considerable increase in capillary fragility and a few showing little or no change The authors of these investigations have not commented on this wide range of response of the platelet count and capillary fragility to apparently equally severe attacks of the same infection, but this finding suggests strongly that it is not so much the virulence of the organism as the susceptibility of the patient which determines the degree to which thrombocytopenia and capillary damage result

Discussion

The significance of thrombocytopenia in acute infections It is known that organisms when injected intravenously into animals become clumped together with platelets and rapidly disappear from the circulation Not all animals react in this way to all organisms If a mixture of staphylococci and pneumococci, for instance, is injected intravenously into rabbits, only the staphylococci are agglutinated (Govaerts, 1921) Pneumococci are, however, agglutinated in this way if injected into dogs (Govaerts, 1921) The agglutination, when it occurs, is accompanied by a peripheral thrombocytopenia (Govaerts, 1921, Dudgeon and Goadby, 1931) This phenomenon is known as 'platelet loading' Its

significance is uncertain, but as organisms are removed just as quickly from the circulation of animals from which the platelets have been removed (Bull and McKee, 1922), it seems that platelet loading is not an important defence mechanism. The literature on this subject has been reviewed by Tocantins (1938). The thrombocytopenia that results from platelet loading is transient Dudgeon and Goadby (1931), who produced severe thrombocytopenia in rabbits by injecting intravenously suspensions of virulent staphylococci, showed that the number of platelets was partially restored to normal within two hours of the injection, although during this time more and more cocci were appearing free in the capillaries and the animal was developing a septicaemia Taniguchi, Joogetsu, and Kasahara (1930), who injected various organisms into guinea-pigs and rabbits, found that the thrombocytopenia due to platelet loading lasted only for a half to one hour In man, Mackay (1930) obtained similar results with typhoid vaccine injected intravenously The platelet count fell steadily for 25 minutes, but regained its original level within two hours It has been suggested (Bannerman, 1924, Tocantins, 1938) that the phenomenon of platelet loading may explain the thrombocytopenia that occurs in so many acute infections This seems improbable because the thrombocytopenia due to platelet loading is of so very much shorter duration In Dudgeon and Goadby's (1931) experiments the number of circulating platelets was increasing at the same time as the number of free cocci in the blood was rising, whereas in one of the patients (Case 4) in the present series, the depression in the platelet count persisted for as long as four weeks after the disappearance of the rash, and in another (Case 5), the platelet count did not return to normal for over a fortnight Moreover, Duke (1913) has shown that the platelet count is lowered in some cases of diphtheria, where any significant degree of platelet loading is unlikely to occur, and in rabbits with thrombocytopenia due to experimental inoculation with fatal doses of diphtheria toxin, he was able to demonstrate degenerative changes in the megakaryocytes which appeared to be sufficiently severe to account for the thrombocytopenia These facts suggest that thrombocytopenia in acute infections may be due to an effect on the bone-marrow rather than to the phenomenon of platelet loading, which appears to be of little importance in this connexion

Pathogenesis of purpura associated with infectious diseases Purpura associated with infectious diseases can be divided into four types

1 Conditions in which purpura forms a part of the normal clinical picture of an infection, for example, septicaemia

2 Cases where the haemorrhages are confined to the rash and appear to be due to an exaggeration of the same process that causes the exanthem

3 Cases of the haemorrhagic forms of the acute infections The nature of these is obscure and very little is known about them The four most commonly described varieties are haemorrhagic measles, haemorrhagic scarlet fever, haemorrhagic smallpox, and haemorrhagic diphtheria They are classically described as overwhelmingly severe infections in which purpura appears early and death occurs in a few days The first two are rare Box (1933) had never

seen a case of haemorrhagic scarlet fever and Ker (Rundle, 1929) stated that he had seen neither haemorrhagic scarlet fever nor haemorrhagic measles. It is doubtful if either of these conditions constitutes a definite clinical entity and many cases described in the older literature appear to have been examples of haemorrhagic smallpox (Rolleston and Ronaldson, 1940, Ker (Rundle, 1929)) In haemorrhagic smallpox, Ikeda (1925, 1928) has shown that there is often an intense septicaemia which he thought might well account for the purpura He was able to demonstrate streptococci in all post-mortem blood cultures and in 74 per cent. of blood cultures taken before death In some of these cases the septicaemia was so gross that numerous organisms could be seen in stained films of blood taken during life Further evidence of the frequent occurrence of haemolytic streptococcal infection of the blood-stream in haemorrhagic smallpox is provided by Wilkinson's (1943) observation that haemolytic streptococci could invariably be isolated from haemorrhagic bullae in such cases. Such a blood-stream infection, occurring in a patient whose platelet count had already been lowered and capillary fragility increased by infection with the virus of smallpox, must have contributed greatly both to the severity of the disease and to the haemorrhagic tendency, and may well explain the appearance of the haemorrhages, although it must be emphasized that it is not known if any other factors are involved as very little work has been done on this type of purpura It is conceivable that the haemorrhages found in some severe cases of diphtheria may be due to a similar invasion of the blood-stream, for it is known that streptococci and *Corynebacterium diphtheriae* may sometimes be found in the blood in this condition (Ammundsen, Bang, Franck, Hansen, Lassen, Poulsen, Snorrason, Thygesen, Vimstrup, and Zimsen, 1947, Leede, 1911, Roedelius, 1913) W D Newcomb (personal communication) has seen one case of diphtheria associated with purpura in which there was a concomitant streptococcal septicaemia Quick (1942) considered the purpura in haemorrhagic diphtheria to be due to the effects of an overwhelming toxaemia, but if this is correct it would be expected that purpura would be a much more common finding than it is in fatal cases, and it seems probable that the vast majority of cases of haemorrhagic diphtheria belong to the next group

4 Cases of the type with which the present paper is concerned, in which purpura occurs as a rare complication of an infection This type of purpura appears to bear no relationship to the severity of the primary infection and may complicate mild or severe cases It has, in the past, been widely held that purpura occurs only in severe infections, but this is clearly not correct The three cases of purpura described here followed very mild attacks of rubella. According to Box (1933), purpura complicating scarlet fever usually follows mild or only moderately severe attacks In diphtheria, Ker (Rundle, 1929) has observed that although the throat symptoms are usually severe in purpuric cases they are not necessarily so, and Gee (1905) stated that the haemorrhagic tendency bears no relationship to the severity of the throat infection, and that the symptoms of diphtheria may be so slight that the diphtheritic origin of the purpura may be overlooked

significance is uncertain, but as organisms are removed just as quickly from the circulation of animals from which the platelets have been removed (Bull and McKee, 1922), it seems that platelet loading is not an important defence mechanism The literature on this subject has been reviewed by Tocantins (1938) The thrombocytopenia that results from platelet loading is transient Dudgeon and Goadby (1931), who produced severe thrombocytopenia in rabbits by injecting intravenously suspensions of virulent staphylococci, showed that the number of platelets was partially restored to normal within two hours of the injection, although during this time more and more cocci were appearing free in the capillaries and the animal was developing a septicaemia Taniguchi, Joogetsu, and Kasahara (1930), who injected various organisms into guinea-pigs and rabbits, found that the thrombocytopenia due to platelet loading lasted only for a half to one hour In man, Mackay (1930) obtained similar results with typhoid vaccine injected intravenously The platelet count fell steadily for 25 minutes, but regained its original level within two hours It has been suggested (Bannerman, 1924, Tocantins, 1938) that the phenomenon of platelet loading may explain the thrombocytopenia that occurs in so many acute infections This seems improbable because the thrombocytopenia due to platelet loading is of so very much shorter duration In Dudgeon and Goadby's (1931) experiments the number of circulating platelets was increasing at the same time as the number of free cocci in the blood was rising, whereas in one of the patients (Case 4) in the present series, the depression in the platelet count persisted for as long as four weeks after the disappearance of the rash, and in another (Case 5), the platelet count did not return to normal for over a fortnight Moreover, Duke (1913) has shown that the platelet count is lowered in some cases of diphtheria, where any significant degree of platelet loading is unlikely to occur, and in rabbits with thrombocytopenia due to experimental inoculation with fatal doses of diphtheria toxin, he was able to demonstrate degenerative changes in the megakaryocytes which appeared to be sufficiently severe to account for the thrombocytopenia These facts suggest that thrombocytopenia in acute infections may be due to an effect on the bone-marrow rather than to the phenomenon of platelet loading, which appears to be of little importance in this connexion

Pathogenesis of purpura associated with infectious diseases Purpura associated with infectious diseases can be divided into four types

1 Conditions in which purpura forms a part of the normal clinical picture of an infection, for example, septicaemia

2 Cases where the haemorrhages are confined to the rash and appear to be due to an exaggeration of the same process that causes the exanthem

3 Cases of the haemorrhagic forms of the acute infections The nature of these is obscure and very little is known about them The four most commonly described varieties are haemorrhagic measles, haemorrhagic scarlet fever, haemorrhagic smallpox, and haemorrhagic diphtheria They are classically described as overwhelmingly severe infections in which purpura appears early and death occurs in a few days The first two are rare Box (1933) had never

not reported as being enlarged in the cases described by Pitten (1929), Gunn (1933), Magnusson (1946), or Fox and Walton (1946) The spleen of Case 3 appeared slightly enlarged at autopsy, although it was not palpable during life. Histologically it showed no change beyond the presence of an increased number of eosinophils Splenic enlargement was detected clinically in the two remaining cases of purpura reported here In Case 2 the spleen became palpable one week after the onset of rubella, but in Case 1 it did not become palpable for over a month after the disappearance of the rash, by which time the purpura had faded The spleen may normally be enlarged during the early stages of rubella (Harries and Mitman, 1940) and this may explain the splenic enlargement observed in some of these cases, although it does not explain that observed in Case 1, and it must be confessed that the cause of the enlargement of the spleen in these cases is uncertain

Studies of the bone-marrow have thrown some light on the mechanism of production of thrombocytopenia in this type of purpura Gross pathological changes in the megakaryocytes have been reported in thrombocytopenic purpura secondary to diphtheria (Baar and Gasul, 1929) and septicaemia (Kienle, 1942), and Leitner (1945) has described a case secondary to pulmonary tuberculosis, and another occurring in the course of generalized septicaemia, in which the megakaryocytes were either absent or greatly reduced in number Hyperplasia of the megakaryocytes has been described by Morrow (1945), in a fatal case of thrombocytopenic purpura after scarlet fever, and by Nickerson and Sunderland (1937), in a case secondary to acute mastoiditis The latter authors stated that the megakaryocytes when stained by Wright's (1910) technique appeared to be forming platelets They therefore suggested that the toxin acted directly on the circulating platelets rather than on the megakaryocytes, but although it has often been claimed that it is possible to demonstrate platelet formation histologically, the interpretation of such appearances is open to doubt Moreover, if it is accepted that platelets are formed by the budding off of portions of the cytoplasm of megakaryocytes, then it seems improbable that a toxin could be so specific that it could injure the platelets without causing any damage to the megakaryocytes, although clearly such damage might be too slight to produce histologically demonstrable changes It therefore seems reasonable to assume that both the megakaryocytes and the platelets are affected by the disease process Normal findings in the bone-marrow have been reported in thrombocytopenic purpura secondary to an acute upper respiratory infection (Fowler, 1936) and infectious mononucleosis (Lloyd, 1944) In Case 3 reported here the megakaryocytes were also present in normal numbers and showed no morphological changes The normal appearance of the megakaryocytes in this case is perhaps not surprising when it is realized that death was due only to the chance occurrence of haemorrhage into a vital organ and that Cases 1 and 2 recovered completely It seems probable that the thrombocytopenia in purpura after infections can be explained on the supposition that both the megakaryocytes and platelets are affected The injury to the megakaryocytes may be severe enough to cause morphological

The interval between the onset of the infection and the appearance of purpura varies considerably Thus, as far as can be determined from the data available, in the seven cases of purpura after rubella previously reported, the purpura developed on the first, second, third, fourth, fifth, seventh, and ninth days after the appearance of the rash In Cases 2 and 3 reported here, the purpura started on the third day, but in Case 1, not until the eleventh day In scarlet fever there is an even wider variation, the usual time of onset being the third or, less commonly, the fourth week after the onset of the disease (Box, 1933), although purpura may occur earlier or later than this and, as in a patient described by Fox and Enzer (1938), purpura may appear during the first week of the disease

The platelets are often present in normal numbers, but in some cases there has been thrombocytopenia Purpura of the Henoch-Schonlein type has been described on rare occasions after scarlet fever (Box, 1933) As the platelet count is frequently normal, the most important lesion seems to be an increase in capillary fragility, although thrombocytopenia when it occurs may tend to increase the haemorrhagic tendency Roskam (1934) has performed many experiments to show that thrombocytopenia may have such an effect, but perhaps the most convincing evidence is that of Bedson (1922) and Elliott and Whipple (1940), who showed that severe haemorrhages will occur if thrombocytopenia is induced in animals whose capillaries have been damaged to an extent insufficient to cause purpura, although the induction of a similar degree of thrombocytopenia in a normal animal has no such effect

The role of the spleen in idiopathic thrombocytopenic purpura is a subject of much controversy, some holding that it destroys platelets in excessive numbers (Kaznelson, 1916, 1919, Doan and Wright, 1946, Alrutz, Nortell, and Piette, 1926), that it inhibits platelet production by the bone-marrow (Minot, 1917, Dameshek and Miller, 1946, Limarzi and Schleicher, 1940) Although the spleen has not usually been considered to be of importance in the development of purpura in infectious diseases, there is considerable evidence that it may play a part in the development of purpura associated with tuberculosis The association of purpura with tuberculosis is rare, but it seems to be well established that in cases in which the spleen is extensively involved, splenectomy may cure the purpura This has been reported both in cases where the splenic involvement has occurred as part of a generalized tuberculous infection and in splenic tuberculosis (Winternitz, 1912), a condition in which the spleen is almost the only organ involved, the primary lesion having healed Cases of purpura of this type which have been cured by splenectomy have been reported by Kellert (1931), Omodei-Zorini (1933), Gerstenberg and Reinwein (1940), and Weiner and Carter (1941) The purpura has generally been thrombocytopenic, and in these cases splenectomy has restored the platelet count to normal, but in Omodei-Zorini's two cases the platelets were present in normal numbers Apart from splenic tuberculosis, no significant changes have been noted in the spleen in purpura associated with infectious diseases The spleen was reported to be palpable during the first week of the illness in the two cases of purpura after rubella described by Warren, Rogland, and Potsubay (1946), but was

conditions, and that the allergic factor which causes acute nephritis may, in another patient, produce purpura It seems that the cases of purpura occurring during convalescence from virus infections such as rubella and measles could be explained on similar lines In this connexion it is interesting to note that in two of the patients (Cases 4 and 7) with uncomplicated rubella reported here there was an unexplained increase in capillary fragility about the twentieth day after the onset of the disease It seems possible that this slight increase may have been due to an allergic response to the original infection of the type which it has been suggested here may precipitate the onset of purpura during convalescence

Summary

1 Three cases of thrombocytopenic purpura occurring after rubella are described Two of the patients recovered spontaneously The third died of cerebral haemorrhage The post-mortem findings are given in detail.

2 In cases of uncomplicated rubella, the platelet count is usually low and the capillary fragility high at the onset of the disease, returning to normal during convalescence

3 Similar changes occur in other acute infections

4 Platelet loading is probably of no importance in the production of thrombocytopenia in acute infections

5 The degrees of thrombocytopenia and increased capillary fragility after infections of apparently equal severity vary strikingly from one patient to another

6 The incidence of purpura after acute infections does not appear to bear any relationship to the severity of the primary disease Purpura may complicate mild or severe infections

7 It is concluded that the degrees of thrombocytopenia and increased capillary fragility in acute infections depend upon the susceptibility of the patients' tissues rather than upon the intensity of the primary infection, and that purpura occurring during the early stages of an infection may be due to a high degree of susceptibility to capillary damage and sometimes also to thrombocytopenia

8 The development of purpura during convalescence can best be explained on the assumption of an allergic basis, similar perhaps to that to which nephritis after streptococcal infections has been attributed

My thanks are due to Professor C Bruce Perry and to Dr H J Orr-Ewing for permission to examine their cases, to Dr Dorothy Ayre for the clinical histories of Cases 1 and 3, and to Professors T F Hewer and W D Newcomb for access to their post-mortem material The illustrations were prepared by Mr T J H Cooke

changes in those cells or may only be sufficient to inhibit thrombopoiesis. In the latter type there may be a compensatory megakaryocytic hyperplasia

There are two striking facts in connexion with this type of purpura that remain to be considered Firstly, there appears to be no obvious relationship between the severity of the primary infection and the incidence of purpura Purpura may occur in severe cases or may complicate very mild infections Secondly, purpura may occur either during the acute stages of an infection or during convalescence Different degrees of increased capillary fragility and thrombocytopenia, persisting for widely different periods, have been demonstrated in the cases of rubella reported here Similar reactions are known to occur in many other acute infections It seems certain that the two effects are produced by the same agent, although this must vary with the primary disease As has been stated above, the variations in the degrees of increased capillary fragility and of thrombocytopenia found in acute infections appear to be the result of variations in the susceptibility of the patients' tissues It seems probable that purpura occurring during the early stages of acute infections represents a high grade of this susceptibility resulting in such severe capillary damage, and sometimes thrombocytopenia, that haemorrhages develop It also seems probable that the severe and prolonged thrombocytopenia encountered in Case 4, and the increased capillary fragility lasting for over a fortnight after the disappearance of the rash in Case 8, represent lesser degrees of this susceptibility, and that although the reactions in these cases were severe, they were insufficient to produce purpura Such a view does, at least, explain the absence of any obvious relationship between the severity of the primary infection and the incidence of purpura, although these two factors should probably not be considered as being entirely separate, as a severe infection occurring in a susceptible patient may well have a greater tendency to cause purpura than a mild infection occurring in the same patient

Although the above hypothesis may account for those cases of purpura that occur during the first few days of an infection, it does not explain those in which purpura appears long after the disappearance of the symptoms of the primary disease It has been shown in the present investigation that increased capillary permeability and thrombocytopenia may persist well into the period of convalescence, but this does not explain why purpura should suddenly develop at this stage It seems probable that, although the increase in capillary permeability and the thrombocytopenia may conceivably be predisposing causes, there must be some other factor tending to precipitate the appearance of haemorrhages Nothing is known of the nature of such a factor, but the existence of a symptom-free period before the onset of purpura suggests the possibility of an allergic basis for this complication similar, perhaps, to that to which nephritis after streptococcal infections has been attributed Indeed, the period of maximal incidence of purpura after scarlet fever coincides with that of post-scarlatinal nephritis, and if it is accepted that the glomerular lesions of acute nephritis are but part of a generalized lesion of the capillaries, then it seems possible that there may be a close relationship between the two

Monro, H N, Lazarus, S, and Bell, G H (1947) *Nutr Abstr Rev* **17**, 291
Moore, J W (1911) *Lancet*, **2**, 255
Morrow, W J (1945) *Arch Pediat* **62**, 255
Nickerson, D A., and Sunderland, D A (1937) *Amer J Path* **13**, 463
Omodei-Zorini, A (1933) *Policlinico* (Sez Med) **40**, 790
Pitten, T (1929) *Arch Kinderheilk* **86**, 114
Quick, A J (1942) *The Hemorrhagic Diseases*, Springfield, Ill
Reitschel, A (1931) In Pfaundler-Schlossmann's *Handbuch der Kinderheilkunde*, Leipzig, vol 2, p 264
Roedelius, E (1913), *Z Hyg Infekt Kr* **75**, 497.
Rolleston, J D, and Ronaldson, G W (1940) *Acute Infectious Diseases* Lond, 3rd ed
Roskam, J (1934) *Sang*, **8**, 129
Rudisill, H (1936) *J Amer Med Ass* **107**, 2119
Rundle, C (1929) *Ker's Infectious Diseases* Lond, 3rd ed
Schiff, E, and Matyas, E (1918) *Mschr Kinderheilk.* **15**, 254
Simpson, R E H (1940) *Brit Med J* **1**, 830
Sprott, N A (1940) *Ibid* **2**, 154
Stitt, E R (1927) *Practical Bacteriology, Blood Work and Animal Parasitology*, Lond, 8th ed, p 324
Stratford, E (1911) *Lancet*, **2**, 156
Ström, J (1940) *Acta Med scand* **105**, 160
Suffern, C (1940) *Lancet*, **1**, 607
Taniguchi, T, Joogetsu, M, and Kasahara, T (1930) *Jap J Exp Med* **8**, 55
Tidy, H L (1940) *Brit Med J* **1**, 869
Tocantins, L M (1938) *Medicine*, **17**, 155
Warren, H D, Rogland, F T, and Potsubay, S F (1946) *Med Clin North Amer* **30**, 401
Weiner, J J, and Carter, R F (1941) *Ann Surg* **113**, 57.
Welt, B, and Kasnetz, J (1938) *Arch Otolaryng*, **27**, 732
Wilkinson, P B (1943) *Lancet*, **1**, 120
Winternitz, M C (1912) *Arch Intern Med* **9**, 680
Witney, E W (1940) *Brit Med J* **1**, 831
Wright, J H (1910) *J Morph* **21**, 263

APPENDIX

Summaries of Case-histories of Patients with Uncomplicated Rubella

N B In each of these cases the diagnosis of rubella was confirmed by a member of the staff of the Bristol Royal Hospital for Sick Children and Women

Case 4, a young woman aged 22 years

9 4 40 First noticed rash on face
10 4 40 Rash very profuse all over body and a few spots on hands and feet
13 and 14 4 40 Occipital glands enlarged Rash fading Joint pains present, chiefly in wrists, also in knees and ankles Patient has felt well all the time
19 4 40 Menstrual period began

Case 5, a man aged 39 years

11 4 40 Rash appeared on face, arms, and chest Occipital glands enlarged.
13 4 40 Rash disappeared Patient has felt well all the time

Case 6, a girl aged 5 years

20 4 40 Rash appeared on neck and shoulders Occipital glands enlarged
21 4 40 Rash generalized Patient feels well
25 4 40 Rash gone

REFERENCES

Alrutz, L F, Nortell, J L, and Pietto, E C (1926) *Arch Path* 1, 356
Ammundsen, E, Bang, J, Franck, G, Hansen, A, Lassen, H C A, Poulsen, J P Vald, Snorrason, E, Thygesen, P, Vimstrup, B J, and Zimsen, H H (1947–8), *Acta med scand* 129, 415
Baar, H, and Gasul, B M. (1929) *Amer J Dis Child* 37, 126
Baehr, G., Klemperer, P, and Schifrin, A (1936) *Trans Ass Amer Phys* 51, 43
Bannerman, R G (1924) *Brit J Exp Path* 5, 16
Beck (1924) *Monatschr f Kinderh* 29, 673
Bedson, S P (1922) *J Path Bact* 25, 94
Bennett, R A, and Copeman, W. S C (1940) *Brit Med J* 1, 924
Box, C R (1933) *Lancet*, 1, 1217
Bull, C G, and McKee, C M (1922) *Amer J Hyg* 2, 209
Cheadle, W B (1881) *Tr Internat Med Congress*, 4, 4
Dameshek, W, and Miller, E B (1946) *Blood*, 1, 27
Dean, C A, and Wright, C S (1946) *Ibid* 1, 10
Dudgeon, L S, and Goadby, H K (1931) *J Hyg* 31, 247
Duke, W W (1913) *Arch Intern Med* 11, 100
Dunlop, A (1871) *Lancet*, 2, 464
Elliott, R H E, and Whipple, M A (1940–1) *J Lab Clin Med* 26, 489
Evans, F B P (1942) *Brit Med J* 1, 240
Fonio, A (1912) *Dtsch Z Chir* 117, 176
Fowler, W M (1936) *Ann Intern Med* 9, 1475
Fox, M J, and Enzer, N (1938) *Amer J Med Sci* 196, 321
—— and Walton, W P (1946) *Marquette Med Rev* 11, 208
Frey, H C (1928) *Frankfurt Ztschr f Path* 36, 419
Gee, S (1905) In Allbutt and Rolleston's *System of Medicine*, Lond, 2nd ed, vol 2
Gerstenberg, H W, and Reinwein, H (1940) *Beitr Klin Tuberk*, 95, 517
Glaister, J (1881) *Tr Internat Med Congress*, 4, 31
Govaerts, P (1921) *Arch Int Physiol* 16, 1
Gunn, W (1933) *Brit J. Child Dis* 30, 111
Harries, E H R, and Mitman, M (1940) *Clinical Practice in Infectious Diseases*, Edinburgh
Harrison, B L (1940) *Brit Med J* 1, 637
Hay, S (1940) *Edinb Med J* 47, 345
Hecht, A (1907) *Jb Kinderheilk* 65, 113
Hess, A F (1916) *Arch Int Med* 17, 203
Hodges, G M W (1940a) *Brit Med J* 1, 548
—— (1940b) *Ibid* 2, 238
Hottinger, quoted by Reitschel (1931)
Ikeda, K (1925) *J Amer Med Ass* 84, 1807
—— (1928) *J. Lab Clin Med* 13, 440
Ivy, A C, Shapiro, P F, and Melnick, P (1935) *Surg Gynec Obstet* 60, 781
Kaznelson, P (1916) *Wien klin Wschr* 29, 1451
—— (1919) *Z klin Med* 87, 133
Kellert, E (1931) *J Amer Med Ass* 96, 2193
Kernau, T (1938) *Arch Kinderheilk* 115, 242
Kienle, F (1942) *Folia haemat* 66, 299
Leede, W (1911) *Z Hyg Infekt Kr.* 69, 225
Leitner, S J (1945) *Die intravitale Knochenmarksuntersuchung* Basel
Limarzi, L R, and Schleicher, E M (1940) *J Amer Med Ass* 114, 12
Lloyd, P C (1944) *Amer J Med Sci* 207, 620
Mackay, W (1930–1) *Quart J Med* 24, 285
Magnusson, J H (1946) *Acta Med scand* 126, 40
Minot, G R (1917) *Arch Intern Med* 19, 1062

Fig 3 Case 3, coronal section of the brain showing the extent of the haemorrhage

Fig 4 Case 3 A large mature megakaryocyte with an ingested polymorph From a section of the femoral marrow ×600

Fig 5 Case 3 A group of megakaryocytes from the femoral marrow, showing the normal morphology of these cells ×600

Case 6 (continued).

27 4 40. Urticaria. Numerous wheals all over trunk Has never had an attack before

16 5 40 Recovered from urticaria.

Case 7, a young woman aged 21 years

11 4 40 Occipital glands enlarged No rash

12 4 40 Generalized rash Patient feels ill

17 4 40. Rash fading, but still faintly seen on face and neck Epistaxis (she does not usually get epistaxes) Joint pains in knees Feels well

1 5 40 Menstrual period due.

Case 8, a girl aged 18 years

8 5 40 Feels well Rash on face, chest, and arms L submaxillary gland enlarged No other glands enlarged Slight conjunctivitis Menstruating

11 5 40 Rash disappeared Slight desquamation on face.

21 5 40 Complained of 'tinglings' in both hands No objective sensory changes

5 6 40 No further 'tinglings'.

FIG 3 Case 3, coronal section of the brain showing the extent of the haemorrhage

FIG 4 Case 3 A large mature megakaryocyte with an ingested polymorph From a section of the femoral marrow ×600

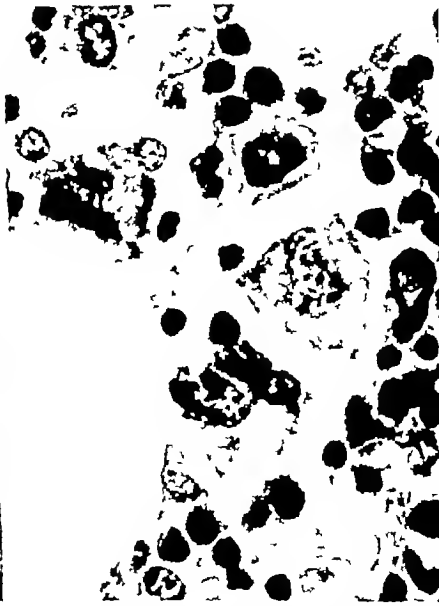

FIG 5 Case 3 A group of megakaryocytes from the femoral marrow, showing the normal morphology of these cells ×600

Case 6 (continued)

27.4.40. Urticaria. Numerous wheals all over trunk Has never had an attack before

16 5 40 Recovered from urticaria

Case 7, a young woman aged 21 years

11 4 40 Occipital glands enlarged No rash

12.4 40. Generalized rash Patient feels ill

17 4 40. Rash fading, but still faintly seen on face and neck Epistaxis (she does not usually get epistaxes) Joint pains in knees Feels well

1 5 40. Menstrual period due.

Case 8, a girl aged 18 years.

8 5.40 Feels well Rash on face, chest, and arms L submaxillary gland enlarged No other glands enlarged. Slight conjunctivitis Menstruating

11 5.40 Rash disappeared Slight desquamation on face.

21 5.40 Complained of 'tinglings' in both hands No objective sensory changes

5 6.40 No further 'tinglings'.

616 831 43–008 64

THE SYNDROME OF HYPOPITUITARISM[1]

By H L SHEEHAN and V K SUMMERS

(From the Department of Pathology, University of Liverpool)

With Plates 34 to 37

The purpose of the present paper is to clarify some aspects of the syndrome which results from loss of the anterior pituitary In a previous paper (Sheehan, 1939) a specific analysis was made of the syndrome which results from post-partum necrosis of the anterior pituitary The present review is not restricted in that way, but includes all varieties of destruction of the gland The subject will be dealt with in two parts, firstly the pathological lesions which destroy the pituitary, and secondly the clinical syndrome which had been present in those patients who were proved at autopsy to have been suffering from such a destruction of the gland The treatment of the disease will not be discussed

In his original description, Simmonds (1914*a*) set up the one essential criterion of the disease, the loss of the pituitary It is necessary to emphasize the primary importance of this, the pathological basis of the syndrome, since it must be the foundation of accurate clinical diagnosis Simmonds's description of the pathological lesions and the clinical syndrome in his original patient was remarkably good in view of the fact that it was made over 10 years before the modern advances in pituitary physiology Nevertheless it cannot now be accepted as a full and completely accurate description of hypopituitarism in human patients The subsequent period saw the acceptance of a false syndrome with an emphasis on loss of weight as a characteristic feature This led to the publication of a great number of case reports of emaciated patients under the unproved diagnosis of Simmonds's disease (Curschmann, 1929, von Bergmann, 1934, Kylin, 1935) Other workers during the past 10 years have attempted to place the clinical diagnosis of hypopituitarism on a firmer basis With this purpose, Escamilla and Lisser (1942) made a very important critical analysis of the cases published as Simmonds's disease They accepted as reliable only those cases which presented certain clinical features that they regarded as essential for the true diagnosis These four cardinal characteristics were (1) loss of weight, (2) loss of sexual function, (3) asthenia, (4) a very low basal metabolic rate From the study of the clinical records of the cases that they had accepted on this basis, and mainly on their Group A of 101 'typical clinical cases with pathological verification', they analysed in detail the clinical syndrome of Simmonds's disease However, a study of their 101 cases shows that only 37 had severe pituitary lesions of long duration and uncomplicated by hypothalamic pressure Furthermore, it is obvious that by their method of approach the

[1] Received November 26, 1948.

hypopituitarism. For this reason, eosinophil adenomas producing acromegalic effects and basophil adenomas associated with Cushing's syndrome have been discarded Tumours with no clear evidence of secretory activity have been accepted

(c) Certain of the pathological lesions in the pituitary which are associated with dwarfism have been cursorily mentioned in the pathological section, but are not considered in detail in the present review

The severity of the lesion This is probably the most important matter to be discussed A direct relationship may reasonably be expected between the degree of destruction of the gland and the severity of the resultant clinical symptoms It is surprising that, in the various reviews of Simmonds's disease in the literature, very little attention seems to have been paid to the degree of destruction of the anterior pituitary Even very slight pathological alterations in the gland have been regarded as satisfactory proof of the existence of hypopituitarism if the clinical features were in conformity with the commonly accepted syndrome

Each pathological process may produce any degree of damage to the anterior pituitary, ranging from negligible lesions up to almost complete destruction of the gland. The present classification of the severity of the lesions has been made purely on the morphological changes in the pituitary (the microphotographs and pathological description) without any regard to the clinical symptoms The pathological records are rarely sufficiently detailed to allow any accurate calculation of the percentage of the gland destroyed, but it is possible to classify the damage fairly satisfactorily into four degrees—severe, moderate, minor, and slight

The term severe implies that the gland has suffered complete or nearly complete destruction, with only very trivial islets of parenchyma remaining Total destruction of the gland probably never occurs, whatever the pathological process, a sufficiently careful histological investigation nearly always shows small vestiges of parenchyma, although these may not amount to more than 1 or 2 per cent of the gland Even surgical hypophysectomy may leave parts of the anterior lobe

The term moderate covers cases with destruction of about three-quarters of the anterior lobe The remains of the parenchyma, although small, may be considered sufficient to maintain some effective function This group also includes a few cases where the pathological description is not very detailed, but the lesion appears probably to have been of either severe or moderate degree

The term minor indicates destruction of only about one-half of the lobe It is extremely doubtful whether such destruction is sufficient to produce any significant functional insufficiency

The term slight is applied to a series of cases with destruction of one-quarter of the lobe or less The more trivial of these cases would not merit consideration, were it not for the fact that they figure in many of the standard papers as classical cases of pathologically proved Simmonds's disease The chief purpose of listing these cases here is to eliminate them from quotation in future

syndrome must inevitably contain the four clinical criteria which were set up initially as cardinal characteristics No answer can be obtained to the question of whether these are in fact cardinal characteristics, and thus whether their cases were really typical

The present review is based on a fundamentally different criterion, the pathological one that Simmonds originally employed, namely, the concrete evidence of the destruction of the anterior pituitary There can be no doubt that this lesion must inevitably produce a corresponding loss of function of the gland An analysis restricted to patients who were proved to have gross destructive lesions of the anterior pituitary should thus give reliable evidence as to what the clinical syndrome of severe hypopituitarism really is

Part 1. Pathological Lesions of the Pituitary

An initial study has been made of all available records of cases in which the pituitary was examined *post mortem* and found to show pathological lesions A number of these have been discarded, such as cases with inadequate pathological data, cases with seriously inadequate clinical data, and certain others for reasons explained below The remainder have been retained for more detailed analysis according to four particular features of the pathological lesion

The aetiology and pathology of the lesion This will be discussed subsequently and needs only brief mention here The anterior pituitary may be removed surgically It may be destroyed by acute or subacute lesions, these may be seen in their early stage, or in their final healed stage when they are represented merely by scar tissue It may be destroyed by fibrosis of uncertain aetiology Finally it may be obliterated by pressure from slowly growing tumours or cysts

The duration of the lesion Lesions which are of long duration are of direct interest Those which are of short duration fall into two categories

(*a*) Acute or subacute conditions which are potentially the early stage of a chronic fibrosis These can give no information about the clinical syndrome of prolonged hypopituitarism, but their pathological relevance is such that they merit consideration They include recent necroses of whatever causation, granulomas, and other inflammatory processes

(*b*) Purely terminal conditions have been discarded as they cannot lead to long-standing lesions Examples are the involvement of the gland by malignant tumours, either metastatic or invading from neighbouring structures, miliary tuberculosis (Schmidtmann, 1919), or surface involvement in purulent or tuberculous meningitis

Complicating factors The complications are of three main types

(*a*) The pressure effects on the hypothalamus and other neighbouring structures produced by suprasellar masses It is difficult to differentiate certain of the effects of hypopituitarism from those of hypothalamic pressure, and these complicated cases are therefore separated sharply from the accepted ones

(*b*) Secreting tumours of the pituitary However severe the destruction of the remainder of the gland, such tumours cannot be considered as leading to true

Massive gummatous necrosis In this group of cases the pituitary is enlarged to about 1 5 to 2 0 gm in weight, but does not usually produce any local pressure symptoms There is a large necrotic mass in the anterior lobe, commonly spreading to involve the posterior lobe also It is usually surrounded by a layer of granulation tissue showing giant cells and plasma cell infiltration Around this there is a fibrous tissue capsule which is sometimes firmly welded to the floor of the sella A considerable amount of evidence is available to indicate that the condition is syphilitic in origin In all of these patients there were gummata in the liver, and in five there were gummata in the skull bones The lesion appears probably to have been of short duration, as judged from the histology, but it is impossible to fix the time of onset of the lesion because few or no symptoms were produced. The patients were usually aged 40 to 60 years, and there was a striking predominance of women It is of interest that nearly all these cases date from before the time when arsenical therapy for syphilis was introduced

References 204 (4), F 44, 125, F 45, 270, F 44, 14 (1), F 41, 138, F 47, 278, F 52, 260, M 78, 304, M 52, 22, F 57, 299, F 27 (In these lists the first number is that given in the References, the figure in brackets is the case number in the paper, and these are followed by the sex and age of the patient The order is that of the date of publication)

Massive tuberculous caseation The pituitary is enlarged and consists mainly of a mass of caseous material, usually surrounded by granulomatous tissue containing giant cells of Langhans type In most cases both lobes are involved Pathologically the lesion is very similar to massive gummatous necrosis However, in one case (Knoll, 1922) tubercle bacilli were found, and five of the patients had tuberculosis elsewhere in the body In three cases there was in addition a tuberculous meningitis in the region of the chiasma, and two patients had associated tuberculosis of the sphenoid The patients were usually in the 20- to 40-year age-group, and none showed any evidence of syphilis These lesions do not appear to have been of long duration Some of the patients had headaches for 10 to 20 weeks, and one had diabetes insipidus for a similar period

References 272, F 48, 123, M 13, 246, F 27, 117 (2), F 36, 156, M 23, 152 (1), F 37

Massive granulomatous necrosis of uncertain aetiology In these cases the entire pituitary was replaced by a mass of necrotic tissue surrounded by a granulomatous reaction The pathological appearances were similar to those of massive gummatous necrosis or massive tuberculous caseation One of the patients was diagnosed as having a gumma of the cerebellum and another as having syphilis, but in both cases the Wassermann reaction was negative In the two cases in which data are available, there had been local pressure symptoms (diabetes insipidus and headaches) for one to two years

References 15, M 17, 291, F 13, 292 (3) F 64, 40 (Gp 1, 1), F 57, 303, M 37, 50, F 9, 44 (8), F 23, 45 (1), M 31, 45 (2), M 54, 42, F 65, 90, F 34, 91 (1), F 40

Giant cell granuloma of the anterior pituitary In these patients there is replacement of nearly all the anterior pituitary by multiple small granulomatous

Grouping of cases The cases are analysed below in five main sections, (1) acute lesions, (2) subacute lesions, (3) chronic fibroid lesions, (4) surgical hypophysectomy, (5) cysts and tumours In each of these sections they are divided into primary groups according to the type of pathological process, with subclassification according to the severity of the lesion The differentiation of the various pathological processes and the title allotted to each type is arbitrary, and is based usually on the morphological appearances, but sometimes on the aetiology when this is reasonably well established

Acute Lesions

The lesion is nearly always a necrosis of the anterior pituitary The extent of the necrosis varies, and the duration of the acute stage is a matter of days or, at most, a few weeks At this stage there are no obvious symptoms of hypopituitarism, though some of the cases have been accepted as true cases of Simmonds's disease by previous reviewers In the later healed stage there will be pituitary deficiency related to the amount of parenchymal loss Most of the literature on this subject has been reviewed elsewhere (Sheehan, 1937, 1948) Necrosis may be due to various factors, such as diabetes mellitus (Kotte and Vonderahe, 1940, Feldman, Roberts, Susselman, and Lipetz, 1947), sinus thrombosis (Weisman, 1944), birth trauma (Schmitt, 1923, Berberich, 1926), temporal arteritis (Jennings, 1948), or unknown factors (Urechia and Retezeanu, 1939, Salomon and Lascano, 1942) It can be produced experimentally in animals (Dandy and Goetsch, 1910) But by far the commonest cause (79 of the 132 recorded necroses), and the condition which leads to the largest necroses, is severe circulatory collapse in an obstetric patient The usual cause of this circulatory collapse is shock and haemorrhage at about the time of delivery These necroses are not fatal in themselves and heal subsequently, leaving a small scarred anterior lobe Haemorrhage into the anterior pituitary has only rarely been reported When it was in any way gross, the accounts are always strongly suggestive of bleeding into a degenerating adenoma (Constobadie and Ryrie, 1924)

Subacute Lesions

The cases in this section are those in which it seems probable that the patient died within a few months after the onset of the pathological process In a few of the cases the hypothalamus was involved as well as the pituitary, such lesions are probably always fatal in the early stages and thus do not give rise to chronic lesions In most of the cases, however, the lesion was confined to the pituitary and might well have healed to a scar if the patient had survived longer In the subacute stage there are various degrees of severity of pituitary damage but, as the conditions are still actively progressing, the cases have not been subdivided according to this aspect The present classification, in five special groups and one miscellaneous, is based essentially on the pathological appearances, the aetiological diagnoses of the original authors have not always been accepted In the whole series, only one patient (Herlant, 1946, Case 1) had physical signs or pathological evidence suggesting a lack of pituitary hormones

there was severe destruction of anterior pituitary tissue, in others the lesions were quite trivial

References 13, F 33, 28, F 38, 168, F 61, 205, M 49, 242 (3), M 26, 206, M 43, 147, M 44, 80, F 15, 21, M 64, 305, M 24, 148, M 49, 282, M 42, 82, F 44, 285, F 42, 164, F 41, 71, F 23, 199, M 47

Chronic Fibroid Lesions

This is a very large series of cases, showing various degrees of long-standing scarring, fibrosis, and atrophy of the pituitary The lesion is sometimes confined to the anterior lobe, and in other cases involves the entire gland It is very difficult to arrive at a satisfactory classification for many of these cases Some appear to be slowly progressive fibroses of uncertain aetiology Others appear to be the late healed stage of acute or subacute conditions which occurred many years previously, in these cases practically all evidencé of the nature of the original lesion has disappeared, and only a small scarred gland is left However, there is one large group (the post-partum necroses) in which the original lesion can be identified from the history The remaining cases have been subdivided chiefly according to their histological characteristics Some of these groups are probably homogeneous in aetiology, in others there may have been a variety of aetiological factors leading to the same pathological appearance A number of dwarfs have been reported in whom the anterior pituitary is very small and fibrous and there are numerous middle-lobe cysts These cases, which will not be discussed further, are probably due to developmental abnormalities of the gland (Hueter, 1905, Simmonds, 1919, Kraus, 1919, Buchler, 1921, Heinrichs, 1931, Katzenstein, 1933, Apitz, 1938) In all, 13 separate groups of chronic fibroid lesions will be considered here

Healed post-partum necrosis of anterior lobe This subject has been discussed in previous papers and need only be summarized briefly In patients who have suffered an ischaemic necrosis of the anterior pituitary at delivery, the necrotic area gradually heals, leaving a loose fibrillar scar The areas of originally undamaged parenchyma remain as small islets of healthy tissue The severity of the general circulatory collapse which gives rise to the necrosis determines the size of that lesion, and this in turn determines the extent of the final scarring There are thus gradations in severity of the ultimate damage to the gland The slight and moderate cases will not be considered in the present paper as they have been described elsewhere (Sheehan, 1940, Béclère and Simonnet, 1946) The cases classed as severe show destruction of practically all of the anterior pituitary, the amount of tissue loss with this lesion is quite as great as that with any of the other pathological processes The anterior pituitary appears to the naked eye as a loose network of fibrous tissue in the sella in front of a normal posterior lobe This fibrous tissue is sometimes condensed to a more solid scar, or may even soften to a cystic structure Microscopically there is usually a small remnant of anterior pituitary tissue at the base of the stalk, and a few tiny islets of cells under the capsule, these are not fibrotic In the previous review a list was given of 33 examples of this lesion which had been proved

nodules resembling tubercles and histologically showing giant cell systems, but only rarely with central necrosis or caseation (A more detailed description is given in the Appendix) There is also extensive infiltration by lymphocytes and plasma cells, and moderate fibrosis. The posterior lobe is sometimes involved in the more severe cases The pituitary is slightly enlarged, but rarely produces any local pressure symptoms Six of the patients had similar lesions in the brain, two involving the dura, one producing multiple surface nodules on the temporal lobe, cerebellum, and pons, while the other three patients had lesions diagnosed as gummata in the brain Certain of these patients were definitely syphilitic, and in one case spirochaetes were found in the pituitary Two of the patients had been suffering from diabetes mellitus for two to three years, and died subsequently from subarachnoid haemorrhage of indefinite aetiology The group may include lesions due to several different causes, such as syphilis, tuberculosis, or sarcoidosis, but most of the cases appear to be examples of a specific disease process whose aetiology is unknown In one non-fatal case of this type (Coleman and Meredith, 1940) tubercle bacilli could not be found by guinea-pig inoculation Certain of the descriptions suggest that the giant cells are formed from parenchyma cells, and that the lesion is really analogous to the pseudo-granulomatous nodules in an atrophying thyroid Nearly all the cases described have been in women aged 45 to 65 years There do not appear to be any particular symptoms by which the duration of the lesion can be assessed, although some of the patients had evidence of cerebral lesions for a year or two before death

References 173, F 45, 297 (2), M 48, 167 (1), F 47, 186, F 65, 306, F 46, 262 (1), F 63, 262 (2), F 73, 262 (3), F 61, 262 (4), F 50, 262 (5), F 49, 97, F 32, 144, F 53, 54, F 43, 165 (2), F 56, 77, F 66, 219 (2), M 28, 298, F 62

Granuloma of hypothalamus and pituitary This group is characterized by a large mass in the region of the hypothalamus and chiasma, made up of small granulomatous nodules resembling tubercles The lesion extends down into the pituitary, where it spreads out to involve the anterior and posterior lobes Sometimes the anterior lobe is more extensively involved than the posterior, but in other cases the reverse holds true The granulomas show central caseation and Langhans giant cells without much round celled infiltration The pituitary itself is usually little altered in size The aetiology is uncertain, two patients had syphilis and two had tuberculosis It is of interest that the usual age incidence falls between 20 and 40 years, as in the cases grouped as massive tuberculous caseation The symptoms were predominantly hypothalamic, three of the patients had diabetes insipidus which lasted for a few months before death

References 121, F 6, 203 (1), F 36, 117 (1), F 32, 117 (3), F 21, 242 (1), F 22, 92, M 32, 33 (3), M 24, 162 (1), F 23, 217, F 33, 126 (1), F 36

Miscellaneous subacute lesions This heterogeneous group contains examples of chronic abscesses, slight chronic inflammation, actinomycosis, cysticercosis, sarcoidosis, lymphadenoma, and leukaemic infiltrations In some of the cases

Cystic degeneration of anterior lobe The anterior pituitary, though apparently normal on external appearance or only slightly shrunken, is found to be only an empty sac Its wall consists of a thin layer of fibrous tissue in which there are small islets of parenchyma, the inner surface of the wall is slightly shaggy, the lumen of the cyst is apparently empty The posterior lobe usually remains intact The condition may be caused by some gradual degenerative process in the anterior lobe, but there have been no descriptions of any early stage of the process Symptoms do not usually develop until late middle age, and most of the patients live for several years longer

References Severe 223, M 50, 145 (3), M 80, 66, M 28, 200, F 69 *Moderate* 39, F 60

Capsular and interstitial fibrosis of anterior lobe The pituitary is small, usually about 0 35 to 0 4 gm, and there is atrophy of the anterior lobe The capsule is very much thickened by dense fibrous tissue Coarse bands of fibrous tissue run from the capsule through the substance of the anterior lobe, and subdivide the gland into islands of various sizes Near the surface these islands are usually small, as if a slowly progressive fibrosis were spreading in from the capsule There is always a considerable amount of parenchyma remaining, though sometimes with some interstitial fibrosis and atrophic changes in the cells The posterior lobe is unaffected The aetiology of this particular 'cirrhosis' is not clear, but the pathological changes are sufficiently uniform to suggest one common causative factor There is insufficient information available to decide the incidence of syphilis in the group The patients may have a variety of symptoms, which do not appear to be of pituitary origin and have little or no relation to the severity of the pituitary lesion These symptoms usually originate at 30 to 45 years of age

References Moderate 41, 110, M 52, 130, 140 (1), M 55, 35, F 69, 216, F 49, *Minor* 20 (5), F 66, 307 (3), F 24, 111, F 52, 202 (2), F 42, 184, F 54, 118, 119, M 35, *Slight* 284, M 29, 193, M 29

Interstitial fibrosis of anterior lobe Some of these cases are similar to the group classified as capsular and interstitial fibrosis, but the lesion is much less severe and, in particular, there is no record of thickening of the capsule The pituitary is either of normal size or shrunken There is a slight increase of connective tissue diffusely through the anterior lobe The posterior lobe is normal There is no evidence to indicate the aetiology of this lesion, though cerebral arteriosclerosis may possibly play a part Interstitial fibrosis appears to be a common finding in a variety of diseases In addition to the individual cases listed below, several series have been recorded in less detail Thaon (1907) described this lesion in 13 patients with pulmonary tuberculosis, Parhon and Briesse (1922) in eight cases of insanity and epilepsy, Morse (1923) in nine cases of dementia precox, Simonds and Brandes (1925) in seven senile patients, Rizzi (1941) in 15 babies with congenital syphilis, and Goldzieher (1946) in nine cases of obesity

References Minor 52, 53, M 47, 307 (5), F 35, 108, F 43, 249, F 64, 170 (2), F 47, 178 (2), F 80, 302, 3, F 25 *Slight* 87, M 58, 7, M 43, 44 (7), M 43, 277 (6), F 53, 296 (3b), —, 237 (1), M 26, 245, M 60, 177, F 70

pathologically, 29 further cases of severe grade are listed below The date of onset of the disease is accurately known in nearly all the cases naturally it is nearly always when the patient is between 20 and 40 years old

References Severe 220, F 33, 273, 274, F 38, 86 (1), 85 (3), F 45, 116 (R R), F 40, 198, F 60, 85 (2), F 42, 85 (4), F 43, 183 (1), F 43, 183 (2), F 40, 189, F 49, 197 (5), F 35, 197 (6), F —, 197 (7), F —, 30 (2), F 63, 30 (3), F 51, 290, F 51, 181 (2), F 68, 300 (1), 301 (1), 63 (3), F 45, 37 (2), F 48, 256, F 38, 143 (1), F 66, 236, F 44, 57, F 59, 289 (5), F 35, 268 (25), F 57, Appendix (CL), F 33, Appendix (RG), F 34, Appendix (FL), F 51, Appendix (TB), F 52 *Uncertain severity* 151, F 60, 63 (AN), F 39, 63 (MT), F 61

Clinical cases of healed post-partum necrosis It is convenient at this point to interpolate a group of clinical cases due to post-partum necrosis These do not fulfil the basic requirement of pathological verification, and are thus not accepted in the present review as proved cases The diagnoses are, however, reliable, the patients had obstetric histories clearly indicative of a post-partum necrosis, and subsequently developed exactly the same syndrome as occurred in the pathologically proved cases A few died but had no post-mortem examination of the pituitary. In the previous review, 19 clinical cases of post-partum necrosis were analysed The present review deals with 51 further severe cases The case of Vandenbroeck and Ferin (1947) is a complicated one, as the necrosis appears to have been due to the combination of premature delivery with diabetes mellitus The case of Merlino (1941) and cases TR and CR of Daughaday, Williams, and Daland (1948) are not sufficiently detailed for inclusion in the series.

References Severe 81 (12), F 38, 215 (1), F 30, 1, F 35, 175, F 31, 233, F —, 257 (Gp A) 8 cases, 257 (3), F 47, 257 (4), F 37, 257 (5), F 33, 257 (6), F 28, 11, F 29, 275 (6), F 23, 275 (7), F 31, 107, F 48, 271 (9), F 38, 197 (3), 96 (1), 181 (1), F 30, 197 (4), 96 (2), F 54, 96 (3), F 34, 96 (4), F 32, 59 (2), F 29, 37 (1), F 52, 143 (2), F 52, 143 (3), F 50, 133, F 35, 101, F 40, 48, F 56, 289 (1), F 63, 289 (2), F —, 289 (3), F —, 289 (4), F —, 12, F 48, 288 (H), F 45, 288 (R), F 47, 286, F 35, 268 (24), F 30, Appendix (PM), F 37, Appendix (SM), F 34, Appendix (MY), F 43, Appendix (RB), F 43, Appendix (DV), F 47, Appendix (BS), F 35, Appendix (AM), F 38, Appendix (AG), F 49, Appendix (DL), F 50.

Indeterminate scarring of anterior lobe In this group the pathological appearances are very similar to those of healed post-partum necrosis, and suggest that the lesion may be the healed stage of some necrosis of uncertain origin It is possible that a few of the cases may actually be healed post-partum necroses, but there is no clinical evidence to support this view On the other hand, the scarred stage of a granuloma or of some other pathological process might give a similar picture The pituitary is very small The anterior lobe consists of a shrunken mass of acellular connective tissue with very small islets of remaining glandular tissue The posterior lobe is normal In this group are included four cases in which the pathological data are incomplete

References Severe 263 (4), F 35, 43, M 40, 187 (7), F 72, 176, F 76, 300 (5), 301 (5), 63 (2), F 47, 126 (2), M 50, Appendix (GN), F 77 *Moderate* 137, F 52, 182 (18), F 53, 155 (6), F —, 190, F 64, 29, F 66, 128, F 66, 142 (2), F 42, 78, F 61 *Minor* 287, M 44, 135, M 23, 67 (1), F 46

pressure at the time of onset of the disease The 'empty sella' lesion probably develops in middle age or later, and may be present for several years before death

References Severe 194, F 61, 208, 209, M 58, 4, F 48, 114, F 40, 251, F 62, 126 (4), F 64 *Moderate* 221 (24), M 54, 34 (2), F 69 *Minor* Appendix (MG), F 63

Healed tuberculosis of the pituitary The appearances in these cases have many similarities to those seen in healed granuloma, but there is a definite description of caseation in the centre of the nests of epithelioid cells Case 2 of Berblinger (1939) was proved to have still smouldering tuberculosis by the finding of acid-fast bacilli in the lesions The other two cases were not proved bacteriologically

References Severe 163, F 25 *Moderate* 34 (4), F 41, 24 (2), F 52

Healed gummatous necrosis of pituitary This small group of cases appears possibly to represent the very late healed stage of pituitary gumma The clinical history is usually characteristic Three of the patients had a sudden onset of suprasellar symptoms, including diabetes insipidus and optic nerve pressure These local symptoms gradually disappeared The similarity to the symptoms of various of the subacute lesions discussed previously will be noted At autopsy 10 to 24 years later the pituitary was represented by a flattened mass of dense scar tissue, in which there were sometimes small islets of non-fibrotic parenchyma The posterior lobe was either unrecognizable or was small and grossly fibrotic The patients had clear histories of syphilis and had gummatous scarring of their livers In peculiar contrast to the cases of active gummata discussed in the section on subacute lesions, these patients were chiefly male, the onset of symptoms was at age 17 to 30 years, and the original lesion had been large enough to produce suprasellar pressure

References Severe 228, 229, M 29, 62, M 49 *Moderate* 185, F 34, 89, M 50

General scarring of pituitary In this group there is very extensive scarring of the whole gland, including the posterior lobe The pituitary is very small in the severe cases The anterior lobe consists of scar tissue in which there are islets of fibrotic or non-fibrotic parenchyma The posterior lobe is usually involved less severely, but is sometimes unrecognizable This is probably a heterogeneous group, and various aetiological factors may be responsible The pathological descriptions are sometimes very deficient in detail

References Severe 95, M —, 213, F 59 *Moderate* 86 (2), 85 (1), M 50, 180 (2), M 48, 174, F 53

Fractured base of skull Trauma has been put forward as the explanation of various cases of pituitary fibrosis, but in many of them gonadal function appears to have continued unimpaired for several years after the head injury Only two examples have been found of head injury as an undoubted cause of pituitary damage In one of these cases the anterior lobe was extensively scarred and the posterior lobe unrecognizable, in the other there was some scarring in the anterior lobe, but the posterior lobe was normal

References Severe 231, M 34 *Minor* 244, M 28

Cytological changes and atrophy of anterior lobe The gland is sometimes slightly reduced in size or may appear macroscopically normal It shows trivial or doubtful histological changes of various types, such as atrophic appearances or cytological disturbances of parenchyma cells, dilatation of capillaries, &c The patients in this group cannot be considered to have suffered from significant loss of pituitary tissue, and the changes often appear to be little more than the results of post-mortem autolysis and poor fixation

References Slight 266, 307 (4), 267 (1), F 42, 225 (1), M 38, 27, M 41, 250 (1), 25, F 24, 170 (3), M 50, 170 (17), F 21, 170 (22), 171 (11), F 18, 191, F 48, 75 (2), F 17, 26, F 21, 17, M 72, 100, M 14, 65, F 28

Healed granuloma of anterior lobe This group is separated from the other fibroid lesions because the histological appearances suggest the healed stage of the giant cell granuloma of the anterior lobe which has been discussed under the heading of subacute lesions In what are probably the more recent cases the pituitary is of normal size, but in the presumably longer-standing cases the gland becomes very small (0 2 to 0 3 gm) and may finally be represented mainly by a layer of scar tissue on the floor of an 'empty sella' The anterior lobe is extensively scarred and contains small groups of cells of 'epithelioid' appearance with occasional giant cells The origin of these giant cells is in dispute, as noted in connexion with the subacute lesions Small foci of calcification are commonly present Lymphocytic infiltration is variable The posterior lobe is normal or may show a slight surface involvement by the granulomatous process Most of the patients are women in the 45- to 65-year age-group

References Severe 237 (3), F 52, 23, M 50, 34 (1), F 51, 102, M 54, 126 (3), F 66 *Moderate* 79 (1), F 50, 152 (2), M 44, Appendix (WL), F 69, Appendix (PL), F 62

Empty sella This is a particular type of scarring in which, at the post-mortem examination, the sella turcica appears to be quite empty, but histological examination of the floor of the sella shows that there is a dense layer of fibrous tissue enclosing a very thin lamina of anterior lobe parenchyma The posterior lobe may be fairly well preserved, it may be shrunken into the fibrous tissue at the back of the sella, it may sometimes be quite unrecognizable If the brain is removed carefully, it is possible to observe the delicate attachment of the pituitary stalk to the floor of the sella (The scaphoid pituitary sometimes seen in routine autopsies may be a very minor degree of the lesion) The condition is anatomically very similar to that seen when the pituitary has been severely compressed by a suprasellar tumour, and certain authors have suggested that the condition was originally produced by pressure from a large cyst which subsequently disappeared completely Such an explanation may be considered fanciful, but it has the merit that it gives a vivid mental picture of the appearance of the sella in these cases A more plausible but quite unproved hypothesis is that the condition is the healed stage of a giant cell granuloma, cystic degeneration, or gumma of the pituitary, firm adhesion between the sella and the under surface of the pituitary would lead to a very flattened scar Only one of the patients had had syphilis and none gave a history suggesting any local

in the literature What has been done is to take a fairly large sample of the published cases, including in particular those in which post-mortem examination showed severe destructive changes in the pituitary, and also those in which a diagnosis of Simmonds's disease was put forward in the case report It is believed that the series analysed, while not comprehensive, is at any rate representative of the entire group Cysts of Rathke type, both intrasellar and extrasellar, have been recorded in dwarfs (Benda, 1900, Kon, 1908, Priesel, 1920, Nonne, 1922, Koch, 1926, Altmann, 1930, Baker and Craft, 1940, Rowlands, Simpson, Russell, and Turnbull, 1942) These will not be considered further

Intrasellar simple cysts The lesion in this group is a smooth-walled cyst, usually lined by columnar or cubical epithelium, and occupying the centre of the pituitary The gland as a whole is thus somewhat enlarged The larger cysts, which may be as much as 2 cm in diameter, lead to a pressure atrophy of the anterior and posterior lobes Sometimes the cysts are smaller so that they produce only moderate pressure effects, and at the lower end of the series they appear to be merely examples of large 'middle lobe cysts' They probably originate from remnants of the Rathke process There is no evidence as to when the cysts reach their full size, and thus as to their significant duration

References Severe 30 (1), F 61, 68, M 27 *Moderate* 81 (45), M 55 *Minor* 146, 307 (2), 154, M 28, 296 (3a), M — *Slight* 202 (1), M 35, 64 (1), F 59, 64 (2), M 17

Intrasellar cholesterol cysts This is a group of intrasellar 'cysts' which have a sufficiently distinctive appearance to warrant their consideration under a separate heading from simple cysts The pituitary is usually enlarged to about twice its normal size, and to the naked eye the anterior lobe appears to be replaced by a yellow mass Microscopically this consists of a large centre made up of solid eosinophil material, homogeneous or finely granular, in which there are numerous cholesterol crystals and small calcified spherules At the periphery there is a thick layer of fibrous tissue containing haemosiderin, either free or in phagocytes In some cases there is an epithelial lining of part of the cyst, either columnar or low squamous Around the mass are the flattened remains of the anterior lobe, with the capsule of the gland stretched over its surface The cyst seems to originate in the substance of the anterior lobe, the posterior lobe is normal or compressed The aetiology of the lesion is uncertain Healing gumma or tubercle, an encysted old haemorrhage, complete thrombosis of an aneurysm, necrosis of an adenoma, Hand-Schuller-Christian disease, and a special type of Rathke cyst have all been suggested The evidence on the matter is inconclusive, but the last of these explanations appears the most probable The duration of the lesion is also uncertain, but symptoms do not usually originate before middle age However, Erdheim (1916) recorded a cyst of this type in a 38-year-old infantile dwarf

References Moderate 31, M 21, 283, F 33, 131, F 57, 192 (1), M 40, 159, F 52, 36, M 67, 32, F 45 *Minor* Appendix (BL), M 68

Hypophysectomy

There are many records of the surgical removal of pituitary tumours where, in the course of the operation, most of the remaining pituitary gland appears to have been removed as well These cases are too complicated by the effects of the tumour to be of present significance, and usually lack autopsy verification Only two cases have been found of deliberate operative removal of the apparently normal pituitary in human beings Chabanier, Puech, Lobo-Onell, and Lelu (1936) removed the pituitary from a man aged 24 years suffering from severe diabetes. This controlled the hyperglycaemia but, six months later, the patient developed pulmonary tuberculosis, became severely emaciated, and died Elden (1936) recorded a hypophysectomy for epilepsy in a 15-year-old negress The clinical details are also given by Stephens (1939, 1940) The patient died six years later, and at autopsy (Elden and Kummer, 1943) it was found that only about 10 per cent of the gland remained The adrenals, thyroid, and genitalia were atrophic, pubic and axillary hair was lost, and amenorrhoea had been present since the operation The patient lost 22 lb in weight after the operation and then regained 27 lb , at death at age 22 years she appears to have been of normal nutrition, with a weight of 128 lb

Cysts and Tumours

These growths produce pressure atrophy of the pituitary as a result of their position in relation to the sella Three general matters need to be mentioned before the groups are considered in detail

1 The growths fall into two main divisions The first consists of purely intrasellar growths with no pressure on the overlying structures The effects are strictly those of hypopituitarism, and these cases are thus of direct value in the present study The second main division is made up of what may be called extrasellar growths These originate either above or below the sellar diaphragm, and project both upwards and downwards Thus they press not only on the pituitary, but also on the chiasma, hypothalamus, and the brain above The non-pituitary pressure gives rise to a variety of general effects which may vary, not only according to the site of the pressure, but also according to whether the mass is progressive in size or has reached a stationary condition

2 The severity of the pathological lesion of the pituitary is often uncertain The tumour spreads out the remains of the pituitary as a thin layer, often with quite a large area This layer may be either on the upper surface of the tumour or in the fibrous floor of an apparently empty sella The assessment of the amount of remaining parenchyma requires, what is very rarely attempted, a quantitative histological study of serial sections of the entire area where there may be pituitary tissue Thus the sub-classification of this group according to the severity of the lesion is probably much more liable to error than that in the other groups

3 It is clearly impossible, within the limits of the present article, to give a complete list of the enormous number of pituitary tumours and cysts recorded

in the literature What has been done is to take a fairly large sample of the published cases, including in particular those in which post-mortem examination showed severe destructive changes in the pituitary, and also those in which a diagnosis of Simmonds's disease was put forward in the case report It is believed that the series analysed, while not comprehensive, is at any rate representative of the entire group Cysts of Rathke type, both intrasellar and extrasellar, have been recorded in dwarfs (Benda, 1900, Kon, 1908, Priesel, 1920, Nonne, 1922, Koch, 1926, Altmann, 1930, Baker and Craft, 1940, Rowlands, Simpson, Russell, and Turnbull, 1942) These will not be considered further

Intrasellar simple cysts The lesion in this group is a smooth-walled cyst, usually lined by columnar or cubical epithelium, and occupying the centre of the pituitary The gland as a whole is thus somewhat enlarged The larger cysts, which may be as much as 2 cm in diameter, lead to a pressure atrophy of the anterior and posterior lobes Sometimes the cysts are smaller so that they produce only moderate pressure effects, and at the lower end of the series they appear to be merely examples of large 'middle lobe cysts' They probably originate from remnants of the Rathke process There is no evidence as to when the cysts reach their full size, and thus as to their significant duration

References Severe 30 (1), F 61, 68, M 27 *Moderate* 81 (45), M 55 *Minor* 146, 307 (2), 154, M 28, 296 (3a), M — *Slight* 202 (1), M 35, 64 (1), F 59, 64 (2), M 17

Intrasellar cholesterol cysts This is a group of intrasellar 'cysts' which have a sufficiently distinctive appearance to warrant their consideration under a separate heading from simple cysts The pituitary is usually enlarged to about twice its normal size, and to the naked eye the anterior lobe appears to be replaced by a yellow mass Microscopically this consists of a large centre made up of solid eosinophil material, homogeneous or finely granular, in which there are numerous cholesterol crystals and small calcified spherules At the periphery there is a thick layer of fibrous tissue containing haemosiderin, either free or in phagocytes In some cases there is an epithelial lining of part of the cyst, either columnar or low squamous Around the mass are the flattened remains of the anterior lobe, with the capsule of the gland stretched over its surface The cyst seems to originate in the substance of the anterior lobe, the posterior lobe is normal or compressed The aetiology of the lesion is uncertain Healing gumma or tubercle, an encysted old haemorrhage, complete thrombosis of an aneurysm, necrosis of an adenoma, Hand-Schüller-Christian disease, and a special type of Rathke cyst have all been suggested The evidence on the matter is inconclusive, but the last of these explanations appears the most probable The duration of the lesion is also uncertain, but symptoms do not usually originate before middle age However, Erdheim (1916) recorded a cyst of this type in a 38-year-old infantile dwarf

References Moderate 31, M 21, 283, F 33, 131, F 57, 192 (1), M 40, 159, F 52, 36, M 67, 32, F 45 *Minor* Appendix (BL), M 68

Intrasellar tumours These are usually adenomas or angiomas The adenomas form a small group between the very common microscopic adenomas of the anterior lobe, which do not produce any significant pressure effects on the gland, and the large tumours which rise out of the sella and compress all neighbouring structures

References. Severe 261 (2), F 9 *Moderate* 165 (5), F 54, 179, F 33 *Minor* 129, F 28, 207 (3), F 41

Extrasellar cysts Most of the cysts are of the general group of Rathke pouch cysts and craniopharyngiomas There is a great variety of pathological appearances, including simple cysts lined by squamous or columnar-celled epithelium, papilliferous cysts, and various intermediate stages up to the solid craniopharyngiomas Some of the cysts appear to be due to degeneration of various types of tumours, these may finally appear as fibrous-walled cysts, with only a trace of tumour tissue in the wall to indicate their origin In the majority of cases the cysts originate in the suprasellar region As well as compressing the pituitary, they sometimes spread far up into the third ventricle and occasionally extend for large distances into the frontal or temporal lobes, with correspondingly great cerebral disturbances (Thibaut, 1947)

References Severe 40 (Gp 4, 3), F 35, 240, F 32, 166 (5), M 29, 166 (6), F 19, 120, M 37, 81, F 26; 210, F 54, 103 (8), F 25 *Moderate* 69 (1), M 35, 150, F 20, 230, M 27, 132 (3), M 27, 115, M 38, 275 (3), M 40, 83, F 20, 70 (2), M 62 *Minor and Slight* 153, M 36, 33 (2), M 44, 98, M 48, 16 (11), M 27, 243, M 22, 134, F 23, 113 (1), M 24

Extrasellar tumours The main pathological processes producing extrasellar tumours are as follows

1 Craniopharyngioma This includes the non-cystic developmental abnormalities related to Rathke's pouch There is a great range of pathological appearances, the tumours may show various types of epithelium, adamantinoma, bone, or other structures The mass usually originates in the suprasellar region, it may grow mainly in the sella or mainly in the lower part of the brain

2 Pituitary adenoma, or rarely carcinoma These tumours are usually solid, but sometimes become cystic, as mentioned above They usually originate in the sella, but later push up into the tissues above

3 Miscellaneous conditions, such as gliomas from the hypothalamus, meningiomas of the suprasellar region, angiomas of the pituitary stalk, tumours of the sphenoid bone, and other masses of this type

In many of the cases there is an astonishing lack of symptoms, despite gross compression of the pituitary and apparent destruction of most of the hypothalamus These are usually tumours of very slow growth and very long duration

References Severe 127, M 26, 226 (2), M 35, 261 (1), M 58, 109, M 58, 46, F 29, 122 (1), M 62, 139 (3), M 46, 130 (4), F 45, 105 (5), F 65, 163 (1), F 20, 163 (4), F 30, 9 (2), M —, 295, F 20, 103 (8), F 27, 104 (4), M 45 *Moderate* 8, F 17, 158 (2), M 32, 51 (33), M 67, 162 (2), 163 (9), M 42, 105 (6), M 50, 232 (2), M 55, 2, M 50, 237 (3), M 65, 163 (5), F 34, 9 (3), F 31, 93, M 62, 103 (10), M 10, 196, M 55, Appendix (AT), M 64 *Minor and Slight* 166 (4), M 43, 58 (2), M 10, 139 (1), M 76, 210 (1), F 54, 207 (Sect 3, 1), M 15, 16 (3), M 10, 293, M 27, 163 (8), M 40, 222, M 22, 275 (2), F 21, 113 (2), F 36, 212, M 70, 239, F 52

Part 2 Analysis of the Syndrome

From the above pathological analysis, a selection has been made of the cases of value for the study of chronic severe hypopituitarism For the reasons explained previously, the acute and subacute lesions, the extrasellar tumours and cysts, and the moderate, minor, and slight degrees of the other lesions cannot be accepted as giving a true picture of the complete and uncomplicated syndrome These exclusions cover a large number of the cases commonly quoted as typical examples of Simmonds's disease The 95 cases accepted here as reliable examples of chronic severe hypopituitarism consist therefore of the pathologically severe chronic fibroid lesions, the pathologically severe intrasellar cysts and tumours, and the surgical hypophysectomies For purposes of comparison, various findings from the 70 cases of clinical post-partum necrosis will also be analysed It is to be emphasized, however, that the conclusions about the syndrome are based primarily on the accepted cases with post-mortem verification, and that the clinical cases are used chiefly to fill out the information on biochemical changes In a few sections details will be given from the unaccepted groups for purposes of comparison with the true syndrome

Onset and duration of the disease Most cases of hypopituitarism result from a catastrophic destruction of the gland, such as ischaemic necrosis For the first few weeks there is little evidence suggesting an endocrine deficiency, apart from failure of lactation if the onset was at delivery Subsequently there is a gradual development of chronic ill health In a few cases the gland is destroyed rather quickly by some lesion, such as a gumma, which gives rise to local pressure symptoms, for example, diabetes insipidus or nerve palsies By the time these effects have disappeared, it is noticed that the patient is not in normal health In patients with tumours or cysts there may be a gradual development of symptoms suggestive of hypopituitarism These symptoms may have lasted from childhood or for many years before death, or they may be only terminal manifestations Most of the cases of fibrosis of uncertain aetiology are recognized only during their final illness On investigation it is found that they have had symptoms for several years, but it is rarely possible to establish the date of onset with any exactness Many reports give no information to indicate the duration of the disease, but in most of the cases of post-partum necrosis and in a few of the others it is possible to fix the exact date of the pituitary damage It appears from the following figures that most of the patients live for five to 15 years, but that occasionally they survive for as long as 40 years after the occurrence of the pituitary damage

Duration in years	1 to 4	5 to 9	10 to 14	15 to 19	20 to 24	25 to 29	30 to 40
Number of cases	12	18	18	10	8	8	6

General Pathological Changes

The pathological changes found in the rest of the body, excluding the pituitary, will be considered at this point, because they account for the physical signs that can be found during life, and because they provide a rational basis for

Intrasellar tumours These are usually adenomas or angiomas The adenomas form a small group between the very common microscopic adenomas of the anterior lobe, which do not produce any significant pressure effects on the gland, and the large tumours which rise out of the sella and compress all neighbouring structures

References *Severe* 261 (2), F 9 *Moderate* 165 (5), F 54, 179, F 33 *Minor* 129, F 28, 207 (3), F 41

Extrasellar cysts Most of the cysts are of the general group of Rathke pouch cysts and craniopharyngiomas There is a great variety of pathological appearances, including simple cysts lined by squamous or columnar-celled epithelium, papilliferous cysts, and various intermediate stages up to the solid craniopharyngiomas Some of the cysts appear to be due to degeneration of various types of tumours, these may finally appear as fibrous-walled cysts, with only a trace of tumour tissue in the wall to indicate their origin In the majority of cases the cysts originate in the suprasellar region As well as compressing the pituitary, they sometimes spread far up into the third ventricle and occasionally extend for large distances into the frontal or temporal lobes, with correspondingly great cerebral disturbances (Thibaut, 1947)

References *Severe* 40 (Gp 4, 3), F 35, 240, F 32, 160 (5), M 29, 166 (6), F 19, 120, M 37, 84, F 26, 210, F 54, 103 (8), F 25 *Moderate* 69 (1), M 35, 150, F 20, 230, M 27, 132 (3), M 27, 115, M 38, 275 (3), M 49, 83, F 20, 70 (2), M 62 *Minor and Slight* 153, M 36, 33 (2), M 44, 98, M 48, 10 (11), M 27, 243, M 22, 134, F 23, 113 (1), M 24

Extrasellar tumours The main pathological processes producing extrasellar tumours are as follows

1 Craniopharyngioma This includes the non-cystic developmental abnormalities related to Rathke's pouch There is a great range of pathological appearances, the tumours may show various types of epithelium, adamantinoma, bone, or other structures The mass usually originates in the suprasellar region, it may grow mainly in the sella or mainly in the lower part of the brain

2 Pituitary adenoma, or rarely carcinoma These tumours are usually solid, but sometimes become cystic, as mentioned above They usually originate in the sella, but later push up into the tissues above

3 Miscellaneous conditions, such as gliomas from the hypothalamus, meningiomas of the suprasellar region, angiomas of the pituitary stalk, tumours of the sphenoid bone, and other masses of this type

In many of the cases there is an astonishing lack of symptoms, despite gross compression of the pituitary and apparent destruction of most of the hypothalamus These are usually tumours of very slow growth and very long duration

References *Severe* 127, M 26, 226 (2), M 35, 261 (1), M 58, 109, M 58, 46, F 29, 122 (1), M 62, 139 (3), M 46, 139 (4), F 45, 105 (5), F 65, 163 (1), F 20, 163 (4), F 30, 9 (2), M —, 295, F 20, 103 (8), F 27, 104 (4), M 45 *Moderate* 8, F 17, 158 (2), M 32, 51 (33), M 67, 162 (2), 163 (9), M 42, 105 (6), M 50, 232 (2), M 55, 2, M 50, 237 (3), M 65, 163 (5), F 34, 9 (3), F 31, 93, M 62, 103 (10), M 10, 196, M 55, Appendix (AT), M 64 *Minor and Slight* 166 (4), M 43, 58 (2), M 10, 139 (1), M 76, 210 (1), F 54, 207 (Sect 3, 1), M 15, 16 (3), M 10, 293, M 27, 163 (8), M 40, 222, M 22, 275 (2), F 21, 113 (2), F 36, 212, M 70, 239, F 52

indicate how long a time is required before the atrophy is clearly recognizable The details of the atrophy of each individual gland in severe hypopituitarism are as follows

Adrenal The glands are small and thin The cortex is reduced to about 0 2 to 0 4 mm in thickness instead of the normal 1 to 2 mm. The remaining cortical parenchyma is very atrophic, but is not fibrotic It contains a normal amount of lipoid, and probably represents mainly zona fasciculata The zona glomerulosa is obscured by a great fibrous thickening of the capsule The zona reticulata has usually disappeared completely, it is replaced by a broad layer of fibrous tissue which forms a sharp boundary between the cortex and medulla There are no pigmented parenchyma cells on the outer side of this layer, and no islets of cortical cells beneath it in the medulla The medulla remains almost unaffected, and thus appears very prominent in sections The combined weight of the two glands in 26 cases averaged 4 7 gm with a range of 2 2 to 7 8 gm , the corresponding range for the normal adult is 10 to 15 gm The persistence of the medulla and thickening of the fibrous capsule maintain the weight of the whole gland higher than might be expected from the great atrophy of the cortex However, if the combined weight of the glands is over 7 gm , the existence of cortical atrophy can be accepted only if the histological evidence is definite

Thyroid The gland is small, in 28 cases it had a mean weight of 7 gm with a range of 2 to 11 gm , as compared with the normal weight of 20 to 30 gm. Histologically it shows a variety of appearances

(*a*) Most commonly (26 cases) there is a well-marked atrophy of the acini, which are very small and lined by a flat and apparently inactive epithelium These acini are usually full of colloid, though this may be only weakly oxyphil Lymphoid infiltration may accompany the atrophy (eight of the 26 cases)

(*b*) Frequently (19 cases) a more severe lesion is present, there is extensive fibrosis throughout the gland, so that the atrophic thyroid acini are broken up into small groups Lymphoid infiltration is a very common accompaniment (14 of the 19 cases)

(*c*) At other times (15 cases) the fibrosis becomes so severe that the thyroid is represented only by a small mass of dense scar tissue, which can scarcely be recognized histologically as thyroid These changes are as severe as in true myxoedema More significant information about the loss of parenchyma is obtained from histology than from the weight of the gland Some of the thyroids weighing 8 to 11 gm consisted almost entirely of fibrous and lymphoid tissue, so that the parenchyma formed only a small proportion of the total weight

Gonads and genital tract Female The essential lesion is an atrophy of the ovaries, and a superinvolution of the uterus, vagina, and vulva The changes are similar in type to those occurring after the menopause (though greater in severity), and for this reason even an extreme degree of genital atrophy after the

the various symptoms The most important of these changes is the atrophy of the adrenal cortex, thyroid, gonads, and, secondarily, of the genital tract The condition of these organs is classified here in five groups

Certainly all atrophied Clear pathological reports of atrophy of adrenal cortex, thyroid, gonads, and genital tract in accordance with the description given below

Probably all atrophied Atrophy of three of these organs, insufficient evidence to assess the condition of the remaining one (usually the genital tract), but no reason to doubt its atrophy

Insufficient information Cases with no details, or with reports of only one or two of the organs

Probably not all atrophied Cases with descriptions suggesting that one or more of the organs were not atrophied

Certainly not all atrophied Cases with clear pathological details indicating that at least one, and often all, of these organs were normal

TABLE I

Relation of Secondary Endocrine Atrophy to Severity of Pituitary Damage

	Chronic pituitary lesions			
	Accepted cases	*Unaccepted cases*		
Adrenal, thyroid, gonads, and genital tract	*severe*	*severe*	*moderate*	*minor and slight*
Certainly all atrophied	54	3	6	3
Probably all atrophied	22	4	10	1
Insufficient information	13	14	21	29
Probably not all atrophied	0	0	6	8
Certainly not all atrophied	6	2	9	26

Table I shows that, in the accepted cases with severe pituitary damage, there is nearly always atrophy of the significant endocrine glands (76 positive, 6 negative) Some of the few negatives date from the period before 1927 when secondary endocrine atrophy was not known and was therefore probably not sought (Simmonds himself recorded these glands as normal in cases where it seems almost impossible that they were not greatly atrophied, and this led to much pathological confusion in the early literature) The other negatives may possibly be due to the assessment as severe of pituitary damage which in fact was only moderate Endocrine atrophy was less commonly present in the moderate grade of pituitary damage (16 positive, 15 negative) The occurrence of the positives suggested that the degree of pituitary damage might perhaps have been under-estimated in these 16 cases, but a reconsideration of the pathological reports on the pituitaries does not support this explanation In the 'minor and slight' group, endocrine atrophy was uncommon (4 positive, 34 negative) The positives may have been atrophy due only to prolonged emaciation, the histological reports are not very convincing It appears justifiable to conclude that secondary endocrine atrophy is an invariable result of prolonged severe pituitary damage There is as yet insufficient information to

basophil masses in the muscle-fibres similar to those seen in myxoedema In the majority of cases there was a moderate degree of atheroma of the aorta

Pancreas In 19 cases the pancreas had a mean weight of 46 gm (range 20 to 100 gm) The normal weight of the pancreas is about 90 gm The islets were usually reported as increased in number and frequently in size, the cells being rather small but apparently more numerous than normal In view of the atrophy of the pancreatic parenchyma, it is possible that the recorded increase in number of islets is more apparent than real, detailed studies of the actual number and volume of the islets do not appear to have been carried out

Thymus The thymus was always noted as being extremely small or unrecognizable This is not a significant abnormality in view of the age of the majority of the patients, but it is of interest that there is no hyperplasia of the type sometimes seen in Addison's or Graves's disease

Parathyroids The parathyroids have been reported in 17 cases In the more detailed descriptions there is usually a remark about the paucity or absence of oxyphil cells

Spleen In 21 cases the mean weight was 110 gm (range 30 to 230 gm) The normal weight is 100 to 200 gm The only abnormality recorded was an excess of haemosiderin

Lymphoid tissue The germinal follicles were usually said to be small or absent in the few cases in which records are available

Gastric mucosa Some atrophy of the gastric mucosa was noted in three cases, but this finding *post mortem* is unreliable without special techniques of examination

Bone-marrow In the few cases in which this has been examined it has been recorded as hypoplastic, but detailed studies have not so far been made

Skeletal system Except in cases of tumours or cysts, there is no alteration in the sella, either on radiological or pathological examination In adult cases there are no recognizable abnormalities in the air sinuses of the skull, and the long bones appear radiologically to be of normal density

Teeth Loss of teeth has been recorded in many of the cases, but its significance is doubtful Caries, pyorrhoea, and loss of teeth are such common conditions that some degree must be regarded as almost normal in hospital patients of this age-group

Skin Histological examination of axillary skin has been made in only three cases These showed a virtual disappearance of sweat glands, sebaceous glands, and hair follicles

Mammary glands The contour of the female breast does not alter On section there is the normal amount of fatty and fibrous tissue, but the parenchyma is always very atrophic

Hypothalamus In several cases the brain was reported as normal, but there is no record of specific examination of the hypothalamus Among 10 severe cases in which the hypothalamus was examined in detail, there were no lesions in three, a reduced number of cells in the supra-optic nuclei in one, some perivascular cuffing in the supra-optic region in two, gliosis in the tuberal region in

age of 45 years is not absolutely diagnostic On the other hand, the absence of complete genital atrophy after this age is conclusive evidence against a significant pituitary lesion In women below the age of 45 years there are only 12 cases in which detailed descriptions of the ovaries are available The combined weight of the ovaries was 3 8 to 5 4 gm, as compared with the normal 10 to 15 gm. A few primordial follicles were sometimes found, but there were never any developing Graafian follicles or corpora lutea In three cases small follicular cysts or small cysts lined by a single layer of cubical epithelium were present Some remaining corpora albicantia are usually seen, even in very long-standing cases The uterus is small, with an overall length of 5 cm and a width of 2·5 cm, its walls are about 5 to 6 mm in thickness The myometrium sometimes consists of closely packed muscle nuclei with little cytoplasm, sometimes it is almost completely fibrotic The endometrium is represented by a flat layer of cubical epithelium with very occasional small cysts beneath it, this explains why diagnostic curettage gives no tissue for examination In a few cases the endometrium is replaced by vascular granulation tissue heavily infiltrated with plasma cells. The cervix forms only a small dimple in the vaginal vault, the vagina and external genitalia show advanced atrophy of senile type There is absence of glycogen in the vaginal epithelium, and of acid and Döderlein bacilli in the scanty vaginal secretion

Male The testes are usually described as very atrophied, but have rarely been weighed, combined weights of 6 gm and 8 gm have been noted, the normal being 20 to 25 gm The seminiferous tubules have enormous hyaline thickening of the basement membrane, which may almost obliterate the lumen Sometimes they have no epithelial lining, sometimes they have a single layer of epithelium with no trace of spermatogenesis The interstitial tissue is increased and consists of oedematous hyaline connective tissue, and the interstitial secretory cells have disappeared completely The epididymis, vesiculae, and prostate are usually noted to be atrophic, but no details of the histological changes have been recorded

Other organs There is a striking atrophy of most of the viscera This appears to be a true trophic atrophy, as nearly all the patients are of normal body-weight

Liver In 32 cases the mean weight was 890 gm (range 570 to 1,400 gm) The normal weight of the liver is 1,400 to 1,800 gm A moderate amount of haemosiderin was commonly present in the liver cells In five cases there was a single large gall-stone, mainly pigment, and in two others there were several small pigment stones

Kidneys In 29 cases the mean weight of the two kidneys together was 170 gm (range 100 to 260 gm) The normal weight of the two kidneys is about 300 gm No characteristic abnormalities were noted in these organs, though pyelonephritic scars were not uncommon

Heart In 26 cases the mean weight was 207 gm (range 150 to 290 gm) The normal weight of the heart is 260 to 340 gm There were sometimes large

used to indicate severe emaciation, the typical example being that of a patient in the terminal stages of carcinoma It is sometimes used in the rather looser sense of 'prolonged debilitating disease' in patients without any loss of weight Thus, for example, a patient with severe hypopituitarism was described in two successive sentences as *mit deutlicher Kachexie* and as *mit gutem Ernahrungszustand* The third meaning is that of an endocrine deficiency There is no implication of emaciation in the description of post-operative myxoedema as cachexia thyreopriva The term pituitary cachexia has obviously

TABLE II

Nutrition at Death

	Number of cases at each nutritional state					
	Fat	*Good*	*Normal*	*Fair*	*Thin*	*Emaciated*
Accepted severe pituitary lesions						
Healed post partum necrosis	0	7	25	11	9	5
Other chronic fibroid lesions	3	3	5	7	1	6
Surgical hypophysectomy	0	0	1	0	0	1
Intrasellar cysts and tumours	0	2	0	0	2	0
Unaccepted pituitary lesions						
Chronic fibroid lesions, and intrasellar cysts and tumours						
(*a*) Moderate	4	5	7	2	4	6
(*b*) Minor and slight	1	2	3	3	2	31
Extrasellar cysts and tumours						
(*a*) Severe	7	3	4	2	1	4
(*b*) Moderate	5	4	2	3	3	3
(*c*) Minor and slight	6	3	1	1	3	5

been used in the title of some publications only as a standard synonym for hypopituitarism, and the data in the report indicate that the patient was of normal nutrition However, for the present review, the word cachexia in a paper has been interpreted as emaciation except where the context indicates clearly that this was not the meaning intended

The nutritional state at death in the various groups is analysed in Table II When the pituitary lesions were severe, only about one-quarter of the patients were thin or emaciated at death This may be compared with the nutrition in minor and slight lesions, where over three-quarters of the patients were thin or emaciated at death In the group of extrasellar cysts and tumours many of the patients were overweight, and a lesser but significant number were considerably under normal weight These disturbances appear to have been due to the cerebral pressure rather than to the pituitary destruction. For comparison, a summary may be given of the nutritional state of the patients in 500 routine autopsies None of these patients had pituitary disease Fifteen per cent were recorded as fat or of good nutrition, 43 per cent were of normal or fair nutrition, and the remaining 42 per cent were either thin or emaciated. The nutritional state in this control sample of patients dying without pituitary disease was thus worse than in the patients who had died from severe pituitary lesions

two, and minor cellular changes in two cases It is difficult to say how far these changes are only terminal, similar changes have been recorded in some of the patients with only slight pituitary damage

State of Bodily Nutrition

In this section the analysis will be extended to include all types of pituitary lesion and degrees of damage, because the nutritional state is the subject on which the present findings conflict with nearly all the standard descriptions of the syndrome It is worthy of note that Simmonds himself did not stress the idea that emaciation is a result of hypopituitarism His original patient, who was of medium height, weighed 103 lb nine years after the onset of the disease and, although he mentioned incidentally in part of one sentence that she had much weight-loss at death two years later, the feature which most impressed him then was the prematurely senile appearance of the patient (Simmonds, 1914*a*, Leschke, 1919, Case 7) His next patient died from carcinoma of the stomach (Simmonds, 1914*b*, Case 13), and the next had pulmonary tuberculosis (Fraenkel, 1916, Simmonds, 1918, Case 2), their nutritional state was clearly not of endocrine significance About this time he had two patients with pituitary tumours who had lost much weight (Simmonds, 1916) and he introduced the term pituitary cachexia However, by 1918 he was clearly more impressed again by the progeria of his sixth patient (Simmonds, 1918, Case 4) and made no note of her nutrition His seventh patient (Simmonds, 1918, Case 3, Bostroem, 1918) was of medium height and weighed 99 lb

The state of nutrition of the patients is classified here in six categories fat, good, normal, fair, thin, emaciated These terms are used with their ordinary clinical significance, corresponding roughly to steps of one-eighth of the normal weight The classification has been given for two standard times, firstly at death, secondly at six months before death

Nutrition at death The nutrition has been assessed initially at the time of death because this is the time for which the most objective and most numerous data are available, in some cases the patient was admitted to hospital in a moribund condition and the previous clinical history was not ascertained The assessment is made from two main sources (*a*) the description of the body given by the pathologist, and the recorded thickness of the subcutaneous fat at autopsy, and (*b*) the clinical description of the patient, the recorded height and weight in relation to the sex, and the photographs of the patient This clinical evidence has to be considered with special regard to the stage of the disease at which these data were obtained, and to the clinical course during the ensuing period (for example, terminal loss of weight) The information about nutrition is sometimes scanty and occasionally discordant, in these cases judgement has had to be made by balancing the evidence The assessment is not of a high degree of scientific exactitude, but it is believed that there are no errors sufficiently important to interfere with the accuracy of the general picture

One difficulty that requires remark is the significance of the word cachexia, which has three quite different meanings in the literature It is commonly

hypopituitarism is characterized by emaciation During the course of the syndrome due to severe pituitary lesions, whether due to post-partum necrosis or other causes, about three-quarters of the patients are of normal nutrition or only slightly above or below this

By contrast, about three-quarters of the patients with minor or slight pituitary lesions were thin or emaciated This cannot be taken as evidence that minor pituitary lesions specifically cause loss of weight The probable explanation seems to be that patients of this type were diagnosed clinically as Simmonds's

TABLE III

Nutrition Six Months before Death

	Number of cases at each nutritional state					
	Fat	*Good*	*Normal*	*Fair*	*Thin*	*Emaciated*
Accepted severe pituitary lesions						
Healed post-partum necrosis	1	10	28	7	8	3
Other chronic fibroid lesions	3	4	9	5	1	3
Surgical hypophysectomy	0	0	1	0	1	0
Intrasellar cysts and tumours	0	2	0	1	1	0
Acceptable severe clinical cases						
Healed post partum necrosis	5	9	24	10	4	3
Unaccepted pituitary lesions						
Chronic fibroid lesions, and intrasellar cysts and tumours						
(a) Moderate . .	5	7	10	4	3	4
(b) Minor and slight .	3	2	5	1	4	27
Extrasellar cysts and tumours						
(a) Severe	8	3	5	3	0	2
(b) Moderate	7	2	4	2	2	3
(c) Minor and slight .	7	1	4	0	3	4

disease because they were of bad nutrition and therefore in agreement with the standard description of the syndrome, and for this reason their pituitaries were subjected to detailed pathological study

There are relatively few cases of severe hypopituitarism in which both the height and weight of the patient are recorded. Fig 1 shows the individual data in the severe cases which were examined *post mortem* and Fig 2 the data in the acceptable clinical series For comparison, these two Figures also show the heights and weights of 65 living female patients in the medical wards of a local hospital, these patients were unselected apart from the exclusion of all cases of carcinoma, tuberculosis, and diabetes mellitus It will be seen from Fig 1 that the patients with severe hypopituitarism tended to be perhaps slightly less heavy at death than the living control patients The seven cases marked in the Figure with black circles instead of squares were examples of terminal emaciation due to the following causes—carcinoma (70 lb and 95 lb), pulmonary tuberculosis (86 lb and 125 lb), and severe vomiting in the last few months of life (66 lb , 91 lb , and 96 lb) Fig 2 shows that the clinical cases of severe hypopituitarism tended to be very slightly heavier than the corresponding controls

Nutrition at six months before death From the clinical aspect it is clearly of far greater importance to know about the nutrition throughout the entire course of the disease, which may last 20 years or more, than to have details of the appearance of the body at death For this reason, consideration must be given to the nutrition of the patients six months before death, that is, before the terminal stage of the disease was reached During the course of the disease the patients sometimes show moderate fluctuations of weight, comparable to those which occur in normal persons If they lose a large amount of weight early in the disease (as from puerperal sepsis), a considerable time, sometimes two or three years, may be required before this is regained However, the weight at about six months before death probably gives a fairly true indication of the average nutritional state throughout the illness Some of the published papers give definite data about the nutrition during the course of the disease as well as at death Others record the nutrition at death, and either state that the patient had had a terminal severe loss of weight or give details of some pathological lesion, such as carcinoma or tuberculosis, which can be accepted as having caused weight-loss In the latter type of case the state of nutrition six months before death has been assessed arbitrarily here as one or two grades higher than that at death, due notice being taken of any clinical evidence available Finally, there are a number of cases where only the nutritional state at death is recorded and no information is given about the course before death, the nutrition of these patients at six months before death is taken for purposes of analysis as the same as that at the time of death The terminal diseases which lasted long enough before death to cause significant loss of weight may be summarized as follows The figures refer to all types of chronic pituitary lesions and to all grades of severity

(*a*) Carcinoma occurred in nine of the patients, various sites were involved

(*b*) Active extensive tuberculosis of lungs, or less commonly of the abdominal viscera, was the cause of death in 17 patients No specific note is made in this paper of patients with inactive or healed tuberculous lesions

(*c*) Severe anorexia, sometimes associated with vomiting, dyspeptic symptoms, or diarrhoea, was usually a rapidly fatal complication in patients with severe hypopituitarism On the other hand, 14 patients, most of whom had lesser degrees of pituitary damage, survived for many weeks or months with this complication, and thus were very thin at death

(*d*) Overdosage with thyroid, in the treatment of the apparent myxoedema of some patients, led to considerable loss of weight Four of these patients died in a very poor state of nutrition

(*e*) In 13 cases miscellaneous emaciating diseases were present as terminal conditions, chronic sepsis, uraemia, &c , and also a very acute type of diabetes insipidus which sometimes occurs in patients with gross hypothalamic lesions

Table III shows the nutritional state in the various groups of patients at six months before death, assessed in the manner explained above The condition of the severe clinical cases of healed post-partum necrosis is also noted in the Table This analysis gives no support to the common opinion that severe

Other Clinical Aspects

From this point onwards the analysis will be concerned only with the results of severe pituitary damage

Sex function Complete and permanent loss of sex function is an invariable consequence, whatever the aetiology of the pituitary lesion, there is no need to tabulate the figures In women menstruation always ceases When the pituitary lesion develops slowly, there may be a period of infrequent and scanty menstruation before complete amenorrhoea develops In cases of sudden onset of the pituitary lesion, such as post-partum necrosis, an immediate development of amenorrhoea and associated sterility is the rule Where the matter was investigated, there was a striking absence of the general symptoms which accompany the natural menopause Information about the sex function in men is available for only seven patients, all of whom were impotent These physical changes are accompanied by corresponding psychological alterations The libido was noted in only 14 women, it was lost in 13, but is said to have been normal in the other case It was lost in all seven men Female patients lose their normal bashfulness, and appear to be quite unconcerned about being photographed or demonstrated in the nude Adequate hormone therapy leads to a return of the normal outlook in this regard In the cases which immediately follow delivery there is a complete absence of breast activity in the puerperium, the mammary glands become soft and involuted within a few days after the delivery and there is no secretion of colostrum or milk Failure of lactation may arise from other causes at that time, and cannot be taken by itself as diagnostic evidence of pituitary destruction

Hair Body hair In both sexes loss of the pubic and axillary hair together appears to be of considerable diagnostic importance Loss of axillary hair alone is not significant Many reports, particularly the older ones, give no information about the pubic hair In routine clinical examination, care is usually taken not to expose the region of the genitalia If such an inspection is made, the lack of pubic hair may fail to provoke any mental response in a doctor who is accustomed to see shaved patients on the operating table As an example, most of the patients studied by us had been in and out of hospital several times without any note being made of their loss of body hair Frequently the condition has been noted for the first time only at autopsy The body hair does not disappear immediately the pituitary has been destroyed. The usual course is that the axillary hair is lost in a few months, but the pubic hair may persist for a year or two, and scanty short hairs may remain on the labia majora almost indefinitely The loss is so gradual that the patient cannot give any exact date for the change However, in patients who had had the pubes shaved at the time the pituitary was destroyed, there is commonly a clear history that the hair did not grow again A variant on this theme is that, if a patient suffers a large necrosis of the pituitary at delivery and subsequently develops puerperal sepsis, then this infection may produce a rapid and generalized loss of hair,

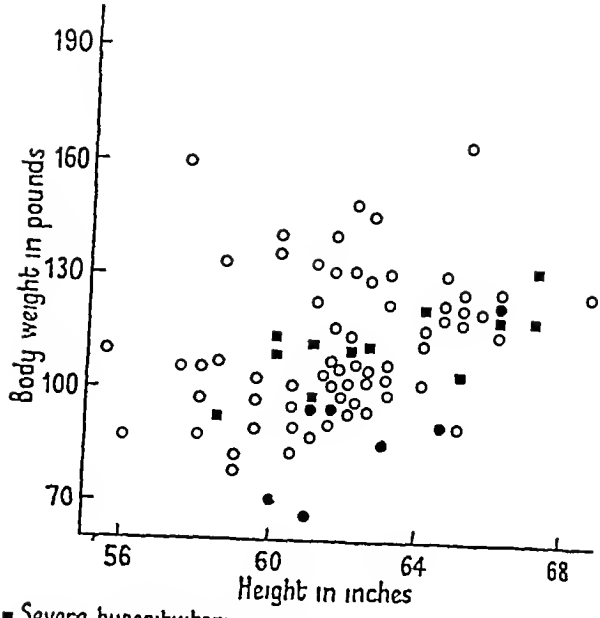

■ Severe hypopituitarism
● Severe hypopituitarism with terminal emaciating disease
○ Female controls

FIG 1 Nutrition in fatal cases of hypopituitarism

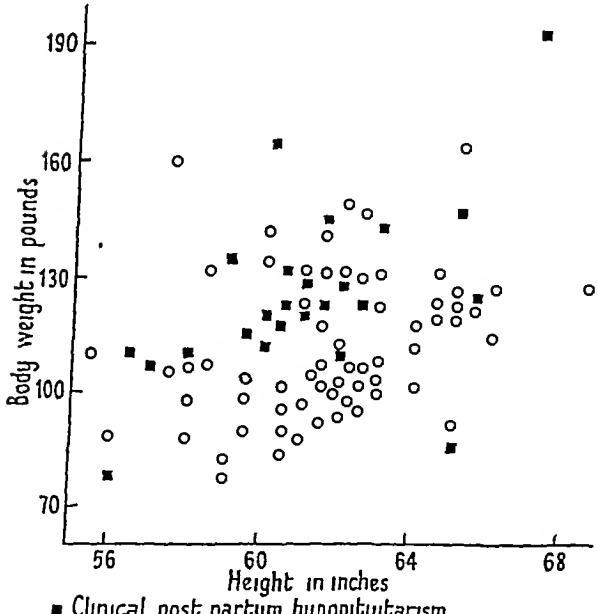

■ Clinical post partum hypopituitarism
○ Female controls

FIG 2 Nutrition in living cases of hypopituitarism

Striking pallor of the face was noted in 34 of the patients, the colour was often described as waxy-white or alabaster There were 16 patients recorded as sallow or as having a lemon-yellow tinge, these were usually patients showing clinical appearances suggestive of myxoedema None of the patients was described as pigmented Similar appearances were described in the clinical group, 27 white, six sallow, and none pigmented There are two separate considerations regarding the pallor of the skin, namely, loss of skin pigment and loss of the capillary flush

(*a*) The loss of skin pigment appears to be due to a true interference with melanin production, and not to the indoor existence which most of these patients adopt There are very few details in the literature about the breast areolae, but in the patients studied by us the areolae were always depigmented, even in multiparous dark-haired women Exposure of these patients to real or artificial sunlight produced no pigmentation in the irradiated areas (This can be used as a diagnostic test, but it is necessary to take great care in attempting to pigment these patients because of the severe sunburn which may occur) The *erythema ab igne*, which is almost always present on the legs of the female patients, does not develop brown pigment No investigations have been made on the 'dopa' reaction of the epithelium Whatever be the physiological explanation, it is a matter of interest that depigmentation of the skin occurs in hypopituitarism, in which the suprarenal cortex is greatly atrophied and the medulla is relatively normal This may have a possible bearing on the problem of the pigmentation in Addison's disease

(*b*) The other feature of the pallor is the lack of the normal capillary flush in the exposed skin, particularly over the cheeks and ears This flush is completely absent in most cases, although the mucosae are normally coloured If the patient is excited there may be a transient reddening over the eyebrow region This condition of the skin capillaries is in marked contrast to the appearances seen in Cushing's syndrome

Facies Most of the patients, particularly the women, have a characteristic and almost pathognomonic facial appearance, which is as easy to recognize at a glance as the facies of exophthalmic goitre or myxoedema, though the change is rather more subtle than in those diseases The facial contours tend to appear weak, suggesting what might be described as a partial regression of those features which are normal in adults and become coarsened in acromegaly There is a lack of animation in the face giving an expression suggestive of myopathy or of a person asleep Slight puffiness of the face, particularly below the eyes, is commonly present The picture is completed by the thinning of the eyebrows and the striking pallor of the skin These appearances are in some ways suggestive of hypothyroidism In the literature, 33 patients are described as of hypothyroid appearance and only three as being not hypothyroid Some of the patients had quite definite appearances of myxoedema, there are 12 such cases recorded A detailed comparison of the degree of the myxoedematous facial appearances with the severity of the pathological lesion of the thyroid

affecting the head as well as the body Subsequently the head hair returns, but the body hair is permanently lost An analysis of the accepted cases shows that the pubic and axillary hair was completely lost in 65, scanty in 10, normal in two, and not recorded in 18 In the acceptable clinical cases it was completely lost in 53, scanty in five, normal in one, and not recorded in 11 From these figures it is clear that the pubic and axillary hair is almost invariably lost The retention of pubic hair may be taken as an indication that the pituitary lesion is either not a severe one, or that it is not of more than about two years' duration On the other hand, the loss of pubic and axillary hair cannot be taken alone as conclusive evidence of severe pituitary damage Such loss occurs in a small proportion of patients with only minor or slight pituitary lesions, and also in patients with other diseases not affecting the pituitary

Facial hair in men It is difficult to arrive at definite conclusions about the condition of the beard, as the details are rarely recorded Excluding cases of infantilism, there were 28 men with severe pituitary lesions who had lost their pubic and axillary hair The beard was absent in four of these, scanty in six, and not noted in the remaining 18

Eyebrows All the patients examined by us have had considerable thinning of the eyebrows The loss was particularly marked over the outer part, as in myxoedema, and any hair remaining in this position tended to be depigmented Among the accepted cases, 30 had thinning of the eyebrows, occasionally almost complete absence, four had normal eyebrows, and the condition of the remaining 61 is not recorded The details of the acceptable clinical cases are similar, 20 with considerable thinning, none with normal eyebrows, and 50 without records

Head hair When details are given, about half the patients are recorded as having had some thinning of head hair, and the other half as having had normal or thick head hair In view of the age of most of the patients, this cannot be considered to be significantly abnormal, and the condition of the head hair appears to be of no value in diagnosis The colour of the hair also appears to be unimportant, despite the attention given to this matter in the literature Among the patients who came to autopsy, four had grey or white hair, while 11 had hair of normal colour Among the acceptable clinical cases, one had grey hair and 14 had hair of normal colour

Skin The skin is nearly always recorded as dry, and is usually described as smooth and soft on the face and body, but sometimes very slightly scaly on the limbs In most patients there was no significant atrophy of the skin, but wrinkling of the face was noted in seven cases The dryness of the skin is due to an absence of sweating, among 32 cases with details on this point, 31 had no recognizable sweating, but the remaining one is said to have perspired normally There has been in all the cases examined by us a lack of the normal greasiness of the axillae, and also an absence of the emotional sweating in that site which occurs in the normal patient after puberty There are no records of axillary furunculosis in any of the patients

matism of joints, particularly of the knees, was noted in 13 patients Deafness occurred in four patients The speech was recorded in 44 cases as slow, quiet, monotonous, and rather hesitating In 10 of these, chiefly in the terminal phases, it was noted as thick or slurred The voice is usually soft and gentle A great degree of mental torpor was recorded in 59 patients, usual descriptions are that the patient has no initiative, loses interest in her home and friends, and settles into a state of placid inertia It is characteristic of these patients that when they are brought into hospital they are completely contented with life in bed, where they are kept warm, have their food brought to them, and are not required to do any work They show no desire to return to their homes, and will stay in hospital for months On the other hand, when they have been discharged, it is difficult to get them to make sufficient effort to return to hospital Definite mental changes were noted in 22 patients, excluding the cases where the patient was approaching coma The disturbances were commonly depression or melancholia, with delusions in a number of cases, mania was rare It is possible that these mental disturbances were due to a combination of hypothyroidism and hypoglycaemia It is open to question whether the relatively high recorded incidence of mental derangement is a true one, or whether it is merely a reflection of the fact that, in autopsies on patients who die in lunatic asylums, the cranial contents are usually examined with care Physical weakness, and a disinclination for any form of physical activity, was a very common observation, being noted in 96 of the accepted post-mortem cases and the acceptable clinical cases In 10 the condition was so extreme that the patients remained in bed for the last few months or years of life Possibly in relation to the diminution of muscular tone, these patients commonly have a round-shouldered posture In addition, most of the female patients studied by us had a filling-out of the flank between the costal margin and the iliac crests, so that the waist contour tended towards the masculine type

Laboratory Investigations

Various haematological and biochemical findings in the accepted post-mortem cases and the acceptable clinical cases are listed in Table IV

Haematology There is nearly always a normochromic anaemia of moderate degree It is usually remarked that the degree of anaemia is much less severe than had been expected from the striking pallor of the patient There are no records of conditions often associated with anaemia, such as perlèche, glossitis, dysphagia, or koilonychia In most cases the red cells do not show any significant abnormality of size or staining reactions, and there is no increase of reticulocytes Some of the long-standing cases develop a macrocytic anaemia which is refractory to liver treatment, and one patient (Bloom and Bryson, 1948) had aplastic anaemia The subject has been reviewed recently by Daughaday, Williams, and Daland (1948) The leucocytes are normal in most cases, though a mild eosinophilia is sometimes recorded It is of interest to note the lack of any reduction of the lymphocytes despite the adrenal cortical dysfunction

fails to show any correlation, a clinical picture suggesting true myxoedema may as well be associated with simple atrophy of the thyroid as with very gross sclerotic replacement of the gland

Since Simmonds's original description, considerable attention has been directed to progeria as a typical feature of hypopituitarism Nevertheless, an appearance of premature senility has been noted in only 10 per cent of the cases, this cannot be considered a sufficiently high incidence to constitute a characteristic sign of the disease Any chronic invalid may look five or 10 years older than the stated age, and patients with hypopituitarism are no exception to the rule The estimation of such slight changes is very much a matter of individual impressions Nearly all the patients studied by us looked to be about their stated age A point of some interest is that, though Gilford's (1904) syndrome of progeria in children is commonly accepted as due to hypopituitarism, there are no cases of this type in the present analysis Only two autopsies appear to have been performed in this disease, the pituitaries were not significantly abnormal to the naked eye, and histological examinations were not made (Gilford, 1904, Talbot, Butler, Pratt, MacLachlan, and Tannheimer, 1945)

Cardiovascular system It is sometimes maintained that a slow pulse is characteristic of hypopituitarism Many of the histories of cases which terminated fatally either give no details about the pulse, or record the rate during the terminal coma (when it is sometimes very slow) or during pyrexia (when it is usually fast) Excluding the records taken during these occasional episodes in the disease, the pulse-rate in 14 cases which came to autopsy ranged from 56 to 85, with a mean of 73 In 10 clinical cases of post-partum hypopituitarism the rate ranged from 57 to 84, with a mean of 71 Radiologically the heart is usually small, in contrast to the enlargement which is sometimes seen in myxoedema Electro-cardiographic findings were noted in 20 cases In 13 cases low voltage electrocardiograms were recorded, in four there were negative T waves in leads 2 and 3, irregularity of rhythm was recorded in three cases The changes are very similar to those of myxoedema, and treatment with thyroid may produce a return to normal The patients tend to have a labile blood-pressure The mean systolic pressure was 108 mm of mercury, 34 patients had a blood-pressure between 70 and 95, 45 between 100 and 135, and 11 between 140 and 240 The majority of the low blood-pressures recorded were from patients in the last two or three months of life, and most of the higher blood-pressures were in patients several months or years before death The blood-pressure always falls during an insulin tolerance test, the trough of the blood-pressure curve occurs at 45 to 60 minutes, when systolic readings of 80 or 90 may be observed

General symptoms Many of the complaints made by the patients are suggestive of hypothyroidism Sensitivity to cold was recorded in 51 cases, this is presumably a symptom of the lowered basal metabolism As a result, the patients sit beside the fire as much as possible, so that *erythema ab igne* is a common finding in women The absence of sweating has been discussed earlier Rheu-

blood-sugar with a tendency towards low values The following biochemical data are not summarized in Table IV

Basal metabolic rate The basal metabolic rate is always low, usually in the range of −25 to −40 per cent In 68 cases the mean level was −31 per cent with a range of −5 to −55 per cent This appears to be related to the thyroid insufficiency Treatment with thyroid extract produces a rise to about the normal level, in 13 patients under thyroid treatment, the basal metabolic rate averaged −3 per cent, with a range of −14 to +6 per cent

Gastric function A fractional test meal was carried out on 21 patients Three had achylia and ten had achlorhydria, which was noted to be histamine-fast in four On the other hand, five patients had a small amount of free hydrochloric acid, and three showed normal curves There is no constant relationship between the severity of the anaemia and the failure of gastric secretion of hydrochloric acid

Renal function tests The urea clearance test gives low figures, in five cases the range was from 29 to 59 per cent, with a mean of 50 per cent of normal In the urea concentration test, the maximum concentration recorded is from 1 7 to 2 4 per cent The Kepler test, which is indicative of the adrenal cortex and kidney relationship, usually gives results corresponding to those seen in Addison's disease In four cases only the first part of the test was carried out and showed an absence of water diuresis (During the course of the disease, many patients remark on the fact that they can drink very large quantities of fluid without this causing a desire to micturate) The second part of the Kepler test gave in three patients a factor of 3 6 to 4 2, but in two patients a factor of 20 to 30

Glucose tolerance test This test is not of any value in diagnosis The curve tends to be prolonged and rather flat, possibly as a result of slow absorption, and comparable to the similar curve in myxoedema The average figures for 25 patients are as follows

Minutes	0	30	60	90	120	180
Blood sugar (mg per 100 c c)	72	112	121	114	96	79

Insulin tolerance test Though insulin tolerance tests have been used in other conditions for over 20 years (Greenblatt and Kupperman, 1947), their application in the study of pituitary dysfunction is only recent A subcutaneous insulin tolerance test was used in such a patient by Rau (1935) The intravenous insulin tolerance test was introduced in the investigation of hypopituitarism by Fraser and Smith (1941), and this test has proved of great value in the hands of many workers Slessor (1946) has recently questioned its significance, but he gives no evidence to prove that any of his patients had pituitary lesions The dose originally suggested (0 1 units of insulin per kg) is liable to produce dangerous reactions in patients who have severe pituitary damage A dosage of 0 03 units per kg yields as much information as the higher dose, and in our hands has never produced hypoglycaemic coma The average figures of 15 insulin tolerance tests are given below These are chiefly from the group of acceptable clinical cases Some of the tests were done with the larger and others with the smaller

Blood chemistry There is a fall in the serum-sodium and plasma-chlorine, probably a reflection of adrenal cortical insufficiency, combined in some cases with the effect of vomiting The records of serum-potassium suggest a rather wide range, but the possibility of technical errors, such as diffusion from corpuscles, leaves the figures open to doubt There is perhaps a tendency for serum-calcium to be low normal and plasma-phosphorus to be high normal, but the changes are not important The blood-urea level is not raised The total plasma-protein is within the normal range McCullagh, Lewis, and Owen (1943) carried out

TABLE IV

Haematology and Biochemistry

	Number of cases	*Mean level*	*Range*	*Normal range*
Red cells (millions per c mm)	80	3 8	1 8 to 5 5	4 5 to 5 5
Haemoglobin (per cent)	76	70	38 to 100	90 to 110
White cells (thousands per c mm)	67	6 6	1 6 to 17 0	4 to 10
Neutrophils (per cent of white cells)	33	56 0	12 to 91	50 to 70
Eosinophils (per cent of white cells)	33	3 5	0 to 13	1 to 3
Basophils (per cent of white cells)	33	0 1	0 to 2	0 1 to 0·5
Lymphocytes (per cent of white cells)	33	37 2	5 to 78	25 to 35
Monocytes (per cent of white cells)	33	2 9	0 to 9	4 to 8
Serum sodium (mg per 100 c c)	14	296	262 to 325	320 to 350
Plasma-chlorine (mg per 100 c c)	25	335	240 to 380	350 to 380
Serum potassium (mg per 100 c c)	9	22	14 to 31	18 to 20
Serum-calcium (mg per 100 c c)	12	9 4	7 to 12	9 to 11
Plasma inorganic phosphorus (mg per 100 c c)	5	4 8	2 4 to 7	3 to 4
Blood cholesterol (mg per 100 c c)	40	271	80 to 560	150 to 200
Blood urea (mg per 100 c c)	17	34	14 to 45	20 to 40
Fasting blood sugar (mg per 100 c c)	41	74	40 to 110	75 to 100
Plasma protein (gm per 100 c c)	10	6 6	5 3 to 8 2	6 to 8 5

electrophoretic studies on four clinical cases of pituitary tumours or cysts These patients appear to have suffered from fairly severe but not complete hypopituitarism The albumen and alpha globulin were lowered, but the other fractions were increased The mean figures were as follows, albumen 3 46 gm. per 100 c c (normal 3 8 to 5 1), alpha globulin 0 35 gm per 100 c c (normal 0 40 to 0 65), beta globulin 1 30 gm per 100 c c (normal 0 75 to 1 05), gamma globulin 0 91 gm per 100 c c (normal 0 70 to 0 90), and fibrinogen 0 46 gm per 100 c c (normal 0 20 to 0 50) Amino-acid tolerance tests showed no change from the normal Further studies are needed to determine whether the ratio of alpha globulin to beta globulin is a useful method of differentiating hypopituitarism from Addison's disease The blood-cholesterol is usually above normal, but may show great fluctuations in an individual patient from day to day, and is sometimes even subnormal (In cases where more than one estimation was recorded, the mean figure has been given in the Table) The tendency to high figures is presumably related to the hypothyroidism As a result of the fluctuations, it is not possible to attempt any correlation between the rise in blood-cholesterol and the fall in the basal metabolic rate As will be discussed later, these patients frequently have severe hypoglycaemia in the terminal stage of the disease During the course of the disease they tend to have a labile

from severe hypopituitarism, he excreted 2 3 mg per diem This suggests that the testis has little or no androgenic activity, it is not feasible to separate the 17-ketosteroids of adrenal and testicular origin at the low levels which occur in this disease

Corticosteroids of the 11-oxy group have been investigated in two cases Both showed an excretion below 10 Venning-Browne units per diem The normal excretion is 25 to 55 units per diem in women and 25 to 85 units per diem in men

Coma and Death

The grave danger facing patients with hypopituitarism is the development of a particular type of coma which is often fatal Among 96 deaths, 62 patients died in coma, seven not in coma, and information is lacking about the remainder Vomiting, anorexia, intercurrent illnesses, or the missing of meals may precipitate this crisis After a short period of illness, sometimes characterized by a confusional state or slurring of speech, the patient becomes stuporose and within a day or two lapses into unconsciousness This phase may be ushered in by localized twitchings or generalized convulsions During the coma there is sometimes rigidity of the limbs, or of the neck and jaw muscles, the deep reflexes are variable but are commonly lost The blood-pressure may be normal or low, such as 90/50 The pulse is usually very feeble and often impalpable The pulse-rate is variable, sometimes normal, occasionally fast, and often slow Figures of 50 to 60 are given in many cases, and a rate as low as 30 has been recorded by electrocardiography The respirations are very shallow The temperature is usually low, between 95° and 97° F, but there are occasional cases with pyrexia (these patients tend not to respond to treatment) The skin is often strikingly cold to the touch, but remains white, there is no flushing but sweating occasionally occurs Gross ketonuria is common, but there is no air hunger The plasma carbon dioxide was reduced to 37 vols per 100 c c in the only case in which records are available The cerebrospinal fluid appears normal in most respects, but in the two cases in which biochemical examinations were made the chlorides were low (650 and 680 mg per 100 c c) and the sugar was very low (3 and 14 mg per 100 c c)

Death may follow after 12 to 36 hours of coma, but some patients recover after intravenous glucose therapy, and others recover spontaneously When recovery occurs, there is usually pyrexia for the next day or two Some of the patients develop bronchopneumonia and die several days later A patient who has recovered from coma is liable to further attacks of the same type within weeks, months, or even years, and death takes place in one of these attacks

As mentioned earlier, the coma is frequently preceded by a short period of vomiting and anorexia It is not clear on the present evidence whether the vomiting and anorexia are pre-coma manifestations of adrenal cortical failure, or whether these symptoms, whatever their causation, are merely factors which precipitate the coma The difficulty is that there is very little evidence about the blood electrolytes in the pre-coma phase or even during the coma, one patient with a low serum-sodium (276 mg per 100 c c), one patient with a

dose of insulin They show the typical insulin sensitivity during the first half-hour, and the poor response to the hypoglycaemia during the next 1½ hours

Minutes	0	20	30	45	60	90	120
Blood-sugar (mg per 100 c c)	84	49	41	45	46	53	50

Apart from carefully controlled biochemical studies of this type, insulin should never be given to these patients There have been several deaths in clinically undiagnosed cases of hypopituitarism which were subjected to insulin therapy.

Hormone excretion Thyrotrophic hormone was not found in the urine in the one case where this examination was made

Gonadotrophic hormone (follicle stimulating hormone) excretion was investigated in 10 cases The techniques varied, some were sensitive to 30 rat units per diem, some to 10 rat units per diem, some to 10 mouse units in 100 c c urine, and some to 5 mouse units in 100 c c No follicle stimulating hormone could be demonstrated in any of these tests The amount of gonadotrophin excreted after the natural menopause is 20 to 60 rat units per diem This test can therefore be used to differentiate amenorrhoea due to hypopituitarism from that due to a premature natural menopause

Oestrogen excretion was studied in seven cases The techniques varied in sensitivity, 10 and 15 international units per litre of urine, and 20 mouse units per diem (1 mouse unit is roughly 1 to 5 international units) One patient excreted 25 international units per diem, but the results in the other six cases were negative The normal excretion of an adult woman ranges from about 20 to 300 mouse units per diem during the menstrual cycle, and about 10 to 20 mouse units per diem after the menopause

Androgens were estimated biologically in two patients The methods were sensitive to 5 and to 20 international units per diem Negative results were recorded The normal excretion as shown by this method is about 25 to 40 international units The biological methods of investigating androgen excretion have been largely replaced by the chemical estimation of 17-ketosteroids in the urine This method was first applied to the study of hypopituitarism by Fraser and Smith (1941) and has proved of great value The normal excretion is 5 to 12 mg per diem in women, and 10 to 18 mg in men, the amounts are expressed in terms of androsterone In 17 cases of severe hypopituitarism the excretion ranged from 0 to 3 5 mg per diem, with a mean of 0 9 mg , in only four of these cases was the excretion recorded as over 2 mg per diem The details of the chemical methods vary a little, some probably estimate other substances which give similar colour reactions, some may involve adsorption loss of true 17-ketosteroids In addition the colour-absorption curve is rather inaccurate at its lower end As a result, the absolute level of the figures in the cases reviewed here is not to be taken as definitive Nevertheless, with the improved methods in present use, it can be said that a patient with severe hypopituitarism does not excrete more than about 1 mg of 17-ketosteroids per diem, and that an excretion of over 2 mg per diem suggests that the pituitary damage is not serious Estimation of 17-ketosteroids is recorded in only one man suffering

changes in other endocrine glands, this is a subject requiring much further study

Patients who still have a quarter or more of the original gland usually have little evidence of pituitary hypofunction, apart from perhaps a partial amenorrhoea, and the diagnosis can be very uncertain There is no evidence in favour of the common view that lack of emaciation indicates an 'incomplete syndrome' which is due to only moderate or minor damage to the pituitary

Severe deficiency is almost invariably shown clinically by a characteristic syndrome made up of all the following symptoms together This syndrome is the same whatever the pathological lesion which has destroyed the pituitary, be it post-partum necrosis or any other process

(*a*) In many cases a clear indication of the aetiology, such as an onset dating from a delivery at which the patient had a severe circulatory collapse as a result of haemorrhage or shock In other cases there may be little indication of the cause of the pituitary damage

(*b*) Atrophy of the gonads and genital tract, with complete amenorrhoea, impotence, and loss of libido

(*c*) Complete loss of pubic and axillary hair.

(*d*) Absence of normal skin pigment, particularly obvious around the nipples, and lack of response to test sun irradiation

(*e*) A characteristic flabby facies, with thinning of the eyebrows and pallor of the cheeks

(*f*) Absence of sweating of [illegible] normal greasiness of the [illegible]

[illegible] ow soft speech

[illegible] under 1 mg per diem

[illegible] sensitivity and hypo-

[illegible] ngerous coma

[illegible] tor sometimes similar

[illegible] t hypochromic

[illegible]) mg per 100 c c

[illegible] ilure to diagnose the

coi

I

T

[illegible] e, with a failure to

reco

(*a* [illegible] ner as myxoedema

whic

normal plasma-chlorine (350 mg per 100 c c) In the few estimations which have been recorded, the blood-urea and non-protein nitrogen were normal except in the pyrexial cases, where the blood-urea reached levels of 100 to 120 mg per 100 c c. Further evidence is required on the possible role of the adrenal cortex in the production of these effects On the other hand, there can be no doubt that the coma in most of these patients is associated with severe hypo glycaemia In nine out of 14 patients the blood-sugar was recorded as between 10 and 30 mg per 100 c c There were nine patients in whom coma was precipitated by insulin, and five died as a result Intravenous glucose was given to 19 patients who were in coma, and 15 recovered consciousness, although they became comatose again and died a day or two later (The present analysis is restricted to fatal cases) It seems probable that the four patients who were not saved by intravenous glucose had been left in coma too long before treatment was initiated More prolonged administration of glucose might have saved the 15 patients who were only temporarily revived Once hypoglycaemia has developed, large doses of glucose produce only a transient rise of blood-sugar, this is well seen when glucose is given after an insulin tolerance test

A recent case suggests that the coma is sometimes due to a type of Addisonian crisis The patient, a woman aged 56 years, had a characteristic history of post-partum necrosis 23 years earlier, followed by symptoms of severe chronic hypopituitarism She had abdominal pain, nausea, and vomiting for two days, and then in the course of a few hours, became deeply comatose The limbs were flexed and very rigid The blood-sugar was 70 mg , serum-sodium 230 mg , plasma-chlorine 225 mg , blood-urea 56 mg , and blood-cholesterol 235 mg per 100 c c Intravenous injection of 100 c c of 50 per cent glucose solution produced a rapid but only partial improvement, the coma became less deep and the muscular rigidity decreased Intravenous saline, desoxycorticosterone, and eucortone were given subsequently, but did not produce any obvious effect The patient recovered slowly during the next few days

Diagnosis

A confident diagnosis of complete hypopituitarism can usually be made easily from a short clinical examination The special tests are chiefly of value for confirmation of the diagnosis, for assessment of the severity of the disease, and for academic study

In patients who have a small amount of actively functioning pituitary tissue, certain aspects of the syndrome may develop quickly to their fullest extent, while others may not appear until many years have elapsed, or may even fail to appear Some of the patients present mainly the appearance of myxoedema, and others mainly that of adrenal cortical failure There appears to be no regular pattern in the development of the symptoms in these cases, apart from the constant occurrence of genital atrophy and loss of body hair The order of the partial syndrome may possibly be related to the amount of residual pituitary parenchyma, or to the particular type of cells remaining there, or to coincidental

changes in other endocrine glands, this is a subject requiring much further study

Patients who still have a quarter or more of the original gland usually have little evidence of pituitary hypofunction, apart from perhaps a partial amenorrhoea, and the diagnosis can be very uncertain There is no evidence in favour of the common view that lack of emaciation indicates an 'incomplete syndrome' which is due to only moderate or minor damage to the pituitary

Severe deficiency is almost invariably shown clinically by a characteristic syndrome made up of all the following symptoms together This syndrome is the same whatever the pathological lesion which has destroyed the pituitary, be it post-partum necrosis or any other process

(*a*) In many cases a clear indication of the aetiology, such as an onset dating from a delivery at which the patient had a severe circulatory collapse as a result of haemorrhage or shock In other cases there may be little indication of the cause of the pituitary damage

(*b*) Atrophy of the gonads and genital tract, with complete amenorrhoea, impotence, and loss of libido

(*c*) Complete loss of pubic and axillary hair.

(*d*) Absence of normal skin pigment, particularly obvious around the nipples, and lack of response to test sun irradiation

(*e*) A characteristic flabby facies, with thinning of the eyebrows and pallor of the cheeks

(*f*) Absence of sweating of the skin, and loss of the normal greasiness of the axilla

(*g*) An impalpable thyroid gland

(*h*) Increased sensitivity to cold

(*i*) Physical weakness and mental torpidity, with slow soft speech

(*j*) A low basal metabolic rate, about —35 per cent

(*k*) A very low urinary excretion of 17-ketosteroids, under 1 mg per diem

(*l*) An insulin tolerance test characterized by insulin sensitivity and hypoglycaemia unresponsiveness

(*m*) A tendency to spontaneous hypoglycaemia and dangerous coma

(*n*) A failure of water diuresis, with a Kepler test factor sometimes similar to that seen in Addison's disease, sometimes higher

(*o*) A moderate degree of anaemia, which is usually not hypochromic

(*p*) Usually a raised blood-cholesterol, about 250 to 300 mg per 100 c c

(*q*) Usually lowered blood-levels of sodium and chlorine

Differential diagnosis There are four main reasons for failure to diagnose the condition

1 *Partial diagnosis*

This is the recognition of only one aspect of the syndrome, with a failure to recognize the other aspects

(*a*) Most of the patients are diagnosed at one time or other as myxoedema which does not respond properly to thyroid

(*b*) Nearly all the patients have had prolonged treatment for anaemia and, not infrequently, for pernicious anaemia The unsatisfactory response to treatment and the results of haematological examinations suggest that the diagnosis is incomplete

(*c*) Despite the amenorrhoea, very few of the female patients consult gynaecologists If they do, there is the possibility of a diagnosis of superinvolution of the uterus, with a lack of recognition of the underlying cause Furthermore, in women past the age of 45 years, the amenorrhoea and atrophy of the genital tract may be passed as normal post-menopausal changes However, even in extreme old age, there is usually some pubic hair in the patient with a normal pituitary.

(*d*) The biochemical changes occasionally suggest the diagnosis of Addison's disease without pigmentation, but it is usually obvious that the patient's condition cannot be explained as due to adrenal insufficiency alone.

(*e*) Blood-sugar estimations may lead to a diagnosis of hypoglycaemia This condition may be regarded as idiopathic or due to alimentary tract disturbances, or an islet cell tumour may be suspected and an exploratory laparotomy carried out

(*f*) In the cases which follow a complicated delivery, the diagnosis of post-partum debility may be maintained for as long as a year or two However, these patients may first be seen by a physician many years later, and the relationship to the delivery may easily be missed

(*g*) In the later stages a number of patients present mental symptoms and are removed to asylums, where attention is focused more on the psychological than the physical aspects of the condition

(*h*) A female patient may sit all day near the fire, apparently an idle negligent slattern taking no care of her home and children or of her own appearance, and not seeking medical advice Such a woman is liable to be dealt with by the social services as a 'problem mother', the physical basis of the condition being unrecognized

2 *Mistaken diagnosis of other diseases*

(*a*) Probably the commonest erroneous diagnosis is that of nephritis This is based on the white and sometimes slightly puffy face, there may be some albuminuria due to urinary infection The diagnosis is usually abandoned when further investigations have been made

(*b*) Occasionally the patient is considered to have a post-encephalitic condition This is based on the expressionless face, monotonous voice, and peculiar mental slowness There is, however, no tremor, rigidity, salivation, or other characteristic sign

(*c*) During the terminal coma, various mistakes in diagnosis may be made Common errors are the diagnosis of cerebral thrombosis (the gradual onset of the coma), meningitis (the rigid neck muscles), epilepsy (the initial convulsions), uraemia (the white puffy face, and the raised blood-urea if pyrexia is present), the Stokes-Adams syndrome (the slow pulse), diabetic coma (the ketonuria),

hypoglycaemia of uncertain origin, and narcotic poisoning In all cases of coma where the cause is not apparent, the pubes should be inspected If pubic hair is absent, a vaginal examination should be made or the testes palpated

3 *Mistaken diagnosis of hypopituitarism*

The opposite aspect of the differential diagnosis is the question of what other diseases may simulate hypopituitarism clinically

(*a*) True hypothyroidism may mimic some aspects of hypopituitarism The rough skin, severe loss of head hair, characteristic facies, and the presence of some pubic hair should point to the true diagnosis of myxoedema The results of the insulin tolerance test, 17-ketosteroid excretion, and the Kepler test are quite different from those in hypopituitarism The mild degree of possible hypothyroidism in the puerperium described by Roberton (1948) should also be easily distinguishable

(*b*) Female patients with Addison's disease sometimes lose their pubic hair, possibly half the cases Men may show a reduction to a female escutcheon The insulin tolerance test, the Kepler test and, in women, the 17-ketosteroid excretion may give results similar to those seen in hypopituitarism Certain of the clinical symptoms are common to the two diseases However, the presence of pigmentation in Addison's disease, and the evidence of thyroid and gonad insufficiency in hypopituitarism, should serve to differentiate the conditions

(*c*) Ovarian agenesis and the other related primary amenorrhoeas commonly lead to a failure of development of the genital tract and of pubic and axillary hair, and may be associated with low 17-ketosteroid excretion There may be stunting of growth A detailed examination is often required before it can be said that the patient is not suffering from hypopituitarism which had its onset in childhood

(*d*) The general group of dwarfism and infantilism is excluded from consideration in the present paper, the part played by the pituitary in these disorders is very complex

(*e*) Hypothalamic lesions may give clinical evidence of their situation, but they may also produce symptoms suggestive of hypopituitarism This again is too large a subject to consider here

(*f*) In haemochromatosis there is sometimes extreme genital atrophy, loss of pubic, axillary, and beard hair, and absence of 17-ketosteroid excretion, and the blood-sugar may fall to almost normal levels The skin may not be pigmented These findings may suggest that the diabetes mellitus has led to lateral necroses in the pituitary with resultant loss of function of the gland However, in one case of this type which we examined, the pituitary was histologically normal apart from slight haemosiderin deposition

(*g*) In old age the axillary hair may disappear completely and the pubic hair become very sparse Similar changes may occasionally occur in prolonged emaciating diseases The distribution of the remaining pubic hair is normal, whereas in hypopituitarism there is complete loss over the pubes and only scanty hair on the labia majora

4 *Erroneous conceptions of the syndrome of hypopituitarism*

Finally, short consideration is required of cases where the diagnosis of hypopituitarism rests on an erroneous conception of the clinical syndrome which results from loss of the pituitary

(*a*) The prevalent opinion that emaciation is a cardinal symptom has led to the diagnosis of hypopituitarism being made in many cases of gross wasting due to various causes This error occurs most commonly in anorexia nervosa

Anorexia nervosa and hypopituitarism have two chief symptoms in common, amenorrhoea and a low basal metabolic rate In the former condition the amenorrhoea is functional and the low basal metabolic rate purely due to the malnutrition, both symptoms rapidly disappear when the psychological disturbance is corrected and the food intake becomes adequate There is no clinical evidence to indicate any reduction of pituitary function, and there is no justification in the present state of knowledge for postulating that the amenorrhoea and low basal metabolic rate are due to a functional hypopituitarism. Autopsies on these patients do not show any significant histological abnormality in the pituitary

(*b*) Similar remarks apply to progeria, which in earlier descriptions was regarded as a constant manifestation of hypopituitarism White-haired, wizened women, particularly if they appear thin, are sometimes diagnosed as cases of Simmonds's disease, and the low basal metabolic rate due to the malnutrition is adduced as supporting evidence Such cases rarely bear any critical examination

Summary

1 Among the published records of cases of true hypopituitarism examined at autopsy, there are 95 with long-standing lesions which had destroyed all, or nearly all, of the pituitary without damaging the hypothalamus These can be accepted as pathologically proved examples of severe chronic hypopituitarism

2 From an analysis of the clinical course in these reliable cases, the true syndrome is outlined The syndrome in cases of severe pituitary damage is the same whatever the pathological process which has destroyed the pituitary

3 The common description of the syndrome in recent literature is incorrect, in that it includes a number of spurious characteristics, such as emaciation and progeria Most of the cases which show these two symptoms have no significant lesion in the pituitary

Acknowledgements

Our thanks are due to those physicians and pathologists who have referred patients to us

REFERENCES

1 Adler, L D (1933) *South African M.J.* 7, 216
2 Aitken, R S, and Russell, D S (1934) *Lancet*, 2, 802.
3 Alpers, B J (1942) *M Clin North America*, 26, 1679
4 Altmann, F (1928) *Frankfurt Ztschr f Path* 36, 393.
5 —— (1930) *Beitr z path Anat* 85, 205
6 Apitz, K (1938) *Virch Arch f path Anat* 302, 555
7 Austregésilo, A., Pinheiro, M, and Marques, E (1913) *Encéphale*, 8, 150.
8 Babinski, M. J (1900) *Rev neurol* 8, 531
9 Bailey, O T, and Cutler, E C (1940) *Arch Path* 29, 368
10 Baker, A. B, and Craft, C B (1940) *Endocrinology*, 26, 801
11 Balen, G F van (1939) *Acta med Scandinav* 101, 433
12 —— (1947) *Nederl tydschr v geneesk* 91, 211
13 Battiscombe, C G (1888) *Lancet*, 1, 971
14 Beadles, C F (1897) *Tr Path Soc London*, 48, 1
15 Beck (1835) *Ztschr f d Ophth* 4, 401
16 Beckmann, J W, and Kubie, L S (1929) *Brain*, 52, 127.
17 Béclère, C, and Simonnet, H. (1946) *Presse méd* 54, 175
18 Benda, C (1900) *Berl klin Wchnschr* 37, 1205
19 Berberich, J (1926) *Monatschr f Kinderh* 34, 595
20 Berblinger, W (1921) *Mitt a d Grenzgeb d Med u Chir* 33, 92
21 —— (1931) *Centralbl f allg Path u path Anat* 50, 2
22 —— (1932) *Hirsch's Handbuch der inn Sekretion*, 1, 910
23 —— (1934) *Endokrinologie*, 14, 369
24 —— (1939) *Schweiz med Wchnschr* 69, 1217
25 Bergmann, G von (1934) *Deutsche med Wchnschr* 60, 159
26 Bergstrand, H (1939) *Acta chir Scandinav* 82, 227
27 Bettoni, I, and Orlandi, N (1932) *Zentralbl f d ges Neurol.* 65, 110
28 Bianchi, G (1914) *Zentralbl f inn Med* 10, 153
29 Bierring, E, and Iversen, M (1943) *Nord Med* 19, 1115
30 Biggart, J H (1941) *Ulster M J.* 10, 87.
31 Bleibtreu, L (1905) *München med Wchnschr* 52, 2079
32 Bloom, A, and Bryson, C C (1948) *Brit Med J* 2, 75
33 Bock, E (1924) *Virch Arch f path Anat* 252, 98
34 Boller, R, and Goedel, A. (1935) *Wien Arch f inn Med* 27, 41
35 Bolsi, D (1924) *Riv di patol nerv* 29, 824.
36 Boom, H, and Boehmer, J W (1938) *Nederl tydschr v geneesk* 82, 5731
37 Borne, G A. K von dem (1942) *Nederl tydschr v geneesk* 86, 363
38 Bostroem, A (1918) *Med Klin* 14, 690
39 —— (1931) *Deutsche Ztschr f Nervenh* 117, 27
40 Boyce, R, and Beadles, C F (1893) *J Path and Bact* 1, 359
41 Brissaud, H H., Gougerot, H, and Gy, A (1908) *Rev neurol* 16, 1354
42. Broussilovski, L (1925) *Encéphale*, 20, 734
43. Broustet, P, and Sarie, R (1936) *Gaz méd de France*, 43, 801 (quoted by Mahaux, 1947)
44 Buchler, P (1921) *Ztschr f d ges Neurol* 72, 207
45 Buday, K (1923) *Klin Wchnschr* 2, 902
46 Budde, M (1921) *Frankfurt Ztschr f Path* 25, 16
47 Canavan, M M (1940) *Arch Path* 29, 310
48 Caughey, J E (1946) *New Zealand M J* 45, 485
49 Chabanier, H., Puech, P, Lobo Onell, C, and Lelu, E (1936) *Presse méd* 44, 986
50 Chiari (1913) *Deutsche med Wchnschr* 2, 1662
51 Christeller, E (1914) *Virch Arch f path Anat* 218, 185
52 Claude, H., and Gougerot, H. (1907) *Compt rend Soc de biol* 63, 785.
53 —— —— (1908) *J de physiol et de path gén* 10, 469

54 Cohn, E (1923) *Virch Arch f path Anat* 240, 452.
55 Coleman, C C, and Meredith, J M (1940) *Arch Neurol and Psychiat* 44, 1076
56 Constobadie, L P, and Ryrie, B. J (1924) *Lancet*, 2, 1007
57 Cooke, R T (1945) *Brit Med J* 2, 493
58 Critchley, M, and Ironside, R N (1926) *Brain*, 49, 437
59 Cunningham, J F, McGrath, J, O'Donovan, D K, and de Valera, E (1942) *Irish J M Sc* 201, 519.
60 Curschmann, H (1929) *Ztschr f ärtzl Fortbild* 26, 409
61 Dandy, W E, and Goetsch, E (1910–11) *Am J Anat* 11, 137.
62 Darley, W, Gordon, R W, and Neubuerger, K T (1944) *Ann Int Med* 21, 890
63 Daughaday, W H, Williams, R H, and Daland, G A (1948) *Blood*, 3, 1342
64 Davis, M A, and Postle, B (1938) *Ohio State M J* 34, 879
65 Dell'Acqua, G (1946) *Schweiz med Wchnschr* 76, 611
66 Dimmel, H (1927) *Wien Arch f inn Med* 13, 377
67 Doane, J C, Blumberg, N, and Tephick, G (1940) *Endocrinology*, 27, 766
68 Dods, L F, and Byrom, F B (1946) *Proc Roy Australasian Coll Phys* 1, 34
69 Duffy, W C (1920) *Ann Surg* 72, 537
70 Dunn, C W (1944) *M Clin North America*, 28, 1386
71 Ekelund, C (1945) *Nord Med* 28, 2640
72 Elden, C A (1936) *Endocrinology*, 20, 679
73 —— and Kuminer, A J (1943) *J Clin Endocrinol* 3, 596
74 Erdheim, J (1916) *Beitr z path Anat* 62, 302
75 Escamilla, R F, and Lisser, H (1938) *California and West Med* 48, 343
76 —— —— (1942) *J Clin Endocrinol* 2, 65
77 Esser, A (1927) *Centralbl f allg Path u path Anat* 39, 97
78 Evensen, O K (1947) *Nord Med* 33, 258
79 Fahr, T (1918) *Deutsche med Wchnschr* 44, 206
80 —— (1922–3) *Centralbl f allg Path u path Anat* 33, 481
81 Falta, W (1923) *Die Erkrankungen der Blutdrüsen*, Springer, Vienna
82 —— and Spitzenberger, O (1937) *Strahlentherapie*, 60, 385
83 Farber, J E (1940) *Ann Int Med* 13, 2171
84 —— Goldstein, K, and Beswick, W F (1941) *J Clin Endocrinol* 1, 688
85 Farquharson, R F, Belt, T H, and Duff, G L (1938) *Tr Am Clin and Climat A* 54, 106
86 —— and Graham, D (1931) *Tr Assoc Am Physicians*, 46, 150
87 Faure Beaulieu, M, Villaret, M, and Sourdel, M (1911) *Presse méd* 19, 691
88 Feldman, F, Roberts, J B, Susselman, S, and Lipetz B (1947) *Arch Int Med* 79, 322
89 Fink, E B. (1926) *Endocrinology*, 10, 317
90 —— (1933) *Arch Path* 15, 631
91 Fleckseder, R (1938) *Wien Klin Wchnschr* 51, 1093
92 Fodor and Jankovich (1921) *Zentralbl f d ges Tuberk* 15, 407
93 Foster, M A, and McCarter, J C (1941) *J Clin Endocrinol* 1, 436
94 Fraenkel, E (1916) *Deutsche med Wchnschr* 42, 1369
95 —— (1922) *Klin Wchnschr* 1, 552
96 Fraser, R, and Smith, P H (1941) *Quart J Med*, N S 10, 297
97 Froboese, C (1918) *Centralbl f allg Path u path Anat* 29, 145
98 Fulstow, M (1928) *Am J Path* 4, 87
99 Gilford, H. (1904) *Practitioner*, 73, 188
100 Glanzmann, E, and Wegelin, C (1942) *Schweiz med Wchnschr* 72, 1401
101 Glass, S J (1944) *J Clin Endocrinol* 4, 273
102 —— and Davis, S (1944) *Ibid* 4, 489
103 Globus, J H, and Gang, K M (1945) *J Mt Sinai Hosp* 12, 220
104 —— Goldfarb, A I, and Silver, S (1947) *Ibid* 14, 308
105 Goldstein, K. (1928) *Deutsche Ztschr f Nervenh* 103, 225
106 Goldzieher, J W (1946) *Arch Path* 41, 203

107 Goldzieher, M. A (1939) *The endocrine glands*, New York, 395
108 Good, T S, and Newman, K O (1929) *Lancet*, **1**, 765
109 Good, W H, and Ellis, A. G (1918) *Endocrinology*, **2**, 431
110 Gougerot, H., and Gy, A (1911) *Nouv iconog de la Salpêtrière Par* **24**, 449
111 Graubner, W (1925) *Ztschr f. klin Med* **101**, 249
112 Greenblatt, R B, and Kupperman, H S (1947) *South M J* **40**, 737
113 Griffiths, G M (1940) *Brain*, **63**, 350
114 Gunther, L, and Courville, C B (1935) *J Nerv and Ment Dis* **82**, 40
115 Haban, G (1935) *Endokrinologie*, **15**, 158
116 Hall, E M, and Hemken, L (1936) *Arch Int Med* **58**, 448
117 Hann, F von (1918) *Frankfurt Ztschr f Path* **21**, 337
118 Hantschmann, L (1934) *Deutsches Arch f klin Med* **176**, 397
119 —— (1938) *Deutsche med Wchnschr* **64**, 361
120 Hart, J F, and Lisa, J R (1939) *Endocrinology*, **25**, 130
121 Haushalter, P, and Lucien, M (1908) *Rev neurol* **15**, 1
122 Heidema, S T (1927) *Nederl tydschr v geneesk* **71**, 2545
123 Heidkamp, H (1912) *Virch Arch f path Anat* **210**, 445
124 Heinrichs, H (1931) *Frankfurt Ztschr f Path* **41**, 512
125 Hektoen, L (1896) *Tr Chicago Path Soc* **2**, 129
126 Herlant, M (1946) *Acta clin belg* **1**, 197
127 Heslop, T P (1848) *Dublin Quart J M Sc* **6**, 46
128 Hess Thaysen, P E, and Warming-Larsen, A (1943) *Ugesk f Laeger* **105**, 1107
129 Heuser (1917) *Inaug Diss Frankfurt* (quoted by Berblinger, 1932)
130 Hirsch, S (1922) *Deutsches Arch f klin Med* **140**, 323
131 —— and Berberich, J (1924) *Klin Wchnschr* **3**, 483
132 Hoet, M (1933) *Bull Acad roy de méd de Belgique*, **13**, 445
133 Hoffman, J (1944) *Female endocrinology*, Philad, 566
134 Howard, C P, and Rhea, L J (1936) *Internat Clin* **1**, 1
135 Hübschmann, H (1937) *München med Wchnschr* **84**, 697
136 Hueter, C (1905) *Virch Arch f path Anat* **182**, 219
137 —— (1917) *München med Wchnschr* **64**, 1563
138 Hunter, W (1898) *Tr Path Soc London*, **49**, 249
139 Illig, W (1928) *Virch Arch f path Anat* **270**, 549
140 Jaffé, R (1922) *Frankfurt Ztschr f Path* **27**, 324
141 Jennings, G H (1948) *Brit Med J* **1**, 443
142 Jersild, T (1943) *Nord Med* **20**, 1789
143 —— and Iversen, K (1943) *Acta med Scandinav* **116**, 58
144 Josephy, H (1920) *Ztschr f d ges Neurol* **58**, 56
145 —— (1922) *Deutsche Ztschr f Nervenh* **74**, 234
146 Jungmann, P (1922) *Klin Wchnschr* **2**, 1546
147 —— (1923) *Ibid* **2**, 18
148 Kaminski, J (1933) *Frankfurt Ztschr f Path* **45**, 290
149 Katzenstein, R (1933) *Virch Arch f path Anat* **289**, 222
150 Keilmann, K. (1922–3) *Centralbl f allg Path u path Anat* **33**, 113
151 Kirketerp, P (1944) *Nord Med* **24**, 1919
152 Kirshbaum, J D, and Levy, H A (1941) *Arch Int Med* **68**, 1095
153 Kiyono, H (1924) *Virch Arch f path Anat* **252**, 118
154 —— (1926*a*) *Ibid* **259**, 388
155 —— (1926*b*) *Ibid* **262**, 149
156 Knoll, W (1922) *Wien Arch f inn Med* **4**, 555
157 Koch, W (1920) *Verhandl d deutsch path Gesellsch* **21**, 274
158 Kon, J (1908) *Beitr z path Anat* **44**, 233
159 Korth, C, Lüdeke, H, and Marx, H (1937) *Virch Arch f path Anat* **300**, 141
160 Kotte, J H, and Vonderahe, A R (1940) *J.A.M.A* **114**, 950
161 Kraus, E J (1919) *Beitr z path Anat* **65**, 535
162 —— (1924) *Med Klin* **20**, 1292

163 Kraus, E J (1937) *Klin Wchnschr* **16**, 1528
164 —— (1942) *J Lab and Clin Med* **28**, 140
165. —— and Reisinger, A. (1924) *Frankfurt Ztschr f. Path* **30**, 68.
166 Krumbhaar, E B (1921) *M Clin North America*, **5**, 927
167 Kufs (1905) *Arch f Psychiat* **39**, 134
168 —— (1915) *Ztschr. f d ges Neurol* **30**, 286
169 Kylin, E (1935) *Ergebn d inn Med* **49**, 1
170 —— (1936) *Klin Wchnschr* **15**, 1756
171 —— (1938) *Acta med Scandinav* **96**, 75
172. Labbé, M (1935) *J d praticiens*, **49**, 52
173 Lancereaux (1859) *Bull Soc anat Paris*, **2**, 106
174 Lang, W R (1946) *M J Australia*, **1**, 335
175 Langen, C D de (1937) *Nederl tydschr v geneesk* **81**, 2897
176 Langeron, L, Giard, P, and Nolf, V (1945) *Ann d'endocrinol* **6**, 166
177 Larsen, G (1947) *Nord Med* **33**, 260
178 Laub, G R (1940) *South Med and Surg* **102**, 56
179 Launois and Cleret (quoted by Berblinger, 1932)
180 Lerman, J, and Means, J H (1945) *J Clin Endocrinol* **5**, 119
181 —— and Stebbins, H D (1942) *J.A M A* **119**, 391
182 Leschke, E (1919) *Ztschr f klin Med* **87**, 201
183 Lichtenfeld, C (1938) *Zentralbl f inn Med* **59**, 913 and 930
184 Liebers, M (1932) *Allg Ztschr f Psychiat* **97**, 158
185 Lindemann, E (1923) *Virch Arch f path Anat* **240**, 11
186 Lucien, M, and Parisot, J (1909) *Rev neurol* **16**, 970
187 Mahaux, J. (1941) *Ann d'endocrinol* **2**, 193
188 —— (1947) *Essai de physiopathologie thyrohypophysaire*, Liége
189 Mallory, T B (1940*a*) *New England J Med* **222**, 766
190 —— (1940*b*) *Ibid* **223**, 588
191 Marani, B D (1938) *Endocrinol e pat costit* **13**, 74 and 253
192 Marañon, G. (1926) *Deutsches Arch f klin Med* **151**, 129
193 Marinesco, G, and Parhon, C I (1932) *Rev franç d'endocrinol* **10**, 105
194 Mayer, K (1919) *Zentralbl f Chir* **46**, 455
195 McCullagh, E P, Lewis, L A, and Owen, W F (1943) *Cleveland Clin Quart* **10**, 88
196 McGavack, T H, Saccone, A, Vogel, M, and Harris, R (1946) *J Clin Endocrinol* **6**, 776
197. Means, J H, Hertz, S, and Lerman, J (1940) *Tr Assoc Am Physicians*, **55**, 32
198 Meerwein, F (1938) *Frankfurt Ztschr f Path* **52**, 54
199 Melton, E I, and McNamara, W L (1946) *Ann Int Med* **25**, 525
200 Meng, H (1928) *Frankfurt Ztschr f Path* **36**, 650
201 Merlino, A (1941) *Arch di Ost e Gin* **5**, 251
202 Merz, W (1930) *Frankfurt Ztschr f Path* **40**, 452
203 Meyenburg, H von (1916) *Beitr z path Anat* **61**, 550
204 Meyer, L (1861) *Allg Ztschr f Psychiat* **18**, 287
205 Meyer, O (1918) *Ztschr f Psych* **74**, 521
206 Micromet, C W G (1922) *Geneesk Bladen*, **28**, 8 (quoted by Pennetti, 1928)
207 Mogilnitzky, B N (1928) *Virch Arch f path Anat* **269**, 1
208 Monakow, P von (1921) *Schweiz Arch f Neurol u Psychiat* **8**, 200
209 —— (1922) *Verh der Gesellsch f inn Med* **34**, 355
210 Moran, T J, and Fetterman, G H (1941) *J Lab and Clin Med* **26**, 1289
211 Morse, M. E (1923–4) *J Neurol and Psychopath* **4**, 1
212 Moss, R E (1942) *J Clin Endocrinol* **2**, 395
213 Müller, E (1923) *Klin Wchnschr* **2**, 1576
214 Nonne, M (1922) *Deutsche Ztschr f Nervenh* **74**, 168
215 Odin, M (1928) *Acta med Scandinav* Suppl **26**, 182
216 Øllgaard, J (1945) *Nord Med* **28**, 2586
217 Pappenheim, M (1934) *Wien klin Wchnschr* **47**, 148

218 Parhon, C J , and Briesse, M. (1922) *Rev neurol* 29, 710
219 Pennetti, G (1928) *Riforma med* 44, 9
220 Pettersson, A S (1928) *Acta med Scandinav* 69, 232
221 Plaut, R (1922) *Deutsches Arch f klin Med* 139, 285
222 Plummer, D E , and Jaeger, J R (1938) *Arch Neurol and Psychiat* 40, 1013.
223 Ponfick, E (1899) *Ztschr f klin Med* 38, 1
224 Priesel, A (1920) *Beitr z path Anat* 67, 220
225 —— (1927) *Virch Arch f path Anat* 266, 407
226 Purves Stewart, J (1909) *Review Neurol and Psychiat* 7, 225
227 Rau, L (1935) *Lancet*, 1, 1502
228 Reuter, A , and Lamprecht, I (1937) *Deutsche med Wchnschr* 63, 1033.
229 Reuter, C (1941) *Deutsche Ztschr f Nervenh* 152, 262
230 Reverchon, L , Delater, G , and Worms, G (1923) *Rev neurol* 30, 217
231 —— Worms, G , and Rouquier, A (1921) *Presse méd* 29, 741
232 Riecker, H H , and Curtis, A C (1932) *J.A.M.A* 99, 110
233 Rijsewijk, C T H van (1937) *Nederl tydschr v geneesk* 81, 32
234 Rizzi, I (1941) *Arch 'de Vecchi' per anat pat e med clin* 3, 62
235 Roberton, H E W (1948) *Brit Med J* 2, Suppl 93
236 Robertson, J S (1945) *M J Australia*, 2, 245
237 Rössle, R (1934) *Verhandl d deutsch path Gesellsch* 27, 152
238 Rowlands, R A , Simpson, S L , Russell, D S , and Turnbull, H M (1942) *Brit J Surg* 29, 304.
239 Rozynek, M (1942) *Virch Arch f path Anat* 308, 776
240 Sainton, P , and Rathery, F (1908) *Bull et mém Soc méd d hôp de Paris*, 25, 647
241 Salomon, H , and Lascano, J C (1942) *Semana méd* 49, 746 (Abstract in *Year Book Neurol and Endocrinology*, 1942)
242 Schaefer, H (1919) *Inaug Diss Jena* (Abstract in 1920 *Centralbl f allg Path u path Anat* 30, 602)
243 Schellong, F (1932) *Klin Wchnschr* 11, 53
244 Schereschewsky, N A. (1927) *Rev franç d'endocrinol* 5, 275
245 Schermann, J (1945) *Arq clin* 1, 230
246 Schlagenhaufer, O (1916) *Virch Arch f path Anat* 222, 249
247 Schmidtmann, M (1919–20) *Centralbl f allg Path u path Anat* 30, 3
248 Schmitt, P (1923–4) *Ibid* 34, 466
249 Schob and Güntz (1932) *Allg Ztschr f Psychiat* 97, 242
250 Schürmann (1934) *Deutsche med Wchnschr* 60, 157
251 Seeger, E (1939) *München med Wchnschr* 86, 882
252 Sheehan, H L (1937) *J Path and Bact* 45, 189
253 —— (1939) *Quart J Med*, N S 8, 277
254. —— (1940) *Lancet*, 2, 321
255 —— (1948) *Irish J M Sc* 270, 241
256 —— and McLetchie, N G B (1943) *J Obst and Gyn Brit Emp* 50, 27
257 —— and Murdoch, R (1938) *Ibid* 45, 456
258 Simmonds, M (1914*a*) *Deutsche med Wchnschr* 40, 322
259 —— (1914*b*) *Virch Arch f path Anat* 217, 226
260 —— (1914*c*) *Dermat Wchnschr* 58, 104 (quoted by Jaffé, 1922)
261. —— (1916) *Deutsche med Wchnschr* 42, 190
262 —— (1917) *Virch Arch f path Anat* 223, 281
263 —— (1918) *Deutsche med Wchnschr* 44, 852
264 —— (1919) *Ibid* 45, 487
265 Simonds, J P , and Brandes, W W (1925) *J.A.M.A* 84, 1408
266 Simons, A (1922) *Zentralbl f d ges Neurol* 30, 125
267 —— (1925) *Ibid* 39, 191.
268 Simpson, S L (1948) *Major endocrine disorders*, London (2nd ed)
269 Slessor, A (1946) *Quart J Med* N S 15, 318
270 Sokoloff, A (1896) *Virch Arch f path Anat* 143, 333

271. Solomon, H A , Weiss, A , and Hochstein, E (1940) *Endocrinology*, 26, 785
272 Sommer, H (1910) *Ztschr f Laryngol* 2, 355
273 Stenström, T (1926) *Deutsches Arch f klin Med* 152, 173
274 —— and Sjövall, H (1933) *Acta path Scandinav*, Suppl 16, 484
275 Stephens, D J (1939) *New Internat Clin* 1, 97
276 —— (1940) *Am J M Sc* 199, 67
277 Strauss, L., and Globus, J H (1930) *J Nerv and Ment Dis* 72, 557
278. Stroebe (1903) *Beitr z path Anat* (quoted by Turner, 1910)
279 Talbot, N B , Butler, A M , Pratt, E L , MacLachlan, E A , and Tannheimer, J (1945) *Am J Dis Child* 69, 267
280 Thaon, P (1907) *L'hypophyse*, Doin, Paris
281 Thibaut, F (1947) *Wien klin Wchnschr* 59, 409
282. Tillgren, J (1935) *Brit J Dermat* 47, 223
283 Turner, J (1910) *Review Neurol and Psychiat* 8, 344
284 Uemura, S (1917) *Frankfurt Ztschr f Path* 20, 381
285 Urechia, C I , and Rotezeanu, A (1930) *Bull et mém Soc méd d hôp de Paris*, 55, 698
286 Vandenbroeck, J , and Ferin, J (1947) *Ann d'endocrinol* 8, 366
287 Veit, B (1922) *Frankfurt Ztschr f Path* 28, 1
288 Venning, E H , and Browne, J S L (1947) *J Clin Endocrinol* 7, 79
289 Visser, A K (1946) *Nederl tijdschr v geneesk* 90, 1864
290 Wadsworth, R. C , and McKeon, C (1941) *Arch Neurol and Psychiat* 46, 277
291 Wagner, E (1862) *Arch f Heilk* 3, 381
292 Weigert, C (1875) *Virch Arch f path Anat* 65, 212
293 Weinstein, A (1935) *Am J Med Sc* 189, 245
294 Weisman, A D (1944) *New England J Med* 231, 118
295 Werner, S C , and West, R (1943) *J Clin Investigation*, 22, 335
296 Werthemann (1930) *Klin Wchnschr* 9, 182
297 Westphal, C (1863) *Allg Ztschr f Psychiat* 20, 481
298 Wilder, J (1946) *Confinia neurol* 7, 96
299 Williams, J E (1940) *Texas State J Med* 35, 672
300 Williams, R H , and Whittenberger, J L (1942) *J Clin Endocrinol* 2, 539
301 —— Whittenberger, J L , Bissell, G W , and Weinglass, A R (1945) *Ibid* 5, 163
302 Wohl, M G , and Larson, E (1942) *M Clin North America*, 26, 1672
303 Wood, C E (1909) *J A M A* 52, 700
304 Woolley, P G (1915) *J Lab and Clin Med* 1, 155
305 Zajewloschin, M N (1932) *Frankfurt Ztschr f Path* 43, 335
306 Zenoni, C (1913) *Sperimentale*, 67, 249
307 Zondek, H (1923) *Deutsche med Wchnschr* 49, 339

APPENDIX

The following cases illustrate the various aspects of the clinical syndrome and the pathology The first series of cases was investigated pathologically and the patients are described in some detail The series consists of five severe cases (four due to post-partum necrosis, and the other an indeterminate scarring), three moderate cases (two of healed giant-cell granuloma, and the other an extrasellar tumour), and two minor cases (an empty sella, and an intrasellar cholesterol cyst) The second series consists of nine severe cases due to post-partum necrosis, but with only clinical evidence, they are described as a composite group

Post-partum Necrosis

The following four fatal cases are examples of severe hypopituitarism due to gross post-partum necrosis

C L , 6-para, aged 33 years at death on November 16, 1946

Previous history and onset of disease Before the onset of the illness in 1941 after her last delivery, she was a healthy vigorous woman, who took pride in her personal appearance and in her home Her first five deliveries were normal, and the babies were all breast-fed At the age of 28 years her sixth delivery was complicated by retained placenta with considerable post-partum haemorrhage. She was given rectal salines and finally recovered During the puerperium the breasts did not secrete or become painful There was occasional slight pyrexia for six days, but the lochia were normal

Subsequent course After this delivery she became a dirty unkempt sloven, neglecting her children and home so that only the help of the neighbours prevented the children from being left to starve She was mentally dull with frequent attacks of depression She felt the cold intensely and sat huddled beside the fire all day She had anorexia and, for a year or two, had some transient loss of weight She was always very pale There was permanent amenorrhoea, apart from slight haemorrhage on one day 11 months after the delivery The pubic and axillary hair gradually disappeared in the course of the next two years

Later stages In May 1946 she was admitted to hospital with a diagnosis of myxoedema, anaemia, and avitaminosis Blood examination showed haemoglobin 80 per cent , red cells 3,600,000 per c mm , and white cells 7,200 per c mm A fractional test meal showed only a trace of free hydrochloric acid at 1½ and 2 hours Under treatment with iron, liver extract, and thyroid extract, the haemoglobin rose to 97 per cent , with red cells 4,500,000, and white cells 9,400 per c mm On October 18 she developed pneumonia of the right middle lobe, with pyrexia lasting about a week During her convalescence it was noted that she was fairly well nourished and not prematurely aged Her skin was strikingly pale Her blood-pressure was 110/70, and fasting blood-sugar 81 mg per 100 c c The absence of pubic and axillary hair was first noticed clinically at this stage It was found that the genital tract was very atrophic, with a uterine cavity 5 cm in length Blood examination showed haemoglobin 60 per cent , red cells 4,100,000, and white cells 7,000 per c mm Convalescence was slow , the temperature and pulse remained normal, but she failed to regain her strength, and X-ray showed some opacity remaining in the right middle lobe

Final illness On November 13, as a result of a misunderstanding, she was given one dose of 8 units of soluble insulin subcutaneously During the following night she became stuporose, with twitching of facial muscles, but recovered

10 hours later, after the administration of 2 litres of 5 per cent glucose-saline intravenously On November 16 the stupor and twitching of facial muscles recurred and she lapsed into deep coma She was given intravenous glucose, but this time without effect, and she died in 18 hours

Pathological findings Height 58 in , slight build, normal nutrition (see Plate 34), subcutaneous fat over abdomen 2 5 cm thick, and over sternum 1 5 cm thick Marked pallor of all skin Weak facial features Head hair dark and normal in texture and amount. Eyebrows thin No axillary or pubic hair, only a few small hairs on the labia Considerable *erythema ab igne* over shins Teeth normal

The pituitary gland was very small and showed complete replacement of the anterior lobe by a loose and rather oedematous connective tissue Microscopically this had the usual appearance of condensed stroma, but was diffusely infiltrated by eosinophil leucocytes which were in places collected into denser foci Only very occasional pituitary cells were found, these formed tiny acini at the site of the original capsule, and probably represented only about 2 per cent of the original gland. They consisted chiefly of indeterminate chromophobe or slightly basophil cells with very occasional eosinophil cells The posterior lobe was normal

The thyroid was very atrophied and weighed 7 5 gm Only one parathyroid was found, but this appeared normal

The suprarenals were small, the left weighing 3 9 gm and the right 4 0 gm., with a thin cortex, measuring from 0 4 to 0 5 mm in depth There was much thickening of the fibrous capsule Apart from atrophy, most of the cortex was of fairly normal histological appearance and had a full content of lipoid, but the zona reticulata was replaced by a flat band of fibrous tissue, rather hyaline in places The medulla was large and contained no cortical cells

The pancreas weighed 35 gm , histologically it showed numerous islets, and these were of large size with the columns of cells separated by wide capillary spaces.

The uterus and appendages weighed 65 gm The uterus and cervix were small with very atrophic endometrium The vagina and vulva were very atrophied. The ovaries were of the size and shape of small almonds, though one had also a clear cyst, 1 cm in diameter, projecting from its surface Histologically there were 12 to 20 primordial follicles in the cortex of each section of a complete ovary, and occasional corpora fibrosa

The breast tissue consisted merely of atrophic small ducts without acini The spleen was small and the Malpighian bodies had no Flemming nodes The viscera in general were small, the heart weighed 165 gm , the liver 825 gm , and the kidneys 90 and 100 gm The right lung had extensive unresolved pneumonia in its upper lobe, with a smooth-walled gangrenous cavity 3 cm in diameter in the lower part of the lobe This cavity was almost filled by a large mass of necrotic lung There were organizing adhesions over the upper right pleura The only other significant pathological finding was a cystitis of moderate severity

Comment It is surprising that she survived the acute stage of a pneumonia and, after this, gangrene of lung These, however, appear to have set the stage for the coma which was precipitated by the insulin injection

R G , 3-para, aged 34 years at death on April 30, 1946

Previous history and onset of disease She was in apparently good health up to the birth of her third child in March 1940 Unfortunately the obstetric

records were destroyed during the war, and no information is now available about the delivery and puerperium, except that the baby was born alive

Subsequent course After the delivery she never returned to normal health She had amenorrhoea and complained of always feeling tired, particularly in the afternoons Her weight remained normal She had dyspnoea on exertion and was frequently treated for anaemia Other clinical details are lacking until December 1945 when she was admitted to hospital with a diagnosis of anaemia and mitral stenosis Intensive iron therapy raised her red cells from 2,800,000 up to 4,100,000 per c mm and her haemoglobin from 58 per cent up to 75 per cent The blood-urea was normal The electrocardiogram showed a biphasic T2 and T3

Later stages On March 28, 1946, she developed a slight cold, and within two or three days lost her appetite and became very lethargic Her pulse was regular but weak, and her blood-pressure 80/60 She was admitted to hospital, where it was noted that her skin was very white, her head hair dry and coarse, and her eyebrows deficient over the outer third There was some puffiness of the face, but no oedema elsewhere The teeth were all present, but there was extensive gingivitis A blood count showed haemoglobin 88 per cent , red cells 4,600,000 per c mm , and white cells 5,200 per c mm A differential count showed polymorphs 67, lymphocytes 28, monocytes 3 5, and eosinophils 1 5 per cent The plasma chlorine was 360 mg per 100 c c The cardiac condition appeared unchanged The pulse and temperature were normal A diagnosis of myxoedema was made and treatment with thyroid extract and vitamins instituted, but no improvement occurred At this point it was noticed incidentally that the patient had no pubic or axillary hair , this prompted a gynaecological examination which revealed very great atrophy of vulva, vagina, and uterus She was therefore given a course of oestrogenic hormone which continued to the time of death 18 days later

Final illness On April 26, in an attempt to improve her appetite, she was ordered 5 units of insulin subcutaneously twice a day After two days of this therapy she became very lethargic and slept most of the time On the third day she developed two epileptiform attacks followed by deep coma, which continued subsequently Some uterine haemorrhage occurred During the coma, a lumbar puncture was done, and examination of the cerebrospinal fluid showed chlorides of 680 mg and sugar of 14 mg per 100 c c After 14 hours in coma, she was given sugar by stomach tube, but died shortly afterwards

Pathological findings A small lightly built woman Nutrition normal (see Plate 34), subcutaneous fat over abdomen 3 cm thick and over sternum 2 cm thick Marked pallor of skin No progeria Head hair normal and brown in colour, outer halves of eyebrows very thin, no axillary or pubic hair, a few short hairs on the inner aspects of the labia Much *erythema ab igne* Teeth normal.

The pituitary stalk appeared normal, but the posterior lobe was flattened against the posterior wall of the sella, and the anterior lobe was represented to the naked eye by only a filmy reticulum of connective tissue Microscopically one very small islet of anterior pituitary tissue was found This was assessed at about 4 per cent of the original amount It lay directly in contact with the shrunken posterior lobe and consisted of cells without very clear differentiation into cell types The remainder of the anterior lobe consisted only of loose fibrillar connective tissue which appeared to be mainly the condensed remains of the original stroma

The thyroid was very atrophied and weighed 4 7 gm The acini were all very small, but contained colloid Slight focal lymphocytic infiltration was present

Only one parathyroid was examined, this was about twice the normal size It consisted mainly of chief cells, but there were a few isolated oxyphil cells

The suprarenals were small, left 3 5 gm, right 2 8 gm The fibrous capsule was very thick The cortex was white and full of lipoid, but was very thin, varying from 0 2 to 0 3 mm in depth The zona glomerulosa and zona fasciculata were miniatures of the normal, but the reticulata was represented only by a thin band of connective tissue forming a sharp boundary between cortex and medulla and containing a number of open capillaries The medulla was healthy and appeared very plentiful, it contained no cortical cells

The uterus had a thin muscle wall, but there was extensive haemorrhage on the inner surface and into the lumen, the uterus including blood clot weighed 125 gm Microscopically, practically no traces of endometrium could be found in the clot over the inner surface of the uterus The ovaries weighed 2 5 gm and 3 0 gm, the larger ovary containing a small fibrous-walled cyst and the smaller an old rather large corpus albicans, but no primordial follicles could be found

The pancreas was small, microscopically the islets were very numerous and large with the cell columns widely spaced from each other

The heart weighed 250 gm and showed considerable mitral stenosis and some tricuspid stenosis There was much brown induration of both lungs The liver weighed 1,030 gm and showed chronic venous congestion with some lobular regeneration, there was much fibrous thickening of portal tracts The gall-bladder contained 20 pigment stones, each about 5 mm diameter The kidneys were congested and weighed 110 gm and 130 gm, they showed slight fatty change in the spiral tubules There was much congestion and oedema of the bladder mucosa The aorta showed a peculiarly gelatinous atheroma

Comment Though there are no obstetric details, the clinical course and pathological findings suggest very strongly that she must have had severe haemorrhage or shock at the delivery It is of interest that she survived for three days after the institution of insulin therapy The endometrial haemorrhage was obviously due to the preceding administration of oestrin

F L, 4-para, aged 51 years at death on March 23, 1947

Previous history and onset of disease She was in excellent health until 1935 when her last child was born She 'had a bad time' at this delivery and was kept in hospital for four months afterwards, but no further details could be obtained

Subsequent course During the 12 years since the delivery she had had permanent amenorrhoea She was very sensitive to cold and spent all her time sitting beside the fire Her appetite was poor, but her weight remained about normal She always appeared very pale She was weak and listless and unable to do any housework She became filthy and verminous, and the children and household became a 'problem' family She was treated occasionally for anaemia and also for indigestion

Later stages In May 1946 she had an attack of severe vomiting which lasted for two days At the end of the second day she became almost comatose and was admitted to hospital, where she was at once given 1 2 litres of glucose-saline intravenously This caused rapid improvement, and her pulse, which had been very feeble, became much stronger, with a blood-pressure of 130/70 The vomiting ceased Her pulse-rate and temperature were normal The non-protein nitrogen at this time was 62 mg per 100 c c She was treated for three weeks as a case of chronic constipation and cholelithiasis, and then discharged

Final illness On March 19, 1947, she caught a severe cold On March 21 she became confused and had slurring speech She quickly lapsed into semi-coma

with very weak heart-sounds and a cold skin She was admitted to hospital with the clinical diagnosis of cerebral thrombosis, unfortunately, in view of this diagnosis, no glucose-saline was given She became gradually more deeply comatose and died within 24 hours

Pathological findings At autopsy the body was that of a small woman (57 in high) of normal nutrition (see Plate 34), the abdominal subcutaneous fat being 4 cm thick The skin was very white The head hair was normal, the eyebrows very thin and short, and the axillary and pubic hair absent, but a little hair was still present over the vulva *Erythema ab igne* was present on both shins

The pituitary was very small and consisted of a rather fibrotic posterior lobe with some loose connective tissue in front of it Histological examination revealed only very occasional tiny islets of anterior pituitary cells remaining at the edge of this connective tissue, possibly 2 or 3 per cent of the original gland The cells were weakly basophil and often very vacuolated

The thyroid was very small, about 5 gm , and dull red on section Microscopically the acini were very small, but contained normal colloid There were many areas of severer atrophy with lymphocytic infiltration

The suprarenals were both very small, weighing 1 05 gm and 1 2 gm The fibrous capsule was only slightly thickened The cortex varied from 0 3 to 0 4 mm in thickness It had a full content of lipoid The histological structure of the outer part was fairly normal, but the zona reticulata was replaced by a thin zone of flattened connective tissue In places there was a hyalinization of the inner half of the zona fasciculata extending outwards from the fibrous zone The medulla appeared of good quantity and contained no cortical cells

The uterus and ovaries were extremely small The spleen weighed 40 gm and its Malpighian bodies showed no germinal centres The other viscera were also very small, heart 165 gm , liver 750 gm There were no other significant pathological findings apart from slight old pleural adhesions

Comment The exact obstetric details are not available, but the remainder of the record is clearly indicative of a post-partum necrosis

T B , 3-para, aged 52 years at death on September 3, 1947

Previous history and onset of disease She was in good health until 1925 when, at her last delivery, she had severe post-partum haemorrhage and manual removal of the placenta No details of the puerperium are available

Subsequent course During the 21 years after the delivery she had complete amenorrhoea and absence of libido The pubic hair, which had been shaved at the time of delivery, never grew again, and the axillary hair disappeared within a few months She was very pale and her skin was dry Her eyebrows became thin She was very sensitive to cold She was dull and apathetic, neglected her housework, and stayed in bed much of the day She had a good appetite and steadily gained weight, so that she was a very fat woman by the spring of 1947 There was no evidence of progeria

Later stages In March and April 1947 she had generalized slight oedema which cleared up slowly, at the same time she gradually developed increasing drowsiness During May and June she had a series of attacks of severe vomiting, accompanied by much weight-loss She was admitted to hospital in June with a diagnosis of ? nephritis, ? myxoedema Cerebration was very slow Her face was rather puffy, but there was no oedema There was severe atrophy of the vulva, vagina, and uterus The vaginal secretion had pH 8 and there was no glycogen in the vaginal epithelium There was much dental caries and oral sepsis but most teeth were present The temperature, pulse, and urine were

normal The blood-pressure was 90/60 to 100/70 An electrocardiogram was normal A fractional test meal showed no free hydrochloric acid. The blood urea was 24 mg per 100 c c, and blood-cholesterol 88 mg per 100 c c A blood count showed haemoglobin 57 per cent, red cells 3,200,000 per c mm, and white cells 4,600 per c.mm The differential count gave polymorphs 55, lymphocytes 39, monocytes 4, and eosinophils 2 per cent. Urinary ketosteroids were 1 4 mg per 24 hours She was treated for a month with thyroid extract without effect The attacks of vomiting continued and there was a further loss of weight

Final illness On September 1 there was a severe vomiting attack with some vertigo The haemoglobin was 56 per cent and red cells 2,500,000 per c.mm The next day she was very drowsy On September 3 she had a convulsion and became comatose She was given adrenalin, but there was no improvement and she died in coma 12 hours later

Pathological findings Height 64½ in, weight 91 lb Poor nutrition (see Plate 34), particularly over thorax and arms, with atrophy of fat in breasts, subcutaneous fat over sternum slightly less than 1 cm thick Abdomen and thighs better covered, abdominal fat 2 cm thick Face very pale Head hair normal and dark in colour, eyebrows very thin, particularly over outer two-thirds No axillary hair, pubic hair represented by only about half a dozen short hairs on the labia No significant *erythema ab igne*

Macroscopically the anterior lobe of the pituitary was represented only by loose fibrous tissue The posterior lobe appeared shrunken, but the stalk was normal Microscopically there was one very tiny islet of chromophobe or weakly basophil cells in front of the attachment of the stalk to the gland, and representing about 2 per cent of the original parenchyma This islet of parenchyma was not fibrotic The remainder of the anterior lobe consisted only of partly hyalinized loose connective tissue fibres The posterior lobe showed some glial proliferation

The thyroid was small (10 gm) and pale in colour Microscopically the alveoli were of moderate size, but with very flat epithelium, the colloid was thin and did not stain with eosin Only one parathyroid was found It was large, and consisted of chief cells, many of which were in various stages of swelling up to very large clear cells, but there were no oxyphil cells

The adrenals were very small (2 54 gm and 2·55 gm) The capsule was very thick and fibrous and was thrown into folds by shrinkage of the gland The cortex was only 0 2 mm thick and was represented only by disorganized cell columns which were probably the remains of zona fasciculata There was very little lipoid, and pigment was absent There was a band of hyaline fibrous tissue between the cortex and medulla The medulla appeared normal

The pancreas weighed 55 gm The islets were histologically normal, but appeared to be much more numerous than is usual

The uterus was very atrophied, measuring 5 cm from external os to peritoneal surface of fundus The myometrium was 3 5 to 4 0 mm in thickness and consisted mainly of closely packed, large, coiled arteries The endometrium was 0 7 mm thick and histologically consisted of a dense mass of plasma cells and lymphocytes with numerous congested capillaries This was covered by a thin layer of squamous epithelium with a very minute remnant of an endometrial gland every 1 to 2 mm along the section

The vagina was very atrophic Its mucosa showed the same chronic inflammatory infiltration as the endometrium The ovaries were very small.

The other organs showed little apart from a general splanchonomicria Heart 200 gm with very thin muscle-fibres Liver 880 gm with some old local scars of uncertain origin Kidneys 85 gm and 85 gm, with microscopically very

prominent juxta-glomerular complexes Lungs 630 gm and 490 gm , with considerable oedema of lower lobes and microscopically a very early bronchopneumonia Spleen (200 gm) and abdominal lymphnodes rather large, the Malpighian bodies and lymph follicles did not show any Flemming's nodes The aorta showed moderate atheroma which histologically had a peculiarly homogeneous and structureless appearance There was one large gall-stone consisting almost entirely of pigment The great omentum contained a considerable amount of fat No thymus tissue could be recognized even on histological examination

Comment There was clearly a post-partum necrosis 21 years before death There was a slow increase of weight until the last six months, when severe vomiting produced much weight loss

Indeterminate Scarring of Anterior Lobe

The following patient showed pathological changes similar to those seen in post-partum necrosis, but the aetiology of the destruction is quite uncertain The lesion is classed as 'severe', but appears to be towards the lower range of that group

G N , 6-para, aged 77 years at death on October 23, 1947

Previous history Her children were born when she was 21 to 27 years old No information is now available about the last delivery, which occurred in 1897

Subsequent course She had no further pregnancies after the age of 27 years There do not appear to have been any non-medical causes for her subsequent sterility, but details of her menstrual history could not be obtained From the year 1940 onwards she spent much of her time sitting beside the fire, she was always very pale and was treated for anaemia on several occasions She did part of her own housework and occasionally went out of doors, usually she was quiet and reserved and did not appear to be seriously ill. Her weight remained unchanged From the autumn of 1946 she had headaches, giddiness, and dyspnoea on exertion. She appeared very anaemic, with skin of a light lemon-yellow colour She had developed some tingling, pain, and weakness in the legs

Later stages Early in October 1947 she had diarrhoea, epigastric pain, and vomiting She was admitted to hospital, where a blood examination showed red cells 1,700,000 per c mm , white cells 3,400 per c mm , haemoglobin 41 per cent , and mean corpuscular volume 108 cu microns She had some oedema of the legs The blood-pressure was 150/60, pulse 64, and temperature normal After seven days' treatment with liver extract and iron, she had a reticulocyte response to 8 per cent , and after four weeks a blood count showed red cells 2,100,000 per c mm and haemoglobin 48 per cent

Final illness On October 22 she developed aphasia and a right-sided hemiplegia She died in coma next day The clinical diagnosis of cerebral thrombosis was confirmed pathologically

Pathological findings Height 60 in Nutrition normal (see Plate 35, the sternum and many of the viscera had not been replaced in the body) Subcutaneous fat over abdomen 3 cm thick Skin of face slightly yellow, but quite smooth Skin over thighs and breasts showed some senile atrophy, but was not scaly Head hair white and of normal thickness for her age Eyebrows normal, no axillary, pubic, or vulvar hair No *erythema ab igne*

The pituitary showed a normal posterior lobe, but the anterior lobe was very

small and to the naked eye appeared to be replaced by fibrous tissue Microscopically a small area of parenchyma, about 5 per cent of the normal, was found in front of the posterior lobe This was not fibrotic The cells were chiefly large eosinophils, but a few of both other types were present In front of this islet there was loose fibrous tissue, partly hyaline The general appearances were the same as those seen in patients with healed *post-partum necrosis*

The thyroid weighed 9 8 gm and was rather brown in colour Histologically it consisted of moderately small acini, full of colloid

The suprarenals were very small, weighing 2 6 and 2 7 gm The fibrous capsule was only slightly thickened The cortex was thin, averaging 0 4 mm in depth The cortical pattern was normal and there was no fibrosis between cortex and medulla

The uterus weighed 25 gm and was very atrophied The endometrium was of advanced senile type, it consisted of a single row of small cysts under a flat epithelium The ovaries were very small and weighed 1 0 gm each They showed rather numerous old corpora albicantia

The pancreas was normal to the naked eye, but was not examined microscopically The other viscera were very small, the kidneys weighed 70 gm each There was one large gall-stone, mainly consisting of pigment and about the size of a damson There was thrombosis of the left middle cerebral artery with recent softening of the corpus striatum on that side

Healed Granuloma

These two cases are examples of healed giant cell granuloma of the anterior pituitary which had practically reached the stage of an empty sella Neither could be regarded as more than 'moderate', the first of them appears to have suffered the greater degree of damage

W L, nullipara, aged 69 years at death on December 4, 1947

Previous history She was married at about 30 years, but had had no children Her menstrual history was unknown, and no details could be obtained about her earlier health except that she had had no medical attention for many years

Clinical course Her husband died in 1945, and since then she had lived in hotels Here she was reputed to be the epitome of selfishness and laziness She spent most of her time sitting close in front of the fire and refused to move, even to allow other guests to get warm From September 1947 she stayed in bed most of the day and was extremely sulky and unco-operative

Final illness On December 1, 1947, she was very dull and her speech was thick On December 2 she became stuporose and fell when she tried to get out of bed She became semi-comatose on December 3 and was admitted to hospital that morning Here she was found to have a vacant stare, generalized spasticity of muscles, slight neck rigidity, and loss of all deep reflexes The radial pulse could scarcely be felt, but a blood-pressure reading of 110/60 was obtained. Her temperature was 96° F, and her skin and extremities were very cold Respiration was very quiet The bladder was distended and catheterization was required The urine contained a trace of albumen, but no acetone She was noted to be obese, the skin was dry and very pale with a light lemon-yellow tinge, the nipples and areolae were very pale

By the evening she was deeply comatose and the heart-rate had fallen to 30 per minute She was given 0 6 c c of Liq adrenalin hydrochloride subcutaneously About an hour later the blood-sugar was 100 mg per 100 c c, blood urea 120 mg per 100 c c, and leucocyte count 3 400 per c mm The diagnosis

was considered to lie between cerebral thrombosis, uraemia, heart-block, and poisoning by some hypnotic drug On December 4 the coma became steadily deeper, the heart-sounds inaudible, and the temperature lower Death occurred at 10 a m

Pathological findings At post-mortem examination, the height was 61 in and the body was very well nourished (see Plate 35) The subcutaneous fat was 6 cm thick over the abdomen and 1 5 cm thick over the sternum The skin was white There was no pubic or axillary hair and the eyebrows were very thin The breast contours were normal

On macroscopic examination the sella appeared to be empty, but histologically the floor of the sella was found to consist of a very flat layer of anterior pituitary tissue sandwiched between two thin layers of loose fibrous tissue. The posterior lobe lay at the back, slightly flattened but otherwise normal The amount of remaining anterior pituitary parenchyma was estimated, from its thickness and area, to be about 10 to 15 per cent of normal It was partly broken up by loose fibrous tissue and consisted chiefly of eosinophil cells, with a few chromophobes and basophils Scattered partly in the parenchyma, but particularly in the fibrous tissue on either surface, there was a heavy and extensive lymphocytic infiltration, and also various stages of 'giant cell granuloma' For convenience the appearances of the 'granulomatous' process may be described as four distinct pictures, but there are all grades of intermediate stages

(*a*) Areas, about 200 to 300 microns in diameter, in which there are very loosely arranged polygonal or elongated cells with irregular outline and an eosinophil cytoplasm. They have some resemblance to histiocytes in a chronic inflammatory focus, or to the endothelioid cells in a tubercle, but it is possible to find a tempting series of steps between them and single pituitary parenchyma cells which lie isolated in the neighbouring loose fibrous tissue Many lymphocytes are present, scattered through the foci and also collected around their periphery

(*b*) Similar areas in which certain of these cells are aggregated into small groups of three to five, forming ill-defined giant cells

(*c*) Areas with two to four large giant cells which are about 20 microns diameter These resemble the giant cells of tuberculosis, and have about 20 nuclei arranged peripherally, a homogeneous central cytoplasm, and a blurred edge There is a considerable infiltration of lymphocytes around them, but only a few of the small cells which characterized the areas described in (*a*)

(*d*) Similar areas in which the giant cells have increased to 60 or 90 microns in diameter The nuclei are correspondingly numerous The central cytoplasm passes through a phase of foaminess, then of very gross vacuolation, and finally becomes a clear space, which sometimes contains large basophil fibrillar inclusions with a superficial resemblance to the rolled squames of a vernix pneumonia

The interpretation of these appearances is uncertain, in particular it is not clear whether they are stages of a process passing from (*a*) to (*d*), or from (*a*) to (*d*) and back again to (*a*) Furthermore, no conclusion can be reached as to whether the small cells are histiocytic or are derived from pituitary parenchyma The condition is, however, not in any way suggestive of tuberculosis or syphilis

The thyroid weighed 65 gm It showed a large colloid adenoma of the left lobe, but the rest of the gland was not significantly atrophied, either naked-eye or microscopically

The adrenals weighed 1 6 and 2 4 gm The cortex was very thin, but the medulla appeared normal

The uterus was very small, measuring only 4 cm from the top of the fundus to the external os It had two small intramural fibroids The myometrium appeared to consist chiefly of closely packed nuclei with very little remaining cytoplasm The endometrium had a single layer of cuboidal epithelium with very occasional tiny remnants of glands The cervix was very atrophied, and the ovaries were about the size of almonds.

The heart weighed 250 gm and appeared normal apart from coronary atheroma The liver weighed 930 gm There was one large and one small gallstone The kidneys weighed 100 gm each, and the spleen 80 gm There was extensive atheroma in the abdominal aorta and in the cerebral arteries, but the brain was normal A moderate degree of diverticulosis was present in the pelvic colon.

Comment. The continuance of the thyroid adenoma despite a considerable degree of hypopituitarism is of interest There is no evidence as to the date of origin or the rate of growth of the adenoma

P L , a parous woman, aged 62 years at death on May 7, 1948

Previous history Apart from the fact that she had partial blindness due to old corneal opacities, no details of her earlier condition were obtained

Clinical course Since August 1947 she had suffered from anorexia and a series of severe attacks of vomiting There was some loss of weight and much asthenia In February 1948 she developed alternating constipation and diarrhoea, and also frequency of micturition A tentative diagnosis of carcinoma of the colon was made, and she was admitted to hospital on March 5 Here she was noted to be well nourished, but to show signs of recent weight-loss Her face was very white and her breast areolae were not pigmented Her head hair was normal, but her eyebrows were thin and she had no pubic or axillary hair The uterus could not be palpated, and the vulva and vagina were very atrophic Cystoscopy revealed much chronic cystitis The blood-pressure was 110/85, the pulse and temperature were normal A blood count showed red cells 4,500,000 per c mm and haemoglobin 77 per cent On March 8 she became drowsy, and uraemia was suspected, but the blood-urea was only 42 mg per 100 c c Intravenous glucose-saline produced clinical recovery A further episode of drowsiness occurred on March 23 and 24, but she recovered spontaneously

Final illness On April 22 she developed nausea and anorexia and within two days had become very drowsy again This state progressed into coma on April 27 She was given glucose-saline by intravenous drip Some hours later her blood-sugar was 118 mg and non-protein nitrogen 26 mg per 100 c c but there was no change in the coma The cerebrospinal fluid had a chloride content of only 620 mg per 100 c c but was otherwise normal The coma continued unchanged, pyrexia began on May 2 and she died with symptoms suggesting hypostatic pneumonia on May 7

Pathological findings The body was of normal nutrition, the subcutaneous fat was 2 5 cm thick over the abdomen and 1 cm over the sternum The skin was very white The eyebrows were very thin, there was no axillary or pubic hair The breasts were of normal size

The sella appeared to be empty apart from the pituitary stalk and the posterior lobe attached to the wall behind Histological examination of these and of the dura forming the floor of the sella showed that the posterior lobe and stalk, including the pars tuberalis, were normal The anterior lobe was represented by a flat layer of loose fibrous tissue along the floor of the sella About the centre of this fibrous tissue there was a thin lamina of anterior pituitary

tissue, consisting mainly of eosinophil cells These were arranged usually in acini, but sometimes as isolated cells in the connective tissue Allowing for the area it occupied, the layer of remaining anterior pituitary parenchyma was estimated to be about 15 per cent of the original amount There was a fairly heavy diffuse sprinkling of lymphocytes throughout the fibrous tissue and in a few places, usually near the original fibrous capsule, there were areas of 'giant cell granuloma' These areas were mostly in the stage described as (c) in the record of the previous case

The thyroid was small (12 gm), its alveoli were uniformly small and contained pale-staining colloid

The suprarenals were small, but their cortex was 0 8 mm thick and showed no histological abnormality, there was no fibrosis of the capsule or zona reticulata

The uterus and appendages weighed 78 gm The endometrium showed senile atrophy, but had a fair number of glands, in contrast to the appearances seen in severe hypopituitarism The ovary was of senile type with a few microscopic cysts

The heart was small (200 gm), but the other viscera were not atrophic, liver 1,600 gm , kidneys 140 and 150 gm There was slight atheroma of the aorta The bronchi contained much muco-pus No other pathological lesions were found

Comment There is no evidence to indicate when the pituitary lesion originated The hypopituitarism was incomplete in various respects

Empty Sella

In this case the damage to the pituitary appears to have been of only minor degree and thus had not led to any clinical symptoms of hypopituitarism The pituitary lesion was only an incidental finding at autopsy, and no evidence could be found, either naked-eye or microscopically, to account for the condition The case is recorded only as an example of the particular pathological lesion

M G , a multiparous woman, aged 63 years at death on May 2, 1948

Previous history Chronic bronchitis since 1917, otherwise nothing of note

Present illness The entire course of the illness was that of a myelosclerosis with megakaryocytic splenomegaly, and there were no symptoms related to the pituitary From January 1947 she had anaemia (haemoglobin 45 per cent , red cells 2,500,000 per c mm , and white cells 2,800 to 4,100 per c mm with a normal differential count), oedema, and gross ascites Numerous paracenteses were required and, finally, the large spleen (2,200 gm) was removed She died four days later of post-operative broncho-pneumonia

Pathological findings Body thin, with subcutaneous fat 1 to 1 5 cm thick over abdomen and about 0 5 cm thick over sternum Skin dark coloured, particularly on face Head hair and eyebrows normal, no axillary hair, normal pubic hair

The sella was larger than normal and, on preliminary inspection, appeared to be quite empty Detailed examination showed that the pituitary stalk was attached to a flattened posterior lobe at the back of the sella and that the fibrous tissue forming the floor of the sella enclosed a layer of anterior pituitary tissue about 0 5 mm thick This parenchyma had a fairly large area, so that it probably represented a third or more of the original gland It was very congested, but was not fibrotic It showed all three types of cell in their usual

The uterus was very small, measuring only 4 cm from the top of the fundus to the external os It had two small intramural fibroids The myometrium appeared to consist chiefly of closely packed nuclei with very little remaining cytoplasm The endometrium had a single layer of cuboidal epithelium with very occasional tiny remnants of glands The cervix was very atrophied, and the ovaries were about the size of almonds

The heart weighed 250 gm and appeared normal apart from coronary atheroma The liver weighed 930 gm There was one large and one small gallstone The kidneys weighed 100 gm each, and the spleen 80 gm There was extensive atheroma in the abdominal aorta and in the cerebral arteries, but the brain was normal A moderate degree of diverticulosis was present in the pelvic colon.

Comment. The continuance of the thyroid adenoma despite a considerable degree of hypopituitarism is of interest There is no evidence as to the date of origin or the rate of growth of the adenoma

P.L , a parous woman, aged 62 years at death on May 7, 1948

Previous history Apart from the fact that she had partial blindness due to old corneal opacities, no details of her earlier condition were obtained

Clinical course Since August 1947 she had suffered from anorexia and a series of severe attacks of vomiting There was some loss of weight and much asthenia In February 1948 she developed alternating constipation and diarrhoea, and also frequency of micturition A tentative diagnosis of carcinoma of the colon was made, and she was admitted to hospital on March 5 Here she was noted to be well nourished, but to show signs of recent weight-loss Her face was very white and her breast areolae were not pigmented Her head hair was normal, but her eyebrows were thin and she had no pubic or axillary hair The uterus could not be palpated, and the vulva and vagina were very atrophic Cystoscopy revealed much chronic cystitis The blood-pressure was 110/85, the pulse and temperature were normal A blood count showed red cells 4,500,000 per c mm and haemoglobin 77 per cent On March 8 she became drowsy, and uraemia was suspected, but the blood-urea was only 42 mg per 100 c c Intravenous glucose-saline produced clinical recovery A further episode of drowsiness occurred on March 23 and 24, but she recovered spontaneously

Final illness On April 22 she developed nausea and anorexia and within two days had become very drowsy again This state progressed into coma on April 27 She was given glucose-saline by intravenous drip Some hours later her blood-sugar was 118 mg and non-protein nitrogen 26 mg per 100 c c but there was no change in the coma The cerebrospinal fluid had a chloride content of only 620 mg per 100 c c but was otherwise normal The coma continued unchanged, pyrexia began on May 2 and she died with symptoms suggesting hypostatic pneumonia on May 7

Pathological findings The body was of normal nutrition, the subcutaneous fat was 2 5 cm thick over the abdomen and 1 cm over the sternum The skin was very white The eyebrows were very thin, there was no axillary or pubic hair The breasts were of normal size

The sella appeared to be empty apart from the pituitary stalk and the posterior lobe attached to the wall behind Histological examination of these and of the dura forming the floor of the sella showed that the posterior lobe and stalk, including the pars tuberalis, were normal The anterior lobe was represented by a flat layer of loose fibrous tissue along the floor of the sella About the centre of this fibrous tissue there was a thin lamina of anterior pituitary

There was a sharply defined calcified tumour, about 3 cm. in diameter, in the midline in the hypothalamic region It occupied the region from the optic chiasma back to the pons, reached upwards to about the centre of the third ventricle, and projected downwards to fill the sella, though without producing any expansion of this structure Histologically the tumour was a craniopharyngioma, its general structure was a cancellous osteoma with, in places, a transition to fibrous tissue of a peculiarly slotted appearance as if it had contained crystals

The pituitary was compressed to a small plaque on the floor of the sella The anterior lobe parenchyma was not fibrotic and showed all three types of cell in the usual proportions It was estimated to be about 20 or 25 per cent of the normal amount

The thyroid was very small, weighing only 7 gm Most of the acini were small, but a few were of medium size There was very little colloid, a few of the larger acini contained a little watery eosinophil colloid which had flowed to one side after death, and a few contained a little basophil colloid

The left suprarenal was small, its cortex was 0 8 mm thick and there was a band of fibrosis between cortex and medulla, but the capsule was not thickened The right suprarenal showed some patches of haemorrhagic necrosis in the cortex, apparently three or four days old

The testes were very small and soft, and were flattened to a disk shape Their tubules were almost occluded by an enormous hyaline thickening of the basement membrane Most of the tubules had no epithelium, but a few were lined by a single layer of vacuolated epithelium The tubules were separated by loose connective tissue in which there were no interstitial cells The epididymis consisted of flattened tubules with a good epithelial lining The prostate was scarcely 1 cm in diameter, so that it was found only on careful dissection, histologically it showed great atrophy of the glands and muscle

The other viscera were small, particularly the heart, liver, and kidneys, but were otherwise normal The lungs showed a very extensive terminal bronchopneumonia

Comment The craniopharyngioma appears to have enlarged very slowly, and to have produced no symptoms before the age of 29 years It had replaced all the hypothalamic region of the brain, and the question arises of how much of the apparent hypopituitarism may have been really secondary to this hypothalamic pressure

B L , male, aged 68 years at death on May 17, 1946

Clinical history He had had symptoms of a duodenal ulcer in 1943 and some cardiac symptoms since early 1945 There was no evidence of hypopituitarism He collapsed suddenly in the street and died in a few minutes

Pathological findings A big well-built man of good nutrition Hair distribution normal

Lying in the front half of the sella and projecting slightly upwards from it, there was a spherical yellowish mass 1 0 cm in diameter The anterior lobe of the pituitary showed compression atrophy to a wedge-shaped area in front of the lower half of the posterior lobe The remaining parenchyma was about one-third of the original amount and consisted of eosinophil and large basophil cells in approximately equal numbers, with remarkably few chromophobe cells There was no fibrosis The mass in front of the gland was made up of a thin fibrous coat enclosing a large centre of solid homogeneous yellowish material Histologically this material consisted basically of an acellular and rather

proportions, but the eosinophil cells were very large and rather hyaline It was well demarcated from the overlying dura, which was histologically normal and was presumably formed from the original diaphragma sellae The posterior lobe showed some patchy infiltration with lymphocytes and eosinophil leucocytes

The thyroid weighed 31 gm and showed alveoli of normal size and with normal content of colloid.

The suprarenals were of normal size, with cortex 1 0 to 1 5 mm deep There was no fibrosis of the capsule or of the zona reticulata, but there was much round celled infiltration in patches near the medulla The uterus and ovaries were of the usual post-menopausal appearance The endometrium was thin and showed dilated glands, the ovaries showed many old corpora albicantia

There was no splanchnomicria, the heart weighed 410 gm, the liver 2,900 gm, and the kidneys 200 gm and 200 gm

The other pathological changes were gross myeloid infiltration with numerous megakaryocytes in the excised spleen, thrombosis of the remainder of the splenic vein, myelosclerosis with marrow hyperplasia in the bones examined, centrilobular necrosis of the liver of a few day's duration, and some terminal broncho-pneumonia

Cysts and Tumours

The following two cases are included only as pathological examples of pressure atrophy of the pituitary by craniopharyngioma or cysts The first was an extrasellar tumour producing a moderate degree of pituitary damage, the second was an intrasellar cholesterol cyst producing only minor pituitary damage

A T, male, aged 64 years at death on March 8, 1947

Previous history He had married at 27 years, and became the father of a child at the age of 29 years

Clinical course From the age of 29 years he was impotent and gradually developed symptoms suggesting myxoedema, he never sweated, he became anaemic, and he lost his axillary hair and most of his pubic hair After the age of 46 years he had occasional treatment with thyroid extract, which seemed to improve his general condition, and he was also given a variety of liver preparations, but without much effect on the anaemia He was able to continue his occupation as a clerk

Final illness On February 20, 1947, he developed severe vertigo When examined, he was wearing four jerseys and three coats and complained of extreme sensitivity to cold His speech was very slow and hesitating The blood-pressure was 115/75 and pulse-rate slow On March 1, when he was next seen, he was stuporose and had dysphagia and a paresis of the left external rectus muscle The next day he became semiconscious with generalized rigidity Retinal examination showed some optic atrophy, the cerebrospinal fluid was normal and not under increased pressure The blood-urea was 56 mg per 100 c c The blood-pressure was 120/85, pulse 58, and temperature 97 He remained unconscious thereafter, with pulse 60, and temperature 97° to 97 4° F On March 7 he became deeply comatose and died next day

Pathological findings A large well-built man, of good nutrition (see Plate 35) with quite thick subcutaneous fat The skin had a creamy-white colour Head hair dark grey, eyebrows scanty over outer half, scanty moustache, very slight growth of beard at sides of chin, although he had not shaved for about two weeks before death No axillary or pubic hair

(c) All the patients had become very sensitive to cold and had stopped sweating All except one sat by the fire most of the day so that they had well-marked *erythema ab igne* This was red and non-pigmented One of the patients had a fairly typical myxoedematous facies and two others had an appearance suggesting hypothyroidism In fact, five of them had been at one time or other diagnosed and treated as cases of myxoedema without any improvement in the symptoms, and two had been diagnosed as suffering from nephritis The head hair was normal in amount and texture in all patients and was never grey, the eyebrows were very much thinned in eight, and moderately thinned in the other patient The skin was always dry and, in two patients, there was very slight scaliness over the arms and legs The thyroid could not be palpated in any of the patients

TABLE V

Clinical Cases of Post-partum Necrosis General data

Name	Age	Duration (yrs)	Height (in)	Weight (lb)	Blood chemistry (mg per 100 c c) Sod	Chlor	Cholest	Red cells (millions per c mm)	Haemoglobin (per cent)
P M	37	6	65½	123	300	355		3 2	72
S M.	34	8	59	135					
M Y	43	8	59½	116	306	345	160	4 7	96
R B	43	9	60	112	330		325	3 8	86
D V	47	11	57	107	334	336	348	4 6	86
B S	35	12	63	143			448	5 1	91
A.M	38	15	60	118	295	286	360	3 7	74
A.G	49	17	58	107	264	370	261	2 8	62
D L	50	21	62	129	285	312	240	4 2	80

(d) All the patients complained of being very weak, becoming tired on slight exertion, and being unable to do their housework In one patient, however, this asthenia did not develop until 11 years after the significant delivery All were dull, quiet, and apathetic

(e) All of the patients became very pale Seven of them had been treated for hypochromic anaemia, and four of these, when they failed to respond to iron, as cases of pernicious anaemia On examination, all had the typically white skin of face and body, with a complete absence of pigmentation of breast areolae and no linea nigra

(f) Four of the patients reported that their weight had not changed since the delivery Two lost a considerable amount of weight during prolonged puerperal convalescence, but gradually returned to normal during the next two years Three of the patients increased in weight by about 14 lb during the two or three years after the delivery One patient was given vigorous thyroid treatment and lost 28 lb in the course of three months, but regained this when treatment was stopped Photographs of the patients are shown on Plates 35, 36, and 37 (some of these photographs were taken on chromatic negatives so that the colour rendering is untrue, particularly the false appearance of pigmentation on faces).

(g) The facial appearance of all the patients was consistent with their stated age, there was no unusual wrinkling or evidence of progeria They all had dull,

hyaline material with slight concentric lamellation Scattered throughout, there were numerous large cholesterol clefts, with sometimes a few fibroblasts and monocytes in the region of these clefts Towards the periphery this essentially dead centre merged gradually into the fibrous capsule which contained some small capillaries, numerous tiny areas of calcification, and occasional foreign-body giant cells

The thyroid and adrenals appeared of normal size and healthy

The other pathological findings were a hypertrophied heart (600 gm) with old and recent infarcts due to coronary atheroma, some hypertensive change in the renal arterioles, and a small duodenal ulcer

Comments This cholesterol cyst was only an incidental post-mortem finding and had no clinical effects It is included only as a pathological example of a lesion which, if large, can lead to significant pressure on the pituitary

Clinical Cases of Post-partum Necrosis

The following nine cases, which have been studied in the past two years, are described as a group They are clinical cases with typical obstetric histories, but they lack pathological verification The clinical course in all of them is characteristic of severe pituitary damage, as judged from the syndrome seen in proved cases

Previous history and onset of illness These patients had been in normal health before the last delivery and appear to have been careful and competent housewives They all had clear histories of very severe circulatory collapse at the last delivery This collapse had nearly always been treated by transfusion of blood or saline, and the patients were unconscious for some hours at the time The causes of the collapse were—severe third stage or post-partum haemorrhage in six, section with severe haemorrhage in one, severe ante-partum haemorrhage in one, and post-partum shock after eclampsia in the remaining patient During the puerperium the breasts never became hard or knotty, but shrank to the non-pregnant condition in the course of two or three days, there was never any lactation One patient had puerperal sepsis and two had a very slow convalescence

Subsequent course (*a*) After the delivery all the patients had permanent amenorrhoea, but none developed any menopausal symptoms Libido was lost in all On examination, the genital organs always showed the same condition The vulva and vagina were very atrophic, the vaginal mucosa had no glycogen, and the scanty vaginal secretion had a pH of 7 to 8, the cervix was represented only by a dimple, the uterus and appendages were too small to palpate Investigation of the uterus by sound or curette was not made The breasts were of normal shape and consistency

(*b*) The pubic and axillary hair disappeared gradually in the course of a few months to about two years On examination there was never any hair in the axillae or on the pubis, but all the patients had very scanty hair on the inner side of the labia majora The axillary skin was smooth, dry, and lacking the normal greasiness

(c) All the patients had become very sensitive to cold and had stopped sweating All except one sat by the fire most of the day so that they had well-marked *erythema ab igne* This was red and non-pigmented One of the patients had a fairly typical myxoedematous facies and two others had an appearance suggesting hypothyroidism In fact, five of them had been at one time or other diagnosed and treated as cases of myxoedema without any improvement in the symptoms, and two had been diagnosed as suffering from nephritis The head hair was normal in amount and texture in all patients and was never grey, the eyebrows were very much thinned in eight, and moderately thinned in the other patient The skin was always dry and, in two patients, there was very slight scaliness over the arms and legs The thyroid could not be palpated in any of the patients

TABLE V

Clinical Cases of Post-partum Necrosis General data

Name	Age	Duration (yrs)	Height (in)	Weight (lb)	Blood chemistry (mg per 100 c c) Sod	Chlor	Cholest	Red cells (millions per c mm)	Haemoglobin (per cent)
P M	37	6	65½	123	300	355		3 2	72
S M	34	8	59	135					
M Y	43	8	59½	116	306	345	160	4 7	96
R B	43	9	60	112	330		325	3 8	86
D V	47	11	57	107	334	336	348	4 6	86
B S	35	12	63	143			448	5 1	91
A.M	38	15	60	118	295	286	360	3 7	74
A.G	49	17	58	107	264	370	261	2 8	62
D.L	50	21	62	129	285	312	240	4 2	80

(d) All the patients complained of being very weak, becoming tired on slight exertion, and being unable to do their housework In one patient, however, this asthenia did not develop until 11 years after the significant delivery All were dull, quiet, and apathetic

(e) All of the patients became very pale Seven of them had been treated for hypochromic anaemia, and four of these, when they failed to respond to iron, as cases of pernicious anaemia On examination, all had the typically white skin of face and body, with a complete absence of pigmentation of breast areolae and no linea nigra

(f) Four of the patients reported that their weight had not changed since the delivery Two lost a considerable amount of weight during prolonged puerperal convalescence, but gradually returned to normal during the next two years. Three of the patients increased in weight by about 14 lb during the two or three years after the delivery One patient was given vigorous thyroid treatment and lost 28 lb in the course of three months, but regained this when treatment was stopped Photographs of the patients are shown on Plates 35, 36, and 37 (some of these photographs were taken on chromatic negatives so that the colour rendering is untrue, particularly the false appearance of pigmentation on faces).

(g) The facial appearance of all the patients was consistent with their stated age, there was no unusual wrinkling or evidence of progeria They all had dull,

expressionless faces and soft, quiet, slow voices The dental condition was a fair sample of that in women in this age group

(*h*) Three of the patients had had attacks of coma and two others had been stuporose In three of these, recovery was spontaneous, but, in the other two, intravenous glucose was required

(*i*) Certain clinical and pathological data are given in Tables V and VI It will be noted that most of these patients were below average height, this may or may not be of significance

TABLE VI

Clinical Cases of Post-partum Necrosis Blood-sugars (mg per 100 c c) in insulin tolerance tests

(Patient S M received 0 1 units per kg)

Minutes after 0 03 units of insulin per kg intravenously

Name	*0*	*10*	*20*	*30*	*45*	*60*	*90*	*120*
P.M	74		50	44	39	45	45	47
S M	70		32	20				
M Y								
R B	62	..	62	47	52	54	45	46
D V		.						
B S	62	.	44	32	26	27		
A.M	90	60	55	50	45			
A G	107	96	68	50	44	51	70	70
D L	71	65	45	41	50	45	50	55

(*j*) Various other examinations were carried out, the more important findings were as follows The pulse-rate was usually 65 to 80 The blood-pressure ranged from 100/70 to 155/100 Electrocardiograms showed low voltages in three patients, negative T2 and T3 in one, and left axis deviation in the fifth patient examined Estimations of 17-ketosteroid excretion were made in eight patients, one had 0 7 mg per 24 hours, the others gave zero readings The basal metabolic rate was measured in four patients with readings of —30, —38, —47, and —59 per cent The leucocyte count ranged from 5,400 to 7,200 per c mm

Case C L

Case R G

Case F L

Case T B

expressionless faces and soft, quiet, slow voices. The dental condition was a fair sample of that in women in this age group

(*h*) Three of the patients had had attacks of coma and two others had been stuporose. In three of these, recovery was spontaneous, but, in the other two, intravenous glucose was required

(*i*) Certain clinical and pathological data are given in Tables V and VI It will be noted that most of these patients were below average height, this may or may not be of significance

TABLE VI

Clinical Cases of Post-partum Necrosis Blood-sugars (mg per 100 c c) in insulin tolerance tests

(Patient S M received 0 1 units per kg)

Minutes after 0 03 units of insulin per kg intravenously

Name	*0*	*10*	*20*	*30*	*45*	*60*	*90*	*120*
P M	74		59	44	39	45	45	47
S.M	70		32	20				
M Y								
R B	92		62	47	52	54	45	46
D V								
B.S	62		44	32	26	27		
A M	90	60	55	50	45			
A G	107	96	68	50	44	51	70	70
D L	71	65	45	41	50	45	50	55

(*j*) Various other examinations were carried out, the more important findings were as follows The pulse-rate was usually 65 to 80 The blood-pressure ranged from 100/70 to 155/100 Electrocardiograms showed low voltages in three patients, negative T2 and T3 in one, and left axis deviation in the fifth patient examined Estimations of 17-ketosteroid excretion were made in eight patients, one had 0 7 mg per 24 hours, the others gave zero readings The basal metabolic rate was measured in four patients with readings of —30, —38, —47, and —59 per cent The leucocyte count ranged from 5,400 to 7,200 per c mm

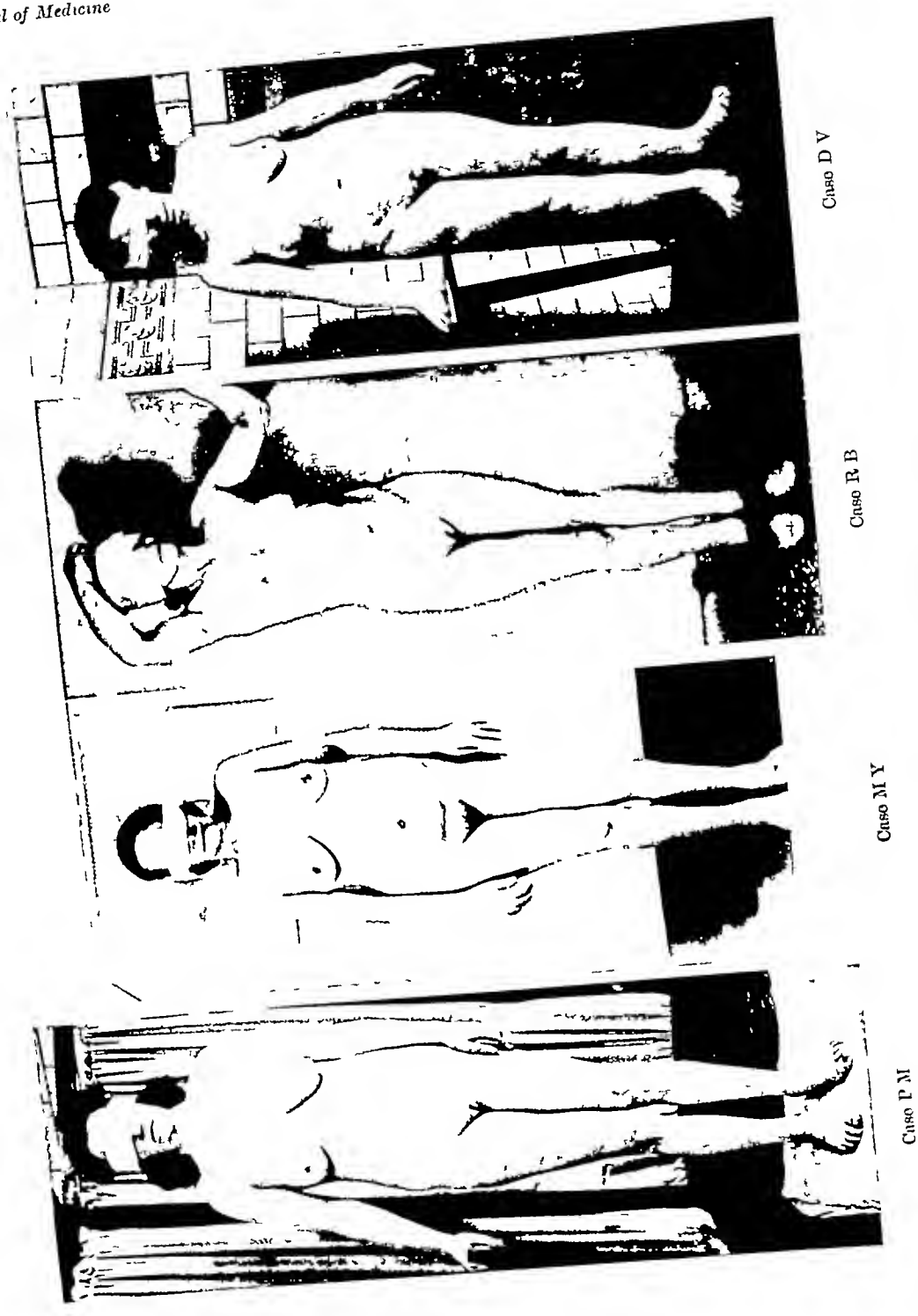

Case D V

Case R B

Case M Y

Case P M

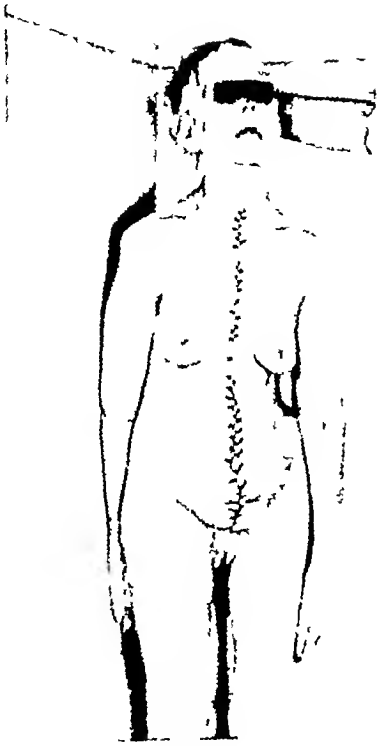

Case G N

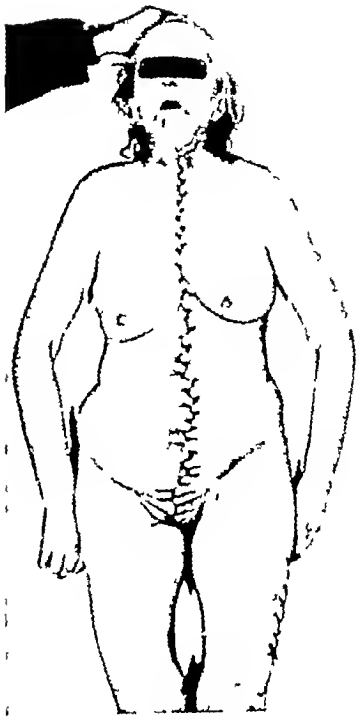

Case W L

Case S M

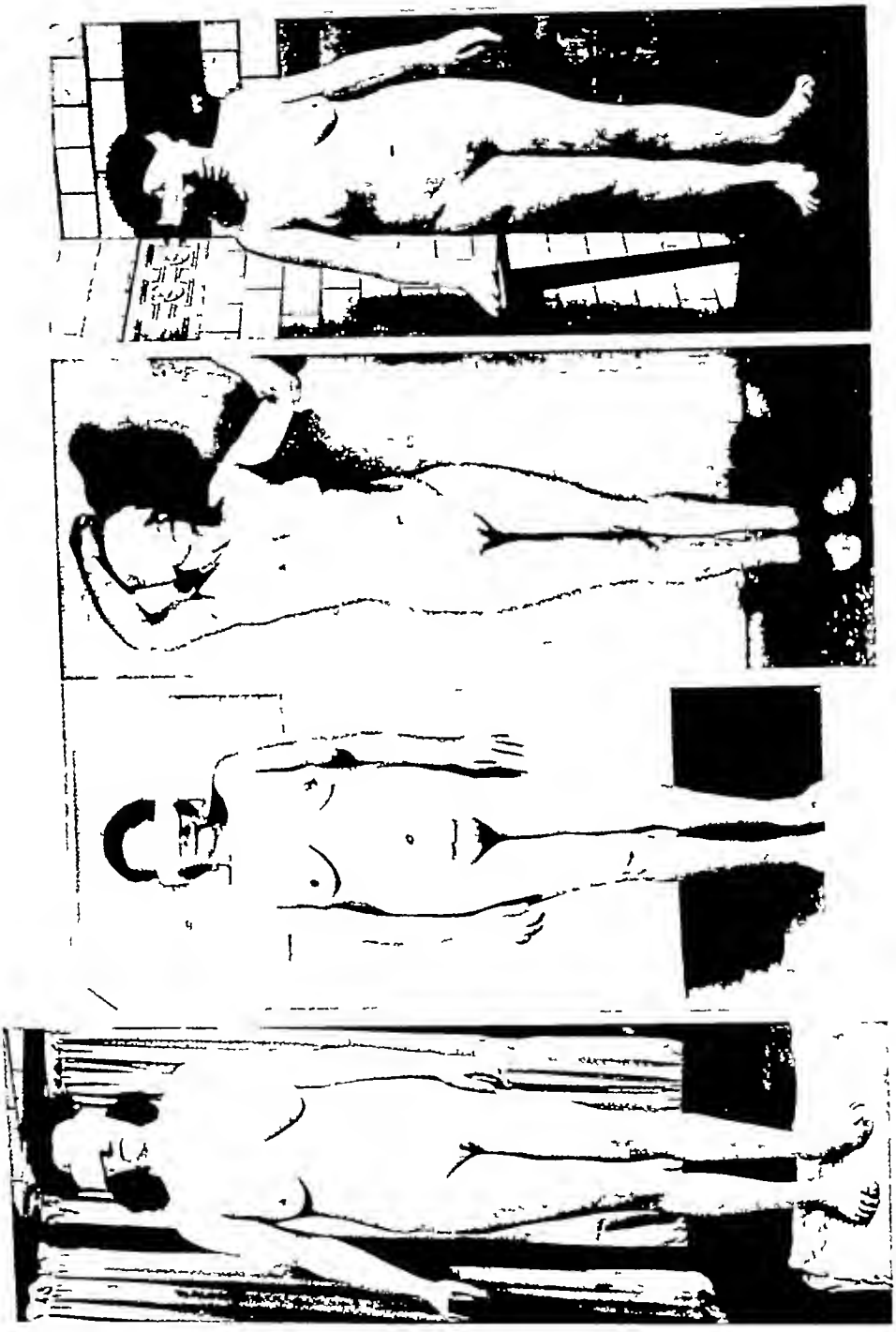

Case D V

Case R B

Case M Y

Case P M

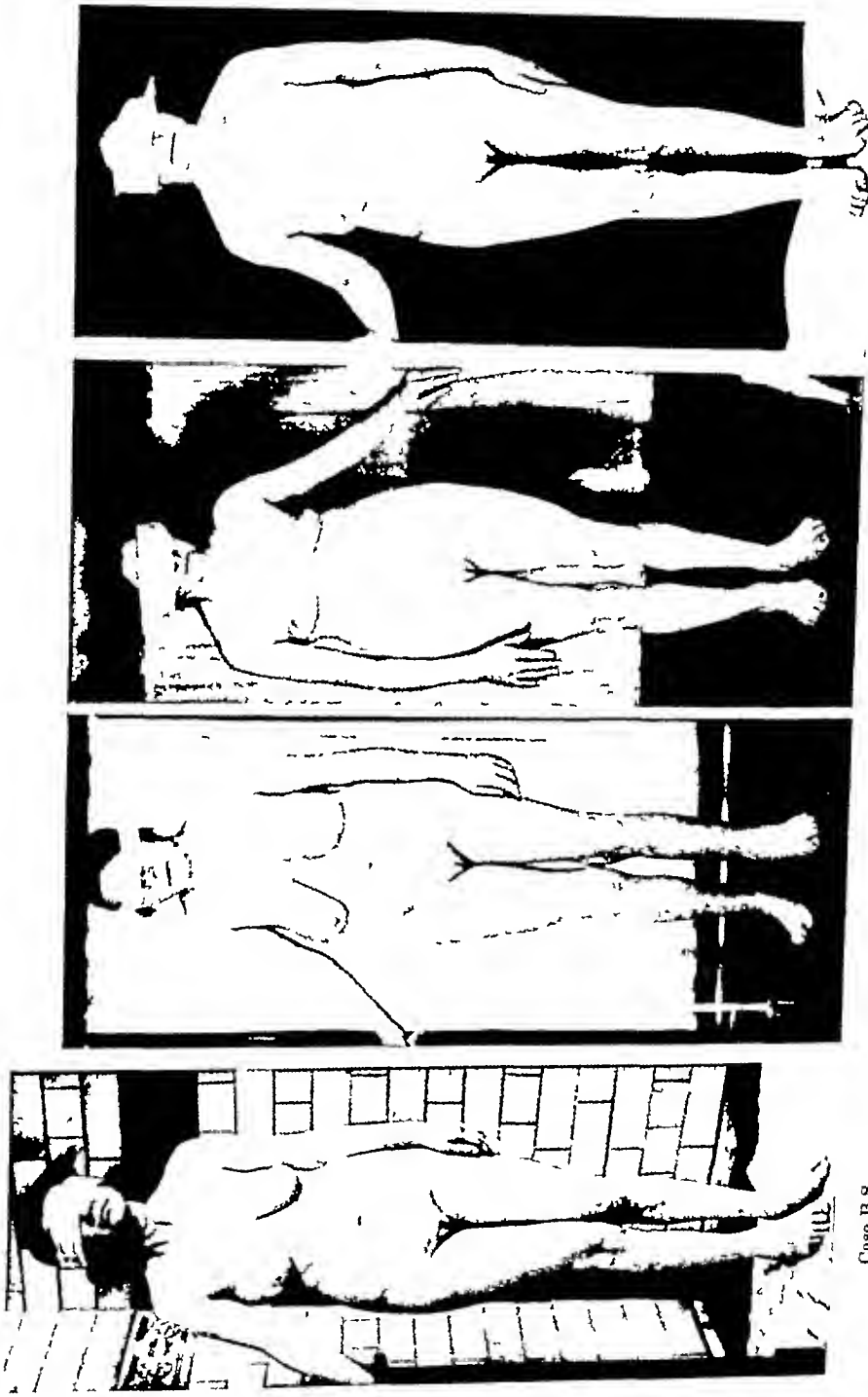

Case D L

Case A G

Case A M

Case B S

616 12–007

GENETIC AND ENVIRONMENTAL FACTORS IN CONGENITAL HEART DISEASE[1]

By MAURICE CAMPBELL

(From the Cardiac Department, Guy's Hospital, and the Institute of Cardiology, London)

Introduction

CONGENITAL heart disease and congenital defects in general may be due to genetic or environmental factors A positive family history in most cases would be the best evidence of genetic factors, and this is not forthcoming The small number of women with congenital heart disease who marry and have children limits the frequency of such a history, but should not prevent the collection of enough collaterals to be decisive Although such a family history is not common, most workers agree that it is more common than would be expected by chance Abbott (1927) found 11 pairs of brothers or sisters with such a heart defect and Brown (1939) has seen six instances Taussig (1947) has seen four families where there was more than one member with congenital heart disease, in two of these the condition passing through more than one generation, in one the grandfather, two of three children, and one of two grandchildren had a patent ductus arteriosus A family history of patent ductus seems more common than of other lesions, perhaps because of its better prognosis, for example, it was found in twins by Smith (1929) and in sisters by Jewesbury (1912) and Ellis (1933), two recent papers have recorded such cases Walker and Ellis (1940) reported a father and four of eight children with patent ductus, and a mother and foetus with identical high ventricular septal defects Stein and Barber (1945) recorded a mother aged 34 years with coarctation of the aorta, and a daughter aged nine years and a son aged 12 years who were both thought to have a patent ductus We have observed the opposite combination, where the mother had a patent ductus and the daughter had coarctation (see p 385) In such a comprehensive book as that of Gates (1946) there is not much pertinent information about the inheritance of congenital heart disease, and this made it seem more worth while to collect and report the data that follow

Mendelian Inheritance in General and in Dextrocardia

A character that is transmitted as a Mendelian dominant is fairly easy to recognize From the small number of cases with direct transmission from parent to child this seems to be excluded, though it does not exclude the transmission in this way of some tendency that could lead to a defect developing if the environment were suitable Thus, Campbell and Warner (1926) found that

[1] Received March 12, 1949.

acholuric jaundice could be shown to be inherited as a Mendelian dominant character, if one examined the other members of the family and so detected latent cases with the specific changes in the blood, in whom no extrinsic factor had precipitated enough haemolysis to cause jaundice and a large spleen

A recessive Mendelian character is more difficult to detect, and the frequency with which the lesion follows consanguineous marriages, especially those between first cousins, gives one clue Roesler (1928) observed consanguinity in 10 per cent. of his cases of cardiac defects, but this has not been confirmed by others and is low in our series Cockayne (1938) has shown that dextrocardia with transposition of the viscera is more common after first cousin marriages and is, therefore, almost certainly transmitted as a recessive Mendelian character. As complete transposition occurs in 1 in 20,000 subjects, and marriages between first cousins in between 0 6 and 0 9 per cent among hospital patients in a large town, he deduced that if dextrocardia is a Mendelian recessive character first-cousin marriages among the parents of such patients should occur in between 5 and 9 per cent actually, he found six such marriages of the parents among his 53 cases, and so provided ample confirmation for this view Cockayne found 15 examples of Fallot's tetralogy and some other congenital abnormalities in those with complete transposition of the viscera, although it is generally said that such a lesion is of no significance, and this is, of course, true of those with no other defect He found that five of his own 55 cases had congenital heart disease Congenital abnormalities occur more frequently in patients with isolated dextrocardia where the other viscera are not transposed, and Cockayne produced some evidence that this may be transmitted in the same way From this and the association of dextrocardia with Fallot's tetralogy Cockayne concluded that Fallot's tetralogy might be carried by the same or a closely associated gene It seemed possible, therefore, that Fallot's tetralogy and other congenital defects might be transmitted as a recessive character even where there was no dextrocardia

Congenital Defects in General

Malpas (1937) made a general inquiry into congenital malformations found at the Liverpool Maternity Hospital in the years 1923 to 1932 There were 294 defects in 13,964 births, about 2 per cent , only 10 of these were cardiac, but he recognized that only those where the lesion was obvious in the first few days of life would be included Multiple defects in the same child were common, and those of unknown aetiology occurred mixed with defects that are known to be hereditary, for example, brachydactyly Malpas (1942) thought that the incidence of foetal malformations was closely bound up with the problem of abortion–stillbirth sequences and that, if a malformation occurred in such sequences for which no cause could be found, the prognosis of a normal child in the future was not as good as it would be otherwise

Congenital Malformations by Murphy (1940, 1947) is a mine of information about congenital defects His study was based on all the children with a congenital malformation as the main cause of death during a five-year period

(1929 to 1933) in Philadelphia, and dealt with 1,476 recorded congenital abnormalities, in 890 of which there was confirmation of the diagnoses Murphy found that 47 of each 10,000 births were children with obvious congenital defects, that 25 per cent of these were stillbirths, and that, as far as his records went, 77 per cent of the children had a defect of one part of the body only. From the nature of the inquiry the defects were inevitably serious ones, and 90 per cent of the children died within a year In families with one defective child the proportion of subsequent children with congenital defects was raised to 11 per cent instead of being under 0 5 per cent Among these families he studied 33 pairs of twins, in 12 both were normal, in 18 one was defective, and in three both were defective He found that 1 8 per cent of the families gave a history of consanguineous marriages between the parents or their progenitors Murphy concluded that there was little evidence of environmental changes as the cause of these defects and some evidence that they were due to genetic causes, and he gave four main reasons for this

1 Congenital defects were nearly twice as common among the white as among the negro population

2 There was a striking sex ratio in certain defects The number of male children to each 100 female children being 306 for pyloric stenosis, 188 for hare lip and cleft palate, and 170 for hydrocephalus alone, but only 115 for all congenital defects

3 He found a period of 'relative sterility' about the time that the children with congenital defects were born, miscarriages and stillbirths occurring more often just before and after the pregnancy in question Malformed children were born prematurely four times as often as others and more often of older than of younger mothers, and children born later in the family were more often defective When a second defective child was born in the same family it was more likely to be later rather than just after the first one, as might be expected with an environmental cause

4 Even more important was that a second defective child was found more frequently in the same families This was also true among more distant relatives, congenital defects being found in 6 9 per cent of the cases In families with two defective children the defects were the same in over 50 per cent , and where more distant relatives were concerned, in just under 50 per cent Murphy gave two specially striking examples In one a mother gave birth to two successive children with absence of the diaphragm, both on the right side, although this rare defect is generally on the left side In the second, the father had a child with a hare lip and cleft palate by each of two wives and in each instance on the right side, which is less common Murphy found much less that was significant as regards the environment (see below)

Maternal Rubella and Other Environmental Factors

Until recently there was not much direct evidence of the environment being responsible, though in animal experiment drastic changes in the environment have resulted in congenital defects In 1941 Gregg described 78 cases, including

13 of his own, of congenital cataract occurring after rubella in the mother during the first two months of pregnancy The cataract was usually bilateral and rather different from other types described Congenital heart conditions were noted in 44 of these 78 cases Few details were given as the paper was mainly ophthalmic, but in the three cases with necropsy there was patency of the ductus arteriosus. In the eight cases examined by Dr Harper none were cyanotic and most had harsh systolic murmurs, some with a thrill In 26 of the 35 cases where information was available, the child was a first child and Gregg correlated this with the young mothers as a large number of young adults were infected with rubella in the 1940 epidemic

These observations of Gregg led to a careful survey by a team of workers in Australia during the next few years Swan, Tostevin, Moore, Mayo, and Black (1943) reported 31 cases which they had collected. If the rubella was during the first or second month 25 of 25 children were affected, but during the third month only four out of eight children, and after this only two of 16 children Among these 31 cases there were 13 with congenital cataract, seven deaf-mutes, and 17 with cardiac defects Fairly full details of the cardiac defects were given. In three the diagnosis was confirmed *post mortem* and all had wide patency of the ductus arteriosus and a small patency of the foramen ovale, one having also a small defect of the membranous ventricular septum In four there were systolic and diastolic murmurs with or without a thrill, suggesting a patent ductus, in three there was cardiac enlargement, and in seven there was a systolic murmur, but even if these last are doubtful there is good evidence of the occurrence of congenital heart disease Cyanosis was not mentioned in any case

Murphy (1947) has collected 295 reports of congenital defects occurring after maternal rubella during pregnancy In 161 there was cataract, sometimes with other eye defects in the same patents Heart defects were the next commonest finding, 117 cases, then deaf-mutism, 88 cases, then mental deficiency and backwardness, 28 cases, and some of these defects over-lapping Turning to the general environment, Murphy (1947) found much less that was significant He found no difference as regards the families' economic or social status, or the fathers occupation, or as regards the incidence of any chronic disease in either parent (8 per cent) or of syphilitic infection (12 per cent) On the other hand, 40 per cent of the mothers had diets that were thought to be deficient in calcium, phosphorus, iron, or vitamins B, C, and D, and 70 per cent were anaemic (under 80 per cent haemoglobin), but he gave no figures for control mothers with normal children and apparently did not regard the findings as unusual

Scope of the Present Inquiry

The chance of seeing so many children with congenital heart disease provided an opportunity for inquiries about any unusual features of the pregnancy that might have influenced the production of the defect From the start the parents (and both were generally seen) were asked about consanguinity and about German measles After a few weeks, inquiries about haemorrhage or threatened

abortion and any illnesses during pregnancy were added The answers were recorded in a special part of the form that was drawn up to be completed in each case Unfortunately, the form contained no question about defects in relations of either parent, though such information was often volunteered or was obtained at later visits No regular question was asked about previous miscarriages and abortions, but recent experience has made me more interested in this aspect and further inquiries are being made The work of Murphy (1940, 1947) and Malpas (1937, 1942) also suggests that this would be of interest, but I had not read these papers until the present inquiry was completed, so that any concordant conclusions reached from the investigation may be regarded as independent confirmation More than 300 forms were available for analysis They were divided into cyanotic and acyanotic cases, the former meaning that cyanosis was constantly present at rest A history of cyanosis at times or on exertion was not considered enough, because I was anxious to include only cases that were certain The details for these two groups are given separately so that the main part of the paper deals with cyanotic congenital heart disease (morbus coeruleus) As the patients get older, details about the mother's pregnancy are less likely to be full and accurate, but in the main they were younger children, so that the information should be reasonably reliable though not complete The ages of the cyanotic patients were as follows

Age group	0 to 4 years	5 to 9 years	10 to 14 years	15 to 19 years	20 to 24 years	25 and over years
Number of cases	108	100	65	25	16	26

At first I analysed the patients not seen as out-patients (privately and elsewhere) separately, because the longer time available for talking might have revealed more details, but there was no difference The figures have, therefore, been combined The inquiries about consanguinity and information about sibs and more distant relations with other congenital defects might provide evidence about genetic factors The inquiries about rubella and other illnesses during pregnancy might reveal some possible environmental influence No inquiries about the general background of the mothers were made, but they seemed distributed in normal proportions between different social and occupational classes, and were not below the average as regards their health If anything marked these parents it was their exceptional care and devotion to the children

Genetic Factors

Any factors that might have a bearing on the genetics of congenital heart disease will be considered first, and then any possible causes in the environment There was no striking sex incidence, but the condition was a little more common among boys, 185 boys and 155 girls There were six pairs of twins where one of the pair had morbus coeruleus There was no case where both twins were so affected I have no proof that any of these pairs were identical twins, but in one this was thought to be so, on account of their close general resemblance until the healthy member developed better because of the heart

disease in the other. In most cases the healthy member was examined and found to be normal

In 255 of 259 unselected patients, including one with true dextrocardia, where the question was asked, there was no known relationship between the parents of children with morbus coeruleus or between their families In the other four the parents were first cousins (Case O115) or second cousins (Cases O121 and O143) and in the fourth the father's mother and the mother's mother were first cousins (Case O181) In addition to this the father's parents were first cousins in one case (Case O001), but this would have no influence on the next generation as regards a recessive character In 55 acyanotic cases there was no known consanguinity among the parents The figures (four of 259 cases, 1 5 per cent) are not much above the normal expectation of 0 6 to 0 9 per cent of hospital patients in a large town, as given by Cockayne (1938) It is, however, more certain that cousin marriages will be found in greater numbers among the parents when any particular recessive gene is rare among the general population, and this has been well shown in alkaptonuria As a gene is more widely spread a larger proportion of cases will arise from random matings and the incidence of cousin marriages may become less significant It seems, therefore, that there is no evidence that congenital heart disease is transmitted as a Mendelian recessive character, though this possibility cannot be excluded The small increase might mean that this type of transmission is important in some small group of cases

Congenital heart disease in relatives No question about relatives with congenital heart disease or other defects was asked regularly Even so, in 100 consecutive cases seen unhurriedly (private patients or hospital in-patients) there were seven where there was a history of sibs or of other members of the family with congenital heart disease This is much more than would be expected by chance, and indicates some developmental abnormality due to genetic factors In one the first child was born cyanotic and died at 11 days old with a diagnosis of congenital heart disease, the patient, who died with a mastoid infection and cerebral complications, had Fallot's tetralogy (Case P068) In another, the patient with gross cyanosis, probably from Fallot's tetralogy with a patent ductus arteriosus, was the eldest, the second child lived only a few minutes, but there was no clear evidence as to congenital heart disease, in the third, who lived only four months, there was cyanosis of the lips and the mother was told that death was due to congenital heart disease (Case P021) In another where the patient had severe Fallot's tetralogy, one brother had acyanotic congenital heart disease, but the type was not known (Case P028) In another, the eldest child had pyloric stenosis, and in addition a cousin of the mother probably had dextrocardia (Case P086) In another the father's brother was said to have died with morbus coeruleus at three months of age (P007) In another the father's first cousin had a baby that died after five hours from congenital heart disease (Case P089) In another there was a vague history of the father's relatives having had children with congenital heart disease (Case P030) Among the other cases the following notes were recorded although no question was

asked regularly The father's two sisters both had children with congenital heart disease, one probably cyanotic and one always cyanotic who died when 21 years old (Case O207) A brother was blue from birth and died at the age of nine years, there was no necropsy, but as he was deeply cyanotic, much disabled, and squatted, he probably had Fallot's tetralogy, there was one normal older sister (Case O185) The uncle of one patient died at 18 months from congenital heart disease (Case O006) One brother died with congenital heart disease at 10 weeks (Case CB11) The sister of one patient died two hours after birth with congenital heart disease (Case O110) There was a similar but less certain story in another case (Case O097)

Dr Paul Wood gave me the opportunity of seeing two brothers where congenital heart disease was known to be present The eldest, aged eight years, had never been cyanotic, he was fully investigated with angiocardiography and cardiac catheterization and was thought to have pulmonary stenosis and a ventricular septal defect, with an aneurysm of the right pulmonary artery and pulmonary regurgitation (Case H272) The younger, aged five years, had been cyanotic from birth and appeared a straightforward case of Fallot's tetralogy (Case H116)

Dr V K St G Breakey has given me details of an interesting family where auricular septal defect was present in a child and her mother and grandmother The girl, aged seven years, had had congestion of the lungs three times and was always breathless on running At four years of age the doctor noticed a long, harsh systolic murmur maximal in the fourth left interspace Radioscopy showed the heart size at the upper limits of normal with fullness of the right auricle and pulmonary conus and a small aortic knuckle The pulmonary arteries were prominent with enough pulsation to be called a hilar dance The mother, aged 37 years, was known to have had a murmur since early infancy and was looked on as having congenital heart disease when she developed rheumatic fever at 16 years of age There was a malar flush with slight dyspnoea on exertion There was a long, harsh systolic murmur similar to that of her daughter and a different systolic and presystolic murmur at the apex Radioscopy showed considerable enlargement of the heart with a large right ventricle and right auricle There was a large pulmonary artery, especially on the left side, and a full pulmonary conus, there was very obvious hilar pulsation and the pulsation extended far out into the lung fields Her mother had died of acute heart failure when she was aged 38 years, and there was an autopsy record of auricular septal defect, but no other details were known

Mother with patent ductus arteriosus and daughter with coarctation Among the acyanotic cases there were two further examples A girl aged eight years (Case O255) had been under observation for four years with coarctation of the aorta She looked a healthy child and had no symptoms except a little fatigue. There was striking pulsation in the neck and a blood-pressure of about 160/110 in the arms, with no palpable pulse in the abdominal aorta or legs Collateral circulation could be seen in the back when she bent down, and notching of the ribs was first certain when she was six years The heart was at the upper limits

of normal, cardio-thoracic ratio 51 (10 25/20 cm) It was possible that she had some additional lesion, as the pulmonary arc was prominent and pulsatile and a faint diastolic murmur was sometimes heard towards the apex There was no rheumatic history or other signs of mitral stenosis, and though a patent ductus would explain the shape of the heart, it seems unlikely that this was present and more likely that she had a slight aortic leak. Her mother, aged 31 years, would not have attended hospital except to bring her daughter with her, but she had been told that she had heart disease as a child and had not been allowed to play games at school She had led a normal life otherwise Her heart was not enlarged and there was a soft continuous murmur high up on the left side under the clavicle, characteristic of patent ductus arteriosus, and a faint systolic thrill The pulmonary artery was prominent, but not outside normal limits It was thought that her murmur must have been more obvious when she was a girl, as it seemed unlikely that a school examination at that time would have revealed the murmur described

Environmental Factors

Rubella and other illnesses during pregnancy Whether a genetic factor is responsible or not, there might be some factor in the environment that is partly responsible for the production of congenital abnormalities in the heart and elsewhere Inquiries were, therefore, made about any illnesses during pregnancy that could have led to injury to the foetus, and special attention was paid to a history of rubella or of haemorrhage or threatened abortion The answer about illnesses during pregnancy was completed on 250 forms In 177 the recorded answer was no illness, no rubella, no haemorrhage, showing that the last two questions had been asked specifically, in 32 the recorded answer was no illness, no rubella, in seven no illness, and in 10 (all early cases when perhaps no other question was asked) no rubella Less than one in 10 (24 cases) gave any answer that could be significant Rubella was specifically inquired for in view of the reports that it may cause congenital heart disease and there were four positive answers here, which is more than would be expected by chance One patient, Case P037, who also had a congenital cataract, was born on 18 10 40, and her mother had had rubella in the previous March or April The heart *post mortem* showed a very large opening between the right and left auricles, the latter being small and ill-developed, and the other features being typical of Fallot's tetralogy with a small pulmonary artery and a fairly severe infundibular stenosis She was in the Bristol Eye Hospital when she was one year old and it was observed that she had constant rotatory nystagmus, and a dense lens opacity in the anterior cortex and centre When admitted to Guy's Hospital Mr Law reported a lens opacity and right fixation nystagmus

Case P045 was born on 13 10 40 and her mother had had rubella that Easter In 1948 she appeared to be an ordinary case of Fallot's tetralogy and was greatly helped by Blalock's operation One of the last big epidemics of rubella, with an unusual number of adults affected, was in 1940 it is interesting that two of these four cases should have occurred in the same epidemic of rubella

that led to the discovery of the connexion in Australia The mother of Case O248, born in January 1945, contracted rubella just after conception and the child had a left congenital cataract as well as Fallot's tetralogy, a second child born since appears normal Case P008 with Fallot's tetralogy was the fourth, but as he was 25 years old the details were less certain he was, however, born three weeks prematurely and thought that his mother had had rubella about the second month Against these four, there were 239 cases where it was recorded that there had been no attack of rubella

Other infectious diseases were not asked for specifically It seems unlikely that when German measles was asked about, one would not have obtained the information if, in fact, the mothers had suffered from ordinary measles, as they were also asked about other illnesses There is little, if any, evidence that measles and most other virus diseases are capable of producing congenital defects in this way, though anterior poliomyelitis may do so As evidence that such histories would probably have been obtained if present, there are notes that the mother of Case P016 had very severe measles in which she went almost blind a year before he was born, and the mother of Case P058 nursed her daughter with severe mumps when she was two months pregnant, but did not develop any symptoms or apparently contract the disease

Other illnesses and haemorrhage In addition to the four with rubella there were 14 with an illness of some sort during pregnancy that was thought worth mention and six with haemorrhage or threatened abortion, they were as follows·

The mother was worse during this than any other pregnancies and had had bronchitis for the first three months (Case O001)

The mother was in hospital with pleurisy from three months until the birth of the child, had made a good recovery, and had been well since Presumably this was tuberculous as the father had pulmonary tuberculosis (Case O009)

The mother had pleurisy at three months and fluid was removed from the chest, and she also had kidney trouble at a later stage, perhaps pyelonephritis She, too, had made a good recovery and was grossly overweight (Case O011)

The mother had a bronchial cough at three months, but does not appear to have been laid up with it (Case O042)

The mother had 'kidney trouble' at three months (Case O107)

The mother had shingles on the right leg at two months (Case O139)

The mother had pleurisy and pneumonia at two months This patient was one of non-identical twins, the other being normal (Case O193)

The mother had whooping-cough at the start of her pregnancy (Case O210)

The mother had a severe fall at three months, her previous pregnancy having been a tubal one (Case O217)

The mother had had an operation for ? salpingitis and thought that both tubes had been tied in November 1941 The patient was born on 10 8 42, so presumably the pregnancy had started just before the operation, during her illness (Case O211, with tricuspid atresia and a non-functioning right ventricle)

The mother of one patient (an only child) had had toxaemia of pregnancy at seven months with an induced labour at eight months and a child that died at

birth, secondly, a miscarriage at three months after hyperemesis, and thirdly, severe vomiting, anaemia, and pyelitis that kept her in bed from the eighth to the thirteenth week of the pregnancy in which the patient was born (Case O018)

The remaining three of the 14 had less definite illnesses One mother thought that her vomiting during the first month had been unusually severe, another had rather more attacks of asthma than usual, the third had severe insomnia and nervous symptoms

There was a total of 14 cases, unless otherwise stated all these children were thought to have Fallot's tetralogy or a closely related lesion

Threatened abortion Haemorrhage or threatened abortion at an early stage of pregnancy (six cases) might indicate changes that had led or could lead to injury to the foetus and some congenital defect, and these questions were asked specifically in nearly all cases, without revealing a significant number of pertinent histories

One mother was told that she had a retroverted uterus at 10 weeks, she had pain but no bleeding (Case P079)

Another had an operation for retroverted uterus at seven weeks (Case P087)

Another had haemorrhage and threatened abortion at two months (Case O126), and two others at three months (Cases O100 and P022)

A sixth saw her periods regularly up to the fourth month, but there does not seem to have been anything else unusual (Case P040)

Previous and subsequent miscarriages No detailed records were made of previous or subsequent miscarriages, but recent inquiries suggest that the factor causing a miscarriage in one pregnancy might lead to the birth of a child with a defect in another

Case O018 just quoted (p 387) is one example The mother of Case O075 with Fallot's tetralogy had a 26-weeks miscarriage one year after the patient was born and again had a miscarriage at four months, two years later The mother of Case P226 with a patent ductus was resting and having injections of progesterone because of three previous miscarriages

The mother of Case P228, a child with pulmonary stenosis, after one normal child, had a premature baby that did not live, and then a miscarriage, when pregnant with the patient she had to rest and have injections, probably of progesterone, from the first or second month

The mother of Case P212 had two miscarriages, at three months and two months, and had rest and injections (? corpus luteum) during her next pregnancy, the child had pulmonary valvular stenosis and a very large heart (confirmed *post mortem*)

Since writing the present paper I have been given two more similar histories The mother of Case O067 had two spontaneous abortions after the death of her first child from whooping-cough, and because of this had injections throughout her next pregnancy when the patient, who had Fallot's tetralogy, was born

The mother of Case P112 had two miscarriages, at three months and five months, and during the pregnancy in question was resting and having progesterone injections, and again had a threatened miscarriage at three months and seven months; the child was cyanotic and was thought to have congenital pulmonary stenosis

Brown (1948) has recently reported three patients with bleeding and threatened miscarriages where for special reasons treatment with ovarian hormones was continued longer than usual, all pregnancies terminated prematurely between the 30th and 35th weeks with abnormal babies, two with exomphalos and one with microcephaly, none of the three survived

Acyanotic cases There were no examples of rubella among the mothers of 50 acyanotic cases There were only five with any history of illness during pregnancy The mother of one boy with an undiagnosed congenital heart and pituitary deficiency had developed diabetes during her pregnancy (Case P211) The mother of a boy with pure pulmonary stenosis had an attack of gall-stones (Case P213), and another mother had recurrent kidney trouble during her pregnancy Another had erythema nodosum at six weeks, but also had such an attack about the same stage of a subsequent pregnancy and the child was normal (Case O111) A fifth had bronchitis and asthma from the third month (Case H254)

A history of tuberculosis seemed uncommon In one case there was a good deal of tuberculosis in the father's family, the first child was stillborn and the second had probably a large auricular septal defect (Case P227) In another the mother complained of no illness during pregnancy, but was admitted to a sanatorium with tuberculosis of the lung when the child was about six months' old, so possibly active infection had, in fact, started earlier (Case P039)

Discussion of Illnesses during Pregnancy

If these illnesses were of no significance it is curious that so many were in the second or third month of pregnancy, though no indication had been given to the parents of what period one was interested in Even the third month is probably too late, as the stage of development when these malformations could most readily occur would be six or eight weeks, but a pathological process that led to the overt illness later might sometimes have started earlier Illnesses during the later months of pregnancy did not seem unusual and have been omitted As a control for these figures I have compared them with some histories obtained by Evans (1948) in normal parents when he was investigating the influence of illnesses during pregnancy in the mothers of children with spastic and athetoid types of paralysis In 50 controls he found 14 illnesses among 10 of the mothers—threatened abortion in four, toxaemia of pregnancy in two, prolonged vomiting in two, pyelitis in two, and miscellaneous conditions in four These figures should be more accurate as special inquiries were being made at the interview, but they appear to be of the same order as in the parents of the children with congenital heart disease Further, Mr G F Gibberd has kindly read the part of the present paper about illnesses during pregnancy

and allows me to quote his impression that rubella is the only disease that is significantly more common than would be expected, and that the general incidence of illnesses, in particular as regards 'kidney disease' and threatened abortion, is no greater than among mothers selected at random A total of 24 cases out of 250 does not seem to be a significant proportion of the whole, and probably a random selection of cases would give as many instances But the four cases where the mother had rubella and a child was born subsequently with morbus coeruleus (and twice with cataract) must certainly be significant It is possible, therefore, that some of the other illnesses may also have been of importance, especially as so many of them were about the second or third month of pregnancy.

Summary and Conclusions

The case notes of 300 children with congenital heart disease, seen since September 1947, have been examined for evidence of genetic or environmental factors in its causation About 250 were cyanotic and 50 acyanotic, but the numbers were not quite the same for each part of the inquiry as not all inquiry forms were complete

In four cases in the series (1 6 per cent of the cyanotic cases), the congenital heart disease, generally Fallot's tetralogy, appeared to be due to the mother having had rubella during the first two or three months of pregnancy, two of these children had congenital cataract also and one was mentally backward Most of the reported Australian cases had acyanotic heart disease, so it is interesting to know that rubella is also one cause, but not an important one statistically, of morbus coeruleus

No decisive evidence of the importance of other environmental factors has been found Anterior poliomyelitis and deep X-ray therapy for the mother during pregnancy may cause congenital defects, though I have no personal examples of these No other illnesses and no other outside factors during pregnancy have been proved to be significant by these cases, though there is some evidence, which is being investigated more fully, that series of stillbirths and miscarriages may be of importance It is not, of course, certain that these are due to environmental causes, because the stillbirths and miscarriages and defects might all be due to genetic causes

Although it is relatively uncommon for two or more examples of congenital heart disease to occur in a family, two striking instances, and some others less striking, were encountered These were two brothers, one with Fallot's tetralogy and one with pulmonary stenosis and aneurysmal dilatation of the pulmonary artery There was a mother with a patent ductus arteriosus and a daughter with coarctation of the aorta

Altogether, more congenital defects, especially of the heart, were found among the sibs and more distant relatives of these patients than could be expected by chance, and this is the best evidence that a genetic factor is often responsible Questions about these relations with congenital defects were not asked systematically, but from some samples it seemed that they occurred in

out 7 per cent of the cases, and were often of the same nature as the fect in the original patient

Congenital defects of other parts of the body were found in many cases, but e not discussed here

Consanguineous marriages were inquired for in an attempt to show that a cessive Mendelian type of transmission was important Four examples were ind, which is somewhat, but not greatly, above the average (1 5 per cent of e cyanotic cases, as against the usual figure of 0 6 to 0 9 per cent) so that no nclusive evidence was found about the method of inheritance

The causes of congenital heart disease are mainly genetic, though maternal bella early in pregnancy is occasionally responsible It is right, clinically, to ll the mother that there is no risk of other children being born with congenital art disease This is not scientifically true, but the risk that the next two or en three children will show any serious congenital defect is small

REFERENCES

bbott, M E (1927) *Osler's Modern Medicine*, 3rd ed , Lond , vol iv

rown, J W (1939) *Congenital Heart Disease*, Lond

rown, R C (1948) *Brit Med J* 2, 853

mpbell, J M H , and Warner, E C (1926) *Quart J Med* 19, 333

ckayne, E A (1938) *Ibid* , N S 7, 479

lis, R W B (1933) *Proc Roy Soc Med* 26, 511

vans, P R (1948) *Arch Dis Childh* 23, 213

ites, R R (1946) *Human Genetics*, New York.

regg, N M (1941) *Trans Ophthal Soc Australia*, 3, 35

ewesbury, R C (1912) *Proc Roy Soc Med* 6, 100

alpas, P (1937) *J Obstet Gynaec Brit Emp* 44, 434.

— (1942) *Ibid* 49, 65

uir, D C , and Brown, J W (1935) *Brit Med J* 1, 966

urphy, D P (1940) *Congenital Malformations*, Univ of Pennsylvania Press

— (1947) *Congenital Malformations*, 2nd edit , Philad , Lond , and Montreal

oesler, H (1928) *Wien Arch inn Med* 15, 487

mith, K S (1929) *Arch Dis Childh* 4, 330

tein, I , and Barber, D J (1945) *Amer Heart J* 30, 118

wan, C , Tostevin, A L , Moore, B , Mayo, H , and Black, G H B (1943) *Med J Australia*, 2, 201

aussig, H B (1947) *Congenital Malformations of the Heart*, Commonwealth Fund, London, Oxford

Valker, G C , and Ellis, L B (1940–1) *Proceedings New England Heart Ass* , p 26

THE ASSOCIATION OF PHYSICIANS OF GREAT BRITAIN AND IRELAND

1949

FORTY-THIRD ANNUAL GENERAL MEETING

THE FORTY-THIRD ANNUAL GENERAL MEETING was held at Belfast on Friday and Saturday, June 3 and 4, 1949, in Queen's University The attendance book was signed by 150 members and 7 visitors The proceedings began at 9 45 a m

The President, Professor John Hay, was in the Chair

The Minutes of the last Annual General Meeting having been published in the *Quarterly Journal of Medicine* were taken as read, confirmed, and signed

The Treasurer presented the Annual Accounts He pointed out that by paying grants to the Clarendon Press for coloured illustrations for the *Quarterly Journal of Medicine*, and by paying travelling expenses of the Committee as previously agreed, the Association could not pay its way without raising the subscription This he was unwilling to recommend. After discussion it was agreed that, except in special circumstances, no grants would in future be made for coloured illustrations, and that travelling expenses would be payable only for the second Committee meeting, except in the case of officers and the local secretary, when travelling expenses would be paid for both meetings The Accounts were then adopted

Place of Meeting in 1950 It was agreed to meet in London in 1950

Election of Officers

President Professor W W D Thomson was elected President and took the Chair He expressed the thanks of the Association to the retiring President, Professor John Hay

Executive Committee

President Professor W W D Thomson

Treasurer Dr C Newman

Secretary Dr W I Card

Members for England

Dr Robert Coope
Professor C H Stuart Harris
Dr G Bourne
Dr T C Hunt
Professor R E Tunbridge
Dr K Shirley Smith

Members for Scotland

Dr T N Morgan
Dr J K Slater
Dr W R Snodgrass

Members for Ireland

Dr D M Mitchell
Dr A Thompson
Dr H Hilton Stewart

Election of Honorary Member

Professor John Hay

Election of Extra Ordinary Members

Dr J le F C Burrow
Sir John Conybeare
Professor John Craig
Dr Ivor J Davies
Dr Anthony Feiling
Professor T H Oliver
Professor R A Peters
Professor V M Synge

Election of Ordinary Members

Thomas Russell Cumming Fraser, M D, F R C P, Reader in Medicine, Postgraduate Medical School of London
Clarence John Gavey, M D, F R C P, Assistant Physician, Westminster Hospital
William Lindsay Lamb, M B, F R C P, Ed, Assistant Physician, Royal Infirmary, Edinburgh
Samuel Lazarus, M D, M R C P, Dispensary Physician, Western Infirmary, Glasgow
Brian Gilmore Macgrath, M B, D Phil, Professor of Tropical Medicine, Liverpool University
Brendan Edward O'Brien, M B, F.R C P, Assistant to Professor of Medicine, Dublin University
Richard William Parnell, B M, M R C P, Physician, Institute of Social Medicine, Oxford
Francis Thomas Garnet Prunty, M D, M R C P, Assistant Physician, St Thomas's Hospital
Norman Lloyd Rusby, D M, F R C P, Assistant Physician, The London Hospital
Henry John Wade, M D, M.R C P, Assistant Physician, Salford Royal Hospital
Stephen Robert Ferguson Whittaker, M D, F.R C P, Consulting Physician to Warwickshire County Council

SCIENTIFIC BUSINESS

Friday Morning, June 3

1 Dr J C Gilson (introduced by Dr C M Fletcher) described a method of *Recording of Diaphragmatic Movement* Using the flourescent screen of the X-ray set, provided with a tilting table, a shadow of the diaphragm is followed with a perspex block linked by a Bowden cable to a pen recording on a kymograph On the same kymograph a record of the spirogram is obtained from a closed circuit re breathing spirometer Cross wires on the screen and a scale on the edge of the table provide an accurate means of recording the positions, and also ensure that only the central rays from the tube are used, thus avoiding distortion The method had been applied to 12 subjects in seven postures, including lying on the side As the subject changed position from standing to one lying at 45° head-down, there was a progressive decrease in the reserve air expressed as a percentage of the vital capacity, and also a reduction of the movement of the diaphragm above the resting level during full expiration In contrast there was no close relation between vital capacity and total diaphragmatic movement with change of posture The method had been used to study the time relations of diaphragmatic movement and the volume of air expelled during the vital capacity measurements A record was shown of the action of 'Flexedil', in which complete paralysis of the voluntary muscles occurred, leaving the diaphragmatic excursions unaffected

2 Dr R N Tattersall (introduced by Professor R E Tunbridge) described 60 cases of *Senile Purpura* in 809 elderly patients He said that this condition was recognizable clinically by its characteristic distribution on the extensor surface of the forearm and hand, by the shape of the lesions, and by their recurrent nature The lesions could be produced artificially by minor traumata, but only on the extensor surface of the forearm and hand, and on the face Histologically an advanced degree of 'senile elastosis' was found in these areas, but not elsewhere Routine blood investigations were normal The condition might be distinguished from the other varieties of purpura occurring in old age by the distribution of the lesions, their shape and size, and their natural history It bore no relationship to any systemic disease or recognizable dietary deficiency Histologically there was a constant association with a high degree of senile degeneration of exposed skin There was considerable evidence that trauma was the precipitating factor in the production of the purpuric lesions, probably because the skin-vessels were inadequately supported by the degenerated connective tissue The exact nature of these degenerative changes in

the skin and the reasons why they always occurred in the same sites were matters of dispute

Dr F Parkes Weber asked if there was any connexion between this condition and cerebral atheromatosis

Sir Henry Tidy asked if nicotinic acid had been used for treatment

Dr. S B Boyd Campbell thought that nicotinic acid should be combined with the air of Northern Ireland

Dr D K O'Donovan asked if Dr Tattersall had studied the phenomenon in patients with poorly controlled diabetes mellitus and premature arteriosclerosis

Dr C J Gavey mentioned a case of a woman with recurrent vitreous haemorrhages coincident with crops of ecchymoses on the upper arms This patient reminded us that haemorrhages in senile purpura are not confined to the skin

Professor R Platt asked what evidence there was that so-called elastic tissue had in fact the property of elasticity

In his reply Dr Tattersall said that nicotinic acid was given a therapeutic trial, but produced no improvement He mentioned another case similar to Dr Gavey's, with the association of senile purpura and ocular haemorrhages A high proportion of the patients in his series had senile dementia He said that examination of normal skin tissue under the electron microscope demonstrated the presence of many collagen fibres and very occasionally an elastic fibre The abnormal skin in senile purpura showed 'unhealthy' collagen fibrils and much amorphous material, but no elastic fibres It seems that much of the material in the body which takes elastic stains is not essentially fibrous in nature and probably has varying physical properties and composition This question was being further investigated

3 Dr. H N Robson (introduced by Professor D M Dunlop) described his *Observations on Splenic Function in Thrombocytopenic States* Twelve cases of idiopathic thrombocytopenic purpura were investigated with regard to changes in bleeding-time, capillary resistance, and platelet counts, before, during, and after splenectomy An alteration in capillary state, as manifested by a reduction in bleeding time, and an increase in capillary resistance, was found to begin during the operation, and to precede any alteration in platelet levels Similar observations were made on a control series of 13 patients undergoing splenectomy for other conditions, and seven patients with other abdominal operations The results of these control observations indicated that the initial capillary changes were brought about by a non specific effect of the operation This reaction of the capillaries was found to be delayed in cases of idiopathic thrombocytopenic purpura as compared with controls, and it was suggested that there was an abnormality of the capillaries as distinct from reduced platelet counts

Professor L J Davis asked Dr Robson whether he had noted the effect of surgical operations, other than abdominal ones, on capillary fragility He remarked that intramuscular injections of whole blood had been said to exert a haemostatic effect in haemorrhagic states, and suggested that such an effect, if it did exist, might be due to a non-specific traumatizing action similar to that of the abdominal operations described by Dr Robson

Sir Henry Tidy congratulated Dr Robson on his paper and pointed out that for many years he had protested against the use of the term thrombocytopenic purpura as an entire misnomer

Dr Ernest Bulmer, Dr H Soarborough, and Dr A Thompson also took part in the discussion

In reply, Dr Robson said that the capillary changes could be produced by other forms of tissue trauma in addition to surgical operations Similar changes had been observed after the production of a large haematoma during blood-transfusion in the case of idiopathic thrombocytopenic purpura The duration of the non specific capillary changes was variable, extending from a few hours to perhaps a few days It had not been possible so far to identify the agent responsible for these changes, though it seemed unlikely that it was the anaesthetic No opportunity had arisen so far to study the effects of operation on a patient with idiopathic thrombocytopenic purpura whose spleen had been removed The rise in platelet counts was very much more pronounced after splenectomy than after any other operation

4 Dr C F Hawkins (introduced by Professor T L Hardy) gave a *Description of a Family Suffering from Multiple Hereditary Anomalies, including Congenital Nephritis and Iliac Horns* The members of this family, consisting of 28 members in six generations, were otherwise of normal mental and physical development There was no consanguinity The commonest trait was a dysplasia of the finger-nails and elbow joints, and rudimentary patellae This trait, due to a dominant heterozygous gene, occurred in 19 instances Occasional features were multiple angiomata of the skin, congenital cataract, polydactyly, 'pigeon chest', cervical ribs, and spina bifida occulta There were nine examples of iliac horns or bony symmetrical processes projecting posteriorly from the iliac bones, palpable in the centre of the buttock They were present in a baby of six months and showed terminal epiphyses in a girl aged 14 years There seemed to be no anatomical or anthropological explanation of these peculiar structures A condition resembling chronic glomerulonephritis existed in six of the family Two died, aged 62 and 50 years, the remaining four persons, two brothers and their daughters, ages ranging from eight to 47 years, were studied over two years All had persistent albuminuria with casts of all types and red blood-cells. The specific gravity of the urine and renal function tests were within normal limits Uroselectan X-ray in one case was normal except for diminished concentration Radiographs in each case showed renal shadows of normal size and shape All the patients were free from symptoms, but one had slight hypertension (blood-pressure = 160/110) This family was the first recorded example of the so-called hereditary familial congenital nephritis associated with multiple developmental abnormalities elsewhere, supporting the existence of a type of renal dysplasia that gave a clinical picture identical with chronic glomerulonephritis

5 Dr F Parkes Weber discussed *Combined Osseous and Dermal Dysplasias* He said that it was a well known rule that when one developmental abnormality occurred others should always be sought The frequent association of various kinds of developmental abnormalities or malformations was clearly seen in asylums for mentally defective children, where the abnormality of mental development was found not rarely to be associated with other developmental abnormalities, such as mongoloid features, congenital heart-disease, malformation of the extremities, etc Dr Parkes Weber then made an attempt to classify the known combinations of osseous and dermal dysplasias In some cases various other developmental abnormalities might be superadded, thereby increasing the number of rare syndromes

Only Dr Parkes Weber took part in the discussion that followed

6 Dr. William Evans, in describing *A Clinical Sign of Cardiac Pain*, said that in extensive or salient cardiac infarction the chest pain was both strong and lasting, and that widespread injury to the heart produced physical signs which were easy to discover The patient was pale, cold, and sweating under the stress of almost unbearable pain, the temperature was low, the pulse small, and the blood pressure had dropped, the heart-sounds were distant with triple heart-rhythm, and occasionally a pericardial friction sound was heard, the abnormal electrocardiogram gave proof of the diagnosis In the other kind of chest pain from restricted cardiac infarction, no such obvious physical signs were present The pain itself was less severe, neither lasting as long nor causing symptoms of shock, often the pain was induced only by effort and quickly yielded to rest The patient was ambulant and might refer casually to his disability Until now, the identification of coronary artery disease in patients in this group had not been helped by clinical examination, and it had been left to electrocardiography to decide the diagnosis He wished to emphasize the value of triple heart rhythm in a patient with chest pain, it was heard in over one fourth of patients who subsequently showed an abnormal electrocardiogram from cardiac infarction The triple rhythm was created by addition of the third heart-sound, and was best heard at the lower end of the sternum with the patient in the recumbent position When present, it was likely that some cardiac enlargement, and especially pulmonary congestion, would be found on radiological examination of the chest, it depended in no way on the presence of hypertension Owing to the paucity of physical signs, the diagnosis of cardiac pain in the ambulant subject had not been possible in the absence of electrocardiography Triple heart-rhythm was a physical sign of inestimable value, permitting by itself the recognition of cardiac infarction in over one fourth of such cases Since the auscultatory sign could predict this lesion with the bell of the stethoscope at the lower end of the sternum, we should apply ourselves diligently to discover it The simplicity of the test was disproportionate to the enormity of the problem which it so often solved

The communication was discussed by Dr C M Fletcher, Dr. S B Boyd Campbell, and Sir Henry Tidy

The Association adjourned at 12 50 p.m

At 1 0 p.m the members and guests lunched in the Drill Hall, Queen's University

At 2 30 p.m there was a clinical and pathological demonstration at the Royal Victoria Hospital

At 3 45 p.m the Association was entertained to tea by the Hospital Committee

4 15 p m. Afternoon Session

7 Dr. Alice M Stewart described *An Epidemiological Study of Tuberculosis in Industry* She pointed out that judging by mortality and morbidity statistics the incidence of pulmonary tuberculosis in the shoe industry was exceptionally high Hitherto it had been thought that this was largely due to factors outside the control of the industry, but according to the present investigation working conditions were also responsible Thus, there was a close relationship between the current rate of infection and the carrier rate in various occupations within the shoe industry, and also between the incidence of disease and the size of the working units in shoe factories Similar findings in other industries suggested that spread of infection during working hours was an important factor determining incidence of disease in the adult population.

8 Dr C C Ungley discussed *The Therapeutic Effects of Vitamin B12* He analysed the response of 50 patients to Lester Smith's red crystalline material Megaloblasts matured in the bone marrow, clinical improvement followed, and erythrocytes, platelets, and leucocytes increased to normal levels. For constructing a dose response curve the reticulocyte response was almost valueless and he used the increase of erythrocytes in 15 days Variations were wide, but on the average 7 to 10 micrograms were needed to produce an increase equal to the expected response Increasing the dosage logarithmically gave progressively less augmentation of the 15-day erythrocyte increase, but the effect was more prolonged Oral administration of 5 micrograms daily was ineffective, whereas the same quantity with 50 c c of normal gastric juice produced a satisfactory response The mechanism whereby normal gastric juice facilitated absorption of vitamin B12, or prevented its destruction in the gastro intestinal tract remained obscure No response followed the application of vitamin B12 to the oral mucosa or to its instillation into an isolated segment of the ileum In each case similar doses, with normal gastric juice, given by the stomach, produced an effect In three patients with megaloblastic anaemia of pregnancy or the puerperium, injections had no effect, whereas all cases subsequently responded to folic acid In nine cases of subacute combined degeneration, vitamin B12 proved as effective as liver extract The usual dosage was 40 micrograms a week, and a quantitative method of neurological assessment was used

Dr. Sheila Callender described the optimal response of an untreated case of pernicious anaemia to an injected extract of faeces from a patient also with untreated pernicious anaemia, containing 1 microgram per c c of B12 equivalent This provided further evidence of a defect in absorption or utilization of B12 from the gastro-intestinal tract in pernicious anaemia

Professor L J Davis said that he was interested to learn that Dr Ungley had confirmed recent American reports that certain cases of megaloblastic anaemia failed to respond to vitamin B12, but did so to folic acid He pointed out that certain types of megaloblastic anaemia, such as that occurring in pregnancy, were frequently refractory to injections of liver extracts, but responded promptly to oral liver preparations such as proteolysed liver

In his reply, Dr. Ungley wondered whether the high vitamin B12 content of the stools of patients with pernicious anaemia was due to deficient absorption or to biosynthesis in the intestine It would be interesting to know of values for the stools of normal persons

9 Sir Henry Cohen described a case of *Carotinaemia due to Failure of Conversion of Carotene into Vitamin A* He said that xanthodermia could arise from jaundice, from the ingestion of such substances as picric acid or saffron, and from hypercarotinaemia (carotinosis cutis) He discussed the known chemistry of the carotinoids and the metabolism of carotene, showing that this followed two paths Firstly, after ingestion it might be converted by the intestinal mucosa (not the liver) into vitamin A which passed through the thoracic duct and systemic circulation for storage in the liver, secondly, carotene itself was transported in lipoids through the portal vein to the liver In the body carotene was

oxidized, and in this both thyroid and iron might play a part Carotene was not excreted in the urine On theoretical grounds, therefore, hypercarotinaemia could result from

(a) *excessive* intake, especially when several pounds of carrots and green vegetables had been taken daily for slimming, in the pre insulin treatment of diabetes mellitus, or because, as in the war, other foods were in short supply, in these cases xanthodermia appears in six to eight months and fades in two to six weeks after the return to a normal diet,

(b) *hyperlipaemia*, as in diabetes mellitus, hypothyroidism, and nephritis,

(c) *failure of conversion of carotene to vitamin A*,

(d) *failure of oxidation of carotene*

He explained how these four groups could be differentiated by estimation of blood lipoids and vitamin A and the xanthophyll carotene ratio of the blood, and showed coloured photographs of patients illustrative of the first two groups He had met one example which he assigned to the third group—a woman aged 38 years, with no dietetic fault, who showed xanthodermia and defective dark adaptation She had a slightly lowered basal metabolic rate, an iron deficiency anaemia, and a histamine-fast achlorhydria Her vitamin A absorption curve was normal Blood analyses over a period of a year showed a persistent hypercarotinaemia, a marked vitamin A deficiency (corrected by adequate intake of vitamin A), normal blood lipoids, and an excess of carotene over xanthophyll, the opposite of what occurs in excessive intake and hyperlipaemia He had been unable to find a similar case recorded

10 Dr V K St G Brfakfy (introduced by Dr T H Crozier) reported four cases of *Marfan's Syndrome* Although there were fewer than 250 cases or a dozen autopsies on record, it was a syndrome as well defined as mongolism, and like mongolism provided a setting for congenital malformation of the heart The four cases were in the main characteristic, with arachnodactyly, small hypotonic muscles, articular deformities, ocular abnormalities in two cases and congenital cardiac anomalies in two cases One patient, however, showed oesophageal atresia, important as further evidence against the theory of a complete mesodermal dysplasia The possible association with polydactyly and brachydactyly was discussed, since a sibling of one case had polydactyly, and another case showing arachnodactyly of the hands had brachydactyly of one toe The similarity to amyotonia congenita was also discussed Muscle biopsy in one case showed an unusual hyaline degeneration, but in the other three cases was normal A more frequent use of muscle biopsy was urged in view of our scanty knowledge of the histopathology of muscular dystrophies and myopathies generally

11 Dr J Reid, Dr R D Watson, and Dr D H Sproull (introduced by Professor J W McNee) discussed *The Early Pathology of Acute Rheumatism in the light of Experimental Observations in Therapeutics with Salicylate* Dr Reid said that the relief of fever, tachycardia, and joint pain and swelling in acute rheumatic fever with salicylate was so certain that if the mode of action of the drug were known, the early pathological changes in the acute rheumatic state might be inferred Coburn had shown that the relief of acute rheumatic symptoms and the return of the erythrocyte sedimentation rate to normal both depended on the attainment and maintenance of a high plasma salicylate level Dr Reid had found that relief of symptoms coincided with acid base changes in the blood plasma and a fall in erythrocyte sedimentation rate, with a diuresis, suggesting that changes in reaction and volume of body fluids were involved An attempt to find out the connexion between these two indices of rheumatic activity had been made by simultaneous study of acid-base and volume changes in body-fluids of patients with rheumatic fever during treatment with salicylate The results indicated that salicylate induced a respiratory alkalosis which was associated with alteration in the distribution of water between tissues and plasma Water was first withdrawn from tissues and this led to a temporary increase in plasma volume Later the excess water was removed from the plasma mainly by diuresis The relief of acute joint pain and swelling coincided with the removal from plasma The two chief criteria of cure of an attack of rheumatic fever were thus both related to the same general change, namely, diminution in the water content of tissues and plasma respectively This suggested that retention of water within the body might be an important abnormality in the acute rheumatic state

Professor C H Stuart Harris inquired whether similar biochemical studies had been made in other febrile disturbances Did study of the chlorides and sodium support the changes demonstrated in body water in acute rheumatism?

Dr D A K Black asked whether the salicylate in these observations had always been given in combination with sodium Certain of the phenomena observed, such as the

increase in extracellular fluid volume and the presumed loss of potassium from the cells, might be partly attributable to a rise in sodium intake

DR R W BROOKFIELD said that he had seen acute left ventricular failure occur a few hours after the institution of salicylate therapy in acute rheumatism with carditis Prompt improvement occurred when salicylate was withheld and mersalyl and digoxin were administered

In reply, DR REID said that the investigation had been confined to rheumatic fever, and other febrile diseases had not been studied The effects were considered to be due to salicylate and not to sodium administration, since similar events followed treatment with aspirin, which contained no sodium Treatment of pulmonary oedema was difficult to assess because few patients developed the condition Their practice had been to stop salicylate, carry out a venesection, and give mersalyl

Annual Dinner

The Annual Dinner was held in the Great Hall, Queen's University The President, PROFESSOR W W D THOMSON, was in the Chair The toast of the Association was proposed by the President That of the guests was proposed by SIR ADOLPHE ABRAHAMS, and the RT HON WILLIAM GRANT, Minister of Health for Northern Ireland, replied The toast of the President was proposed by SIR HENRY TIDY The dinner was, in every way, an immense success

Saturday, 9 30 a m Morning Session

12 DR DONALD HUNTER described *Some New Toxic Hazards of Industry* He said that the importation from Sweden of methyl mercury compounds for use as fungicides against the seed-borne diseases of flax was regrettable, not only because Swedish workmen had died making them, but also because seed dressing in Great Britain and Ireland was rendered hazardous The United States of America made 88,000,000 flourescent strip lamps in 1948 The handling of zinc beryllium manganese silicate as a phosphor in such lamps was a dangerous hazard to health If inhaled it might cause either pneumonitis or chronic berylliosis The manufacture of stilboestrol led all too readily to amenorrhoea in the female worker, and loss of sex desire with enlargement of the breasts in the male Protection of the worker was difficult because of the exceedingly small quantity of the material needed to do the harm Dinitro-*ortho*-cresol sprayed on fields of corn in hot weather as a weed-killer was highly dangerous to the spray operator Toxic symptoms were thirst, loss of weight, and fever, the basal metabolic rate was raised Careless handling of the weed killer had been responsible for unnecessary deaths He illustrated his communication by showing some of the substances discussed and seized the opportunity of recording the fingerprints of the President, Professor W W D Thomson.

13 SIR ADOLPHE ABRAHAMS described some personal observations he had made on *Arterial Calcification* He said that radiographic evidence of extensive calcification in the arteries of his lower limb had encouraged an investigation which might throw some light on the significance of Mönckeberg's sclerosis, and the possible influence of long continued exercise in its production and aggravation He had had a portion of his dorsalis pedis artery excised Histological examination showed slight fibrous thickening of the intima without any true atheroma The intimal elastic lamina was pigmented and in one or two places reduplicated The media showed calcification in the form of clearly circumscribed blocks of varying degrees of thickness, with advanced degeneration of the elastic and smooth muscle fibres, and replacement by a myxomatous stroma These changes were absent in a similar biopsy of his radial artery The comparative infrequency of calcification in Buerger's disease, and the greater incidence in the lower limbs of Buerger's disease and Mönckeberg's sclerosis, suggested the influence of gravity as well as of muscular activity in the production of these conditions, although entirely different pathological processes were in question Biochemical investigations were all within normal limits Despite the extensive calcification and the presumed reduction of contractility in the vessels, little impairment of circulatory efficiency had occurred, since he had experienced no muscular pain even in such exercise as running nine miles in an hour He hoped that this communication might encourage others to make similar observations

DR T H CROZIER hoped that at the next meeting in Belfast, Sir Adolphe Abrahams would be able to give an even more complete account of his condition

14 DR G M BULL, DR A M JOEKES and DR K G LOWE (introduced by PROFESSOR J MCMICHAEL) described *The Dietetic Retardation of Uraemia in Acute Renal Insufficiency*

The lesions of particular interest were the acute tubular nephroses (including the lower nephron nephroses and the toxic nephroses, typically seen with mercury poisoning) in which the renal damage was recoverable if the patient could be tided over the period of oliguria In 1946 the treatment centred round the removal of retention products by blood dialysis with a Kolff artificial kidney In the last year dialysis had virtually been discarded and the treatment consisted entirely of extremely careful control of the water intake and the administration of a high calorie diet containing no protein or mineral salts Of 10 cases treated in a period of eight months, eight survived and left hospital well In none of the cases did the extreme oliguria last less than seven days, and the blood urea peak was never less than 300 mg per 100 c c Both patients who died had complications other than renal The daily fluid intake was restricted to 1 litre above the previous 24 hours urinary output, that is, if the patient was anuric only 1 litre was given, this maintained the body in normal fluid balance by compensating for extrarenal water loss The procedure was very simple As soon as possible from the time of onset of the renal failure, a mixture was dripped slowly through an indwelling stomach tube over the 24 hours, containing glucose 400 gm, peanut oil 100 gm, sufficient acacia to emulsify, and water 1,000 c c All vomitus was collected, filtered, and returned to the stomach Water intake was increased over 1 litre by a volume equal to the volume of urine passed in the previous 24 hours

Dr F Avery Jones stated that he had had five cases of profound oliguria in patients after abortion He had treated them without using any of the recommended measures to promote diuresis, such as hypertonic saline, sodium sulphate, sucrose, and splanchnic block, but had given a basal intake of fluid, and in all cases a spontaneous diuresis had occurred towards the end of the second week followed by complete recovery In these cases the blood urea rose about 50 mg per 100 c c per diem, and the patients were extremely ill during the second and third week The method described by Dr Jockes retarded the rate of increase of the blood-urea, and their patients were less seriously ill He felt that a conservative approach, but giving a high calorie intake as recommended by Dr Jockes was the best method of treating these cases

Dr. H G Miller asked whether nephrectomized animals survived longer on this regime

Dr George Graham asked whether the alkali reserve had been estimated He thought that it was important to keep it within normal limits if possible, as the kidney then had its best chance of recovery He also asked whether it was not possible to give some protein as it seemed a pity to break down muscle protein unnecessarily

In reply, Dr. Jockes thanked Dr Avery Jones for his help and advice in the early days of the investigation He did not agree that it was advisable to induce a moderate amount of oedema in oliguric patients in order to dilute the concentration of potassium or other toxic substances in the body fluids The large majority of deaths in recoverable oliguric renal failure were considered to be due to excessive water administration In reply to Dr Miller, Dr Jockes said that the accurate control of water intake in rats was difficult, but it was known that bilaterally nephrectomized rats could be kept alive longer by dietetic means He did not feel that correction of a low plasma bicarbonate was advisable as this was difficult without introducing an excess of other kations or water There was no evidence that added protein to the diet would further reduce the endogenous protein breakdown, which in a group of five control subjects on this diet was reduced to less than 2 gm of nitrogen in 24 hours

15 Professor R A McCance described *Some Clinical Results of Severe Undernutrition* He said that between 1946 and 1948 many cases of undernutrition were seen among the civilian population in Germany, in the civil prisons, and particularly among prisoners of war repatriated from Russia No signs of vitamin deficiencies were detected and the changes reported he attributed solely to a deficiency of calories and protein A curious yellowish pallor was very characteristic and a number of abnormalities were seen in the skin It was uncertain to what extent these were connected. The skin, particularly of the legs, was often dry and covered with fine branny scales or large flakes of epidermis All degrees of hyperkeratosis pilaris were seen and sometimes the papules were pigmented Chronic ulcers on the legs were not uncommon among the civil prisoners in 1946 and must have been very much more common in the prisoners of war, for their legs were frequently covered with the scars When the prisoners returned from Russia they frequently became abnormally fat, and many of them developed swollen parotid glands These enlargements

were not painful, nor did they vary with meals Clinical observation suggested that they were composed of hypertrophied gland tissue, and post mortem examination of one gland confirmed this He suggested that the swellings were really a work-hypertrophy

SIR HENRY TIDY described the changes of pellagra in Egyptians with rapid recovery from nicotinic acid therapy He asked if sections of the skin had been taken during recovery and pointed out that parotid swellings occurring during lean periods had also been known in Egypt for a long time There was no known aetiology

DR D K. O'DONOVAN suggested that the skin changes described by Professor McCance might not be due to a simple caloric deficiency A study of the skin in anorexia nervosa was of some interest as this disease was probably the best clinical example of uncomplicated caloric deficiency There was usually a smooth skin and a plentiful growth of axillary hair with scanty or normal pubic hair There was sometimes a fine downy growth over the body The general pattern of hair growth, combined with other findings, suggested an inhibition of all the pituitary hormones except that controlling some adrenal corticoids necessary for life Overactivity of the pituitary had been suggested to explain some patients who had resumed full diet and showed gross obesity with or without virilism He presumed that the parotid enlargement was a physiological response to the very high carbohydrate diet.

DR CHARLES NEWMAN wondered, apropos of the old descriptions of starvation which Professor McCance mentioned, whether the meeting had noticed the description in Josephus of the results of famine during the siege of Jerusalem There was a particularly good description of the diarrhoea which followed over eating after prolonged starvation, and it included the interesting story of how a party of Jews who escaped from Jerusalem swallowed gold coins before they left and suffered from diarrhoea after being welcomed by the Romans and given food Unfortunately for the Jews, the Romans noticed the gold coins passed by the first one and proceeded to do post-mortems on the rest without going to the trouble of preliminary anaesthesia.

PROFESSOR MCCANCE in reply said that biopsy sections had been done, but their interpretation was difficult

16 DR H G MILLER discussed a case of *Polymorphic Collagen-Vascular Disease* in a 19 year old girl The patient had had a past history of acute and subacute rheumatism and angioneurotic oedema, and exhibited over the course of many months a skin eruption clinically similar to that of erythema nodosum, but more widely distributed She concurrently developed polyneuritis, a localized transient sclerodermatous lesion, and probably an active carditis An initial skin biopsy showed a necrotizing arteritis and periarteritis identical with that seen in polyarteritis nodosa or erythema nodosum, but a further section five months later revealed the appearances of scleroderma without true arteritis Such mixed and atypical cases of inflammatory vascular disease were not very uncommon They lent clinical support to the unitary conception, based on histopathological and experimental evidence, that there was a common factor underlying a group of diseases characterized primarily by necrosis of collagen in the arterial walls and the extravascular supporting tissues The common factor appeared to be anaphylactic hypersensitivity, and in this group of diseases were included human and experimental serum sickness, some forms of drug hypersensitivity, acute rheumatism, polyarteritis nodosa, disseminated lupus erythematosus, anaphylactoid purpura, and possibly others They had in common not only a basically similar morbid anatomical pattern, varying in local incidence and severity, but also a common clinical setting in that they all followed bacterial infections, drug intoxications, or foreign serum injection, while clinically they shared a considerable common symptomatology which included urticaria and erythemas, arthralgias, nephritis, carditis, and migratory pneumonitis

DR S B BOYD CAMPBELL asked if this patient had been having sulphonamides

SIR HENRY COHEN drew attention to the work of Klemperer, Bachr, and Pollack in diffuse collagen disease The changes found in disseminated lupus erythematosus and diffuse scleroderma were observed less conspicuously in rheumatic fever, dermatomyositis, periarteritis nodosa, rheumatoid arthritis, Buerger's disease, serum sickness, and other diseases in which clinical evidence of vascular change, carditis, pleurisy, arthritis, dermatitis, and the like were found Indeed fibrinoid degeneration of collagen could occur both as a general and local expression of injury and in a wide variety of heterogeneous disease processes There was insufficient evidence on which to regard all these as having an

allergic basis, their essential nature might well be dissimilar He discussed also the importance of recent biochemical work on the collagens, especially hyaluronic acid and hyaluronidase and mentioned a grave case of Libman Sacks syndrome which had shown a temporary remission on massive doses of penicillin

In reply Dr Millar said that polyarteritis nodosa had already been reported after intoxication by a number of drugs, including several sulphonamides, thiourea, iodine, phenytoin, and even aspirin, so avoidance of potential pharmacological causes presented difficulties He agreed that remarkable recoveries in this group of diseases had occasionally followed intensive penicillin therapy, though he had had no personal experience of such massive dosage as mentioned It might be that in responsive cases there was some persisting infection as a source of circulating antigen More often neither penicillin nor anti histamine drugs seemed to influence the process He agreed also that collagen necrosis was not specific to hypersensitivity reactions, but suggested that clinical and experimental evidence as well as purely morbid anatomical considerations lent weight to the suggested relationship.

At the conclusion of the session, Sir Henry Cohen, on behalf of the Association, expressed thanks to Professor W. W D Thomson and all the Belfast members, particularly Dr Robert Marshall and Dr T H Crozier, for a most successful meeting

At 1 15 p m the members of the Association were entertained to luncheon by the Minister of Health in the Members' dining room Stormont The toast of the Association was proposed by the Minister, the Rt Hon William Grant, and Professor John Hay responded Afterwards, members were shown round the Houses of Parliament

SIR WILLIAM OSLER

At the request of the Editors, Professor W W D Thomson, President of the Association of Physicians, has kindly allowed us to publish the following extract from his speech at the Belfast Meeting of the Association

THIS centenary year of Osler's birth should be remembered gratefully by us at this meeting My younger, narrower path never crossed his older, wider orbit, and so I fain could wish that someone with a close and intimate knowledge of the man could have recalled his memory for us this evening

How highly he ranked the work done in connexion with medical societies can be realized from this passage from 'his account book' 'Completed today ten years in Oxford Extraordinarily happy years I have done three useful things or better, helped to '1 The Association of British Physicians 2 The Quarterly Journal of Medicine 3 The Historical Section of the Royal Society of Medicine '

On the other side of the Atlantic the year 1849 recalls the rush of the 'forty-niners' to the goldfields of California But there was no surplus gold to be found in the log parsonage at Bond Head near the edge of the almost unbroken primeval forest which in those days was Upper Canada, where on July 12, 1849, was born William Osler, the eighth child of the Rev Featherstone Osler and his wife, Ellen

Mr Osler had come from Cornwall and settled down as a missionary clergyman in the wilds of Canada 12 years before The young pair had endured for the first few years a life of actual and almost intolerable hardship, but at the time of which I speak the family was comfortably established at Bond Head, a growing village of some 200 people The majority of the more recent colonists were ardent Orangemen from Ulster

For some years it had been the custom of the Orangemen of the district to gather at Bond Head for their annual celebration of the Battle of the Boyne on the Twelfth of July, just as they had done in their native Ulster Adorned with sashes and orange lilies they marched to Mr Osler's parsonage where they were sympathetically and cordially received and speeches were made to the 'pious, glorious, and immortal memory' of King William On their annual visit in 1849 they learnt that a new baby boy had arrived that very day at the parsonage. The Orangemen insisted he should be called 'William' despite the original choice of his parents for the names 'Walter Farquhar' The baby was promptly dubbed the Young Prince of Orange, and 'William' he was duly christened Cushing narrates that on his subsequent birthdays, decked out in the appropriate colours of orange and blue he was brought out on the parsonage veranda to greet the procession, which the other children came to regard as arranged solely in his honour

Just as Osler in his lifetime, whether in Montreal, Philadelphia, Baltimore, or Oxford, was the teacher, friend, and fellow student to every earnest seeker after

truth in medicine, so to many of my own and later generations who were brought up on his original text-book, who have read his monographs, and who have studied and pondered his addresses, he is still the wise friend, the clinical adviser, the unseen consultant, and the peacemaker when professional friction arises His published addresses ensure the persistence of his influence 'He being dead yet speaketh' The essays in 'Aequanimitas' should be the 'Religio Medici' of every medical student and young doctor

J. M Barrie tells us 'if you have charm you don't need to have anything else' 'Osler's main strength lay in the singular and unique charm of his presence, in the sparkling brilliancy of his mind, in the rare beauty of his character and life and in the example that he set to his fellows and his students He was a quickening spirit' So wrote W S Thayer his friend and colleague at Johns Hopkins, and let me conclude with a few lines of Thayer's poem on Osler

A tongue that dances with the ready word
That like an arrow seeks its chosen goal,
A presence like the freshening breeze that as
It passes sweeps the poisoned cloud aside,
A heart whose alchemy transforms the dross
Of dull suspicion to the gold of love

INDEX OF CONTRIBUTORS

ACKROYD, J F Three Cases of Thrombocytopenic Purpura occurring after Rubella, with a Review of Purpura associated with Infections With Plate 33 299

ADAMS, E B Chronic Agranulocytosis 173

ALLCHIN, F M Ankylosing Spondylitis With Plates 29 to 32 217

BÜLBRING, E Reduction in Coronary Flow by Pituitary (Posterior Lobe) Extract in Relation to the Action of Nicotine and to Smoking 73

BURN, J H Reduction in Coronary Flow by Pituitary (Posterior Lobe) Extract in Relation to the Action of Nicotine and to Smoking 73

CAMPBELL, M Genetic and Environmental Factors in Congenital Heart Disease 379

DALEY, R Massive Dilatation of the Left Auricle With Plates 9 to 14 81

DAVIS, L J On the Nature and Significance of Stippling in Lead Poisoning, with Reference to the Effect of Splenectomy With Plates 7 and 8 57

DAVSON, J A Clinical and Pathological Study of Renal Disease Part I Nephritis With Plates 21 and 22 149

DRESNER, E Primary Optic Atrophy in von Recklinghausen's Disease (Multiple Neurofibromatosis) With Plates 15 and 16 93

FRANKS, R Massive Dilatation of the Left Auricle With Plates 9 to 14 81

GILLANDERS, A D Circulatory Dynamics in Emphysema 263

HART, F D Ankylosing Spondylitis With Plates 29 to 32 217

HERSON, R N The Ocular Manifestations of Polyarteritis Nodosa With Plate 17 123

HUBBLE, D Cushing's Syndrome and Thymic Carcinoma With Plates 18 to 20 133

HUTCHISON, J H Bronchoscopic Studies in Primary Tuberculosis in Childhood With Plates 5 and 6 21

HUTCHISON, R William Osler 275

LATNER, A L Ankylosing Spondylitis With Plates 23 to 26 187

LEATHAM, A The Retinal Vessels in Hypertension With Plates 27 and 28 203

MCFADZEAN, A J S On the Nature and Significance of Stippling in Lead Poisoning, with Reference to the Effect of Splenectomy With Plates 7 and 8 57

MACLAGAN, N F Ankylosing Spondylitis With Plates 29 to 32 217

MARKS, J The Marchiafava Michli Syndrome 105

MIDDLEMISS, J H Ankylosing Spondylitis With Plates 23 to 26 187

MONTGOMERY, D A D Primary Optic Atrophy in von Recklinghausen's Disease (Multiple Neurofibromatosis) With Plates 15 and 16 93

MOWBRAY, R Ankylosing Spondylitis With Plates 23 to 26 187

MUIR, A Carbohydrate Metabolism and Gastric Secretory Activity 235

OSWALD, N Honeycomb Lungs With Plates 1 to 4 1

PARKINSON, T Honeycomb Lungs With Plates 1 to 4 1

PLATT, R A Clinical and Pathological Study of Renal Disease Part I Nephritis. With Plates 21 and 22 149

ROBINSON, K C Ankylosing Spondylitis With Plates 29 to 32 217

ROBSON, H. N Idiopathic Thrombocytopenic Purpura 279

SAMPSON, R The Ocular Manifestations of Polyarteritis Nodosa With Plate 17 123

SHEEHAN, H L The Syndrome of Hypopituitarism With Plates 34 to 37 319

SUMMERS, V K The Syndrome of Hypopituitarism With Plates 34 to 37 319

THOMSON, W W D Sir William Osler . . . 403

WALKER, J M The Effect of Smoking on Water Diuresis in Man 51

WALKER, J M Reduction in Coronary Flow by Pituitary (Posterior Lobe) Extract in Relation to the Action of Nicotine and to Smoking 73

WITTS, L J. Chronic Agranulocytosis . . 173

INDEX

Agranulocytosis, chronic, 173
Ankylosing spondylitis, 187, 217
Auricle, left, massive dilatation of, 81, general clinical features, 81, special clinical features, 82, fluoroscopic appearances, 86
Blood, peripheral, frequency of stippling in lead poisoning in, 60
Bone-marrow, frequency of stippling in lead poisoning in, 60
Bronchoscopic studies in primary tuberculosis in childhood, 21
Carbohydrate metabolism and gastric secretory activity, 235
Carcinoma, thymic, Cushing's syndrome and, 133
Chronic agranulocytosis, 173
Circulatory dynamics in emphysema, 263
Clinical and pathological study of renal disease Part I Nephritis, 149, type 1 nephritis, 150, type 2 nephritis, 155, distinction between type 1 and type 2 nephritis, 158, note on acute focal nephritis, 160
Coronary flow, reduction in, by pituitary (posterior lobe) extract in relation to the action of nicotine and to smoking, 73, action of nicotine, 74, action of pituitary (posterior lobe) extract, 77, heart–lung preparations, 77
Cushing's syndrome and thymic carcinoma, 133 [379
Dextrocardia, Mendelian inheritance in,
Diuresis, water, in man, effect of smoking on, 51
Effect of smoking on water diuresis in man, 51
Emphysema, circulatory dynamics in, 263
Gastric secretory activity, carbohydrate metabolism and, 235
Genetic and environmental factors in congenital heart disease, 379, Mendelian inheritance in general and in dextrocardia, 379, congenital defects in general, 380, maternal rubella and other environmental factors, 381, discussion of illnesses during pregnancy, 389
Glioma, optic, incidence of, in von Recklinghausen's disease, 101
Heart disease, congenital, genetic and environmental factors in, 379, Mendelian inheritance in general and in dextrocardia, 379, congenital defects in general, 380, maternal rubella and other environmental factors, 381, discussion of illnesses during pregnancy, 389
Honeycomb lungs, 1, associated with other disorders, 1
Hypertension, retinal vessels in, 203
Hypopituitarism, syndrome of, 319, pathological lesions of the pituitary, 320, acute lesions, 322, subacute lesions, 322, chronic fibrotic lesions, 325, hypophysectomy, 330, cysts and tumours, 330, analysis of the syndrome, 333, general pathological changes, 333, state of bodily nutrition, 338, other clinical aspects, 343, laboratory investigations, 347, coma and death, 351
Idiopathic thrombocytopenic purpura, 279
Lead poisoning, on the nature and significance of stippling in, with reference to the effect of splenectomy, 57, morphological characters of stippling in, 58, iron-staining properties of stippling in, 59, frequency of stippling in bone-marrow and peripheral blood in, 60
Lungs, honeycomb, 1, associated with other disorders, 1
Marchiafava Micheli syndrome, 105
Massive dilatation of the left auricle, 81, general clinical features, 81, special clinical features, 82, fluoroscopic appearances, 86
Mendelian inheritance in general and in dextrocardia, 379
Metabolism, carbohydrate, and gastric secretory activity, 235
Nephritis, 149, type 1 nephritis, 150, type 2 nephritis, 155, distinction between type 1 and type 2 nephritis, 158
— acute focal, note on, 160
Neurofibromatosis, multiple (von Recklinghausen's disease), primary optic atrophy in, 93
Nicotine, reduction in coronary flow by pituitary (posterior lobe) extract in relation to the action of, and to smoking, 73
Ocular manifestations of polyarteritis nodosa, 123

On the nature and significance of stippling in lead poisoning, with reference to the effect of splenectomy, 57, morphological characters of stippling, 58, iron-staining properties of stippling, 59, frequency of stippling in bone-marrow and peripheral blood, 60, effect of splenectomy in guinea-pigs poisoned with lead, 62
Optic atrophy, primary, in von Recklinghausen's disease (multiple neurofibromatosis), 93, pathology of the optic-nerve tumours, 99, incidence of optic glioma in von Recklinghausen's disease, 101
Optic-nerve tumours, pathology of, 99
Osler, William, 275, 403
Pituitary (posterior lobe) extract, reduction in coronary flow by, in relation to the action of nicotine and to smoking, 73, action of pituitary (posterior lobe) extract, 77, heart-lung preparations, 77
Poisoning, lead, on the nature and significance of stippling in, with reference to the effect of splenectomy, 57, morphological characters of stippling in, 58, iron staining properties of stippling in, 59, frequency of stippling in bone-marrow and peripheral blood in, 60
Polyarteritis nodosa, ocular manifestations of, 123
Primary optic atrophy in von Recklinghausen's disease (multiple neurofibromatosis), 93, pathology of the optic nerve tumours, 99, incidence of optic glioma in von Recklinghausen's disease, 101
Proceedings of the Association of Physicians of Great Britain and Ireland, 1949 Forty-third Annual General Meeting, 393
Purpura, review of, associated with infections, 299
— thrombocytopenic, idiopathic, 279
— thrombocytopenic, three cases of, occurring after rubella, with a review of purpura associated with infections, 299, investigation of cases of uncomplicated rubella, 306
Reduction in coronary flow by pituitary (posterior lobe) extract in relation to the action of nicotine and to smoking, 73, action of pituitary (posterior lobe) extract, 77, heart-lung preparations, 77
Renal disease, clinical and pathological study of Part I Nephritis, 149, type 1 nephritis, 150, type 2 nephritis, 155, distinction between type 1 and type 2 nephritis, 158, note on acute focal nephritis, 160
Retinal vessels in hypertension, 203
Rubella, three cases of thrombocytopenic purpura occurring after, 299
Smoking, action of, reduction in coronary flow by pituitary (posterior lobe) extract in relation to the action of nicotine and to, 73
— effect of, on water diuresis in man, 51
Splenectomy, effect of, on the nature and significance of stippling in lead poisoning, with reference to, 57, in guinea-pigs poisoned with lead, 62
Spondylitis, ankylosing, 187, 217
Stippling in lead poisoning, on the nature and significance of, with reference to the effect of splenectomy, 57, morphological characters of, 58, iron staining properties of, 59, frequency of, in bone-marrow and peripheral blood, 60
Syndrome of hypopituitarism, 319, pathological lesions of the pituitary, 320, acute lesions, 322, subacute lesions, 322, chronic fibrotic lesions, 325, hypophysectomy, 330, cysts and tumours, 330, analysis of the syndrome, 333, general pathological changes, 333, state of bodily nutrition, 338, other clinical aspects, 343, laboratory investigations, 347
Three cases of thrombocytopenic purpura occurring after rubella, with a review of purpura associated with infections, 299, investigation of cases of uncomplicated rubella, 306
Thrombocytopenic purpura, idiopathic, 279
— three cases of, occurring after rubella, with a review of purpura associated with infections, 299, investigation of cases of uncomplicated rubella, 306
Thymic carcinoma, Cushing's syndrome and, 133
Tuberculosis, primary, in childhood, bronchoscopic studies in, 21
Tumours, optic nerve, pathology of, 99
von Recklinghausen's disease (multiple neurofibromatosis), primary optic atrophy in, 93, optic glioma in, 101
Water diuresis in man, effect of smoking on, 51